

3.A.43.

This work must be consulted
in the Boston Medical Library
8 Fenway

Accessions

Shelf No.
3749.2

SIC UT PATRIBUS SIT DEUS NOBIS
BOSTONIA
CONDITAD
1630
CIVITATIS REGIMINE DONATA A.D. 1822
JONATHAN PHILLIPS, DIED, 1869.
BOSTON PUBLIC LIBRARY

FROM THE
Phillips Fund.

Added

S. FEB 15
K NOV. 8
OCT 18
K MAR 29

Digitized by the Internet Archive
in 2011 with funding from
Open Knowledge Commons and Harvard Medical School

http://www.archive.org/details/demonstrationsof00elli

DEMONSTRATIONS

OF

A N A T O M Y;

BEING

A GUIDE TO THE DISSECTION

OF THE

HUMAN BODY.

BY

GEORGE VINER ELLIS,

ONE OF THE DEMONSTRATORS OF ANATOMY IN UNIVERSITY COLLEGE.

LONDON:

PRINTED FOR TAYLOR AND WALTON,

BOOKSELLERS AND PUBLISHERS TO UNIVERSITY COLLEGE,

UPPER GOWER STREET.

1840.

LONDON:
Printed by A. SPOTTISWOODE,
New-Street. Square.

PREFACE.

ANATOMY may be studied in two different methods, the one demonstrative, and the other descriptive: — the former treats of the parts only as they are exposed in dissection, and of their relative position; the latter gives minute details of objects unseen, describing the different structures without reference to the order in which they appear, and has been very generally employed in the numerous works of instruction in practical anatomy; but every one acquainted with the difficulties to be overcome by the young dissector will readily admit that this method is insufficient as a guide to his progress.

To supply this deficiency the present work, designed and completed from the subject, and confirmed by experience, is humbly submitted to the student, in the hope that his labours will be diminished, and the advantages to be gained in the pursuit of practical knowledge increased. In the execution of the plan, the great divisions of the body which are generally established, viz. head and neck, thorax, back, extremities, and abdomen, have been placed in different sections, and the dissection of each has been conducted by the employment of successive stages, determined either by certain apparently natural limits, or by those most convenient in practice; — by means of full directions for the performance of the different steps; — by describing at one time only so much of a part as is visible; — and by noting each as it appears. In the completion of the detail I have not been regardless of the information

to be obtained from the best anatomical works; and I have also received much assistance from my friend Mr. James Harrison, by whom the practicability of the instructions has been fully confirmed, and to whom I am much indebted for his readiness to forward my views.

That the dissector may survey at one glance the different parts in their order of succession, side notes have been introduced in each page; and to remove any difficulty consequent upon a previous unacquaintance with the numerous branches of any vessel or nerve, tables of these and of the actions of the muscles have been inserted at the end of each section.

In conclusion, I gladly take this opportunity of expressing my obligations to Dr. Sharpey, for his valuable advice and suggestions, and for a perusal of his manuscript notes on the membranes of the spinal cord.

University College,
October 31st.

CONTENTS.

	Page
Dissection of the Head and Neck	1
Dissection of the Brain — its Membranes and Vessels	9
The Base of the Skull, with the Dura Mater and Nerves	54
Dissection of the Face	64
Dissection of the Orbit	87
Dissection of the Eye	102
Posterior Triangle of the Neck	114
Dissection of the Back	121
Dissection of the Spinal Cord — its Membranes and Vessels	149
The Anterior Triangle of the Neck	158
Dissection of the left Side of the Head and Neck	224
Dissection of the Pharynx	230
Cavity of the Mouth	240
Dissection of the Nose	242
Deep Nerves and Vessels of the Head	246
Dissection of the Tongue	255
Dissection of the Larynx	258
Continuation of the Neck — *Deep Muscles and Ligaments*	269
Dissection of the Ear	279
Table of the Arteries of the Head and Neck	297
Table of the Veins, &c.	298
Table of the Cranial Nerves, &c.	299
Table of the Spinal and Sympathetic Nerves, &c.	300
Table of the Actions of the Muscles, &c.	301
Dissection of the Upper Extremity	303
Dissection of the Thorax	324
Dissection of the Shoulder and Scapular Region	366
Dissection of the Arm	375
Dissection of the Forearm	391
Dissection of the Palm of the Hand	406
Dissection of the Back of the Forearm	421
Continuation of the Upper Extremity — *the Ligaments*	431
Table of the Arteries of the Upper Extremity and Thorax	441
Table of the Veins of the Extremity, &c.	442
Table of the Spinal Nerves, &c.	444
Table of the Muscles, &c.	445
Table of the Sympathetic Nerve in the Thorax	446
Dissection of the Perinæum	447
Dissection of the Female Perinæum	466
Dissection of the Abdomen	468
Dissection of the Cavity of the Abdomen	504
Dissection of the Pelvis	571
Dissection of the Female Pelvis	586
Anatomy of the Female Generative Organs	607

Page
Continuation of the Abdomen — *the Ligaments* - - 610
Table of the Arteries of the Abdomen and Perinæum - - 617
Table of the Veins, &c. - - - - - 618
Table of the Spinal Nerves, &c. - - - - 619
Table of the Sympathetic Nerves of the Abdomen - - 620
Table of the Actions of the Muscles of the Abdomen, &c. - 620

Dissection of the Lower Extremity - - - - 621
Dissection of the Back of the Thigh - - - - 659
Dissection of the Back of the Leg - - - - 682
Dissection of the Sole of the Foot - - - - 691
Dissection of the Front of the Leg - - - - 705
Continuation of the Lower Extremity — *the Ligaments* - 715
Table of the Arteries of the Lower Extremity - - 732
Table of the Veins of the Extremity - - - - 733
Table of the Spinal Nerves, &c. - - - - 734
Table of the Actions of the Muscles, &c. - - - 735

ERRATA.

Page 2. line 15. for "flaps," read "flap."
16. line 42. for "branch," read "root."
28. line 6. for "that," read "these."
30. line 23. for "fourth," read "third."
30. 33. } passim, for "medulla incognita," read "medulla innominata."
63. line 32. for "inferior longitudinal," read "inferior petrosal."
66. line 27. for "depressor," read "compressor."
99. line 26. for "sphenoidal," read "spheno-maxillary."
160. line 32. for "body," read "cartilage."
162. line 46. for "thyro-hyoid," read "sterno-thyroid."
163. line 23. 196. line 41. } for "sublingual," read "submental."
201. line 16. for "os hyoides," read "tongue."
225. line 31. for "internal," read "common."
228. line 38. insert the word "dorsal," after the word "tenth."
338. line 9. for "descending," read "ascending."
347. line 47. for "lyrinx," read "larynx."
356. line 38. for "right," read "left."
line 39. for "left," read "right."
393. line 38. for "ulnar," read "ring."
397. line 3. for "passes," read "pass."
408. line 16. for "plantar," read "palmar."
423. line 13. for "again," read "also."
477. line 41. for "internal," read "external."
548. line 45. for "Its," read "Their."
594. line 9. for "which are inferior," read "the former being superior."
597. line 23. for "inferior," read "superior."

299. Portio dura of the seventh nerve *for*
- cervico-facial — temporal / malar / infra-orbital.
- temporo-facial — Buccal / supra-maxillary / infra-maxillary.

read
- cervico-facial — Buccal / supra-maxillary / infra-maxillary.
- temporo-facial — temporal / malar / infra-orbital.

DEMONSTRATIONS

OF

ANATOMY.

DISSECTION OF THE HEAD AND NECK.

In the dissection of this part, the subject is placed on the back; the head is to be raised to a convenient height, by means of blocks, and the external parts of the head are to be first examined, preparatory to removing the brain. The integument of the scalp is thick and dense, and beneath it is a granular cellular tissue which is to be removed with care, so as not to injure the cutaneous vessels and nerves contained in it, or the occipito-frontalis and the small muscles of the ear, which are situated between it and the cranium. The position of the small muscles of the ear is marked by projections between the side of the head and the auricle, when the ear is drawn in different directions; the prominence above the ear corresponding to the position of the attollens and attrahens aurem muscles, and that behind it, to the retrahens aurem. For the dissection of the muscles of the right ear, turn the face to the left side, and draw the ear downwards with hooks; make an incision upwards, on the side of the head, about three inches in length, and along the centre of the projection of the attollens and attrahens aurem muscles *; a second incision of the same extent is to be made transversely, above the ear, and the flaps of skin are to be raised. By removing some cellular membrane, the thin muscular fibres are seen to radiate upwards on the side of the head; the most anterior constituting the attrahens, and the most posterior the attollens aurem muscle; and beneath the anterior fibres are the superficial temporal vessels and nerve. To expose the retrahens aurem, fasten forwards the ear, and carry a vertical incision behind it, from the extremity of the one already made above, to a level with the lower part of the lobe, and from this point,

Dissection.

* When the integument is to be divided, the incision is never to pass deeper than the skin, unless the contrary be specified.

another forwards, below the auricle; raise the flaps of integument included by these lines towards the ear, and next remove it from the back of the auricle; the fibres of this muscle are covered by a fascia much denser than that which covers the other muscles, and they are collected into distinct bundles or fasciculi; on the mastoid process, are the posterior auricular nerve and artery which give branches to the back of the auricle. The occipito-frontalis muscle is exposed by removing the remaining portion of the integument from this half of the head; and, for this purpose, divide it by an incision over the vertex of the head, from the centre of the forehead, a little above the nose, to an inch below the occipital protuberance; from its front, carry a transverse incision above the eyebrow, to join that for the dissection of the muscles of the ear; raise the flaps of skin, without cutting the cutaneous vessels and nerves, or the thin tendon of the occipito-frontalis muscle, which intervenes between its anterior and its posterior fleshy portion; leave the flap connected to the integuments at the back of the head. Numerous arteries, veins, and nerves are found in the cellular structure superficial to the occipito-frontalis, and they are to be examined before the muscles.

In front of the head are the supra-orbital and frontal arteries and veins, with the branches of the supra-orbital nerve, from the first division of the fifth; on the side of the head, the superficial temporal vessels, with the auriculo-temporal nerve of the third division of the fifth, the cutaneous branches of the portio dura nerve, and also those of the orbital branch of the second division of the fifth nerve; and behind are the occipital vessels, with the large and small occipital nerves, a cutaneous branch from the posterior division of the third cervical nerve; and near the ear, the posterior auricular vessels, and the nerve of the same name from the portio dura. The same dissection is to be repeated on the opposite half of the head.

Supra-orbital Artery.

The *supra-orbital artery*, a branch of the ophthalmic in the orbit, leaves this cavity by passing through the supra-orbital notch with its vein and accompanying nerve; it is placed, at first, beneath the fleshy fibres of the occipito-frontalis and orbicularis palpebrarum muscles, and it divides into two branches: — one becomes superficial by perforating the occipito-frontalis, and it ascends towards the top of the head, to supply the integument and the muscle; the other remains beneath the muscle, and supplies it and the periosteum. This artery anastomoses on the forehead with the anterior branch of the temporal artery, which turns forwards to join it.

Frontal Artery.

The *frontal artery*, a branch, also, of the ophthalmic in the orbit, is smaller than the preceding, internal to which it is placed; its course is upwards, in the direction of the supra-orbital, which it joins, and its branches of distribution go to the integuments, muscles, and periosteum.

The *superficial temporal artery* can be seen, now, only in its terminal or cutaneous part. It is a branch of the external carotid, and it appears in front of the ear, after it has escaped from the parotid gland: it ascends beneath the fibres of the attrahens aurem muscle; and, placed on the deep temporal fascia, it divides into its two branches: — the *anterior* runs forwards, in a serpentine course, on the side of the head, superficial to the fascia; and, on the forehead, it divides into branches which supply the integuments and muscles, whilst others anastomose with the supra-orbital and frontal arteries: the *posterior*, larger than the other, passes backwards, along the side of the head, above the ear, and superficial to the temporal fascia; and, in the occipital region, it divides into branches that anastomose with the occipital and posterior aural arteries: this branch supplies also the integuments, occipito-frontalis, and periosteum. In a well-injected subject, this artery is seen to anastomose with the one of the opposite side. The anterior division of this artery is the one selected for arteriotomy. Superficial Temporal Artery.

The *occipital artery* is the large trunk which occupies the occipital region of the head, with the branches of the great occipital nerve. The terminal portion of the artery perforates the attachment of the trapezius muscle, and it divides into large and tortuous branches which diverge from each other over the occipital bone, and anastomose with the artery of the opposite side, with the posterior auricular, and posterior branch of the temporal artery: other branches pass deeply to supply the occipito-frontalis, the periosteum, and the bone. Occipital Artery.

The *posterior auricular* artery appears in front of the mastoid process, with its nerve, and it soon divides into two branches; the *external* runs outwards over the mastoid process, to supply the occipito-frontalis and the integument, and to anastomose with the occipital; the *internal* or proper *auricular* branch ascends to the auricle, supplies the retrahens muscle and the posterior surface of the ear, and it sends a branch through the auricle to the other surface, on which it is distributed. Posterior Auricular Artery.

The *veins* of the exterior of the head accompany the arteries, and are very similar in their course and anatomy; but, unless they are injected, or distended with blood, they are not very apparent. The *frontal* commences in a plexus which is situated over the upper part of the forehead, between the integument and epicranial aponeurosis, and is formed by the ramifications of this vein and the temporal; the vein then descends towards the root of the nose, and joins a transverse arch,— the *nasal arch*. Into this arch, the *supra-orbital vein* also opens, but this branch lies beneath the muscles, and is joined by the vein from the upper eyelid; from the extremity of the arch arises, below, the *angular vein*, which is continued into the facial. The *superficial temporal* vein is large, and it presents numerous ramifications Veins.

which extend upwards to the top of the head, and forwards and backwards with the temporal artery; near the zygoma it is joined by a deep branch, and beneath the parotid it unites with the internal maxillary, in the external jugular vein. The *posterior auricular* vein has the same distribution as the artery: it descends with it beneath the parotid, and, after the union of the *stylo-mastoid vein*, it joins the common trunk of the internal maxillary and superficial temporal, to form the external jugular. The *occipital* commences on the back of the head, follows the same course as the artery, and it opens into either the internal or the external jugular. Beneath the splenius muscle it receives a branch from the lateral sinus through the mastoid foramen. The veins outside the skull join those within, by means of small branches that pass through the sagittal suture, or through the parietal and mastoid foramina.

Cutaneous Nerves.

The nerves, like the arteries, are only the cutaneous portions of branches to be afterwards dissected.

Supra-orbital Nerve.

The *supra-orbital* nerve, a continuation of the frontal branch of the ophthalmic, leaves the orbit by the supra-orbital foramen, and it is covered, at first, by the occipito-frontalis and orbicularis muscles. The first filaments given off from it supply the eyelid; and others run transversely outwards in the orbicularis muscle, in which they join with the portio dura nerve. The nerve finally divides into two branches: the *internal*, placed, at first, beneath the occipito-frontalis, ascends on the frontal bone, perforates the muscle, and it is distributed to the integuments; the *external*, the larger of the two, lies, for a greater distance, beneath the muscle, with the external branch of the artery; but it perforates the muscle, and is distributed to the integuments with the internal branch: these filaments of distribution can be followed to the upper and back part of the head, or, in favourable subjects, near to the lambdoidal suture. This nerve gives some filaments to the periosteum.

Temporal branch of the Superior Maxillary Nerve.

The *cutaneous temporal filaments* of the *orbital branch* of the second division * of the fifth nerve differ much in size in different subjects. The temporal branch of this nerve perforates the temporal fascia about a finger's breadth above the zygoma, and either near the orbit, or about midway between it and the ear, and it divides into many filaments; some join the branches of the portio dura nerve that ascend, over the zygoma, to unite with the branches of the supra-orbital nerve, and to supply the orbicularis; and others are distributed to the integuments over the temporal fascia. The branches of the portio dura that cross the temporal fascia will be dissected with the face.

* These branches are sometimes described as cutaneous filaments of the deep temporal nerves of the third division of the fifth; but we have always found them to be derived from the second branch, as described by Meckel,—"*de quinto pare nervorum cerebri*," in the Scriptores Neurologici (Ludwig), tom. i. § lix.

The *temporal branch* of the *auriculo-temporal nerve* of the third division of the fifth, is placed nearer the ear than the preceding. The branches of this nerve accompany the superficial temporal artery, which is the guide to them: they are very long and small, and, near the ear, lie deeper than the artery; but as they ascend, they become more superficial, and they give off very few lateral branches until they reach the top of the head, on which they are distributed to the integument. Near their termination, these nerves are crossed by the long posterior branches of the supra-orbital nerve. Before the nerve becomes cutaneous, it gives filaments to the ear. Temporal branch of the Inferior Maxillary Nerve.

The *great occipital nerve,* or cutaneous portion of the posterior branch of the second cervical nerve*, is the largest of the cutaneous nerves at the back of the head; and it is always recognised by its proximity to the occipital artery. It perforates the trapezius muscle, and divides into numerous large branches which cover the occipital region: these ascend, diverging, as high as the upper part of the occipital bone, and they end by supplying the integument. This nerve joins, externally, with the small occipital nerve, and it is altogether distributed to the scalp. Great Occipital Nerve.

The *cutaneous* or *occipital portion* of the posterior branch of the third cervical nerve, smaller than the great occipital, is placed also internal to it: it ends in the integuments nearer the middle line than the preceding nerve, and it is nearer the neck than it. Occipital portion of the Third Cervical Nerve.

The *small occipital nerve,* situated external to the great occipital, or about midway between it and the ear, is one of the ascending branches of the cervical plexus. The nerve perforates the fascia of the neck at the posterior border of the sterno-mastoid muscle, and below the superior transverse ridge of the occipital bone; it then ascends in the integuments parallel to the great occipital nerve, but external to it, as high as to the upper part of the occipital bone; and it ends in the integuments. The internal filaments join those of the great occipital; and, when the nerve is large, it frequently gives off an *auricular* branch which supplies the upper half of the posterior surface of the ear, and joins the posterior auricular nerve. Small Occipital Nerve.

The *posterior auricular nerve,* a branch of the portio dura of the seventh pair, is rather small in size, and it is found in front of the mastoid process, with the posterior auricular artery. The nerve is given off as soon as the portio dura has left the stylo-mastoid foramen, and it becomes superficial by turning over the anterior surface of the mastoid process; it then ascends in front of this process, is joined by a branch of the great Posterior Auricular Nerve.

* In this arrangement, the sub-occipital nerve is reckoned the first cervical nerve.

auricular nerve of the cervical plexus, and it divides into an auricular and an occipital branch. The *occipital* runs transversely inwards across the mastoid process, and along the superior transverse ridge of the occipital bone, to reach the posterior part of the occipito-frontalis muscle, in which it ends: this branch lies, at first, close to the bone, in a dense cellular structure, and it afterwards crosses beneath the great occipital nerve. The *auricular branch* ascends towards the ear, perforates the fibres of the retrahens aurem muscle, to which it gives filaments, and it ends by being distributed to the upper part of the posterior surface of the auricle of the ear.

Occipital branch.

Auricular branch.

The great auricular nerve is also partly dissected at its distribution to the lower part of the ear; but its anatomy will be seen with the cervical plexus.

Attrahens Aurem Muscle.

The *attrahens aurem muscle* is formed by the most anterior of the radiating muscular fibres above the ear, and, at its upper attachment, its fibres are joined with those of the attollens; but, below, a cellular interval separates the two. The muscle is of a conical form, and the fibres *arise*, above, from the outer or cutaneous surface of the tendon of the occipito-frontalis muscle, near its anterior fleshy portion; the fibres pass downwards and slightly backwards, and they converge, to be *inserted* into the front of the helix. The muscle is subcutaneous, but it covers the superficial temporal vessels and the temporal aponeurosis. This muscle is oftentimes very indistinctly seen.

Origin.

Insertion.

Relations.

Attollens Aurem Muscle.

The *attollens aurem muscle*, more strongly marked than the preceding, is of the same shape. It *arises* from the tendon of the occipito-frontalis, and the fibres converge, below, to be *inserted* into the projecting part of the posterior surface of the concha. The muscle is subcutaneous, and it lies over the temporal fascia, a thin prolongation from the margin of the tendon of the occipito-frontalis intervening between the two. The anterior border is united with the attrahens muscle.

Origin.

Insertion.

Relations.

Retrahens Aurem Muscle.

The *retrahens aurem muscle*, situated behind the ear, consists of shorter and stronger muscular fibres than are found in either of the other two, and they are collected into three or more fasciculi, constituting the *musculi retrahentes* of Albinus. The fibres of the muscle *arise* from the outer surface of the mastoid process, they pass transversely inwards, and are *inserted*, by aponeurotic fibres, into the lower part of the posterior surface of the concha. This muscle is covered by a strong fascia, and the posterior auricular artery and nerve are in contact with it.

Origin.

Insertion.

Relations.

Occipito-frontalis Muscle.

The *occipito-frontalis muscle*, placed on the upper convex part of the skull, consists of an anterior and a posterior fleshy portion, and of an intervening tendon or epicranial aponeurosis; and it will be rendered more evident by removing the cutaneous vessels and nerves from it, as well as any cellular membrane that may remain on it. The *anterior* or *frontal portion* is a thin

Frontal portion.

muscular expansion over the frontal bone, and the strength of its fibres varies much in different subjects: the fibres of this part of the muscle are united, below, with those of the orbicularis palpebrarum and corrugator supercilii muscles; but, nearer the middle line, they are attached to the internal angular process of the os frontis, and a pyramidal slip — the pyramidalis nasi muscle — is prolonged on the nasal bone; from this origin, the fibres ascend with a direction outwards, the external being longer than the internal, and they end in the epicranial aponeurosis a little below the line of the coronal suture: their point of union with the tendon presents a semilunar line with the convexity turned upwards. The *posterior* or *occipital portion*, more muscular than the anterior, is somewhat of a square shape like it; it *arises*, by aponeurotic fibres, from the outer two thirds of the superior curved line of the occipital bone, and slightly from the mastoid portion of the temporal; the fibres ascend obliquely inwards to join the aponeurosis. The *epicranial aponeurosis*, or *galea capitis*, is the common tendon into which the frontal and occipital portions of the muscle are inserted, and it gives attachment also to the two anterior auricular muscles. It is a white shining tendon, which reaches in front to the frontal, and behind to the occipital region; internally, it joins the corresponding tendon of the muscle of the opposite side, and, externally, a thin fascia is prolonged from it over the temporal aponeurosis, but a defined semilunar border may be given to it by removing this with the scalpel. The cutaneous surface of the muscle is covered, in front, by the supra-orbital and frontal vessels and supra-orbital nerve; behind, by the occipital vessels and nerves; on the side, by the temporal vessels and nerve, and auricular muscles; and it is closely united to the skin. The anterior part or origin is united with the orbicularis and corrugator supercilii; the attachment of the posterior part corresponds to the insertion of the sterno-mastoid muscle; and the muscle lies on the arch of the skull; but a loose cellular membrane which intervenes between the tendon of the muscle and the pericranium allows the tendon to move freely on the bone beneath.

Origin

Insertion.

Occipital portion.

Origin.

Insertion.

Epicranial Aponeurosis.

Relations.

Examine the temporal fascia and the origin of the temporal muscle on the left side of the head, and leave them untouched on the right: the utility of this step will be perceived in a future stage of the dissection. To expose the deep temporal fascia, it will be necessary to take away the auricular muscles, the epicranial aponeurosis, and the prolongation from it over the fascia.

Dissection.

The *temporal aponeurosis* or *fascia* is a dense, white, shining structure, much stronger than the epicranial aponeurosis, and it conceals the temporal muscle, to which it gives attachment. It is wide above, and is inserted into the curved line that bounds the temporal fossa on the side of the skull; but, below, it is

Temporal Aponeurosis.

narrower and thicker, and it is fixed to the zygoma. The cutaneous surface of the fascia is covered by the two anterior muscles of the ear, and the prolongation from the epicranial aponeurosis, by the superficial temporal vessels and nerve, by the branches of the portio dura nerve, and the filaments of the orbital branch of the superior maxillary, which perforate the fascia to join with the portio dura. Make a transverse incision in the fascia, a little above the zygoma; it will be found to consist of two layers, attached to the outer and inner edges of this process, and between them is an interval filled with a granular cellular tissue that varies in quantity in different subjects. In this space is a small artery from the temporal, and it is directed forwards to the orbicularis muscle, to which it is distributed, after perforating the fascia; the cutaneous temporal nerve, from the orbital branch of the second division of the fifth, is also seen between the two layers of the fascia, before it becomes cutaneous. Detach the connection of the fascia to the skull, and throw it down; it is thinner in the upper than the lower part; it conceals the temporal muscle which arises from it, and near the zygoma it is separated from the muscle by a soft cellular tissue.

Temporal Muscle. Origin.

The *temporal muscle*, situated in the temporal fossa, is wide and thin above, but it is pointed and thick below, near its insertion. The fibres of the muscle *arise* from the line which bounds, above, the temporal fossa, from the surface of the fossa as low as to the ridge of the outer surface of the great wing of the sphenoid, and also from the fascia that covers the muscle; from these parts of origin the fibres descend, and they converge, the anterior passing obliquely backwards and downwards, the posterior forwards, and the middle vertically, to be *inserted* around a tendon which is at first concealed in the centre of the muscle; but it finally escapes from the muscular fibres, and it is inserted into the under surface of the coronoid process of the lower jaw. The insertion of the muscle, as well as the direction outwards and forwards of the lower deep fibres, will be dissected with the pterygoid region.

Insertion.

Relations.

The muscle is covered by the integuments, anterior muscles of the ear, and the temporal fascia with the cutaneous nerves and vessels before seen on it, also by the zygoma and the masseter muscle attached to it; and the muscle lies on the temporal fossa, the deep temporal vessels and nerves, together with the external pterygoid muscle. The distribution of the deep temporal nerves and vessels, in the substance of the muscle, may be followed by scraping through its fibres.

Dissection.

Throw down the temporal muscle of the right side from the bone, together with its fascia, without, however, separating one from the other, as low as to a level with the eyebrow or upper part of the orbit; then make an incision around the skull, and let it pass in front, one inch above the superciliary ridge of the

orbit, and, behind, close above the protuberance of the occipital bone. Saw the skull in the line of the incision, and when the outer table is divided, use the chisel and mallet to cut through the inner; remove now the calvaria, or skull-cap: a chisel may be introduced at first, to separate the sawn surfaces, but afterwards it may be forcibly torn from the dura mater by the fingers. In some subjects there may be morbid adhesion between the calvaria and dura mater, and it will be necessary to cut the membrane on a level with the sawn bone, before the skull can be removed. When this is taken away, the dura mater is exposed.

DISSECTION OF THE BRAIN — ITS MEMBRANES AND VESSELS.

The *dura mater*, or external investing membrane of the brain, is a strong fibrous membrane of a greyish colour; it is formed by fibres that cross in different directions, and give rise to two layers that may be separated from each other. The membrane serves as an internal periosteum, in which the vessels ramify, before entering the bone, and the outer surface is rough, and covered by numerous small fibrous and vascular processes which have been torn from their osseous canals. These are more numerous along the line of the sutures than elsewhere; for the attachment of the membrane to the centre of the frontal and occipital bones, and to the squamous portion of the temporal bone, is very slight, and easily separated. The vessels now seen are the middle meningeal artery and veins which ascend, and give off many branches towards the top of the head, to supply the dura mater and the bone. From the inner surface, processes are sent inwards, to support the different portions of the brain; and these are formed by a separation of the internal from the external fibrous layer. Between the layers are canals, named sinuses, which receive the venous blood; they communicate with the veins external to the skull through the apertures in it, and they are lined by the same membrane as the veins in the other parts of the body; some of these are triangular, some circular; and they are formed, also, by the separation of the two layers of the membrane. Dura Mater.

The *superior longitudinal sinus*, named from its position, may be examined before the brain is removed. It is placed along the centre of the dura mater, and corresponds to the middle of the frontal bone, to the line of union of the parietal, and to the centre of the occipital as low as the occipital protuberance. In this extent, it receives numerous small veins from the diplöe between the tables of the skull, as well as from the veins ex- Superior Longitudinal Sinus.

ternal to the skull; the extremities of these vessels, that have been ruptured by the forcible separation of the skull-cap, will be seen by carrying the finger along the sinus from before backwards, when the blood will escape from them. Cut open the sinus, with a scissors, from the front to the posterior part. It is narrow in front, and wide behind, it commences at the crista galli of the ethmoid bone, and joins sometimes a small vein of the nose; and it ends opposite the occipital protuberance, by joining in a common point of union, the torcular Herophili, with some of the other sinuses of the brain. The cavity of the sinus is triangular, the base being formed by the external layer, and the sides by the internal layer, which is then prolonged between the hemispheres, as the falx cerebri. In the interior of the sinus

Chordæ Willisii.

are small transverse tendinous bands, the *chordæ Willisii*, which extend from one side to the other, and surround the apertures

Glandulæ Pacchioni.

of the veins in the sinus. Small granular bodies, the *glandulæ Pacchioni*, are found either in the interior of the sinus, or external to it. They vary much in size and number in different subjects, and a greater number are found in old age than in youth; those external to the sinus may be either superficial to the dura mater or beneath it: the glands superficial to it are oftentimes large enough to mark the surface of the skull. The origin and use of these bodies are uncertain.

Dissection.

Cut through the dura mater with a scissors, on a level with the sawn skull, but leave untouched, in the middle line, both before and behind, the superior longitudinal sinus; raise the two lateral portions of the dura mater towards the superior longitudinal sinus, without detaching, from the sides of the sinus, the veins that enter it from the exterior of the hemispheres.

The inner surface of the dura mater, now exposed, differs much from the outer, since it is smooth and polished, and it is

Veins of the Sinus.

lined by the arachnoid, or serous membrane of the brain, which is reflected over it. Besides the small veins from the exterior of the skull, and the veins of the diplöe, the superior longitudinal sinus receives many large veins from the surface of the cerebrum, and the greater number of these are at the back and upper part of the hemispheres; they run upwards and inwards to the wall of the sinus; but, before perforating it, they are connected to it, for a certain distance, by the arachnoid, so that the part of the vein on the wall of the sinus is at a right angle to the rest of the trunk, and the current of blood circulating in it runs from behind forwards, in a direction the opposite to that in the sinus; a probe passed into the veins, either from the sinus, or by an aperture in the vein, will show the extent of the vein on the side of the sinus, before it perforates to open into it. The cerebral veins which open into the fore part of the sinus are very small, and they do not change their direction before opening into it; but they run almost horizontally inwards to join it.

Detach the veins on one side from the sinus, separate slightly the same hemisphere of the brain from the middle line, and a process of the dura mater is seen to project downwards, between the two halves or hemispheres of the brain; this has been named the *falx*, from its resemblance to a sickle. It is narrow and pointed, in front, at its attachment to the crista galli of the ethmoid bone, and wide behind, at its junction with another process of the dura mater, — the tentorium cerebelli which is stretched horizontally between the cerebrum and cerebellum. The upper border, convex, and largest in extent, is fixed to the crista galli, to the centre of the frontal bone, to the line of union of the parietal bones, and to the centre of the occipital, as far as its protuberance; the superior longitudinal sinus is contained in this border. The lower border, concave, is in contact behind with the corpus callosum, but, in front, it is at a considerable distance above it: in this border, the inferior longitudinal sinus is contained. The base of the process joins the tentorium along its middle line, the straight sinus lies along the line of junction of these two processes, and into the fore part of this sinus the veins of Galen open, after they have passed from beneath the corpus callosum: these parts will be seen by gently raising the posterior lobes of the brain. The lateral surfaces of the falx are in contact with the hemispheres between which it is placed. Falx Cerebri.

Cut across the attachment of the falx to the crista galli, as well as the different veins that enter the sinus; throw the falx backwards, and proceed to remove the brain. The parts that retain the brain in the skull are, the tentorium, fixed over the cerebellum; the prolongation of the medulla spinalis; the nerves that leave the brain, and the vessels that enter for its supply. Raise the shoulders by blocks, and incline the head backwards, that the brain, by its own weight, may be separated from the base of the skull. A very sharp knife will be required for the division of the nerves; and, on the right side, they should be cut at a distance from the apertures of transmission, but, on the other, close to the foramina; so that their origin will be best seen on the one side of the brain, and their exit through the foramina in the base of the skull at the opposite side. The following description applies to only one side, but the same is to be done on the opposite. Raise the anterior lobes of the brain from the orbital plates of the frontal bone, with the olfactory nerve that forms an enlargement on the side of the crista galli; behind this is the commissure of the optic nerves, and the large optic nerve diverges from it on each side, to enter the optic foramen, internal to the carotid artery: it is to be cut across. Divide, now, the internal carotid, which is placed between the optic and third nerves; and then support the brain with the left hand. Dislodge the pituitary body from its fossa, by dividing around it the arachnoid membrane that binds it Dissection.

down, and the anterior and posterior portions of the circular sinus may be seen before and behind it; next cut through the third nerve, or motor oculi, which lies outside the carotid, and rather below it, and perforates the dura mater close to the anterior clinoid process; as well as a small artery that passes from the cranium to the orbit, through a foramen below the small wing of the sphenoid bone. Along the free margin of the tentorium which still retains the brain, is the small fourth nerve; it perforates the margin of the tentorium near the posterior clinoid process: cut it across, and divide the tentorium, on each side, close to its attachment to the petrous portion of the temporal bone, by an incision from the posterior clinoid process to the occipital bone; if the knife be carried too deeply, the fifth nerve and cerebellum will be injured. Beneath the tentorium are found the following nerves, and they are to be divided in the order in which they are met with: — the fifth, or trifacial nerve, is close to the tentorium, and it consists of an anterior small, and a posterior large portion. The sixth extends forwards in the middle line to the posterior part of the body of the sphenoid bone: it is a long slender nerve. Below the fifth, and behind it, is the seventh nerve, which enters the meatus auditorius internus; like the fifth, it has a small anterior portion, — the portio dura, and a large posterior, — the portio mollis. Directly below the seventh, is the eighth nerve, which consists of three distinct portions: — the upper one, the smallest, is the glosso-pharyngeal, it runs upwards and outwards to the foramen lacerum; the next below is the pneumo-gastric, this is the largest nerve, and leaves the skull by the same aperture; and the third, a long round nerve, the spinal accessory, enters the skull through the foramen magnum; and, in its course to the foramen, by which the others pass, it lies so close to the margin of the foramen magnum that it is difficult to cut it. The only remaining nerve is the ninth, or hypoglossal, a small nerve, in the middle line; it is divided into two portions, and it leaves the skull by the anterior condyloid foramen. After the nerves, the vertebral arteries are to be divided, as they wind round the upper part of the medulla oblongata. When all these parts are cut on each side, let the brain pull, very slightly, upon the medulla oblongata, which alone retains it; pass a knife into the spinal canal as far as can be done, with the surfaces directed forwards and backwards, and then divide the medulla by turning the edge backwards; cut through also any filaments of the spinal nerves that pass laterally from the medulla, and raise the medulla oblongata from the canal, by means of the first and second fingers introduced into it. Place the brain, with its base uppermost, in the centre of a small cloth coiled round; and take care that the parts be not too much crowded together; examine first the remaining membranes of the brain.

The *arachnoid membrane*, named from its tenuity, is the thin serous membrane that lines the internal surface of the dura mater, and gives to it the smooth and polished surface. The arachnoid, like the other serous membranes, is a closed sac which is reflected around the walls of the cavity and the viscus situated in it, and it contains only a thin serous vapour that lubricates the surfaces. That portion of it which lines the dura mater, or the *parietal* layer, is inseparably united to this fibrous membrane, and it is continued over the processes of the dura mater, which project between the different parts of the brain; but that which covers the brain, or the *visceral* layer, is separated from the brain by a considerable interval which is much increased in extent on the under surface, and is dilated into the sub-arachnoid spaces. Around the vessels and nerves that pass by the cranial apertures, it gives processes which extend for a short way, on these, through the apertures, but are then reflected back to join the portion of the membrane on the dura mater. Beneath this membrane is a serous fluid which passes by the sub-arachnoid spaces of the brain, into the sub-arachnoid space of the spinal canal. On the upper or convex surface of the brain, the arachnoid passes over the sulci, from one convolution to the other; whilst the pia mater, or vascular membrane, alone projects downwards between the convolutions; but it lines the median fissure between the hemispheres, and, according to Bichat, it is prolonged into the lateral ventricles by a process which encircles the veins of Galen, and passes through an aperture, the foramen of Bichat, below the posterior border of the corpus callosum and the fornix. On the lower or under surface of the brain, it covers the anterior lobes, binds down the olfactory nerves which lie on these, and it sinks into the median fissure; but, behind this, it is much looser, and it is separated from the surface of the brain by a considerable interval, the *anteiror sub-arachnoid space*, which is bounded behind by the pons, in front by the anterior lobes, and on each side by the middle lobe. The second, third, and fourth nerves, and the internal carotid artery, receive prolongations from the unattached portion of the membrane that covers in the space; and the infundibulum is also enveloped by a tube which passes along it to the pituitary body, over which it is reflected. If an aperture be made in this unattached portion of the arachnoid, much strong, fibrous, or cellular structure is seen to cross the space between the arachnoid and the pia mater; and if a probe be introduced into the space, it will pass forwards in the middle line, outwards in the interval between the anterior and middle lobes, and backwards along the sides of the pons, to the posterior sub-arachnoid space, as well as below this to the posterior lobe of the cerebrum, along the vessels to this lobe. When the arachnoid is followed backwards, it closely covers the pons, binds down

Arachnoid Membrane.

Anterior Sub-arachnoid Space.

the basilar artery to it, and it then passes to the under surface of the cerebellum, which it covers, closely, except in the fissure between the lobes, where the membrane is loose, and covers in the *posterior sub-arachnoid* space, which is best seen by pulling forwards the medulla oblongata. This space, situated between the medulla oblongata and the hemispheres of the cerebellum, is wider before than behind, and communicates, in front, with the anterior space by the side of the medulla and pons; on the sides and behind, with the under surface of the cerebellum; and, below, with the large sub-arachnoid space in the spinal canal. When this space is opened, the aperture of the fourth ventricle is exposed: it is placed close to the medulla, and between the inferior cerebellar arteries; it is triangular in shape, the base at the medulla, and the apex at the inferior vermiform process, and the sides are bounded by the pia mater continued from the surface of the medulla oblongata to the inferior vermiform process; the vascular choroid plexus of the fourth ventricle is connected to the inner surface of the membrane that bounds the aperture on each side. By this aperture, the cavities of the interior of the brain communicate with the sub-arachnoid spaces both of the brain and of the medulla; and Dr. Sharpey thinks it probable, that the membrane, which he considers to line the interior of the sub-arachnoid space of the medulla, is continued into the cavities of the brain by this opening.*

Posterior Sub-arachnoid Space.

Pia Mater.

The *pia mater*, the vascular envelope of the brain, consists of the minute subdivisions of the vessels of the brain, which are connected together by cellular membrane, and form an extensive ramification and anastomosis before they perforate its substance. This membrane closely surrounds the different parts of the brain, and dips into the sulci between the convolutions; but it also sends processes into the interior, to supply vessels to the walls of the ventricles. The fold of it that penetrates into the cerebrum is named velum interpositum, and it enters below the corpus callosum and fornix, by a great fissure, — the fissure of Bichat; and the vascular margins of this process are called the plexus choroides. The membrane covers the cerebellum in the same manner as the cerebrum, and sinks into the intervals between its laminæ, but it is more closely united to it; it also

* "We might conceive this membrane (the internal arachnoid) to be prolonged from the external arachnoid by the canal of Bichat, into the interior of the ventricles, after lining them, to be continued through the opening of the fourth ventricle into the so-called sub-arachnoid space which it lines, being applied to the surface of the spinal cord, the nerves and the ligamentum denticulatum, on the one hand, and, on the other, to the surface of the external sac of the arachnoid, the two by their mutual adhesion forming the loose arachnoid."— MS. notes of Dr. Sharpey, with a perusal of which I have been favoured.

sends a process behind the medulla oblongata, into the fourth ventricle; this is the choroid plexus of the fourth ventricle.

Dissection. To expose the vessels and nerves with the other parts at the base of the brain, take away the arachnoid from the base; from the anterior median fissure, to allow of the separation of the lobes from each other; and also from the fissure that runs transversely outwards between the anterior and middle lobes. Clean the pons, and follow outwards the arteries both to the cerebrum and cerebellum. In tracing the one to the upper surface of the cerebellum, the artery to the posterior part of the cerebrum is seen, as well as the fourth nerve which accompanies it. See now the position of the different parts of the base of the brain, previously to tracing the distribution of the arteries.

Parts of the Base of the Brain. The *cranial or encephalic portion* of the nervous system consists of cerebrum, or great brain; cerebellum, or small brain; and pons, and medulla oblongata, which are intermediate in position between the other two. The cerebrum is divided, by a great median fissure, into two halves or hemispheres, connected together by certain parts in the middle line; and each, convex above to correspond to the arch of the skull, is divided below into three lobes, an anterior, a middle, and a posterior. The *anterior* rests on the orbital process of the frontal bone and small wing of the sphenoid, or in the anterior fossa of the base of the skull; it is separated from its fellow of the opposite side by the median fissure, and from the middle lobe by the fissure of Sylvius; on its under surface, near the median fissure of the brain, is a sulcus, which lodges the olfactory nerve. The *middle lobe*, the most prominent of the three, projects into the middle fossa of the base of the skull, and it rests on the great wing of the sphenoid bone, and the squamous and petrous portions of the temporal bone; its limits are, in front, the fissure of Sylvius; behind, the anterior line of the cerebellum or the anterior border of the tentorium cerebelli; and, internally, it reaches towards the middle line, and overhangs the crus cerebri. The *posterior lobe*, separated from the middle by no visible line of demarcation, is supported on the tentorium cerebelli which separates it from the cerebellum, and it reaches forwards to the anterior margin of the tentorium, which is attached to the ridge of the petrous portion of the temporal bone. In the middle line of the cerebrum is the great median fissure which is wide in front, but is closed behind this by the contact of the hemispheres; in the bottom of the fissure is the white medullary corpus callosum, and on it the anterior cerebral arteries which are united to each other, as they enter the fissure, by the anterior communicating artery. Behind this, in the middle line, is the large flat commissure of the optic nerves; then a grey or cineritious mass, — the tuber cinereum, with the infundibulum that descends to the pituitary body: posterior to this are two white pea-shaped

bodies, — the corpora albicantia; and behind these an excavated spot, perforated by many small arteries, — the locus perforatus, which is placed in front of the pons, and between the diverging crura cerebri. An arterial circle of communication between the branches of the internal carotid and basilar arteries, or the circle of Willis, circumscribes the hollow in the centre, which corresponds to the anterior sub-arachnoid space; external to the circle are the third and fourth nerves that pass from behind forwards. Raise with care the middle lobe from the crus cerebri; a portion of the fissure that leads into the lower part of the lateral ventricle is seen between the two. At the inner termination of the fissure of Sylvius, is another spot, perforated by many small vessels; this is the substantia perforata antica, or lamina cribrosa, and in the fissure is the middle cerebral artery. The pons, a square-shaped medullary mass, is divided into two halves by a median sulcus which contains the basilar artery: to its front are connected the crura cerebri, to the sides the crura cerebelli, and, behind, the medulla oblongata. Behind the pons is the medulla oblongata, which is also divided into two halves by a median fissure, and each half is subdivided into an anterior portion, — the corpus pyramidale; a lateral, — the corpus olivare; and a posterior, — the corpus restiforme. The cerebellum is divided also by a median fissure, into two hemispheres which are received into the posterior fossæ of the base of the skull, and lie on the occipital and temporal bones. In the centre of the fissure that separates the hemispheres is the inferior vermiform process, and in front of it the aperture into the fourth ventricle. Behind the crus cerebelli, between the medulla and the hemisphere, and beneath the eighth nerve, is the flocculus or sub-peduncular lobe of the cerebellum.

Arteries. The brain is supplied with blood from the vertebral and the two internal carotid arteries, which divide into branches, for the supply of its different lobes.

Vertebral Artery. The *vertebral arteries*, branches of the subclavian, ascend in the series of foramina of the transverse processes of the cervical vertebræ, to reach the arch of the atlas; they there perforate the posterior ligament between the atlas and occipital bone, enter the cavity of the cranium through the foramen magnum, and run obliquely upwards and forwards over the spinal accessory nerve; they next turn round the sides of the medulla oblongata, between the ninth nerve and the anterior branch of the sub-occipital, to unite, at the lower border of the pons, in one artery, — the basilar. Between the point of entrance into the skull, and the termination in the basilar, each artery gives off three named branches, the anterior and posterior spinal, and the inferior cerebellar.

Posterior Spinal branch. The *posterior spinal artery*, a small branch, leaves the vertebral close to the posterior part of the medulla, and it is therefore either cut through, or left in the spinal canal, when

the brain is removed; it descends along the side of the medulla spinalis, and sends off numerous branches which ramify on the lateral and posterior part of the cord, and they anastomose with the one of the opposite side, and with the small branches that enter to the medulla through the different apertures in the spinal canal.

The *anterior spinal artery*, nearly the same size as the preceding, is given off near the termination of the vertebral; it runs towards the middle line of the front of the medulla oblongata, to unite with its fellow of the opposite side, in a single artery, which descends, on the front of the medulla spinalis, beneath the fibrous band on this surface, and it anastomoses with small arteries, sent to the medulla through the intervertebral foramina in the different regions of the neck, thorax, and abdomen; by which the artery is continued downwards to the extremity of the medulla. Anterior Spinal branch.

The *inferior cerebellar artery*, much larger in diameter than the other two, is the last branch of the vertebral, and it is distributed to the cerebellum. It arises from the vertebral, close to the border of the pons, and very often, on one side, from the basilar; it runs downwards and backwards round the upper part of the medulla oblongata, between the spinal accessory and pneumogastric nerves, and on the side of the aperture of the fourth ventricle, to reach the fissure on the under surface of the cerebellum: the artery is now directed backwards in a depression between the inferior vermiform process and the hemisphere, and it divides into a branch which runs outwards over the under surface of the hemisphere, as far as the circumference, to anastomose with the superior cerebellar; and into another, which continues backwards the course of the artery in the depression, and turns to the upper part of the cerebellum, to anastomose with the same artery as the preceding branch. Inferior Cerebellar branch.

When the vertebral arteries enter the skull, and before giving off the branches to the medulla, they supply some small arteries—the *posterior meningeal*—to the dura mater lining the occipital fossæ, and also to the falx cerebelli. Posterior Meningeal.

The *basilar artery*, resulting from the union of the two vertebral arteries, extends from the lower to the upper border of the pons, and it divides at this spot into four arteries, — a posterior cerebral, and a superior cerebellar, for each side. In this course, the artery lies on the basilar process of the occipital bone, from which it receives its name, and it corresponds to the median groove of the pons, in which it is bound down by the arachnoid membrane. Parallel to this artery, but external to it, is the sixth nerve on each side. Besides the four branches mentioned above, the basilar gives numerous *transverse arteries* which vary in size, and are chiefly distributed to the pons; Basilar Artery. Transverse branches.

Anterior Inferior Cerebellar Artery.

though one on each side the *anterior inferior cerebellar artery* larger than the rest, extends to the front of the under surface of the cerebellum, to which it is distributed; and one usually enters the meatus auditorius internus with the seventh nerve.

Superior Cerebellar Artery.

The *superior cerebellar artery*, one of the two branches into which the basilar divides for the supply of each side, passes directly backwards round the crus cerebri, crosses the third nerve, and accompanies the fourth to the upper surface of the cerebellum. As it turns backwards, it is nearly parallel to the posterior cerebral artery, but nearer the pons than it, and on the upper surface of the cerebellum, it divides into many branches; some of these extend to the margin of the hemisphere to anastomose with corresponding branches from the inferior cerebellar; and other central arteries supply the process of pia mater, or velum interpositum, which projects into the interior of the brain; one or more branches run by the side of the vermiform process to meet the ascending branches from the inferior cerebellar, in the median fissure. From this artery sometimes arises the small branch to the meatus internus.

Posterior Cerebral Artery.

The *posterior cerebral artery*, the remaining branch of the basilar, has nearly the same course backwards round the crus cerebri, as the superior cerebellar; and it is separated, at first, from this artery by the third nerve which projects forwards; it is then directed outwards to reach the inner surface of the posterior lobe, or the convolution of the corpus callosum, along which it continues, to opposite the posterior extremity of the corpus callosum; where it passes to the under part of the posterior lobe, and divides into numerous branches, which are followed to the extremity of the lobe, and turn upwards, both in the median fissure, and on the outer surface of the hemisphere, to anastomose with the other cerebral arteries. Close to the commencement of the artery, numerous small branches arise; these perforate the substance of the locus perforatus, and it is joined soon afterwards by the small posterior communicating artery of the internal carotid; it then gives a small *choroid artery*, which turns round the crus cerebri, and ascends to supply the velum interpositum which enters the brain below the corpus callosum.

Choroid.

Thus the vertebral arteries supply with branches the upper part of the medulla spinalis, the cerebellum, and the posterior lobe of the cerebrum.

Internal Carotid Artery.

The *internal carotid artery* enters the skull through the carotid canal of the petrous portion of the temporal bone, it then passes through the cavernous sinus, and appears internal to the anterior clinoid process; it comes into contact with the base of the brain at the inner termination of the fissure of Sylvius, and it divides immediately into an anterior cerebral, a middle cerebral, and a small posterior communicating artery. In the interior of the

skull, as soon as the artery has passed above the anterior clinoid process, it is enveloped by the arachnoid, and it lies between the optic nerve to the inner, and the third nerve to the outer side: this last nerve is at some distance from the artery, and the relation is best seen when the brain is being removed.

Anterior Cerebral Artery.

The *anterior cerebral artery* has a course inwards and forwards in front of the depression in the centre of the base of the brain, to approach the one of the opposite side in the median fissure which separates the anterior lobes of the brain, and at the posterior part of this fissure it is joined to its fellow by a short thick trunk,—the *anterior communicating artery*,—which is about one line in length. The artery then runs horizontally forwards on the corpus callosum, turns round its anterior extremity, and, as will be afterwards seen, divides on its upper surface into two branches; one to supply the inner and fore part of the hemisphere of that side of the brain to which it belongs, and the other to continue on the corpus callosum to its posterior part, before it is distributed to the back and inner part of the hemisphere. This last branch anastomoses with the posterior cerebral in the fissure between the hemispheres. This artery forms, on each side, the anterior boundary of the arterial circle, and it is situated beneath the optic nerve, in this position of the brain; but above it, in the natural state. It gives branches to the under part of the anterior lobe, and to the olfactory and optic nerves.

Anterior Communicating Artery.

Middle Cerebral Artery.

The *middle cerebral artery*, the largest of those from the internal carotid, has the most extensive and numerous ramifications; it runs almost transversely outwards to the fissure of Sylvius, along which it extends as far as to the island of Reil, where it divides into two or more branches which circumscribe these few convolutions; and the branches into which these divide, after turning over the convolutions of this part, and dipping into the sulci, run upwards on the outer part of the hemisphere, supply the anterior and middle lobes, but chiefly the latter, and they anastomose with the anterior and posterior cerebral arteries. At the inner termination of the fissure of Sylvius, this artery sends off numerous small arteries, which perforate the substantia perforata to enter the corpus striatum.

Posterior Communicating Artery.

The *posterior communicating artery*, the smallest branch of the internal carotid, is directed backwards along the inner side of the middle lobe, and parallel to the third nerve which is external to it, to join the posterior cerebral, — a branch of the basilar, — near the pons; this small artery connects, directly, the internal carotid with the basilar artery.

Choroid Artery.

Another small artery derived from the internal carotid, or from the middle cerebral, is the *choroid artery*, whose course is outwards and backwards, with the optic nerve, and external to the posterior communicating, to enter the lateral ventricle by

the fissure in this part: it is supplied to the choroid plexus of the lateral ventricle.

The internal carotid, then, supplies the greater portion of the cerebrum by its anterior and middle cerebral arteries which turn upwards to distribute branches to the outer and inner parts of each hemisphere.

Circle of Willis. By the anastomosis of the internal carotid and basilar arteries at the base of the brain, they give rise to an arterial circle which is named the *circle of Willis*. It is formed, laterally, by the internal carotid dividing into the anterior cerebral and posterior communicating arteries, in front, by the convergence of the anterior cerebral and the anterior communicating branch which joins them, and, behind, by the basilar dividing into the posterior cerebral arteries. In this circle are contained the lamina cinerea which is prolonged from the corpus callosum to the tuber cinereum, the commissure of the optic nerves, the tuber cinereum, the infundibulum, the corpora albicantia, the locus perforatus, and a small part of the crus cerebri, which bounds this spot on each side: these parts above enumerated, as contained in the circle of Willis, form the floor to the third ventricle of the brain. So free an anastomosis is seen to exist between the two arteries supplying the brain, that an obstruction in one does not prevent the blood from passing, very soon, almost as freely to the opposite side, by means of the anastomosis.

Veins. The veins of the brain do not accompany the arteries, but they open into the sinuses of the dura mater.

Sympathetic Nerve. Branches of the sympathetic nerve, from the plexus in the cavernous sinus, accompany the branches of the internal carotid artery; and a small ganglion — the ganglion of Ribes — is said to be situated on the anterior communicating artery.

Remove carefully the arteries, to see the origins of the nerves, and the parts of the base of the brain.

Cranial Nerves. The *cranial nerves* which issue by the apertures in the base of the cranium are named, numerically, first, second, third, &c., from the order in which they leave the skull; but the number of these will vary according to the system of classification adopted in speaking of them. That of Willis, in which they are nine, is most commonly made use of; but these same nine nerves are reckoned as twelve by Sœmmering. These nerves have, also, other apellations, derived from either their function, distribution, or appearance.

Cranial portion of the First Nerve. The *first* or *olfactory nerve* lies in the sulcus on the under surface of the anterior lobe, near the median fissure, and it is bound down to the hemisphere by the arachnoid which is reflected over it, but the pia mater enters beneath the nerve, and lines the sulcus. It is a flat-looking, medullary band, wider at each end than in the middle, and in front it forms an enlargement, — the olfactory bulb; the surface of the nerve now

looked upon is grooved along its centre. When it is raised from the sulcus, after the arachnoid is divided, it is prismatic in form, the apex of the prism being directed downwards; and the nerve is very soft and pulpy, since it is destitute of any sheath or neurilema. The nerve arises from the cerebrum by three roots; an *external*, long, linear, and medullary, which is directed outwards along the posterior part of the last convolution of the anterior lobe, crosses the fissure of Sylvius beneath the middle cerebral artery, and close to the inner projecting part of the island of Reil, and it then sinks deeply into the cerebral substance, to be connected to the radiations of the anterior commissure; an *internal*, also medullary, and often very indistinctly marked, which is short, and passes inwards to the substantia perforata antica, or to the lateral prolongation from the corpus callosum to this part; and a *central* root, which is cineritious, from a papilla at the posterior part of the sulcus, and which is seen when the nerve is raised: this last root is prolonged forwards on the under part of the nerve. The olfactory nerve is now directed forwards in the sulcus, with an inclination towards the one of the opposite side; and, by the side of the crista galli, whilst situated on the cribriform plate of the ethmoid bone, it forms a gangliform enlargement, — the *olfactory bulb* which, consisting of both cineritious and medullary matter, sends down numerous filaments through the cribriform plate of the ethmoid to the membrane of the nose.

External Root.

Internal.

Central.

Olfactory Bulb.

The *second* or *optic nerve*, the largest of the cranial nerves, except the fifth, appears as a flat band surrounding the crus cerebri, and it unites with the one of the opposite side in the commissure. Previously to reaching the commissure, the nerve is soft, is attached for the most part to the crus cerebri, and it is invested on only one surface by the pia mater reflected over it; but beyond this, where the nerve is round and firm, it is invested by a neurilema, which continues with it to its termination. The origin of the nerve, which is not now visible, is from the optic thalamus and nates, by bands which unite together; the nerve resulting from their union appears between the crus cerebri and middle lobe, and it then extends forwards as a flat band around the crus, to which it is connected by its external border: this extent of the nerve is the optic tract. At the front and inner part of the crus, the nerve becomes rounder, and it passes inwards to the commissure, in front of the tuber cinereum, to which it is united, and to which it gives some white filaments. The *chiasma*, or *commissure* of the optic nerves, is a squarish-shaped body, situated on the olivary eminence of the body of the sphenoid bone, and within the circle of Willis; in front of it is the lamina cinerea, which passes beneath it to join the tuber cinereum, placed behind the commissure. The outer fibres of each optic nerve pass straight forwards without crossing those

Origin of the Second or Optic Nerve

Commissure.

of the opposite side; but the inner and posterior fibres decussate each other in the commissure, so that those of the right nerve are continued to the left, and vice versâ. Each nerve now diverges from the other to reach the foramen opticum, by which it leaves the skull, and enters the orbit; it terminates in the eyeball. In its course it lies internal to the trunk of the internal carotid artery, and it crosses over the anterior cerebral artery.

Origin of the Third Nerve, or Motor Oculi.

The *third nerve*, or *motor oculi*, a round and firm nerve, appears at the inner part of the crus cerebri, near to the locus perforatus, and about a line in front of the pons; but, when followed into the crus, it divides into filaments which can be traced into the locus niger, and into the medullary fibres both above and below this spot. The nerve now runs forwards between the superior cerebellar and posterior cerebral arteries, and external to the posterior communicating artery, parallel to which it lies, to reach the outer wall of the cavernous sinus; it perforates the dura mater close to the anterior clinoid process, and it is distributed to most of the muscles of the orbit.

Origin of the Fourth Nerve.

The *fourth*, or *pathetic*, or *trachleator nerve*, the smallest of the cranial nerves, arises from the valve of Vieussens, at the back and upper part of the fourth ventricle; this origin cannot be seen now. It then turns, with the superior cerebellar artery, round the crus cerebri, and, appearing between the cerebrum and cerebellum, it is directed forwards to enter the free margin of the tentorium cerebelli, near to the posterior clinoid process: its final distribution is to the orbit.

Origin of the Fifth, or Trifacial Nerve.

The *fifth*, or *trifacial*, or *trigeminal nerve*, the largest of the cranial nerves, consists of two portions or roots, — a large or sensitive, and a small or motor; and since the sensitive portion forms a ganglion, and the two roots then unite, only, beyond the ganglion, it has been classed by Bell with the spinal nerves which it resembles both in arrangement and function. The nerve appears on the side of the pons, in front of the junction of the crus cerebelli with it, and the two roots of origin are very near each other. The *large* or *sensitive root*, escaping between the transverse fibres of the pons, is constricted opposite the surface, but it soon enlarges; and when it is traced in a pons hardened in spirit, it can be followed downwards and backwards, beneath the transverse fibres of the crus cerebelli, as far as to the posterior surface of the medulla oblongata, to its origin from a small eminence by the side of the calamus scriptorius, in the floor of the fourth ventricle. The *small* or *motor root* appears on the surface, by an aperture distinct from that of the large, and it is separated from it by a slight interval; it is placed also behind, but rather above it; this root, when followed backwards through the transverse fibres of the pons, is found to pass to the same part in the floor of the fourth ven-

Sensitive Root.

Motor Root.

tricle as that from which the large arises.* The two roots pass upwards and forwards, separate from each other, and beneath the tentorium, to enter an aperture in the dura mater, above the point of the petrous portion of the temporal bone; the large root then forms the Gasserian ganglion, and the small one, unconnected to the ganglion, unites with only one branch from the ganglion, to give rise to a nerve both motor and sensitive in function.

Origin of the Sixth or Abducens Nerve.

The *sixth* or *abducens nerve* arises from the upper narrowed part of the corpus pyramidale of the medulla oblongata, when it is about to enter the pons; sometimes the nerve has two attachments to this part. It then passes forwards and upwards on the outer side of the basilar artery, and it perforates the dura mater, behind the body of the sphenoid bone, to enter the cavernous sinus which conducts it to the orbit.

The third, fourth, fifth, and sixth nerves cannot be referred to in their whole course, since they are contained in the dura mater for a certain distance before they reach the apertures by which they pass from the skull, and their farther anatomy in the cranium will be seen with the dissection of the nerves of the base of the skull.

Origin of the Seventh Nerve.

The *seventh nerve*, situated on a level with the sixth, at the lower border of the pons, but more externally than it, consists of two portions very distinct both in appearance and origin; the internal portion small, but firm and round, — the portio dura, and the external large and soft, in contact with the flocculus, is the portio mollis. † The *portio dura* appears on the surface of the restiform body, close to the pons; its fibres arise from the restiform body, and some can be followed in a hardened medulla, through this body, to the ascending fibres of the lateral tract of the medulla, near to the calamus scriptorius in the floor of the fourth ventricle. The nerve then turns forwards over the border of the pons, to which it is closely connected, and, passing outwards, meets with the portio mollis, to which it is applied. The *portio mollis*, which lies external to the *dura*, is attached to the outer and back part of the restiform body, and some of its fibres of origin enter into it, but others turn backwards round this body, and arise from the floor of the fourth ventricle; it is then directed upwards and forwards over the crus cerebelli, with the portio dura which is placed in front of it, and the two enter the meatus auditorius internus with a small artery.

Portio dura.

Portio mollis.

Origin of the Eighth Nerve.

The *eighth nerve*, formed by the most external set of filaments which are attached to the medulla oblongata, consists

* See the Cyclopædia of Anatomy and Physiology, article *Fifth Pair of Nerves*, by Dr. Alcock.

† The portio dura is the seventh nerve of some authors, and the portio mollis the eighth.

of three distinct portions; the glosso-pharyngeal, pneumo-gastric, and spinal accessory*, all of which converge, from the side of the medulla oblongata and medulla spinalis, to the flocculus which is situated close below the junction of the crus cerebelli to the pons, and on which they lie previously to leaving the skull. The *glosso-pharyngeal*, the smallest of the three nerves, and situated highest in the series, is a small band formed by two or three filaments more or less united into one, which arise from the front and inner part of the restiform body close below the portio dura; the nerve formed by the union of these runs outwards over the flocculus and choroid plexus of the fourth ventricle, but separated from the pneumo-gastric below, by a slight interval, to reach the foramen lacerum jugulare, through which it leaves the skull. The *pneumo-gastric*, the next highest nerve, arises also from the restiform body close below the glosso-pharyngeal, by a series of filaments which unite into six or eight bundles, and these, placed below each other in a line, ascend, and converge to unite in the large flat band of the pneumo-gastric nerve, which also passes outwards over the flocculus, and reaches the foramen lacerum, by which it leaves the skull. The *spinal accessory* differs from the two preceding in its extent of origin which is cut through in removing the brain from the skull, as well as in its appearance which resembles a rounded cord, like the third or sixth nerve. It arises from the lateral part of the medulla spinalis, opposite about the fifth cervical vertebra, behind the ligamentum denticulatum of the cord, and near to the posterior roots of the spinal nerves; the nerve ascends along the side of the medulla, behind the ligament, and close to the posterior roots of the nerves, and it receives filaments of origin from the medulla at different distances, the upper being near the filaments of origin of the pneumo-gastric, with which they seem continuous. Opposite the posterior root of the first cervical or sub-occipital nerve, it is joined by filaments from this nerve, and it is frequently connected to the posterior root of the second as it passes by. Above the first cervical nerve it ascends behind the vertebral artery which has crossed its course, enters the skull by the foramen magnum, and, lying close to the bone, turns outwards to the pneumo-gastric, with which it leaves the skull. In some cases, the whole of the posterior root of the first cervical or sub-occipital nerve joins the spinal accessory which then gives filaments to the anterior root of this nerve.

Glosso-pharyngeal.

Pneumo-gastric.

Spinal Accessory.

Origin of the Ninth Nerve.

The *ninth*† or *hypoglossal nerve*, whose roots of attachment are placed on the front of the medulla oblongata, arises in the

* Those who adopt the classification of these into distinct nerves, call the glosso-pharyngeal the *ninth*, the pneumo-gastric the *tenth*, and the spinal accessory the *eleventh cranial nerve*.

† Or twelfth, according to the other arrangement.

sulcus between the corpus pyramidale and olivare, on a line with the anterior roots of the spinal nerves, by a series of ten or twelve filaments placed in a line; these ascend to unite into two bundles which leave the skull by the anterior condyloid foramen, and afterwards unite into one.

Medulla oblongata.

The *medulla oblongata*, or upper dilated portion of the medulla spinalis, is contained, almost altogether, in the cavity of the cranium, and it lies on the basilar process of the occipital bone. It reaches from the lower border of the pons, whose transverse fibres limit it above and in front, to the lower part of the crossing of the fibres of the pyramids in the middle line, or opposite to the lower margin of the first cervical vertebra; but, posteriorly, the transverse fibres of the pons are absent, and there is no marked limit to the extent, upwards, of the medulla. The medulla is pyramidal in shape, the base above, and the apex below; its length is about one inch and a quarter, and its greatest breadth about three quarters of an inch. The anterior surface, convex, corresponds to the basilar process of the occipital bone, and it is divided into two halves by a fissure, — the continuation of the anterior median fissure of the medulla spinalis,—which ends above in an enlargement, the *foramen cæcum;* the decussation of the pyramids is seen in the fissure opposite the lower extremity of the medulla oblongata, and, frequently, some cross medullary fibres are found in it above this. To this surface are connected the nerves that arise from the medulla; the sixth being attached to the anterior pyramid close to the pons; the ninth, lower down, to the sulcus between the pyramid and the olivary body; and the eighth and seventh to the restiform body: the latter nerve is close to the pons. The posterior surface is received into the hollow between the hemispheres of the cerebellum: it forms the floor of the fourth ventricle, and it will be afterwards seen to have also a median fissure. Each half of the medulla oblongata is formed, for the most part, of the fibres which pass through it, from the corresponding part of the cord, to either the cerebrum or the cerebellum, but which have in it a disposition different from that of the cord; thus, in each half are found four bodies: the anterior pyramid, continuous with the anterior division of the cord; external to this, the continuation upwards of the lateral part of the cord, with the oval projection of the corpus olivare situated on it near the pons; and more posteriorly still, the restiform body, the greater number of whose fibres are prolonged up from the posterior part of the cord; and, between the restiform and the median sulcus behind, there is a small projection, which is not now seen, the posterior pyramid: these bodies are separated by slight grooves. The grey matter contained in the cord, in the shape of a semilunar mass, in each half, is also continued into the medulla oblongata, but it becomes diffused in the medullary substance,

and it is found particularly in the posterior part, or floor, of the fourth ventricle.

Anterior Pyramid. To see the constituent parts of the medulla, the pia mater is to be removed from one half, say the left. The *anterior pyramid*, or central projection of the medulla oblongata, is placed on the side of the median fissure, and it is separated from the olivary body by a slight groove. It is about ten lines in length and three in breadth, and it reaches from the pons to the decussation of the pyramids; it is small below, at the decussation across the median fissure, but it enlarges as it ascends, and it is finally contracted and rounded before entering the pons; and to this part the third nerve is connected. The pyramid consists of longitudinal fibres which join, below, the fibres of the front of the cord, but many are derived from the opposite half of the cord across the median fissure, in which the bundles of one side digitate with those of the other. After the accession of the cross fibres from the opposite half of the cord, this body is much more prominent, and, at the lower part of the olivary body, some arched fibres, named *arciform*, pass upwards and outwards from it to join the restiform body, with which they are continued to the cerebellum. Separate the pyramid from the olivary body, by passing the knife between them; the line of separation between the two is recognised by the greater density of the olivary body, and by the existence of some small vessels that enter at this part; carry the handle of the knife up and down as well as beneath the pyramid, to separate it completely, and then cut it across, and turn one half up and the other down. The pyramid is now seen to be prismatic in shape, the apex of the prism being directed downwards and inwards; and the olivary body projects beneath it to the middle line, so as to separate it entirely from the remainder of the medulla. Its fibres are continued above into the pons, and they are followed,

Decussation of the Pyramids. downwards, to the *decussation of the pyramids* which is situated in the median fissure about ten lines below the pons, and is formed by fasciculi or bundles of fibres of one half of the medulla spinalis crossing those of the opposite, to enter the pyramid of the other side. The length of the decussation is about four lines, and its depth nearly the two anterior thirds of the medulla. Not only the superficial fibres of the cord, but also the deeper ones, enter into the decussation; and these are best seen by tracing each fasciculus of the decussation, up and down,

Olivary Body. in a medulla hardened in spirit. The *olivary body*, found only in the human medulla oblongata, is the oval eminence on the outer side of the anterior pyramid; it is separated from the pyramid by a groove, and from the restiform body also by a wider interval. Its length is about half an inch, and its direction is obliquely downwards and inwards; the upper extremity, more prominent than the lower, is separated from the pons by an

interval of a line, and the lower is bounded by the arched fibres from the anterior pyramid to the restiform body. The portion of the olivary body which projects on the surface is covered by medullary matter; but it is only a dilated portion of it, for the body extends, as already seen, beneath the pyramid. Separate this body from the lateral part of the medulla on which it lies, and raise it upwards, but leave it connected by its upper and posterior part. Its structure is much denser and harder than the rest of the medulla; and portions of it are to be sliced off to expose the wavy, yellowish or wood-brown line which circumscribes a centre or nucleus of orange-white medullary matter; this zigzag appearance is the *corpus dentatum* of the olivary body, and it is only a capsule or bag of a yellowish or brownish matter, with its dilated part towards the surface, and its narrower portion, or neck, which is open, directed backwards. A band of fibres is continued from its nucleus to the fibres of the lateral part of the medulla on which it lies; this band is the *fillet* of Reil. This body was considered a ganglion of increase by Gall. Beneath the olivary body, and projecting to the surface, in the interval between it and the restiform body, are the *lateral fibres of the cord* *, which, in passing upwards through the medulla oblongata, are thrown to the side, and backwards also to the floor of the fourth ventricle. This can be well seen only in a hardened medulla †, in which the anterior pyramid and the restiform bodies are separated from it, and raised upwards; they are then found to be narrow below, and to send fibres to the decussation across the median fissure; but, as they ascend to the pons, they form a thicker and wider fasciculus which reaches to the middle line beneath the pyramid and olivary body, is in contact externally with the restiform body to which it sends fibres, and it reaches backwards to the floor of the fourth ventricle. The prolongation of the fillet is connected to these fibres. Bell describes a separate decussation for these fibres of the lateral part of the cord, but its existence is doubtful. The *restiform body,* or inferior peduncle of the cerebellum, continuous with the fibres of the posterior part of the cord, can be seen only in part, since it would interfere with the anatomy of the cerebellum and fourth ventricle to examine it in this stage of the dissection. ‡ It is the largest prominence on the half of

Corpus dentatum.

Fillet of Reil.

Lateral fibres of the Cord.

Restiform Body

* This is called, also, the *lateral* or *sensory tract* of the cord; or the "*faisceau innominé*" Cruveilhier. *Anatomie Descriptive,* tom. iv.

† If the dissector can procure a hardened medulla oblongata, in which the anterior pyramid and restiform body are raised from these fibres of the lateral part of the cord, he will obtain a much better view of this part in it than in the recent medulla.

‡ Another portion of hardened brain, in which the fourth ventricle was laid open, and the restiform body exposed, might be advantageously used to illustrate the anatomy of this.

the medulla oblongata, it is situated behind the olivary body, from which it is separated by an interval before seen, and it bounds, laterally, by its posterior border, the fourth ventricle; to its anterior surface are connected the portio dura and portio mollis nerves, and, below that, the pneumo-gastric and glosso-pharyngeal nerves; and the posterior surface is in contact with the flocculus which comes from beneath it, as well as with the choroid plexus of the fourth ventricle. The greatest number of its fibres are longitudinal, and, continued from the posterior part of the spinal cord, ascend with a direction backwards to the cerebellum without passing through the pons. In consequence of the divergence of the restiform bodies from the middle line behind, each appears on the side of the medulla oblongata, and they leave a space — the fourth ventricle — between them. The restiform body is joined in front by the superficial arciform fibres from the pyramid, and by deep from the prolongation upwards of the fibres of the lateral part of the cord; behind, it is joined also by the continuation upwards of the small posterior median division of the cord, or the *posterior pyramid*, which can be seen only in the fourth ventricle, and must be omitted now, as well as the further consideration of the restiform body. In the middle line of the medulla, between the deep longitudinal fibres of the lateral part of the cord of each side, is a *septum*, composed of fibres which pass from before backwards, and it divides the medulla into two halves; this extends as low as the decussation, and it is continued, above, into the pons; it may be seen in a hardened medulla by an incision on one side of the middle line.

Posterior Pyramid.

Septum.

Pons Varolii.

The *pons Varolii*, or annular protuberance, is the square-shaped medullary portion, situated near the centre of the cranial mass, between the cerebrum, cerebellum, and medulla oblongata, which are connected to it; and to see it, remove the pia mater which covers it. It occupies the space in front of the tentorium cerebelli, and its transverse measurement, about one inch and a half, slightly surpasses the antero-posterior. The anterior surface, oblique in the natural position of parts, rests against the cuneiform process of the sphenoid bone, and it is grooved along the middle line, usually for the reception of the basilar artery; the sixth nerve extends forward on each side of the artery. On the posterior surface is the floor of the fourth ventricle. The upper border surrounds the crura cerebri which are connected to this part of the pons, and to the lower border is united the medulla oblongata; the sixth nerve is found along this border, on each side, near the middle line, and the seventh near the outer termination. To the sides of the medulla are the crura cerebelli, and immediately above their junction with the pons is the fifth nerve. From the divergence of the crura cerebri and crura cerebelli from the pons, this body

has been likened to an animal, of which the crura cerebri were the arms, the crura cerebelli the legs, and the medulla the tail. The superficial fibres of the pons are transverse, and continuous with those of the crura cerebelli, or anterior peduncles of the cerebellum, and they pass inwards to the middle line. It will be found, in dissecting the pons, that it consists of alternate layers of transverse fibres, in the interstices of which grey matter is deposited, and that, through these, the fibres from the medulla pass upwards to the cerebrum. The pons is sometimes called the great *commissure* of the transverse or converging fibres of the cerebellum, and it is supposed to perform for the cerebellum the same office that the corpus callosum does for the cerebrum. Divide the transverse fibres over the line of the longitudinal which enter the pons from the pyramid, and on the same side as that on which the medulla was examined; the fibres of the pyramid will be seen to pass upwards through the transverse fibres and the grey substance; when about to leave the pons they form a wider band than at their entrance, and they are continued, in this position of the brain*, to the inner and superficial part of the crus cerebri. Raise, with the handle of the scalpel, the superficial layer of transverse fibres, and turn it towards the cerebellum. Beneath the longitudinal fibres of the pyramid are seen other transverse fibres forming a second but deeper layer, which is to be divided rather external to the longitudinal fibres, and to be thrown outwards with the handle of the scalpel; and beneath them other longitudinal fibres are arrived at: this second bundle of longitudinal fibres, more numerous than the preceding, is placed beneath the deep transverse fibres of the pons, by which it is pressed backwards to the floor of the fourth ventricle, and it is continuous below with the fibres of the lateral part or tract of the medulla; the fibres then pass through the pons, and, leaving it above, are continued into the crus cerebri, of which they form the deep and outer part; they are separated from the others by the locus niger. Connected to this set of fibres is the band, or *fillet*, from the olivary body, which divides in the pons into two portions; one is continued forwards with these, and the other turns outwards and upwards beneath the fifth nerve, and emerges on the upper part of the crus cerebri, close to the corpora quadrigemina, and its point of appearance must be seen afterwards; the distribution of the *fillet* is seen only on a hardened medulla and pons. No other transverse fibres of the pons are beneath these longitudinal ones; but the superior peduncles of the cerebellum are still deeper than they. The roots of the fifth nerve pass downwards

Fillet of Reil.

* The terms above and below are here used as the parts lie during the dissection; but when the brain is in its natural position, they will be reversed.

through the deep transverse fibres of the pons, to join the bundle of the deep ascending longitudinal fibres in the floor of the fourth ventricle.

Septum. A *septum* similar to that in the medulla oblongata, is found in the middle line of the pons; one border rests on the commissural fibres of the pons, and it is continuous below with that in the medulla oblongata.

Crura Cerebri. The *crura cerebri* are two cylindrical, medullary processes, extended from the upper border of the pons, from which they issue, to the under part of the hemispheres, and chiefly to the optic thalami. Each crus is narrow at the pons, but it becomes wider as it extends forwards to the hemisphere, and it is about three quarters of an inch long. The superficial surface is free, and crossed near the front by the tractus opticus, and farther forwards, and rather external to the optic tract, is a white medullary band,—the *medulla incognita;* the deep surface corresponds o the optic thalamus and corpora quadrigemina: to the outer side of the crus cerebri, and between it and the convolution of the middle lobe, is the fissure into the inferior horn of the lateral ventricle. Between the two crura is a space in which are seen the locus perforatus, the corpora albicantia, and tuber cinereum, which form part of the floor of the fourth ventricle; and to its inner side is attached the third nerve. The crus consists of the longitudinal fibres which have been seen in the pons, and which leave this body to enter it; the superficial longitudinal fibres are continuous with those of the pyramid, as may be proved by raising forward this bundle of fibres with the handle of a scalpel, as far as to the tractus opticus. When this is done, a grey body—the *locus niger*—is exposed, as well as the origin from it of the third nerve. Divide the locus niger by a vertical incision; it will be seen to lie nearer the inner than the outer part of the crus, to be convex towards the surface, and concave in the opposite direction; and beneath it again are the deep longitudinal fibres of the pons, or of the lateral tract, which pass beneath the locus niger, whilst those from the pyramids lie superficial to this substance.

Medulla incognita.

Locus niger.

Posterior extremity of the convolution of the Corpus callosum. To the outer side of the crus cerebri is a club-shaped convolution, from which the pia mater is to be removed, and on the same side as on the pons and medulla. It is the posterior extremity of a convolution which surrounds the corpus callosum, and is continued forwards to the fissure of Sylvius; it is narrow behind, where it turns round the corpus callosum, but it widens as it extends forwards along the outer surface of the crus cerebri, and it ends in a somewhat triangular-shaped extremity. Along the inner side is a small portion of the convolution prolonged backwards for about an inch, and if the convolution be raised with the handle of a scalpel, a medullary band — the tænia hippocampi — is seen to be connected to this prolonged

portion. Between the tænia, or extremity of the lateral prolongation of the fornix, and the crus cerebri, is the aperture into the inferior cornu of the lateral ventricle; by which the pia mater enters this part of the ventricle, and the aperture is only the lower termination of the great fissure of Bichat. Cut across this convolution, and turn it back; the cavity of the inferior cornu of the lateral ventricle is opened, and the projection of this convolution into it, or the hippocampus major, is exposed; this elevation is covered by the medullary matter which lines the inferior cornu. By this step, the attachment also of the optic nerve to the corpora geniculata can be observed, as well as the bands which pass to the optic thalamus of this side from two of the corpora quadrigemina.

Fissure of Sylvius.

The *fissure of Sylvius* will be exposed by taking away the arachnoid, which is reflected across it from the anterior to the middle lobe, and also by removing the pia mater that lines it. It is directed upwards and backwards between the anterior and middle lobes; it contains the middle cerebral artery, and it corresponds to the small wing of the sphenoid bone and its fold of membrane. The fissure divides above into two portions, one of which passes before, and one behind some small convolutions which constitute the island of Reil. At the inner extremity of the fissure is a medullary spot,—the *substantia perforata antica*, or *lamina cribrosa*,—perforated by numerous vessels which enter the corpus striatum; and the *island of Reil*, situated in the fissure, consists of five or six small convolutions united below in a projecting part which connects the anterior and middle lobes, but they are separate above: the branches of the middle cerebral artery surround the island.

Substantia perforata.

Island of Reil.

Locus perforatus.

Return again to the middle line: the space included by the divergence of the crura cerebri is the *locus perforatus*, a spot in which many apertures for vessels exist, and which forms part of the floor of the third ventricle.

Corpora albicantia.

The *corpora albicantia* are two small, pea-shaped bodies placed in front of the locus perforatus, and behind the tuber cinereum. They are medullary on the outer surface, and the covering of medullary matter is derived from the crus of the fornix, which makes a remarkable turn around this body; but the interior of each is cineritious, and they are moreover connected together by a slight commissure of grey matter.

Tuber cinereum.

Infundibulum.

The *tuber cinereum*, or grey matter behind the commissure of the optic nerves, assists to form part of the floor of the third ventricle; and it is continued above into the ventricle, the lower part of which it lines; in front of it is the commissure of the optic nerves, each nerve sending a white filament into it, and from its centre projects the infundibulum to the pituitary body. The *infundibulum* descends, with an inclination forwards, behind the commissure of the optic nerves, to the pituitary body;

it is wide above, but contracted below; and, if cut across, it is found to contain a canal which descends to near the pituitary body, but is then closed by the lining membrane of the third ventricle which descends in it. It is a reddish-looking body, and consists of an envelope or tube of pia mater, in which is contained cineritious matter continuous with that of the tuber cinereum, and third ventricle.

Pituitary Body.

The *pituitary body*, most commonly injured in removing it from its bony case, would be better seen by leaving it sometimes in the base of the skull, and by afterwards removing the vertical plate of bone behind the sella turcica. It is a reddish-looking body, situated in the hollow of the sella turcica, and between the two cavernous sinuses; one portion of the circular sinus is before and the other behind it; the arachnoid membrane is stretched across the upper surface of this body, but the dura mater passes between it and the bone. The lower surface is convex, but the upper flat, or slightly concave, is joined by the infundibulum. This body is divided into two portions; the anterior is the largest, and it is hollowed out to receive the posterior.

Dissection.

In the median fissure between the anterior lobes, is the anterior termination of the corpus callosum; and, to expose it, the convolutions of the under part of the anterior lobe are to be removed, on the same side as that on which the other parts have been dissected. Remove the convolutions on the under surface of the anterior lobe, except the one which is in contact with the corpus callosum, and bends round its front to pass backwards to the fissure of Sylvius: the posterior part of this convolution has been seen to come forwards to the same spot; so that it surrounds the corpus callosum and the inner part of the hemisphere. Cut across this convolution, and throw it forwards: some medullary longitudinal fibres, which extend backwards to the fissure of Sylvius, are raised with it from the transverse fibres of the corpus callosum; these constitute the covered band of Reil.

Anterior extremity of the Corpus callosum.

The *corpus callosum* bending upon itself, in front, extends horizontally backwards in the median fissure to within about a quarter of an inch of the anterior commissure, and it ends in a well-marked, concave margin, from the centre of which a thin excavated, grey portion — the *lamina cinerea* — is prolonged to the tuber cinereum, beneath the commissure of the optic nerves, and over the round anterior commissure of the cerebrum, which may be seen through it. This lamina closes the front of the third ventricle, and it is so thin that it is often broken through in removing the pia mater from it. On each side is a white medullary band,—the *fillet* of the lamina cribrosa, which is prolonged from the corpus callosum to the substantia perforata, and it is continued backwards to join the medullary substance

Lamina cinerea.

Fillet.

on the crus cerebri, external to the optic nerve, or the medulla incognita of Reil. The part of the corpus callosum that bends is called the *knee*, and the prolonged portion the *beak*. In the centre of this body is a raphé, with which the fillets are often continuous; and to the other surface of this reflected part is connected the septum lucidum, or partition between the lateral ventricles; so that an incision on one side of the raphé would open the lateral ventricle. The corpus callosum extends, laterally, into the anterior lobe, beneath its convolutions; it forms part of the floor of the lateral ventricle, and the under part of a medullary capsule for the corpus striatum.

Knee. Beak.

Follow outwards on this left side, on which the convolutions of the anterior lobe have been removed, the lateral part of the corpus callosum, and rather in front of the island of Reil is the prominence of the corpus striatum, — a body to be seen in the lateral ventricle,— which is covered by this medullary layer. Remove a thin portion of the corpus striatum by a horizontal incision, and the anterior commissure will come into view near its inner part, either with the first or second cut of the knife.

Dissection.

This *section of the corpus striatum* exposes a grey substance, of a conical form, with the large extremity to the front of the brain; and it is divided into two portions, an inner and an outer, by a vertical septum of medullary fibres which pass to the hemisphere, and are continuous with those of the crus cerebri; these two portions of the grey substance of the corpus striatum unite in front of their septum, and in them some of the small medullary fibres terminate. The *inner* division of the grey matter is least exposed by this incision, and coming through it, as well as through the inner and lower part of the septum of medullary fibres, is the *anterior commissure* of the cerebrum, a round, white, medullary fasciculus, which then bends backwards and outwards across the outer division of the grey matter, nearly parallel to the optic nerve, but separated from it by the substance named medulla incognita, to reach, near the island of Reil, the inferior lobe of the cerebrum, in which it expands, most of its fibres radiating to the roof of the descending portion of the lateral ventricle: the long root of the olfactory nerve is traced to this radiation of the anterior commissure. The *outer* portion of the grey substance of the corpus striatum is incased by medullary matter externally and below, and internally by the medullary fibres which ascend through the corpus striatum to the hemispheres: these medullary boundaries to this grey portion of the corpus striatum constitute the *medullary capsule* of Reil.* To the outer side of

Section of the Corpus striatum.

Anterior commissure.

Medullary Capsule of Reil.

* To pursue further this subject, consult the essays of Reil, in his *Archives of Physiology*, in the volumes from the year 1807 to 1812; or the translation by Mayo.

the corpus striatum and its capsule, are the convolutions of the island of Reil.

The examination of the base of the brain is now completed; but, before turning it to dissect the upper part, place some tow or a portion of cloth into the hollow on the under part of the anterior lobe; then turn over the brain on to its base, and let the anterior lobes be raised by something of the same thickness, nearly, as the cerebellum, that the hemispheres may be level. Remove the pia mater from the outer and inner surfaces of the hemispheres.

Cerebrum.

The upper surface of the cerebrum is oval, the larger end is directed backwards, and the surface is convex, to correspond to the concavity of the skull. A median fissure, the continuation of that already seen in the base, divides the cerebrum into two parts or hemispheres; the fissure is limited below by the corpus callosum, and in it are the anterior cerebral arteries which ramify on the inner sides of the hemisphere. The outer surface of each hemisphere is convex, as before said, and the inner flat, touches the opposite in front, but is separated from it behind by the falx cerebri; the anterior part of each is smaller than the posterior. The division of each hemisphere, below, into lobes, has been examined. The surface of each hemisphere is irregular and contorted, like the small intestine; the twisted portions are called *convolutions*, and the depressions between these the *sulci*. The only convolution which it is necessary to examine is that of the corpus callosum, which lies close against this body; and the sulcus is one which extends horizontally backwards along the inner part of the hemisphere, on a level with the corpus callosum, and from the posterior part of the convolution of the corpus callosum; this depression corresponds to an elevation — the hippocampus minor — in the posterior cornu of the lateral ventricle; from this horizontal sulcus a vertical one passes upwards to the convex part of the hemisphere.

Convolution of the Corpus callosum.

Cut off the upper part of each hemisphere to a level with the convolution of the corpus callosum: this *convolution of the corpus callosum* is a long and single convolution, except behind, where it is marked by some vertical, superficial indentations, and it bends round both the front and back of the corpus callosum, to reach the fissure of Sylvius, which alone interrupts the continuity around the hemisphere; it is narrower before than behind, and its anterior and posterior terminations have been seen at the base of the brain. Between this convolution and the corpus callosum is an interval, sometimes called the *ventricle* of the corpus callosum: divide this convolution by a vertical incision about its centre, and tear it off the corpus callosum beneath, towards both the front and back of the brain: in doing this, a band of longitudinal fibres, which lies superficial to

the transverse of the corpus callosum, is raised with it; this is the *covered band* of Reil. Covered Band of Reil.

From the incision now made into the cerebrum, it is seen to consist of a central medullary portion continuous with the corpus callosum, and of an enveloping layer of grey matter about a line in thickness, which sends prolongations inwards to different distances, according to the depth of the sulci which it lines. The medullary substance, which is fibrous, is covered by small drops of blood from the extremities of the divided vessels, particularly in a fresh brain, and each convolution consists of a medullary nucleus, or centre, enveloped by the grey or cineritious matter. When only one hemisphere of the cerebrum is cut off on a level with the corpus callosum, the appearance of the medullary matter is said to form the *centrum ovale minus;* but when both are removed to the level of the corpus callosum, the *centrum ovale* of Vieussens is exposed. Centrum ovale.

The *corpus callosum*, or great commissure of the cerebrum, is placed as a roof to the lateral ventricles which it closes, and it not only extends in the median line between the two hemispheres, but it reaches also into them. The length is about four inches, and the anterior part, narrower than the posterior, is also nearer the front than the posterior part of the brain. The upper surface, rather convex from before backwards, presents in the middle line a slight depression, on each side of which is a raised line, — the *longitudinal nerve* of *Lancisi:* these, together, constitute the *raphé* of this body. The arteries of the corpus callosum, and the posterior part of the falx cerebri, are in contact with the central part of this surface of the corpus callosum, and on each side, its convolution and the covered band are situated on it. The anterior part turns upon itself to reach the base of the brain, where it has been seen, and the posterior, thicker, bends down to join the fornix which is situated beneath it and parallel to it. Its fibres are transverse in the middle line, but at each extremity they are oblique, those in front arching outwards into the anterior lobe, and those behind into the posterior lobe, as well as into the posterior cornu of the lateral ventricle, which they line. Beyond the extent of the covered band, the transverse fibres cease, in a raised line which marks the point at which the fibres assume the form of laminæ, and peel off in a hardened brain. Corpus callosum. Raphé.

Divide the corpus callosum from one end to the other in a line rather external to its free central part, and on the side on which the base has been dissected; and from its front and posterior part carry the incisions outwards into the anterior and posterior lobes, to open the lateral ventricle beneath. In cutting through the fibres of the corpus callosum, a thin diaphenous membrane — the lining membrane of the lateral ventricles — is seen to line its under surface, and from its centre a thin projection Dissection.

extends down between the cavity in this hemisphere and that in the opposite.

The thickness of the corpus callosum is greatest at the posterior part, and its fibres are continued into the floor of the posterior part of the lateral ventricle, to form the medullary layer which invests this cornu, and covers the two projections of the hippocampus minor and major: the anterior part is also thicker than the centre. The under surface forms the upper part or roof of the lateral ventricle, and from its centre descends the septum lucidum to the fornix, with which the corpus callosum joins behind, when it makes its posterior fold.

Lateral Ventricle.

The *lateral ventricles* are two in number, one for each hemisphere, and they are separated by a partition which descends from the under part of the corpus callosum to the fornix. An aperture of communication exists in the lower part of the septum. Each lateral ventricle, larger before than behind, is a narrow interval which occupies the centre of the hemisphere, and it extends forwards into the anterior lobe, backwards into the posterior, and downwards into the inferior lobe; so that it is said to consist of a body and three cornua, or of a horizontal and a descending portion. The body or centre of the horizontal portion of the ventricle is almost straight, but it has, however, a slight inclination outwards; and opposite the posterior fold of the corpus callosum, the horizontal portion of the lateral ventricle divides into two parts: a posterior portion or posterior cornu, and a descending part or inferior cornu, which diverge from each other, the former with a direction at first outwards, then inwards to the middle line, so as to form a slight convexity externally, and the latter obliquely downwards and inwards, below the level of the horizontal portion, to end beneath it, close to the fissure of Sylvius; the anterior extremity, or cornu, is directed outwards, and it diverges from the one of the opposite side. The surface of the ventricle is white, or lined by medullary matter, except a part in the floor, near the front, which is occupied by the large grey or cineritious body, the corpus striatum; and on the walls, particularly in front, are numerous veins. A serous membrane, prolonged from the third ventricle by the aperture of communication between the two lateral ventricles and it, or by the foramen of Monro, lines the interior of the cavity, and it secretes an aqueous vapour. This membrane is said to be a prolongation of the arachnoid into the interior of the brain by the canal of Bichat; and by its reflections in the lateral ventricle, it closes the aperture in the inferior cornu, as well as the horizontal fissure between the margin of the fornix and the optic thalamus, in the floor of the ventricle.

Boundaries.

The roof of the horizontal portion of the lateral ventricle is formed by the corpus callosum which extends, laterally, into the hemisphere. The floor, much more irregular, presents, in

front, the portion of the corpus callosum which passes beneath the corpus striatum from the reflected part of the corpus callosum, then the large, grey, pear-shaped body, the corpus striatum; behind this, the optic thalamus, on which are placed the vascular fold of the pia mater, or plexus choroides, and the thin, white border of the fornix; and between the optic thalamus and the corpus striatum is a white line,—the tænia semicircularis; close behind the optic thalamus the descending portion begins, and the commencement of a large projection — the hippocampus major—forms a part of the floor; and in the posterior extremity or cornu, called digital cavity, from its resemblance to the impression of a finger, is a small eminence, — the hippocampus minor. The boundaries and relations of the descending portion must be omitted till it can be dissected. The inner wall, or septum, between the ventricles, is thin, almost pellucid, and much deeper in front than behind, because of the greater depth of the lateral ventricles at this part: in it, opposite the front of the optic thalami, is the foramen of Monro, or aperture of communication between the cavities. The septum lucidum and the part of the fornix which arches over the foramen of Monro, enter into the formation of the *septum ventriculorum*: numerous veins ramify on the septum. The outer boundary is the angle of union of the roof and floor, which are inclined towards each other, so as to meet externally.

Septum lucidum.

The *septum lucidum*, or inner boundary of the lateral ventricle, will be better seen by opening the lateral ventricle of the opposite side, in the same way as the other, and by gently raising the central part of the corpus callosum which remains. It is a thin, transparent partition between the lateral ventricles, somewhat triangular in form, the larger extremity being before, and its narrow pointed portion behind; the surfaces look to the lateral ventricles, of which they form part, and they are covered by the same lining membrane and veins. The upper border, convex, is attached to the centre of the under part of the corpus callosum as far as to its posterior border; the under, concave, is united along the centre of the upper surface of the fornix as far as to the anterior part of the optic thalamus, but in front of this it is connected to the anterior commissure, to the centre of the prolonged part of the corpus callosum, which lies between the fillets of this body, as well as to the under or reflected portion of the corpus callosum in front of this. The septum consists of a medullary layer on each side, on the outer surface of which, near its lower and anterior part, is placed some cineritious matter prolonged to it from the third ventrical beneath, and it is covered by the lining membrane of the lateral ventricle. Cut across the central portion of the corpus callosum rather in front of its middle, and turn the ends forwards and backwards: which will separate the layers of the septum lucidum, and expose the

cavity of the fifth ventricle within; or this may be made more apparent by blowing air, by means of a blow-pipe, between the two layers. The *fifth ventricle*, inclosed between the layers of the septum lucidum, is larger in front—at which part it is about a line in breadth—than behind, where it ends in a point above the end of the fornix; a thin smooth membrane lines the cavity which is said to communicate in the fœtus with the third, by an aperture between the crura of the fornix; but it is not open in the adult.

Fifth Ventricle.

Dissection.

Throw well back the posterior part of the corpus callosum by dividing the septum lucidum, but with care, so as not to injure the fornix beneath; the anterior part is also to be raised, and the fornix, which is placed below, may be examined before the parts in the lateral ventricle, since this proceeding will then allow a more continued dissection of that part.

Fornix.

The *fornix* or vault is a horizontal, triangular-shaped layer of medullary substance, situated at a certain distance beneath the corpus callosum,—the septum lucidum reaching between the two,—and above the third ventricle which it assists to close. Its extent forwards is to the front of the optic thalamus, at which part it is narrow, and it bends downwards over the foramen of Monro, whose upper boundary it forms, to end in two crura, or processes, which descend by the side of the thalamus to the corpora albicantia at the base of the brain. The posterior part, wider than the rest, joins in the middle line the corpus callosum, and it sends off, laterally, to the descending portion of the lateral ventricle, a riband-like band, which is called *tænia hippocampi*, or *corpus fimbriatum*. The border on each side is free, projects into the lateral ventricle, and along it is placed the flocculent plexus choroides; the fissure between the contiguous borders of it and the optic thalamus is closed by the lining membrane of the cavity. The upper surface receives along its centre the septum lucidum, to which it gives fibres, and each lateral portion that rests on the optic thalamus forms part of the floor of the lateral ventricle. Cut across the fornix, near its front, and throw it forwards; the descending pillars are seen behind the transverse medullary band of the anterior commissure, which appears between the diverging crura; the *foramen of Monro*, or *foramen commune anterius*, is also opened: this aperture is bounded above by the fornix, and on each side by the rounded extremity of the optic thalamus; it is single below, and divided above into two portions,—one for each lateral ventricle,—beneath the free margins of the fornix: through this aperture the third and lateral ventricles communicate, the plexus choroides lies in it, some veins from the corpus striatum pass through it to the veins of Galen, and the lining membrane of the lateral ventricle joins that of the third by means of it. Throw back the remaining portion of the fornix from the velum inter-

Tænia Hippocampi.

Foramen of Monro.

positum beneath, and numerous small vessels are seen entering it on its under surface; also, near where it joins the corpus callosum, is an appearance, called the *lyra*, or *corpus psalloides*, which is formed by some transverse fibres between the two longitudinal bands of the tæniæ hippocampi, which converge to each other in the body of the fornix. The fornix consists of two medullary portions — the crura — which commence in the optic thalami, and then ascend and unite together above the foramen of Monro to form the body of the fornix, which gives off behind other two medullary bands or crura, — the tæniæ hippocampi; and at the point of divergence of the posterior crura is the lyra. Lyra, or Corpus psalloides.

Return to the examination of the lateral ventricles, and leave for the present the velum interpositum and plexus choroides.

The *corpus striatum* is the large, cineritious, pear-shaped body situated in the floor of the lateral ventricle, and it corresponds externally, as seen at the base, to the island of Reil, in the fissure of Sylvius. This body is placed obliquely, so that the anterior extremity, which is largest, is near the septum in the middle line; but the posterior extremity, thin and pointed, extends to the roof of the descending portion of the lateral ventricle, and it is directed outwards and backwards external to the optic thalamus; the inner and upper surface is free in the lateral ventricle, of which it assists to form the floor, and it is covered by numerous veins,— the veins of the corpus striatum; the outer and lower surfaces correspond to the hemisphere and island of Reil. The optic thalamus is internal to it, and between the two bodies is a white band, — the tænia semicircularis. The corpus striatum is grey externally, and it has been called the superior ganglion of the cerebrum, by Gall; since he conceived that it increased the number of the medullary fibres of the crus cerebri, which pass through it to the hemisphere. Make a small incision into the centre of the corpus striatum of that hemisphere which is untouched at the base, until the medullary fibres are reached, and the reason why this body has received its name is evident. The fibres that pass through this body are continuous with those of the crus cerebri; and to see them on the opposite side, remove with the handle of the knife the whole of the cineritious part of the corpus striatum above the fibres; follow also backwards to the posterior and inferior lobes, the fibres which radiate from the outer side of the optic thalamus. In raising the grey substance of the corpus striatum from the anterior of the medullary fibres, processes of it are seen to cross or digitate with the white bundles; this is called the *pecten* by Reil, and this arrangement obtains to near the posterior part of the optic thalamus; some vessels also pass with the grey substance, between the bundles of white fibres. The anterior commissure is also exposed as it crosses this mass Corpus striatum. Pecten of Reil.

of grey substance, before it perforates the radiating medullary fibres.

Diverging fibres of the Crus Cerebri, or Fibrous Cone of Reil.

The *radiating* or *pyramidal fibres*, exposed by the previous dissection, form the *fibruos cone of Reil;* they are continuous with the fibres of the crus cerebri, but they are increased in number, and are prolonged through the optic thalamus and corpus striatum, to radiate from their outer borders into the anterior, posterior, and middle lobes of the cerebrum. The anterior fasciculi of the fibres, long and slender, are connected to the anterior commissure which perforates them, to reach the lower portion of the grey matter of the corpus striatum, across which it passes to the roof of the inferior cornu of the lateral ventricle, as seen in the dissection of the base.* The next in order from before backwards, shorter and thicker, are the principal fibres that digitate with the processes of the grey matter; the fasciculi to the posterior lobe are the longest, and they pass horizontally backwards beneath the tail of the corpus striatum, instead of through the centre of the grey substance; and the fibres to the inferior lobe do the same, and are directed downwards. These medullary fibres pass through the corpus striatum, and divide it into an upper and a lower mass of grey substance: the upper has been removed, but the lower will be exposed by either a horizontal or a vertical section of the fibres, and it has been before seen, in part, at the base of the brain; it does not extend so far back as the upper, so that the fibres to the posterior and inferior lobes have grey matter on only the upper surface; and it joins with the grey substance of the upper mass by prolongations between the medullary fasciculi, as well as in front of the fasciculi of the diverging fibres; it is also contained in a capsule, of which these diverging fibres form the upper and inner sides.†

Tænia semicircularis.

The *tænia semicircularis,* to be seen on the side opposite to that in which the corpus striatum has been examined, is a thin, white band, situated between the corpus striatum and the optic thalamus; in front it passes downwards and inwards,

* If the corpus striatum has not been cut into at the base of the brain, a good view of the course and relations of the anterior commissure may be obtained by the following dissection: open the lateral ventricle in the usual way; scrape away with the handle of the knife the upper and inner mass of the cineritious substance of the corpus striatum, which will expose the commissure passing through it to perforate the medullary fasciculi; cut through the medullary fasciculi, and remove the lower mass of cineritious substance from the capsule that contains it, but leave untouched the commissure which passes through it. The commissure then perforates the outer wall of the medullary capsule that contains this lower cineritious mass of the corpus striatum, and it enters into the roof of the inferior cornu, where it radiates: it may be seen in the cornu of the ventricle, by opening it from the outside, as in the usual dissection.

† For a more detailed description of these fibres, consult the accurate essays of Reil, before referred to.

becomes broader, and joins the anterior pillar of the fornix; and behind it continues backwards, internal to the pointed extremity of the corpus callosum, and it ends in the roof of the descending portion of the ventricle, near the corpus geniculatum externum, by joining the medullary matter which invests the cornu. Beneath this body passes the vein of the corpus striatum to join the veins of Galen. Superficial to the anterior part of the tænia, is a thin, yellowish-looking band,—the *lamina cornea*, which appears to be a thickening of the lining membrane of the ventricle, and under it pass some veins to join that of the corpus striatum. Lamina cornea.

The optic thalamus is only partially seen now, and it should be left till after the dissection of the third ventricle.

The *hippocampus minor* or "*ergot*" is a projection in the floor of the posterior extremity or cornu of the lateral ventricle; it is broad before and pointed behind, and liable to great varieties both in size and form; it is covered by a medullary layer which lines the whole cornu, and is derived from the posterior extremity of the corpus callosum. When cut across transversely, the projection is found to be formed by a sulcus, before seen at the posterior part of the inner surface of the hemisphere, and it is covered internally by the white matter of the cornu. Hippocampus minor.

The *descending portion* or *inferior cornu* of the lateral ventricle will be exposed by cutting vertically, at the back of the optic thalamus, through the substance of the hemisphere not dissected below, nearly to its base, and following forwards with the knife the great projection of the hippocampus major. This portion of the ventricle is a narrow interval which passes round the crus cerebri, and below the optic thalamus, to near the fissure of Sylvius; and its direction, curved something like a half-bent finger, is at first outwards; it then turns downwards and inwards, and it is finally prolonged almost horizontally forwards. Its upper boundary is the under surface of the optic thalamus, and the surface of the hemisphere external to it, on which are seen, if the roof be raised, the termination of the thin, pointed extremity of the corpus striatum, and internal to it the white band of the tænia semicircularis; these end near the corpus geniculatum externum. The floor is formed by the curved projection of the hippocampus major, with the thin prolongation of the fornix or the tænia hippocampi, along its concave margin; the plexus choroides rests on this; and external to the hippocampus is another projection, also medullary on the surface,—the *pes accessorius* or *eminentia collateralis*. Between the hippocampus and its tænia, and the crus cerebri, which they half encircle, is a fissure,—part of the great fissure of Bichat,—by which the pia mater enters the lateral ventricle, but it is closed by the reflection of the arachnoid membrane across it. Descending part of the lateral Ventricle. Pes accessorius.

The *hippocampus major* or *cornu Ammonis* is the large pro- Hippo-

campus major. jection into the floor of the descending part of the lateral ventricle; convex on the surface that looks into the ventricle, it is also convex externally, but concave internally, and it is curved in the same direction as the cornu of the ventricle: the anterior extremity, larger than the posterior, presents, externally, two or three projections, — the *pes hippocampi*. This body is covered, on its ventricular surface, by the medullary matter which invests the cornu, and is continuous with the posterior part of the corpus callosum. The *tænia hippocampi* or posterior crus of the fornix extends along its concave margin, but it gradually becomes smaller, and it ends anteriorly in its medullary investment. Cut across the portions of the corpus callosum and fornix, which remain in the middle line above the velum interpositum, and turn them aside to see the convolution of the corpus callosum, which descends around the crus cerebri, bounds externally the fissure into this part of the ventricle, and forms inferiorly the hippocampus major, by its projection into the inferior cornu. Turn aside the tænia hippocampi, and remove the pia mater from the grey matter beneath it, and the margin of the grey matter contained in the *navicular fossa* of the convolution has a notched or serrated border, which has been named the *corpus denticulatum* or *fascia dentata*. If the hippocampus be divided, it is seen to be formed by the convolution of the corpus callosum, which projects into the cornu; it is covered internally by medullary matter, and into its centre projects also a medullary layer.

Pes.

Tænia Hippocampi.

Fascia dentata.

Fissure of Bichat. By replacing the convolution of the corpus callosum against the crus cerebri, and again removing it, a correct knowledge will be obtained of the formation of the *fissure of Bichat*, or great horizontal fissure of the brain. This fissure is an interval left, in the development, backwards, of the hemispheres, between them and the corpora quadrigemina, in the middle line, and between them and the crus cerebri and optic thalamus on each side. It consists of a central or horizontal portion between the corpus callosum and fornix above, and the tubercula quadrigemina below, and of a vertical or descending part, on each side, which reaches nearly to the fissure of Sylvius, and it is bounded, externally, by the corpus fimbriatum, and convolution of the corpus callosum, or by the inner part of the hemisphere; and, internally, by the crus cerebri and optic thalamus. Through this great fissure the pia mater projects into the lateral ventricle, forming in the centre the velum interpositum; and the lateral portion of the membrane, corrugated and irregular at its margin, is the plexus choroides. A part of the same fissure, is the interval in the lateral ventricle, between the margins of the fornix and the optic thalamus, since, if the hemispheres were forcibly pulled forward, the fornix would be raised with them. The reflections of the arachnoid membrane in the cavity of the ventricle, as before said, close this fissure.

The *velum interpositum* is the central part of the fold of pia mater, which enters the brain by the fissure of Bichat; it is situated beneath the fornix, and it covers the interval left between the optic thalami: it is triangular in shape, the base behind, and the apex in front in the foramen of Monro, and it divides anteriorly into two portions which join the plexus choroides. The upper surface is in contact with the fornix, to which it gives many vessels, which were cut through in raising this body; the under surface looks to the third ventricle, of which the velum forms the roof, and it covers a part of the optic thalamus of each side, the pineal body, and the veins of Galen, which are seen through it. The borders are connected to the plexus choroides by a thin portion of membrane, which passes beneath the border of the fornix. The *plexus choroides* of each side, or the free margin of the fold of pia mater which enters by the fissure of Bichat, is a red, somewhat round, fringed body, which extends through the lateral ventricle from the foramen of Monro to the aperture in the inferior cornu; its lower portion is larger than the anterior, and it lies on the optic thalamus, by the side of the fornix, in the horizontal portion of the ventricle, and on the hippocampus major in the descending portion; a thin fold of pia mater passes beneath the margin of the fornix to connect it to the velum interpositum, and in the foramen of Monro it joins also the velum. It contains arteries and veins, and it receives veins from the walls of the ventricle; from its anterior part emerges a vein to join the vein of Galen of that side. Some rounded hard bodies, as well as small cysts, are found oftentimes in this fold of vascular membrane.

Velum interpositum.

Plexus choroides.

The *veins of Galen* may be rendered visible by blowing them up by means of a pipe introduced into the extremity that joins the straight sinus; there is one for the right and one for the left side, and each commences at the foramen of Monro, by the union of the large vein from the corpus striatum with one from the plexus choroides; the veins then run side by side to the back part of the velum interpositum, and they usually join into one, which opens, at the margin of the tentorium, into the straight sinus: before doing so, it is joined by a vein from the upper surface of the cerebellum.

Veins of Galen.

Raise the vein formed by the union of the veins of Galen; it is enveloped by a funnel-shaped tube of the arachnoid membrane, and beneath it is the aperture described by Bichat as the canal by which the arachnoid membrane enters the ventricles. The *canal* of *Bichat*, situated below the velum interpositum and the veins of Galen, and above the pineal body, opens in front of the pineal body, but below it, into the posterior part of the third ventricle behind the plexus choroides of this ventricle: this will be seen when the velum is raised. This canal, closed in the adult, is open in the fœtus, and the arachnoid membrane, which

Canal of Bichat.

enters by it, passes into the third ventricle, which it lines; then into the two lateral by the foramen of Monro, and into the fifth by the aperture of communication with the third; from the third it is prolonged backwards into the fourth, from which it is continued into the sub-arachnoid space of the cord by the aperture of the fourth ventricle. In the lateral ventricle the serous membrane envelopes the plexus choroides; and by its reflection from one margin to the other of the fissure of Bichat, this great aperture into the lateral ventricle is closed.

Dissection. Raise, with care, the velum interpositum, without removing the pineal body which is closely surrounded by the pia mater; and on its under surface are two folds of membrane, similar to the plexus choroides of the lateral ventricles, with which they join in front: these are the *plexus choroides* of the *third ventricle*. The third ventricle is now exposed.

Third Ventricle. The *third ventricle*, or interval between the optic thalami, is situated in the middle line of the cerebrum, below the level of the other ventricles, with all of which it communicates, and its floor forms part of the base of the brain; the depth of the cavity is much greater before than behind, in consequence of the

Boundaries. obliquity of its floor. The sides of the ventricle are the optic thalami; and, stretching across the centre of the space from one to the other, is a soft grey body, — the *soft commissure*. This is to be cut through, and it will be seen that the upper part of each lateral boundary is the optic thalamus, with the peduncles of the pineal body extending along it; but the lower and anterior, is the grey substance of the third ventricle: a groove separates the two portions. The roof is formed by the velum interpositum and fornix; and the floor, covered by the grey matter of the ventricle, consists of a narrow, grooved part, behind, which corresponds to the locus perforatus between the crura cerebri; but in front of this the floor is hollowed out, and is placed over the corpora albicantia, tuber cinereum, and infundibulum; and still anterior to this is the lamina cinerea, inclined obliquely downwards and backwards. In front of this space are the descending crura of the fornix, and the anterior commissure, which is a round, white cord, situated in the interval between them and in front of them; and behind are the posterior commissure, pineal body, and corpora quadrigemina. This space, or ventricle, joins anteriorly the lateral ventricles by the foramen of Monro, and also the fifth ventricle, in the fœtus; inferiorly is the prolongation, below the anterior commissure, into the infundibulum, or the *iter ad infundibulum*, which descends only a certain way, since the arachnoid closes it below; and posteriorly is the aqueduct of Sylvius, or *iter à tertio ad quartum ventriculum*,— an aperture which leads into the fourth ventricle beneath the posterior commissure and the corpora quadrigemina.

The *grey matter* of the third ventricle entirely conceals the crus of the fornix, which descends by the side of the optic thalamus, and it is prolonged along these to the septum lucidum; it is also continued across the cavity as the soft commissure; below it is continuous with the tuber cinereum, with the grey matter in the corpora albicantia and their commissure, and in front with the lamina cinerea. Grey Substance of the Ventricle.

The *pineal body* or *conarium*, of a greyish colour, is conical in form; the base in front is attached to its peduncles, and the apex behind is free; it is situated between the anterior pair of the tubercula quadrigemina, and above the posterior commissure; it is closely enveloped by pia mater, except below, and it is attached to the optic thalami by two medullary processes, — the *peduncles*, which extend along the upper and inner part of the thalami, and end, anteriorly, by joining the descending crura of the fornix. Two other crura are described as passing vertically down the inner part of the optic thalamus. This body is sometimes hollow, the interior being lined by a thin vascular membrane, and at others it is solid: when it is pressed between the fingers, a viscid fluid is squeezed from it, and it often contains calcareous particles. Pineal Body. Peduncles.

The *thalamus opticus*, to be seen on that side on which the inferior cornu has been dissected, is a square-shaped body which assists to form part of the third and of the lateral ventricles, and it is sometimes called the inferior ganglion of the brain, from the fact of the fibres of the crus cerebri being increased in number after they have passed through it in their course to the cerebrum. The upper surface forms part of the floor of the lateral ventricle, it is marked by a tubercle in front, near the tænia semicircularis, in which the root of the fornix arises, and it is covered in part by the plexus choroides and the margin of the fornix. The under surface forms a portion of the roof of the inferior cornu, and it is joined by the crus cerebri; the inner enters into the third ventricle, the lower half being covered by the grey matter of the ventricle, and along its line of junction with the upper surface is the peduncle of the pineal gland; the crus of the fornix descends also along this surface of the optic thalamus; the outer surface is in contact with the corpus striatum and substance of the hemisphere. The anterior extremity, directed inwards to the middle line, looks to the foramen of Monro, of which it forms the posterior limit, the fornix bending round it to form the anterior part; the posterior extremity, from the obliquity of the position of the thalamus, looks outwards to the inferior cornu, and it has on its surface two small, round, but prominent, medullary tubercles, — the *corpora geniculata*, to which the optic nerve is connected; they are named, from their position, *corpus geniculatum internum* and *externum*. These bodies are grey internally, but white exter- Thalamus opticus. Corpora geniculata.

nally, and extending towards the internal is a medullary band from the testes. Raise well up the under surface of the optic thalamus to see the origin of the optic nerve from the corpus geniculatum externum, by one medullary band which passes then onwards above the corpus geniculatum internum to the nates, and by another band from the corpus geniculatum internum; the nerve is also connected to the optic thalamus. The internal structure of the thalamus and corpus striatum will be dissected after the examination of the commissures and crura of the fornix.

Anterior Commissure.

The *anterior commissure* of the cerebrum is a white round cord placed transversely between the corpora striata, and in front of the third ventricle; its size is about that of a goose quill, and the central part only of this body is seen in the third ventricle between the crura of the fornix, in front of which it is situated; the posterior part is free, but to the anterior is attached the septum lucidum; the lateral part of the anterior commissure has been seen in dissecting the base of the brain, and the corpus striatum of the same side.* Each lateral half passes outwards through the inner portion of the grey substance of the corpus striatum, and below or through the anterior radiating fibres of the fibrous cone; it then turns outwards, and it is directed downwards and backwards through the outer mass of grey substance of the corpus striatum external to the tractus opticus, to which it is nearly parallel; it then perforates the outer wall of the medullary capsule of this mass, and it ends in diverging fasciculi of fibres which join the medullary substance of the roof of the inferior cornu of the middle lobe, and some reach even to the posterior lobe. The commissure is formed of fasciculi of fibres invested with a cellular sheath.

Posterior Commissure.

The *posterior commissure,* much smaller than the anterior, is situated between the posterior part of the optic thalami, above the aqueduct of Sylvius, and beneath the pineal body; on each side it reaches to the thalamus, in which it ends.

Dissection.

To trace the anterior pillar of the fornix, carry the knife through the anterior commissure in its centre, as well as through the prolonged part of the corpus callosum; gently separate the hemisphere from the opposite one, and trace the crus of the fornix down through the grey matter of the third ventricle to the corpus albicans; from this, follow it upwards in the substance of the inner part of the thalamus to the projection on its upper surface.

Crus of the Fornix.

The *crus of the fornix* commences in the optic thalamus about a line beneath the tubercle on its upper surface; it then descends,

* If the dissector is willing to forego the view of the structure of the corpus striatum from the outside, he may follow the anterior commissure, on the side in which the corpus striatum is untouched, according to the dissection given in a note to page 40.

convex backwards, to the corpus albicans, and it makes a turn like the half of the figure of eight to envelope the grey matter in this body; the crus is then directed forwards and upwards in an arched form, with its convexity forwards, through the grey substance on the side of the optic thalamus; disengaged from this, it is joined by the medullary bands of the tænia semicircularis, and of the peduncle of the pineal body; each crus then turns upwards behind the anterior commissure, and, in front of the optic thalamus, it unites with the opposite one in the horizontal part or body of the fornix, which has been seen.

Dissection. To obtain a view of the structure of the optic thalamus and corpus striatum, carry a vertical incision forwards, from the cut, to expose the inferior cornu, along the hemisphere, and close to the outer side of these bodies; then make successive cuts into them.

Structure of the Corpus striatum and Optic Thalamus. These sections will show the *corpus striatum* divided into two portions by the white fibres passing through its centre; the upper portion is large in front and pointed behind; and the lower contained in its capsule, is oval in shape, and it extends as far back as the posterior extremity of the optic thalamus; the outer wall of the capsule is removed by this section, but the upper and lower boundaries remain. The anterior commissure perforates the outer wall of the capsule, after passing through the grey matter contained in it. The *optic thalamus* is formed in its upper and internal parts by layers of grey and white substance, and between the upper two of these is the band of origin of the crus of the fornix; in a hardened brain these layers can be traced to be continuous with the expansion of the fillet, with the superior peduncle of the cerebellum, and with the band from the corpus geniculatum internum. The lower and outer part is medullary, and consists of the fibres from the upper part of the crus, which ascend through this body, and then radiate from it in the fibrous cone.

Dissection. Cut, vertically, through the centre of the optic thalamus of each side, and remove, from the corpora quadrigemina and cerebellum that remain united, the whole of the cerebrum in front of the incision: take away the pia mater from the surface of the corpora quadrigemina, if it is not done.

Corpora quadrigemina. The *corpora quadrigemina* or optic lobes, four rounded bodies, a pair being on each side of the middle line, are on the upper surface of the crura cerebri, and in front of the pons; a groove in the middle line separates the two bodies of the right side from that of the left, and there is a second one which is transverse, between the anterior and posterior pair. The *anterior pair*,—the *nates*, larger than the posterior and oblong from before backwards, send forwards, on each side, a medullary band to join the optic thalamus and the optic nerve; and it is continued above the corpus geniculatum internum. The *posterior pair*,—

Nates.

Testes. the *testes*, smaller than the preceding, and round, are whiter in colour, and on each side is a medullary band sent forwards beneath the corpus geniculatum internum to blend with the optic thalamus. A vertical process — the *columella* — extends backwards, from the interval between the testes to the valve of Vieussens. These bodies are four round masses of grey substance, placed above the iter à tertio ad quartum ventriculum, and on the process of the fillet that passes inwards to join a similar process of the opposite side.

Columella.

Fillet of the Olivary Body. On each side of the corpora quadrigemina is a triangular portion of medullary substance, the apex of which is above at the testes, the base, below, marked by a line that separates it from the crus cerebri. The anterior side is the band from the testes to the optic thalamus, and the posterior is marked by the superior peduncle of the cerebellum. This portion of medullary substance is continuous with the *fillet or band of the olivary body*, which escapes from the pons between the superior and lateral peduncles of the cerebellum, and, after sending inwards a process beneath the corpora quadrigemina, over the fibres of the superior peduncle of the cerebellum, to join a similar one from the opposite side, it passes forwards into the optic thalamus, and joins the radiating fibres of the fibrous cone: this can be traced only in a hardened and prepared brain.

Section of the Crus Cerebri. A horizontal section of the other crus cerebri may now be made, to see the disposition of the fasciculi of fibres from the medulla oblongata on each side of the locus niger; those on the upper surface of the crus, from the lateral part of the medulla, are more numerous than those on the under, from the pyramid, and they join directly the optic thalamus; whilst those below the locus niger pass upwards to the corpus striatum. The convexity of the locus niger, and its position nearer the inner than the outer side of the crus, are also visible.

Dissection. Remove the pia mater from the surface of the cerebellum, but with great care from the median fissure on the under surface; pass the handle of the knife in the horizontal fissure between the upper and under surfaces of the cerebellum, round to the median fissure behind.

Cerebellum. The *cerebellum* or little brain is elongated transversely, and therefore its greatest measurement, which is about four inches, is from side to side; it is situated in the inferior occipital fossæ of the base of the skull, and beneath the tentorium cerebelli which separates it from the cerebrum; and, like the cerebrum, it is divided into a right and a left hemisphere by a fissure at the back, into which the falx cerebelli is received; as well as by a deep sulcus on the under surface. The upper surface, raised in the centre, but sloped off obliquely to the sides, is separated from the under by the horizontal fissure, which is wide in front, for the reception of the peduncles of the cerebellum, but narrow

behind, as it is continued backwards to the central fissure. There is no median sulcus along the centre of this surface to establish the division into hemispheres, but each half is connected by a prominent portion,—the *superior vermiform process*, which occupies the middle line like an isthmus between the hemispheres, and it extends from the anterior part of the cerebellum to the median fissure behind; it consists of laminæ, which are continuous across the middle line, between the front of each hemisphere, and the most anterior laminæ are bent forwards. The under surface is more distinctly divided into two hemispheres by a great median fissure,—the *valley*, which is wider in the centre than at either extremity, and receives the medulla oblongata. In the bottom of the valley is a large projecting body,—the *inferior vermiform process*, which is separated from the hemisphere, on each side, by a depression that contains the inferior cerebellar artery, and the process extends backwards to meet the superior vermiform in the posterior part of the median fissure; the two together are named the general commissure of the cerebellum, from connecting in the middle line the corresponding parts or lobes of each hemisphere. But the inferior is divided into many parts that may be readily separated by the handle of the knife introduced between them, after the removal of the pia mater, and the following is their arrangement from behind forwards: some transverse laminæ, named *commissures* by Reil, between the posterior part of each hemisphere; then the *pyramid*, a tongue-shaped body, elongated transversely, which forms the largest portion of the inferior vermiform process, and it is marked by transverse laminæ; in front of this is the *uvula*, a narrower body, longer from before backwards than from side to side; it is divided into laminæ, and it is marked also on each side by a *furrowed band;* and lastly, the apex of the uvula, which projects into the fourth ventricle, is the *nodule*.

Superior Vermiform Process.

Valley.

Inferior Vermiform Process.

Commissures of Reil

Pyramid.

Uvula.

Nodule.

Each hemisphere is convex downwards, on the under surface, to correspond to the concavity of the occipital fossæ of the base of the skull, and it has appended to it two small lobes, the amygdala, or almond-like lobe, and the flocculus, or sub-pedunacular lobe.* The *amygdala* is a small, roundish lobe which projects into the valley opposite the uvula, and it is partly concealed by the medulla oblongata. The flocculus will be seen by cutting off a portion of the under surface of the hemisphere external to the almond-like lobe, so as to allow this lobe to be everted from its position in the valley: in doing this, great care must be taken not to injure a thin medullary lamina attached to the nodule, and lying before this lobe. The *flocculus* is a small rudimentary lobe which appears on the surface of the cerebellum beneath the seventh and eighth nerves, and between the middle

Lobes of the Cerebellum.

Almond-like Lobe.

Flocculus.

* Each surface of the cerebellum has been divided into other lobes besides these. See the Essays of Reil on the Cerebellum.

and inferior peduncles of the cerebellum; it is divided into laminæ, and it is attached by a white medullary stem which divides into processes for the laminæ, and is then continued to the floor of the fourth ventricle, and to the inferior vermiform process.

Posterior Medullary Velum.

Connecting the flocculus to the nodule is a thin, delicate, medullary lamina,—the *posterior medullary velum*, of a semilunar form, with its convex border attached, behind, to the restiform body, and to an elevation of medullary substance, which limits, behind, a depression,—the *swallow's nest*, and is placed in front of the lateral furrowed band which extends between the amygdala and the uvula; its anterior border is unattached between the inner connection to the nodule, and the outer to the flocculus; the inner part of the posterior velum joins the anterior velum or valve of Vieussens, and with it assists to form the roof of the fourth ventricle. This dissection exposes also the membrane that closes the fourth ventricle, below the medullary vela, by its reflection from the side of the medulla to the nodule and under surface of the cerebellum, and to it are fixed the plexus choroides of the fourth ventricle: the aperture to the fourth ventricle is in this membrane.

Dissection.

Turn over the cerebellum, and placing the knife in the horizontal fissure, on the side opposite to the one on which the pons was dissected, remove the laminæ superficial to it, as far as to the vermiform process, and expose the corpus dentatum in the medullary substance which now comes in view: in the opposite hemisphere a vertical incision may be made into the laminæ.

Structure of the Cerebellum.

The surface of the cerebellum is marked by laminæ instead of convolutions, and, placed one before the other, they form segments of circles with the convexity directed backwards, and those at the circumference are the largest. On the upper surface the laminæ are continued from one hemisphere to the other with only a slight inflection forwards in the superior vermiform process; but on the under they are separate and distinct in each hemisphere, in front, and the posterior only join the lateral parts of the inferior vermiform process. Between the laminæ are sulci which extend downwards to different distances, the deeper ones separating the cerebellum into segments or lobes, and the shallower ones into laminæ; these sulci are interrupted here and there by cross laminæ. Each lamina consists of an external grey, enveloping part, and of an interior medullary portion, and when these are divided vertically, they have a disposition resembling the branching of a tree; and therefore it is called the *arbor vitæ;* this is produced by offsets or prolongations from the medullary centre of the cerebellum, which divide into smaller branches, and these again subdivide into still smaller, which enter the centres of the laminæ, and are invested by the grey exterior. The large medullary centre is now exposed by

the horizontal section made in the one hemisphere; it occupies the centre of the cerebellum, it sends processes from its circumference to the different laminæ that cover it, and, in front, the *peduncles* to connect the cerebellum to the cerebrum, pons, and medulla oblongata; in its centre is contained the *corpus dentatum* or *rhomboideum*, which resembles that in the medulla oblongata in structure, since it is a partial capsule formed by an undulating line of grey or brown matter, interrupted in front; and it contains an orange-white nucleus that is continuous, anteriorly, where the capsule is deficient, with the superior peduncle of the cerebellum. This body measures three quarters of an inch from before backwards, and about half an inch from side to side, but its depth is much less: it reaches internally to the inner border of the medullary centre, and, behind, to about two lines from the horizontal fissure that divides the upper from the under surface of the cerebellum; numerous veins are found in it, and it has been called the ganglion of the cerebellum by Gall: a vertical section may be made of it in the opposite hemisphere. The large processes that pass in front from this centre are called superior, middle, and inferior peduncles of the cerebellum.

Corpus dentatum.

The *superior peduncles*, or *processus ad cerebrum*, commonly called *processus ad testes*, are rather flat, they form part of the roof of the fourth ventricle, and the fibres are continuous behind with the medullary centre, as well as with those of the nucleus of the corpus dentatum; each extends forwards to the posterior part of the corpora quadrigemina, and it then dips downwards and inwards beneath these bodies, and the band of the fillet, to reach the thalamus opticus in which the fibres expand. Between the processes of opposite sides is a thin medullary membrane,—the *anterior medullary velum* or *valve* of *Vieussens;* it is pointed in front and connected to the posterior part of the corpora quadrigemina, to which it is joined by a small vertical process; and it is wide and expanded, behind, at its junction with the posterior medullary velum and medullary substance on the under surface of the vermiform process; a part of this process may be removed to see this. The fourth nerve of each side arises from its anterior extremity, and it forms a part of the roof of the fourth ventricle. The *middle peduncle*, or *processus ad pontem*, commonly named the crus cerebelli, is the largest of the peduncles, it ascends for a short way nearly parallel to the superior, and then turns outwards and forwards to the pons, whose transverse fibres are formed by it; and its fibres arch over the ascending or longitudinal fibres of the crus cerebri. The *inferior peduncle, processus ad medullam*, or restiform body, passes downwards and backwards to the medulla, on each side of the fourth ventricle, and it will be more fully seen in the fourth ventricle.

Superior Peduncle.

Anterior Medullary Velum.

Middle Peduncle.

Inferior Peduncle.

Dissection. Divide the superior vermiform process through its centre, or to one side of it, and the fourth ventricle is exposed by pulling away from each other the halves of the cerebellum.

Fourth Ventricle. The *fourth ventricle* is a lozenge-shaped space at the back of the medulla oblongata and pons, and it results from the lateral divergence of the posterior pyramids and restiform bodies to reach the cerebellum, instead of being continued vertically upwards in the middle line, as the other portions of the medulla.

Boundaries. The upper angle of the lozenge, reaching as high as the upper border of the pons, is between the superior peduncles, and in it is the aperture of communication with the third ventricle; the lower angle is between the restiform and pyramidal bodies, and the aperture from this ventricle to the subarachnoid space is found in this part. The roof of the cavity is raised in the middle, opposite the vermiform process, and the two medullary vela are inclined obliquely towards each other, and the section now made shows it to be formed in front by the anterior medullary velum or valve of Vieussens which looks downwards; below this, by the inferior medullary velum which looks forwards, and joins above the anterior; then by the medullary surface of the nodule of the vermiform process; and, lastly, by the fibrous membrane between the medulla oblongata and cerebellum. The floor is vertical, and it is formed by the posterior surface of the medulla oblongata and pons; it is bounded below on each side by the restiform body and posterior pyramid, and, above this, by the superior peduncle: these bodies inclose with those of the opposite side, the lozenge-shaped space of the fourth ventricle. In the centre of the space is a median groove, which ends below in a point, and which, from some resemblance to a writing pen, is called *calamus scriptorius;* the median groove of this represents the shaft, its lower termination in a *cul-de-sac* beneath the posterior pyramids, the point of the pen, and the lateral striæ, the barbs. On each side of the median groove is a cylindrical elevation which ascends from opposite the decussation of the pyramids, and it is formed by the fibres of the lateral part or tract of the cord, which pass to the floor of the fourth ventricle, before they enter the pons; these bodies are wider in the centre of the fourth ventricle than in either the upper or lower part, and they are continued upwards through the pons to the thalami. Crossing inwards round the restiform bodies, are the striæ before alluded to; they are some filaments of origin of the portio mollis of the seventh nerve from the grey matter of the fourth ventricle. The surface of the floor of the fourth ventricle is covered by a thin layer of medullary matter, and through it is seen the grey matter diffused over the lozenge-shaped space of the floor; this is a continuation of the grey matter of the cord, and it is left exposed by the divergence of the posterior

Calamus scriptorius.

divisions of the cord from the middle line. At the upper part of the floor, and in the line of union of the superior peduncle with it, is a line of very dark substance. This ventricle is continuous, above, with the third ventricle by the aqueduct of Sylvius, and with the sub-arachnoid space by the aperture in its lower part; the arachnoid membrane of one is prolonged into the other. In the fourth ventricle is a *plexus choroides* for each side, similar to those in the lateral ventricle; each is attached to the pia mater that closes the cavity below, it passes upwards and outwards over the restiform body, and enlarges beneath the pneumo-gastric nerve, and it ends, at this spot, in contact with the flocculus.

Plexus choroides.

The *posterior pyramid*, placed nearer the middle line than the restiform body, is continuous above with this body, and below it extends down the posterior part of the cord on each side of the posterior median fissure; it is about two lines wide, it is separated from the restiform body by a slight depression; and, at the point of divergence from the middle line, and over the point of the calamus, each is slightly enlarged in size, but it becomes gradually smaller above this, and joins the restiform body.

Posterior Pyramid.

The *restiform bodies*, now also more fully exposed than when dissecting the medulla oblongata, are two white cords, one on each side of the fourth ventricle which they bound below; they are roundish in shape, and are joined by the fibres of the posterior pyramid, as well as by the fibres from the front and lateral part of the cord: each is continued up to the cerebellum. A little below the olivary body the restiform is slightly increased in size, and when it is cut into, it is seen to contain a grey substance, — the *grey tubercle* of Rolando, the continuation upwards of the lateral portion of the grey substance of the cord.

Restiform Body.

Grey Tubercle of Rolando.

The *general commissure* of the cerebellum, or median lobe, consisting of the superior and inferior vermiform processes, is seen, by the incision through the centre, to be formed of laminæ with a grey exterior and a white interior, as in the other portions of the cerebellum. The medullary centre of the middle lobe, continuous on each side with that of the hemispheres, extends below into the roof of the fourth ventricle, partly enveloping the anterior extremity of the inferior vermiform process; and it gives off, above, two primary portions, one for the upper and one for the lower vermiform process, which subdivide into secondary processes, and these again into smaller ones, which are distributed to the laminæ of the vermiform process.

Structure of the General Commissure.

The fibres of the brain can be traced only in a brain that has been hardened; but should the dissector wish to follow them in a prepared brain, he will find ample directions, and a detailed and accurate description of them, in the essays of Reil.

THE BASE OF THE SKULL, WITH THE DURA MATER AND NERVES.

Dissection. After the completion of the brain, return to the examination of the dura mater, and sinuses in the base of the skull, as well as the apertures by which the nerves pass from the cranium; raise the head with blocks, and fasten the tentorium near its natural position by two or three stitches. The dissector should be provided with the base of a skull for this dissection.

Tentorium Cerebelli. The *tentorium cerebelli* is an almost horizontal partition between the cerebrum and cerebellum, and it supports the posterior lobes of the cerebrum, which, alone, rest on it. The posterior or attached margin is convex; it is much larger in extent than the free one, and it contains the lateral and the superior petrosal sinus of each side; each half of this border adheres to the transverse groove on the inner surface of the occipital bone, to the inferior angle of the parietal, to the ridge or upper border of the petrous portion of the temporal, and to the posterior clinoid process of the sphenoid bone. The anterior, or free margin is concave, and it is separated from the body of the sphenoid bone by an interval, in which is placed the pons Varolii; this border is fixed in front to the anterior clinoid process of each side by a narrow pointed slip, which passes over the attachment of the convex border to the posterior process, and assists to form, laterally, the fossa for the pituitary body: the third nerve lies in the interval between the attachments of the pointed extremities of the two borders to the clinoid processes. The upper surface in the natural state of parts, is convex along the middle line, and it is maintained in this position by the falx which is connected to it; the posterior cerebral lobes lie on it. The under surface is concave, and in contact with the cerebellum. Along the centre is the straight sinus which reaches back to the torcular Herophili, and in its circumference is a portion of the lateral sinus of each side, as well as the superior petrosal sinus of each side. Cut through the stitches, raise the tentorium, and beneath it is the fold of the falx cerebelli.

Falx Cerebelli. The *falx cerebelli* is a fold of the dura mater, that resembles the falx cerebri, except that it is so much smaller; the base of the fold is directed, like that of the falx cerebri, to the tentorium, and the apex is below, at the foramen magnum of the occipital bone, to each side of which it sends a small slip. The anterior border projects into the interval between the hemispheres of the cerebellum, whilst the posterior is fixed to the part of the vertical crest of the occipital bone, below the transverse ridge. The sides are in contact with the surfaces of the hemispheres, and the occipital sinuses are contained in the fold.

The *sphenoidal fold* is a narrow process which is fixed to the small wing of the sphenoid bone, and it projects into the fissure of Sylvius. Sphenoidal Fold.

In the base of the skull the dura mater sends processes through the different apertures to join with the periosteum of the bones; it also gives sheaths to the different nerves, and it dips into the different inequalities of the base; thus, when it is examined from before backwards, it is found to be attached to the crista galli, and it sends a prolongation into the foramen cæcum; on each side of this process of bone, it sends down, through the foramina of the cribriform plate, a series of tubes which surround the divisions of the olfactory nerve, and unite with the lining membrane of the nose: small processes also pass through the orbital foramina to join the orbital process. Each optic nerve receives a separate sheath which accompanies it to the sclerotic coat of the eye, and a large process enters into the orbit by the sphenoidal fissure, to serve as a periosteum to the bones of this cavity. The sella turcica is lined by the dura mater, but the pituitary body intervenes between the arachnoid and it. By the side of the body of the sphenoid bone, it divides into two layers that inclose the space of the cavernous sinus, and the third and fourth nerves, and the ophthalmic division of the fifth, receive a prolongation from it as they enter the wall of the sinus; the sixth nerve does not appear to receive a tube from it. In the middle line it adheres closely to the basilar process of the occipital bone, and it then descends into the spinal canal, which it lines; it is attached very firmly to the margins of the foramen magnum. A process of it enters the meatus auditorius internus, and at the foramen lacerum, distinct apertures exist for the divisions of the eighth nerve, and for the sinuses. Connections of the Dura Mater in the base of the skull.

The *sinuses* of the dura mater are, as before stated, only venous spaces between its layers, into which the blood is received before it passes from the skull by the two lateral sinuses. In the interior of the skull, the sinuses are collected together into two centres, which may be taken as points of departure in the examination of them; one, the torcular Herophili, is opposite the occipital protuberance, and the other, the cavernous sinus, is placed by the side of the body of the sphenoid bone. Sinuses of the Dura Mater

The *torcular Herophili* is placed opposite the occipital protuberance, between the layers of the tentorium, and, when opened, it is seen to be an irregularly-shaped space, into which numerous sinuses open: thus, above, is the superior longitudinal sinus; below, the two occipital; on each side, the lateral sinus; and, in front, the straight sinus which is joined by the inferior longitudinal. Torcular Herophili.

The *straight sinus* occupies the centre of the tentorium, and Straight Sinus.

it corresponds to the line of union of it and the falx cerebri. It is of a triangular shape; it is joined in front by the inferior longitudinal sinus, by the veins of Galen, which come from the interior of the brain, and it receives also some small veins from the posterior part of the cerebrum and upper part of the cerebellum. Its opening into the torcular Herophili is sometimes double.

Inferior longitudinal Sinus.

The *inferior longitudinal sinus* is very small, and it is contained in the free or concave margin of the falx, of which it occupies about the posterior half; it receives blood from the falx, and opens into the straight sinus. The superior longitudinal sinus has been already dissected.

Occipital Sinus.

The *occipital sinuses* are two small sinuses in the falx cerebelli. They commence by the sides of the foramen magnum, and sometimes they unite with the lateral sinuses; pass a probe into them from above, and cut them open. They receive veins from the dura mater that lines the occipital fossæ, and they open into the torcular Herophili.

Lateral Sinus.

The *lateral sinuses* appear to be the continuation of the torcular Herophili, and they are the channels by which the blood collected at this point is carried from the skull. They extend from the occipital protuberance to the foramen lacerum jugulare, and they end in the internal jugular vein; lay open the sinuses; they are smaller at their commencement than at their termination, and the right is usually larger than the left. Each sinus, in its course to the foramen lacerum, is very flexuous, and makes two turns, one on the inferior angle of the parietal bone, and the other on the jugal eminence of the occipital bone. It first passes horizontally outwards on the occipital bone, then on the inferior angle of the parietal; it now descends almost vertically on the mastoid portion of the temporal bone, and it lastly passes forwards on the occipital to reach the foramen. In its course, it receives the superior petrosal sinus opposite the upper border of the petrous portion of the temporal bone, some small veins from the cerebrum and cerebellum, and oftentimes a small vein by the mastoid foramen, and, as it is passing from the skull, it is joined by the inferior petrosal sinus. The foramen lacerum jugulare is subdivided into three distinct portions by processes of the dura mater, which are attached to projections seen along the margins in the dried bones; the posterior one, the largest, gives passage to the jugular vein; the anterior, the smallest, to the inferior petrosal sinus; and the middle to the divisions of the eighth nerve, which again perforate the dura mater through smaller openings. If the inferior petrosal sinus be laid open, and if a probe is passed into it, as well as into the lateral sinus, it will be seen that these sinuses are united only at the lower border of the foramen, or where the sinus ends in the internal jugular vein.

The *cavernous sinus*, so named from the reticulated structure of its interior, is placed by the side of the body of the sphenoid bone, and it is formed by the dura mater dividing into two layers, one of which lines the surface of bone that corresponds to the sinus, and the other is stretched across the hollow, on the side of the body of the sphenoid, at some distance from the bone, and it forms the outer wall which contains some nerves and veins. The space, or sinus included in the separation of these two layers, extends from the posterior clinoid process and tip of the petrous portion of the temporal bone to the sphenoidal fissure in front. Open the sinus, on the left side, by an incision through the outer boundary, a little in front of the posterior clinoid process, and external to it: this is to be done without injuring the small fourth nerve contained in this portion of dura mater. The irregular space of the sinus is larger behind than before, and, in the cavity, are many shreds of fibrous tissue with small arteries. The internal carotid artery passes through the space from behind forwards; it makes a remarkable curve in it, and on the outer side of the artery is the sixth nerve which enters the posterior part of the space; the artery and nerve are not in contact with the blood of the sinus, since the thin lining membrane of the cavity is reflected around them, in the same way as the serous membranes of other cavities around the viscera that are contained in them. In the outer wall of the sinus are the third and fourth nerves, and the ophthalmic division of the fifth: these lie in the dura mater, and are provided with fibrous sheaths from it. This sinus receives, in front, the ophthalmic vein, and some small veins from the under surface of the cerebrum perforate the outer wall; it communicates with the one of the opposite side by the circular sinus, and posteriorly with the lateral, by the petrosal sinuses. The probe should be passed into these different sinuses as they are described.

Cavernous Sinus.

The *circular sinus* of Ridley consists of two portions that reach from the cavernous sinus of one side to that of the other; one passes in front of the pituitary body, and the other behind it; they receive small veins from the pituitary body, and they allow the blood in the cavernous sinus to pass freely from one side to the other. These are destroyed by the removal of the pituitary body.

Circular Sinus.

The *transverse or basilar sinus*, named from its position across the basilar process of the occipital bone, is on a level with the point of the petrous portion of the temporal bone, and the posterior angle of the cavernous sinus appears to be prolonged into it. A second transverse sinus is sometimes found lower down on the basilar process.

Transverse Sinus.

The *superior petrosal sinus* extends backwards from the cavernous to the lateral sinus; it is contained, at first, in the

Superior petrosal Sinus.

process of dura mater, which lies above the fifth nerve, then in a groove on the upper angle of the petrous portion of the temporal bone, and it joins the lateral sinus where it touches the mastoid portion of the temporal bone. It receives a small vein from the cerebellum.

Inferior petrosal Sinus.

The *inferior petrosal sinus,* shorter in extent than the superior, lies in the angle of union of the petrous portion of the temporal bone and the basilar process of the occipital, and at the foramen jugulare it passes through the anterior of the three spaces into which the aperture is divided by the dura mater; it is then continued downwards on the outer and anterior surface of the pneumo-gastric nerve, between it and the glosso-pharyngeal, to open into the lateral sinus, as this ends in the internal jugular vein, close below the foramen. The course of this sinus is sometimes external to the sixth nerve, and at others internal to it. A small vein from the exterior of the skull passes through the foramen lacerum basis cranii to open into the front of it.

Arteries of the Dura Mater.

The *arteries* that supply the dura mater with blood are named meningeal, and they are anterior, middle, and posterior, according as they appear in the anterior, middle, or posterior fossa of the base of the skull.

Anterior Meningeal.

The *anterior meningeal* are very small, and are derived from the anterior and posterior ethmoidal arteries; these are distributed to the dura mater, in the region of the orbital plates of the frontal bone.

Middle Meningeal.

The *middle meningeal* are the largest of the meningeal branches, and the chief of these, on each side, is a branch of the internal maxillary artery. It is named *middle meningeal,* and it enters the skull by the foramen spinosum of the sphenoid bone; it then ascends, with a direction forwards, to the anterior inferior angle of the parietal bone, enters a canal in the bone, and it divides into numerous branches which diverge from each other, and are distributed to the bones of the upper part of the cranium, and to the dura mater. Soon after it has entered the skull, the artery sends backwards a considerable branch over the squamous portion of the temporal bone to the posterior part of the parietal, on which it is distributed in the same manner as the anterior branch. This artery is accompanied by two veins, and it gives off one or more *orbital* branches to the orbit, by some apertures below the small wing of the sphenoid, to anastomose with the ophthalmic artery, another branch — the *vidian* — into the hiatus Fallopii to join the stylo-mastoid artery, and some *temporal* branches enter the temporal fossa. The remaining arteries supplied to the dura mater, in the middle fossa of the base of the skull, are small branches from the ascending pharyngeal, and a small artery, the *small meningeal,* through the foramen ovale: this last is a branch of the middle meningeal, before it enters the cranium.

Posterior Meningeal.

The *posterior meningeal* branches are also small, and they are derived from the occipital and vertebral arteries; those from the occipital

enter by the foramen jugulare, and those from the vertebral are branches of these arteries after they have entered the foramen magnum.

Nerves of the Dura Mater.

The nerves of the dura mater can be seen, only, when this membrane has been prepared by immersion in dilute nitric acid. They are described by Arnold as coming from the fourth nerve, and from the ganglion of the fifth; they supply chiefly the tentorium, and the membrane in the region of the petrous portion of the temporal bone.

Nerves of the Base of the Skull.

The *cranial nerves*, as they pass through the foramina at the base of the skull, are enveloped by processes of the dura mater, which are lost on the nerves, or join the parts to which the nerves are distributed. Some of the nerves, whilst contained in the skull, are received into sheaths of dura mater, which conceal them from view as they reach forwards to their foramina; but the greater number are free, and their cranial course and relations have been referred to with their origins.

Olfactory Nerve.

The *first nerve*, or *olfactory*, forms the olfactory bulb by the side of the crista galli; from this, numerous branches are given off through the foramina in the cribriform plate to be distributed to the lining membrane of the nose; the processes of the fibrous membrane that accompany and surround these filaments are lost in the fibrous structure of the nasal fossæ.

Optic Nerve.

The *second* or *optic* leaves the skull by the optic foramen and with the ophthalmic artery, and the process of dura mater that accompanies it joins the sclerotic coat of the eye.

Dissection.

In the middle fossa of the base of the skull, or by the side of the body of the sphenoid bone, and concealed by the dura mater, are found the third, fourth, fifth, and sixth nerves; with the internal carotid artery, and the cavernous plexus of the sympathetic which lies on it. The third and fourth nerves, with the ophthalmic or orbital division of the fifth nerve, lie in the outer wall of the cavernous sinus, in their numerical order from above downwards, and the sixth lies in the sinus; these all converge to the sphenoidal fissure, by which they leave the skull. The fifth nerve forms a ganglion on the point of the petrous portion of the temporal bone, from which branches proceed, and the carotid artery lies in the cavernous sinus. To expose these parts, make the following dissection: — raise with care, on the right side, the layer of dura mater that forms the outer wall of the cavernous sinus; and, as the fourth nerve is frequently cut in doing this, find it entering the margin of the tentorium, and then reflect the dura mater which is superficial to it; continue the removal of this layer, forwards, to the sphenoidal fissure, and, outwards, rather beyond the line of the foramen ovale and the foramen rotundum, in the middle fossa of the skull. Separate the fibrous sheaths of dura mater from the other nerves in the wall of the sinus, and follow the divisions of

the ganglion of the fifth nerve to their apertures of transmission.

Third Nerve

The *third nerve*, round, rather large and firm, enters the wall of the cavernous sinus by perforating the dura mater near the posterior clinoid process. In its course forwards, to leave the skull by the sphenoidal fissure, it is contained in a fibrous sheath, and it is above the other nerves; but as it approaches the fissure it dips downwards to pass between the two heads of the rectus muscle into the orbit. The nerve lies above the first turn of the carotid artery (for this vessel makes two turns in the cavernous sinus, so as to resemble the letter S), it then runs parallel to the antero-posterior part of the artery, but above it; and it finally crosses on the outer side of the anterior vertical portion of the artery, which ascends to the base of the brain. Near the orbit, this nerve is joined by a delicate filament from the cavernous ganglion, and also by one from the ophthalmic division of the fifth.

Fourth Nerve.

The *fourth nerve*, the smallest of those in the wall of the sinus, is between the third and the ophthalmic division of the fifth, and at the posterior part of the sinus it is much external to the third; the nerve runs forwards along the outer side of the carotid artery to the sphenoidal fissure, and, as it enters the orbit, it rises higher than any other of the nerves that supply this part. It is joined to the ophthalmic division of the fifth whilst in the wall of the sinus, and it frequently deviates from the straight line in consequence of the close connection between it and this branch of the fifth; it sometimes gives branches to the lachrymal nerve, a branch of this portion of the fifth. The nerve gives off a branch to the tentorium; this passes backwards from it, as it lies in the wall of the sinus.

Fifth Nerve.

The *fifth nerve* has been seen to arise by two roots, a large and small, which pass together through an aperture in the dura mater, above the point of the petrous portion of the temporal bone, into the middle fossa of the base of the skull; and, immediately afterwards, the large or sensitive portion enlarges in the Gasserian ganglion, but the small or motor passes beneath the ganglion and joins with only one branch from it. The *Gasserian ganglion*, formed by an inextricable interlacement of fibres, is placed in a depression on the point of the petrous portion of the temporal bone, and it is closely united to a thin layer of dura mater, which must be removed to see that the ganglion presents a semilunar elevation, the convexity of it being directed forwards and the concavity backwards. From the front, or convexity of the ganglion, three branches are given off: the ophthalmic, which runs in the outer wall of the cavernous sinus to the orbit; the superior maxillary, which leaves the skull by the foramen rotundum; and the inferior maxillary, the largest, passes almost vertically downwards through the foramen ovale

Gasserian Ganglion.

in the great wing of the sphenoid bone. Raise the ganglion from the surface of the temporal bone; the small motor portion of the nerve is seen to lie beneath the ganglion, to be unconnected to it, and to pass with the inferior maxillary nerve through the foramen ovale; these unite together external to the skull, but the motor part does not join the whole of the inferior maxillary nerve, but chiefly that portion of it which supplies branches to the muscles of the jaw. The three divisions of the fifth nerve are sensitive as they come off from the ganglion, and it is only that part of the inferior maxillary with which the motor joins, that is both motor and sensitive, and therefore similar to a spinal nerve. The *ophthalmic* or *orbital branch* from the ganglion is the only one that requires to be examined in the base of the skull; it is a large flat band, which is directed forwards in the outer wall of the sinus to enter the orbit by the sphenoidal fissure. This nerve, at its commencement, is much external to the other nerves of this part, and it conceals the sixth, which is internal to it, but not below it; but, as it approaches the orbit, in consequence of the different nerves converging together, it is found below the third and fourth, and above the sixth; it here gives off from its inner side the nasal nerve, and it then divides into frontal and lachrymal. In the wall of the sinus, this nerve is united to the fourth nerve; to the sixth by a small filament, opposite to where the filaments of the carotid plexus join this nerve; and to the third, near the sphenoidal fissure: it is joined also by filaments from the cavernous ganglion near the orbit. This nerve gives some small filaments to the dura mater, and some come also from the Gasserian ganglion.

Ophthalmic branch.

On the anterior surface of the petrous portion of the temporal bone, and beneath the ganglion, are the *small* and *large petrosal nerves;* the latter connects Meckel's ganglion and the carotid plexus with the portio dura, and the former, the otic ganglion with Jacobson's nerve.

Small and large petrosal Nerves.

The *sixth nerve* enters the space of the cavernous sinus by perforating the dura mater behind the body of the sphenoid bone, and it extends forwards to enter the orbit by the sphenoidal fissure. Its extent along the side of the body of the sphenoid bone, from the point of perforating the dura mater, to the fissure, is greater than that of the preceding nerves, and at the back of the sinus it is on the same level as the fifth, and internal to it; but, near the orbit, it is lower than the other nerves that enter the sphenoidal fissure. It lies along the inner boundary of the sinus, separated from the blood by the lining membrane, and it crosses the root of the posterior clinoid process, and the posterior vertical portion of the internal carotid artery; it then runs parallel to the antero-posterior or horizontal portion of the artery, but below it, the third nerve being above

Sixth Nerve.

it, and it finally crosses below the anterior turn of the vessel. As the nerve crosses the carotid artery, it is joined by two or more large branches which ascend from the carotid plexus, and it is joined also at the same part by a filament from the fifth nerve.

Dissection. To see the cavernous plexus, separate, with care, the fifth, fourth, and third nerves, from the carotid artery, and cut off the part of the anterior clinoid process that overhangs the artery. The branches of communication from this plexus to the other nerves are exceedingly minute, and require the carotid artery to be uninjected; it would be better seen, also, in a special dissection of it, when the orbit could be opened.

Cavernous Ganglion. The *cavernous ganglion* is a small plexiform body to the inner side, and somewhat in front of the artery which it surrounds, near where it is crossed by the third and fourth nerves, and the ophthalmic division of the fifth. It receives filaments which ascend, around the carotid artery, from the carotid plexus in the carotid canal, and it sends upwards many filaments around the carotid, which accompany it to its division, and form secondary plexuses around the branches. A small ganglion, the ganglion of Ribes, is said to be placed on the anterior communicating artery of the brain, and in it the nerves of opposite sides are united. The ganglion gives filaments of communication to the ophthalmic division of the fifth, as it crosses the artery; and one long, slender filament which either joins the nasal nerve, or runs alone to the lenticular ganglion in the orbit; this small nerve lies internal to the ophthalmic, and enters the orbit between the two heads of the rectus. The filaments from the ganglion to the third nerve are very small, and they join it just before its division into two branches.

Internal Carotid Artery. The *internal carotid artery*, after ascending in the petrous portion of the temporal bone, enters the cranium at the point of the petrous portion of the temporal; it here lies above the cartilage that closes the foramen lacerum basis cranii, and it is internal to the Gasserian ganglion. The artery then enters the space of the cavernous sinus, and ascends almost vertically towards the posterior clinoid process; it now bends forwards and runs along the side of the body of the sphenoid bone, and on the side of the pituitary body, to the root of the anterior clinoid process; at which point it makes another turn, and ascends internal to the anterior clinoid process, perforates the dura mater again, and comes into contact with the base of the brain opposite the inner part of the fissure of Sylvius; and it finally divides into the anterior and middle cerebral, and posterior communicating, arteries. The course of the artery through the sinus resembles the letter S, and the vessel is separated from the blood by the lining membrane which is reflected around it; numerous branches of the sympathetic surround the

artery. The posterior vertical, or ascending part of the artery, is crossed on its outer side by only the sixth nerve, the others being superficial to it; the horizontal portion has the third, fourth, ophthalmic division of the fifth, and the sixth, nerves nearly parallel to it, the sixth being below; and the anterior vertical, or ascending, is crossed by the same nerves, except by the sixth, which lies below the anterior turn of the artery.

The branches of this part of the artery are few, and, with the exception of the ophthalmic, there are only some small and unimportant ones in the sinus, which are named *arteriæ receptaculi;* these are distributed to the walls of the sinus and the dura mater.

Ophthalmic branch.

The *ophthalmic artery* leaves the carotid opposite the anterior clinoid process, and it enters the orbit through the optic foramen, external to the optic nerve, and rather below it. The further anatomy will be seen in the dissection of the orbit.

Seventh Nerve.

The *seventh nerve* enters the meatus auditorius internus, but the two portions of the nerve then separate, the larger, or portio mollis, is distributed to the internal ear by the foramina in the bottom of the meatus; and the smaller, or portio dura, enters the aqueduct of Fallopius which opens also into the bottom of the meatus, and it continues along this canal to the stylo-mastoid foramen, by which it escapes from the skull.

Eighth Nerve.

The *eighth nerve* leaves the skull by the foramen lacerum jugulare, and the three divisions of the nerve pass through the middle of the three compartments into which this foramen is divided by the dura mater; but the three portions of this nerve have not the same envelope of the dura mater and arachnoid, for the glosso-pharyngeal lies anterior and external to the other two, and it is separated from them by the extremity of the inferior longitudinal sinus; a distinct tube of the dura mater and of the arachnoid accompany it. The pneumo-gastric and spinal accessory are inclosed in the same tube of the dura mater, but they are separated from each other by a layer of the arachnoid.

Ninth Nerve.

The *ninth nerve* passes from the skull by the anterior condyloid foramen; the two portions into which it is divided pierce separate apertures in the dura mater, and they do not unite till they have passed from the foramen.

DISSECTION OF THE FACE.

Dissection.

The nerves and vessels in the base of the skull having been completed, proceed with the dissection of the face.* Take some of the blocks from beneath the head, so that it may hang backwards, and, as a preparatory step, place some cotton wool or tow into the nostril, as well as beneath the eyelids of the left side, and stitch them together over it; insert some in the mouth between the lips and the alveolar processes, but keep the teeth closed, that the cotton wool may not pass into the cavity of the mouth; fasten now the margins of the lips with sutures, like the eyelids. By this means, the orbicular muscles that surround the fissure between the eyelids, and the aperture of the mouth, are rendered prominent and tense, and the dissection of their fibres is facilitated. Turn the face to the right side and fasten it in this position with hooks, then make, on the left side, a vertical incision in front of the ear, from the divided integuments, above, down to the angle of the jaw, and from this point continue another along the base of the jaw to the middle line, raise the flap of integument from the side of the face towards the middle line, and, in removing it from the orbicular muscle of the eyelids, great care must be taken not to divide its thin, pale fibres, which have but a very thin cellular layer interposed between them and the skin; on the ala of the nose, the skin is closely united to a strong, fibrous tissue which is to be cut through; some fibres also of the orbicularis oris, which are attached to the integument at the angle of the mouth, are to be divided: leave the flap of skin adherent in the middle line, that it may be replaced on the dissected parts. Beneath the skin are the muscles that act on the apertures of the eye, nose, and mouth; the branches of the portio dura nerve, or motor nerve of the face; and the terminations of the three branches of the fifth, which give sensation to the parts to which the portio dura of the seventh gives motion, together with the facial vessels; all these parts are covered by cellular tissue which varies much in quantity, according to the condition of the subject. Since it is almost impossible to expose the nerves, arteries, and muscles on the same side of the face, dissect the muscles and vessels on this — the left — side, and reserve the nerves, on the other, till afterwards.† Take away the cellular membrane on the left side to expose

* If it should be wished to take next the dissection of the orbit, instead of the face, refer to the dissection of that part; but we think it is most advantageous to dissect the face before the orbit.

† The head and neck is sometimes considered two distinct parts; in such a case, the dissector will be deprived of this advantage, and he must endeavour to dissect it on one side. For the precautions to be taken in dissecting the portio dura, see the dissection of it.

the muscles, and at the same time observe the chief branches of the portio dura nerve. Near the ear is the parotid gland, covered by a strong fascia, and its duct extends forwards from it, on a level with the meatus; it is accompanied by the transverse facial artery and nerves. The facial vessels cross the face obliquely, upwards and inwards, from the base of the jaw to the angle of the eye.

Muscles of the Face.

The *muscles of the face* are often very indistinct and pale, and contain much cellular membrane in the interstices of the muscular fibres, especially in a fat subject. The superficial muscles of the face act in diminishing or enlarging the apertures of the eye, mouth, and nose. An orbicular or sphincter muscle surrounds each of the two first apertures, and other muscles which are united to it act in enlarging these apertures in different directions, so that there is a distinct set for each aperture. Some of the deeper muscles about the jaws are concerned in the movements of these parts, and they will be subsequently dissected.

Orbicularis Palpebrarum Muscle.

Origin.

The *orbicularis palpebrarum muscle* is the sphincter of the elliptical opening between the eyelids, and its fibres, which form ovals of different diameters around the aperture, give rise to a flat muscle which varies in thickness and extent in different subjects. The fibres of the muscle *arise* at the inner angle of the eye, from the internal angular process of the frontal bone, from the ascending process of the superior maxillary, and, below this, from the borders and cutaneous surface of a small white tendon, — the *tendon of the orbicularis*, which is about two lines long, and is attached, internally, to the anterior margin of the groove for the lachrymal sac, and externally by two processes to the tarsal cartilages of the eyelids; the fibres arise also below this tendon from the anterior margin of the groove for the lachrymal sac: from these numerous origins the fibres run outwards, some above, and some below the aperture between the eyelids, they form a muscle which extends from the margins of the lids to beyond the margins of the orbit, and the fibres of the upper half unite with those of the lower, at the outer angle of the orbit. The most external fibres, the thickest and strongest, are the orbital; they project beyond the margin of the orbit, and are nearly circular in their direction; the most internal, the ciliary, very pale and thin, form a small bundle along the margins of the opening close to the cilia or eyelashes, and the fibres describe ellipses; whilst the intervening fibres which occupy the eyelids, and are intermediate both in size and direction, between the outer and the inner, are named the palpebral fibres. The cutaneous surface of the muscle is covered only by the skin, and by a very fine cellular tissue interposed between it and the internal fibres; the circumference of the muscle is united above to the occipito-frontalis, corrugator

Insertion.

Relations.

supercilii, and pyramidalis nasi muscles, and below it is free. The muscle covers the margin of the orbit, and the eyelids with their ligaments and cartilages; the upper half of the muscle lies on the corrugator supercilii muscle and supra-orbital vessels and nerves; the lower half on the zygomatic muscle, the elevators of the lip, and ala of the nose, and it is also superficial to the infra-orbital vessels and nerves. At the inner angle, it lies over the lachrymal sac, and at the outer, on the temporal fascia.

Corrugator Supercilii Muscle. The *corrugator supercilii muscle* is thick and short, and it is placed beneath the orbicularis, at the inner part of the superciliary ridge. Turn down the upper half of the orbicularis, and this muscle is distinguished by the closeness of its fibres, and the dark colour of them.

Origin. The fibres *arise* from the internal part of the superciliary ridge of the frontal bone, and they pass outwards and upwards, along the margin of the orbit, to join with the occipito-frontalis and orbicularis muscles about the middle of the orbital arch.

Insertion. Relations. The orbicularis conceals this muscle; and it lies on the bone, on the frontal vessels, and supra-trochlear nerve.

Pyramidalis Nasi Muscle. The *pyramidalis nasi muscle*, situated on the nasal bone, and nearer the middle line than the orbicularis, is a small pyramidal muscle, and it appears to be a prolongation, along the nasal bone, of the anterior fibres of the occipito-frontalis, with which it is continuous.

Origin. Insertion. The fibres of the muscle end, below, in an aponeurosis which joins that of the depressor nasi muscle on the dorsum of the nose.

Relations. This muscle is subcutaneous, and it lies on the nasal bone; the outer border is united to the orbicularis, and the inner is separated by an interval from the muscle of the opposite side.

Orbicularis Oris Muscle. The *orbicularis oris muscle*, the other sphincter of the face, surrounds the large aperture of the mouth, and it consists, as that of the eyelids, of elliptical fibres which bound the opening: the fibres of the upper half do not join, directly, those of the lower at the angles of the mouth, as was the case with the sphincter in the eyelids, but they are continuous with the lower fibres of the buccinator muscle, and those of the lower half of the orbicularis join the upper of the buccinator, so that there is a crossing of the fibres of the upper and the lower lip at the angles of the mouth.

Relations. The cutaneous surface is closely united to the skin; the inner margin bounds the aperture of the mouth, and is covered by mucous membrane; the outer is united with the fibres of the different muscles which act on the opening; thus, to the upper half on each side are united the elevator and depressor of the upper lip, and the common elevator of it and the nose; to the lower half, the depressor and elevator of the lower lip; to the angle on each side the elevator and depressor of the angle, with the two zygomatic muscles and the bucci-

nator. The muscle conceals the small depressor of the upper lip and elevator of the lower, as well as the labial glands and coronary vessels which separate it from the mucous membrane of the mouth.

Levator Labii superioris Muscle.

The *levator labii superioris muscle* is flat and thin, and it extends vertically from the lower margin of the orbit to the orbicularis. Its *origin*, about one inch wide, and external to that of the common elevators, is from the margin of the orbit above the infra-orbital foramen, and it is attached to the superior maxillary and malar bones; the fibres descend to join the orbicularis oris between the middle line and the angle of the mouth. The cutaneous surface of the muscle is covered, above, by the orbicularis palpebrarum, but, below, it is subcutaneous; to its inner border is the common elevator of the lip and nose, with which it is often united; and to its outer are the zygomatic muscles and elevator of the angle. The muscle lies on the infra-orbital vessels and nerves, the compressor nasi muscle, and the filaments of the portio dura that run inwards to the side of the nose.

Origin.

Insertion.

Relations.

Levator Labii superioris Alæque Nasi Muscle.

The *levator labii superioris alæque nasi muscle*, situated nearer the nose than the proper elevator of the upper lip, is thin and pointed above, but divided below into two portions. It lies on the ascending process of the superior maxillary bone, from which it *arises* below the tendon of the orbicularis; the fibres descend to form a wide but thin muscle which gives a slip to the skin and cartilage of the ala of the nose, and it then descends to the orbicularis, with which it is united. This muscle lies between the pyramidalis nasi and proper elevator of the upper lip, but separated from the last by the angular vessels; it conceals the compressor nasi, and it is subcutaneous.

Origin.

Insertion.

Relations.

Zygomaticus major Muscle.

The *zygomaticus major* is a long, roundish muscle, directed downwards to the angle of the mouth. It *arises* from the lower part of the outer surface of the malar bone, near its junction with the zygomatic process of the temporal; the fleshy fibres descend to the angle of the mouth, and they join with those of the orbicularis and other muscles that come to this part.

Origin.

Insertion.

Zygomaticus minor.

The *zygomaticus minor muscle*, when present, is smaller than the preceding muscle. Its *origin* is from the malar bone above that of the zygomaticus major, and anterior to it; the fibres are scarcely so vertical as those of the other muscle, and they pass downwards and inwards to join either the levator labii superioris, or the orbicularis. These two muscles are subcutaneous; and the inner border of the minor is almost parallel to the elevator of the upper lip: they lie on the malar bone and buccinator muscle, and cross the facial vessels, and the nerves of the portio dura.

Origin.

Insertion.

Relations.

Levator Anguli Oris Muscle.

The *levator anguli oris muscle* lies deeply in the canine fossa; it is a flat muscle with well-marked fibres, and it is partly covered

by the elevator of the upper lip, which is to be turned aside to see it.

Origin. It *arises* from the canine fossa beneath the infra-orbital foramen, and the fibres descend to the angle of the mouth to join in the common union of the muscular fibres; but the greater number of them run over the buccinator muscle, and join the fibres of the depressor anguli oris.

Insertion.

Relations. The muscle lies beneath the levator labii superioris, but it escapes from beneath this muscle below; it is crossed by filaments of the portio dura and infra-orbital vessels, and it lies on the bone and buccinator muscle.

Buccinator Muscle. The *buccinator muscle* will be better seen by removing some granular fat that is placed in the interval beneath the coronoid process of the jaw, and conceals the posterior part of the muscle. It is a thin, flat muscle that fills the interval between

Origin. the jaws, and completes the cavity of the mouth. The muscle is attached, above, to the outer surface of the alveolar process of the superior maxillary bone, from the tuberosity of this bone to the first molar tooth, and, below, it is united to the oblique line on the inner surface of the lower jaw, as far forwards as the first molar tooth; and, in the interval between the bones, it is fixed, behind, to a fibrous or ligamentous band,—the *pterygo-maxillary ligament*, which descends from the external pterygoid plate of the sphenoid bone, to the posterior part of the internal oblique ridge of the lower jaw: this last attachment cannot be well seen in this stage of the dissection. From this extensive origin the fibres pass forwards to the angle of the mouth, and they terminate by the upper passing downwards to join the fibres of the orbicularis in the lower lip, and the lower fibres

Insertion. upwards, across the descending upper fibres, to unite with the orbicularis of the upper lip, and thus the fibres decussate at the

Relations. angle of the mouth. This muscle is covered by the zygomatic muscles, and by the muscle of Santorini, by the elevator and depressor of the angle of the mouth, and, at the posterior part, by the masseter and coronoid process; numerous vessels and nerves lie on the cutaneous surface, and passing across it, near the upper part, is the duct of the parotid, which perforates it near the second molar tooth. The mucous membrane of the mouth and buccal glands are placed on the under surface of the muscle, and the buccal branch of the fifth nerve supplies its substance. The posterior border of the muscle corresponds to part of the superior constrictor of the pharynx, since the constrictor is attached behind the pterygo-maxillary ligament, and the buccinator in front of it.

Risorius Muscle. The *risorius muscle* of Santorini * is a narrow fasciculus of fibres, sometimes divided into two or three bundles, which is closely united to the skin near the angle of the jaw, and passes

Origin. inwards to be connected to the apex of the depressor anguli oris

Insertion. muscle, with which it is *inserted* into the orbicularis.

* *Observationes Anatomicæ*, cap. i. § xxxiv.

The *depressor anguli oris muscle*, triangular in shape, is situated on the side of the lower jaw. It *arises*, by its base, from the oblique line on the outer surface of the jaw, from the masseter to near the middle line, and this attachment is united to the fibres of the platysma myoides; the fibres ascend towards the angle of the mouth, and they converge, to be *inserted* into the angle, some of the fibres joining those of the elevator of the angle. The muscle is subcutaneous, and it lies on the side of the jaw, and inferior maxillary vessels and nerve, on the buccinator and depressor of the lower lip; it is joined near its insertion by the risorius muscle.

Depressor Anguli Oris Muscle. Origin. Insertion. Relations.

The *depressor labii inferioris*, or *quadratus menti muscle*, is placed nearer the middle line than the last, and its fibres are blended with a yellow cellular tissue that obscures the muscular structure. It *arises* from the external oblique line on the jaw, and some of its fibres are continuous with those of the platysma myoides; the fibres ascend parallel to each other to join the orbicularis in the lower lip. The muscle is, in part, subcutaneous, and in part covered by the depressor of the angle of the mouth; and it lies on the bone, and branches of the mental vessels and nerve. The outer border is overlapped by the depressor anguli, and the inner joins the muscle of the opposite side.

Depressor Labii inferioris Muscle. Origin. Insertion. Relations.

Cut the stitches that are passed through the lips, and remove the cotton wool to see the two remaining small muscles which act on the lips; they are beneath the mucous membrane, and on the side of the frænum.

Dissection.

The *levator labii inferioris muscle*, situated on each side of the frænum of the lower lip, is seen by removing the mucous membrane from the inside of the lip. It is a small, thick, and conical muscle, and it *arises*, by a small tendon, from the fossa on the side of the symphysis of the lower jaw; the fibres ascend, diverging from each other, and they are *inserted* into the integuments of the chin. The muscle of each side is placed between the depressors of the lower lip; it lies on the jaw, and it is separated from its fellow by the frænum, and some cellular membrane.

Levator Labii inferioris Muscle. Origin. Insertion. Relations.

The *depressor labii superioris alæque nasi muscle* is on the side of the frænum of the upper lip, and when the mucous membrane is removed, it is seen to *arise* from the incisor or myrtiform fossa of the superior maxillary bone; the fibres radiate upwards, some joining the cartilage of the side of the nose, and others the orbicularis oris muscle: it is covered by the orbicularis, and some of its upper fibres join those of the compressor nasi muscle.

Depressor Labii superioris. Origin. Insertion. Relations.

The *compressor* or *dilator nasi muscle* is covered by the common elevator of the upper lip and wing of the nose, and it cannot be well seen till this muscle is turned aside. It is flat and triangular in shape, and it *arises* by a pointed process from the

Compressor Nasi Muscle. Origin.

inner part of the canine fossa of the upper maxillary bone; the fibres pass inwards, spreading out at the same time, and they end in an aponeurosis which covers the cartilage of the nose, to which it is attached. It is covered by the common elevator of the upper lip and wing of the nose, and it lies on the upper maxillary bone and nasal cartilage. The pyramidalis nasi muscle joins the aponeurosis in which the muscular fibres end.

Insertion.

Relations.

Facial Artery.

The *facial artery* is a branch of the external carotid, which, after a short course in the neck, appears on the side of the lower jaw, and it crosses this anterior to the masseter muscle; from this point the artery ascends in a very tortuous course, near the angle of the mouth, and along the inner part of the cheek, to the internal angle of the eye, and it ends in a small branch that joins with the angular branch of the ophthalmic. The turns of this artery are very numerous and irregular, and its course is comparatively superficial, since it lies in the mass of fat of the inner part of the cheek. It is covered, at first, by the platysma; near the angle of the mouth it is crossed by the zygomatic muscles, and below the margin of the orbit by some fibres of the levator labii superioris. The artery lies on the jaw, on the buccinator and levator anguli oris muscles, and then on the elevator of the upper lip, whose fibres separate it from the infra-orbital nerve and vessels. The facial vein accompanies the artery, but, instead of being coiled like the artery, it is nearly a straight tube, and it lies to the outer side of this vessel: branches also of the portio dura nerve cross the artery.

Branches of the Facial.

From the outer side of the artery numerous unnamed branches are given off to supply the masseter and buccinator muscles, and to anastomose with the transverse facial artery: many also supply the cellular membrane and integuments. The branches from the inner side of the artery are also many, and they are distributed to the parts in the middle line, internal to its position across the face; and they are the following: —

Inferior Labial branch.

The *inferior labial artery*, the first branch after the facial has turned over the base of the jaw, runs directly inwards beneath the depressor anguli oris, and it supplies branches to the muscles and integuments of the lower lip; it anastomoses with the one of the opposite side, and with the mental branch of the inferior dental.

Inferior Coronary branch.

The *inferior coronary artery*, given off near the angle of the mouth, sometimes as a separate trunk, and sometimes in common with the superior coronary, perforates the muscular fibres which surround the aperture of the mouth, it is then directed inwards along the lower lip, between the mucous membrane and the fibres of the orbicularis, and it ends in the middle line by joining its fellow of the opposite side; from the arterial arch formed by the union of the two inferior coronary arteries, numerous small branches are sent to supply the lips, and the labial glands which

are most numerous in the lower lip; and others anastomose with the inferior labial artery.

The *superior coronary artery* commonly arises by one trunk with the inferior, and from the bifurcation of this trunk, at the angle of the mouth, the artery runs inwards in the upper lip between the mucous membrane and the muscle; and it ends, like the lower coronary artery, by joining its fellow in the middle line: branches from the arch supply the lip, glands, and mucous membrane, and other small branches run upwards to the nose, which they supply. One long branch, the *artery of the septum*, runs along the septum of the nose to its apex; this branch anastomoses with the arteries of the nose. Superior Coronary. Artery of the Septum.

The *lateral nasal artery* arises opposite the wing of the nose, it passes inwards beneath the common elevator of the upper lip and ala of the nose, and it is distributed by numerous branches to the side of the nose; some of these anastomose with its fellow of the opposite side, as well as with the nasal of the ophthalmic, and artery of the septum. Lateral Nasal branch.

The *angular branch* of the facial, or the continuation of the artery, ascends, with the vein of the same name, between the elevator of the lip, and the common elevator of it and the nose; and it terminates by joining, beneath the last muscle, with the angular branch of the ophthalmic which lies on the side of the nose: some branches also anastomose with the infra-orbital artery. Angular branch.

The *facial vein* commences at the root of the nose by a small vein, — the angular, from the extremity of the nasal arch which receives the frontal veins. The *angular vein* receives the veins of the lower eyelid and from the side of the nose, and now become facial, it descends over the elevator of the upper lip, and, lying external to the artery, it passes away from it, beneath the zygomatic muscle, and over the buccinator and the extremity of the parotid duct; it then crosses the side of the jaw with the artery, and it opens either into the lingual, or external jugular vein. This vein receives from the alveolar plexus a large *alveolar* branch which runs beneath the malar bone, and doubles the size of the facial below this after it has joined it: the vein is joined by *coronary*, *masseteric*, *buccal*, and *labial veins*, that correspond to the branches of the arteries, and, below the base of the jaw, it is joined by the small veins that accompany the branches of the facial artery in this part. Facial Vein.

The *transverse facial artery* is a branch from the temporal in the substance of the parotid gland: it appears at the inner border of the gland, and, at the anterior edge of the masseter muscle, it divides into arteries to supply the masseter, parotid gland and integuments, and others anastomose with the facial and infra-orbital arteries. As it lies on the masseter it is sur- Transverse Facial Artery.

rounded by branches of the portio dura nerve, and it lies above the parotid duct.

Vein. The *vein* that accompanies this artery enters with it beneath the parotid, and it opens into the plexus of veins of the internal maxillary and temporal.

The remaining small branches of arteries to the face, viz., the mental, buccal, malar, nasal, and infra-orbital, correspond, in their distribution and relations, to the branches of the nerves to be examined on the opposite side; and their anatomy will be given with the trunks of which they are the terminations.

Dissection. It will be necessary, in order to expose more completely the parotid gland, to carry an incision backwards, below the ear, from the base of the jaw to the anterior border of the sterno-mastoid muscle, and to connect this with the one made for the dissection of the posterior muscle of the ear; raise the flap of skin towards the ear, or take it away. The auricularis magnus nerve is seen ascending to the lobe of the ear and to the parotid, and it divides into branches for these parts. A strong fascia that covers the gland is next to be taken from it, and its superficial relations can be examined; but its deep ones must remain till after the dissection of the portio dura through the gland.

Parotid Gland. The *parotid gland*, the largest conglomerate salivary gland, is placed between the ear and angle of the jaw; it extends more or less on the face, and it sends forwards a duct to enter the mouth by perforating the buccinator. A strong fascia, which is prolonged from that of the neck, passes over the surface of the gland, so as to bind it down, and it is connected above to the zygoma, and behind to the cartilage of the ear, but in front it is thin, and is prolonged over the face. The cutaneous surface of the gland is flat, and one or two lymphatic glands are situated on it; but the deep is very uneven, and sends off processes into the inequalities of the space in which it is contained. The shape of the gland is determined by its boundaries; it is large below where there are no resisting or osseous structures to limit it, and it projects down on the neck in the interval between the angle of the jaw and mastoid process, so as to be in close proximity to the submaxillary gland; but it is separated from it by a deep process of the cervical fascia,—the stylo-maxillary ligament. A line from the angle of the jaw to the tip of the mastoid process marks the extent downwards of the gland; but when it is enlarged, it projects beyond this, and touches the submaxillary gland. The upper part of the parotid is small, and it is bounded by the zygoma and articulation of the lower jaw, and from beneath this border issue the temporal nerves and vessels. Its extent backwards is limited by the meatus auditorius externus, by the mastoid process and sterno-mastoid muscle; and by the styloid process and

its muscles, between which it sends a deep portion. In front of the gland is the ramus of the jaw, but it is prolonged over this, and the masseter muscle, by a narrow accessory part which lies between the zygoma and the duct of the gland, and is named the *socia parotidis;* from beneath this border the different branches of the portio dura, and the transverse facial vessels escape. Connected to this border is the *excretory duct* of the parotid, or the *duct of Steno*, which crosses the masseter muscle above its centre, and opens into the mouth by perforating the buccinator muscle opposite the second molar tooth. The duct lies below the socia parotidis, it is crossed by the zygomatic muscles, and near its termination by the facial vein, the transverse facial artery lies above it, and numerous branches of the portio dura accompany it, but the greater number below it; a line drawn from the meatus to the nostril marks the position of the duct, and the centre of the line, its aperture in the mouth.

Socia Parotidis. Duct of Steno.

The *structure* of the parotid is similar to that of other conglomerate glands; it is divided into numerous lobules by processes of fascia sent into it from the strong fascia that covers it, and each lobule consists of a number of small grains connected together by ducts which issue from them to unite with others to form larger excretory ducts, and these again join the common duct. The ducts also from the socia parotidis join the common duct, which is a tube with an external thick fibrous coat, and an internal mucous lining; open the duct, pass a bristle into it, and push it on into the mouth to see its opening into this cavity. In passing through the lateral boundary of the mouth, the duct runs obliquely for an extent of two lines. The arteries to the parotid are from the external carotid; and the nerves, from the facial and the great auricular nerve.

Structure.

The *molar glands* are some small conglobate glands, situated near the upper attachment of the buccinator, and along the course of the parotid duct; some open into the duct, and the others into the mouth.

Molar Glands.

Remove from the side of the nose the pyramidalis and compressor nasi muscles; in doing this a cutaneous branch of the nasal nerve will be seen: take away the thick cellular tissue, nerves, and vessels, from the outside of the cartilage of the nose on the left side, and remove the integuments from the lower margin of the nostril of this side; the cartilages of the nose are now exposed; they are five in number, two on each side, — a lateral, and a cartilage of the aperture; and the fifth or middle one — the cartilage of the septum — will be dissected with the cavity of the nose.

Dissection.

The *lateral cartilage*, the upper, and the larger of the two cartilages of the side of the nose, is triangular in shape, and it is attached above and behind by a ligamentous or fibrous struc-

Cartilages of the Nose.

The lateral Cartilage.

ture, to the inclined borders of the nasal and superior maxillary bones, which bound the nasal aperture; internally, or in the middle line, it joins, above, the one of the opposite side, but it diverges below from its fellow, so as to leave an interval, into which projects the cartilage of the septum. The lower border, much thinner than the others, is irregular; and it is connected by fibrous membrane to the cartilage of the aperture. This cartilage is covered by the compressor nasi, and by ramifications of vessels and nerves.

Cartilage of the Aperture.

The *cartilage of the aperture* is situated below the former, and it is directed obliquely backwards and outwards from the septum which it touches in front; it is very irregular in shape, and it occupies the outer part of the nostril. In the middle line this cartilage projects below the septum, and touches its fellow; and at this point it is bent at an angle, one part of it, bounding the inner side of the aperture, is in contact with the septum, and the other extends round the outer part of the aperture, and assists, by its firmness, to keep it always open. This difference in the direction of the two parts of the cartilage has occasioned it to be divided into an outer and an inner portion.

Outer portion.

The *outer portion*, directed obliquely upwards and backwards, is narrow and pointed behind, but in front it is swollen out at its point of union with the inner, by which the prominence of the apex of the nose is formed; and it projects below the cartilage of the septum, and touches that of the opposite side. The upper border is fixed by fibrous structure to the lateral cartilage and bony margin of the aperture; and the lower is connected to the semi-cartilaginous tissue that forms the lower margin of the aperture of the nostril; the extent of this border is marked by the depressed line on the outer side of the nose immediately above the swollen rim of the aperture.

Inner portion.

The *inner portion*, situated below the proper cartilaginous septum, extends farther forwards than it, and it projects backwards, — from its point of union with the outer, — along the partition between the nostrils, to near the anterior nasal spine of the superior maxillary bone; and it ends in a prominence. This inner portion of the cartilage of the aperture assists to form the partition between the nostrils, since it projects below the proper septum, and it is connected to the lateral cartilage by a loose fibrous tissue, in which a small cartilaginous process is found near the septum.

On the side of the face which remains as yet untouched, examine the external parts connected with the organ of sight; and on the left, in which the muscles are dissected, the different structures that enter into the eyelids.

Eyebrows.

The *eyebrows*, situated above the eye and along the orbital arch, are two curved prominences formed by the orbicularis and occipito-frontalis muscles: they are covered with hairs, which are coarse, directed outwards, and longer at the inner than at

the outer part. They are separated from each other by an interval which corresponds to the root of the nose.

The *eyelids* are two moveable bodies, of a semilunar shape, situated in front of the eyeball, which they protect and partly cover; the upper is wider and more moveable than the lower, and when they are closed, it descends below the middle of the eyeball; their point of union, both externally and internally, is the commissure or canthus. The anterior surface of each is convex, and marked by transverse wrinkles when the eye is open; and the posterior, consequently concave, is lined by mucous membrane, and is applied to the prominence of the eyeball. The upper attached portion of the lid is continuous with the integument, but the lower margin, thicker than the rest of the lid, is slightly concave when the eye is opened, but straight when it is closed; the inner sixth of this border is straight, and, at the point of union of the two portions, there is a slight projection, in which is a small aperture, — the punctum lachrymale, that leads into the lachrymal canal, and is always open to receive the tears; pass a bristle into the aperture of each eyelid, and push them on through the lachrymal canals, into the lachrymal sac. The thickened part of each lid is sloped obliquely from before backwards; and, when the lids are closed, an interval is left between them and the ball, for the conveyance of the tears to the puncta lachrymalia. To the anterior edge of the free border two or more rows of long hairs — the *cilia* — are united; they are larger in the upper than in the lower eyelid, but they diminish in length from the centres to the commissures; the upper cilia are convex downwards, and the lower are convex upwards, so that they meet when the lids are closed; along the posterior edge are situated the openings of the Meibomian follicles, from which the secretion may be pressed. The cilia and Meibomian follicles are absent in the straight portion of the eyelid. Eyelids. Cilia.

The mucous membrane that lines the eyelids is named, from its office, the *tunica conjunctiva.* It lines the inner surface of the eyelids, joining at their free margins with the cutis, and it is then reflected over the ball of the eye and cornea. At the inner canthus of the eye, it forms a prominent, red, fleshy-looking body, — the *caruncula lachrymalis,* on which are placed some minute hairs, and mucous follicles that contain a yellow secretion; external to the caruncula is a small fold of the membrane, — the *plica semilunaris,* which extends for a short distance on the ball of the eye, and is analogous to the membrana nictitans of birds. As the conjunctiva lines the eyelids, it is continued down the lachrymal canals and sac into the nose. Conjunctiva. Caruncula lachrymalis. Plica semilunaris.

On the side on which the muscles of the face have been seen, the different structures of the eyelids are to be examined. The upper eyelid is the best fitted for this, and the cotton wool is Dissection.

still to remain beneath the lids to keep them stretched; each eyelid is formed by the integuments, by the orbicularis palpebrarum, by a palpebral ligament and tarsal cartilage, beneath this by a layer of mucous membrane, and in it are vessels and nerves. In the upper lid there is also, in addition, the tendon of the levator palpebræ muscle. If the eyelids are to be dissected without the face, make a circular incision through the skin, around the margin of the orbit, and throw the flaps inwards.

Structure of the Eyelids. Orbicularis.

The portion of the orbicularis that enters into the eyelid consists of its palpebral and ciliary fibres, which are very thin and pale, and they form a layer which is placed close beneath the skin, and rests on the palpebral ligament and tarsal cartilage. The vessels and nerves of the lid are also concealed by the muscle. Divide carefully the muscle around the margin of the orbit, and throw it inwards; the vessels and nerves are exposed.

Arteries of the Lids.

The *arteries of the eyelids* are derived, chiefly, from the palpebral and lachrymal branches of the ophthalmic artery. The *palpebral*, two in number, one for each eyelid, arise from the ophthalmic at the inner angle of the eye; they run outwards, along the eyelids, between the orbicularis and palpebral ligament with its tarsal cartilage, and they anastomose externally with the lachrymal; from the arch that each forms, numerous small arteries proceed to the eyelids. The *lachrymal* artery perforates the palpebral ligament of the upper eyelid near the outer canthus, and it divides into branches that supply the lids, and anastomose with the upper and lower palpebral arches. The *veins* have the same distribution as the arteries, and open into the frontal and angular veins near the root of the nose.

Veins.

Nerves of the Lids.

The *nerves of the lids* are supplied by the fifth and seventh nerves. In the upper eyelid are branches of the *lachrymal*, which pierce the palpebral ligament with the artery, and join branches of the portio dura; this nerve also sends some small filaments upwards to the integuments of the forehead. The *frontal*, or *supra-orbital* nerve sends down some filaments, about the centre of the lid; and internal to this are very small filaments from the *supra-trochlear*, which is beneath the corrugator supercilii, and from the *infra-trochlear*, which is still internal, and on the side of the nose; all these branches of the nerves, from the ophthalmic division of the fifth, supply the orbicularis, integument, and conjunctiva. These will be again seen in the dissection of the orbit, and a better dissection of them is made from the inner than from the outer side. In the lower eyelid are small filaments from the *infra-orbital* branch of the superior maxillary nerve; these turn upwards to it, after the nerve has appeared in the face.

Palpebral Ligament.

The *palpebral ligament*, best seen in the upper eyelid, is situated beneath the orbicularis, and it is a thin prolongation of

fibrous membrane from the periosteum of the margin of the orbit, which descends to join the tarsal cartilage, and to fix it in its position. The inner part of the ligament in the upper lid, as well as that in the lower, is thin and loose; but at the outer part it is much thicker and stronger, and if a portion of it, at the outer angle, be removed, some distinct fibrous bands will be seen beneath it to attach the tarsal cartilage to the outer angle of the orbit, in the same way as the tendon of the orbicularis does at the inner part.

Tarsal Cartilages.

The *tarsal cartilages* are two cartilaginous plates, one for each eyelid, which give the form of these organs, and extend to their free borders. They are fixed, internally, by the small *tendon of the orbicularis*, or *tendo oculi*, which is attached, internally, to the superior maxillary bone, in front of the lachrymal groove, and divides, after an extent of about two lines, into a process for each cartilage; the tendon crosses the lachrymal sac, and, when the whole of the fibres of the orbicularis are removed from it, it is seen to give off an expansion to cover it. At the outer angle of the orbit, the cartilages are fixed, also, by ligamentous or fibrous bands. Neither cartilage occupies the whole extent of the lid, and in each lid they differ much in shape and size. In the upper lid the cartilage is the largest; it is about half an inch wide in the centre, but it tapers to each end; it is convex before, concave behind, and marked by grooves for the Meibomian follicles; the upper border is thin, convex, and gives attachment to the palpebral ligament and tendon of the levator palpebræ muscle; the free or lower border is thick, and sloped off obliquely from before backwards. In the lower lid, the cartilage is a narrow band, about two lines broad, with borders nearly straight; it is thinner than the other, and the palpebral ligament is connected to it, as in the other eyelid. The cartilages are covered by the orbicularis externally, and by the conjunctiva internally, and they assist with the palpebral ligament to form the second layer of the lids.

Tendon of the Orbicularis.

Meibomian Follicles.

The *Meibomian follicles* will be seen when the cotton wool is removed from the eyelids, and the cartilages turned outwards; they are small yellowish-looking tubes, placed side by side beneath the tarsal cartilage which is grooved for them; about forty are found in the upper lid, but only twenty in the lower. They are placed vertically, extend from the thick to the thin margin of the cartilage, and they lie parallel to one another; those in the centre of the upper eyelid are the longest and largest. Each follicle is a straight tube, into which smaller follicles open laterally; each contains a yellow sebaceous secretion, and opens in a row along the posterior edge of the free border of the lid. A bristle may be passed into some of these.

If the palpebral ligament be cut through in the upper eyelid, the tendon of the levator palpebræ is exposed; it descends in

front of the eyeball, to join the upper part of the cartilage by a wide expansion.

Auricle of the Ear. The *auricle of the ear* is to be examined, also, on the left side; it is a cartilaginous plate, covered with integuments, and attached to the side of the head around the margin of the meatus auditorius externus of the temporal bone. The form of the auricle or external ear is irregularly oval, the larger extremity being placed upwards and backwards, the smaller downwards and forwards, and it is connected to the side of the head by its anterior and lower part. The surface next the head, or the back, is convex, but the opposite is concave, and presents many elevations and depressions that have received different names. The lower, prolonged, pendulous part of the ear, which is soft, destitute of cartilage, and connected to the side

Lobule. of the face, is the *lobule;* the hollow above the lobule, and in the centre of the auricle, which leads downwards and inwards, is

Concha. the *concha*, and the aperture in the bottom of it, the entrance to

Meatus auditorius. the *meatus auditorius.* In front of the concha is a triangular-

Tragus. shaped cartilaginous projection, — the *tragus,* which closes the entrance to the meatus when it is depressed, and it is covered, in old people, by hairs on its inner surface. On the opposite side of the concha, but rather below the level of the tragus, is

Anti-tragus. another small elevation, the *anti-tragus,* of the same shape as the tragus, but smaller than it, and it is separated from this projection by a prolongation of the cavity of the concha. The

Helix. round rim-like margin of the ear is named the *helix;* it commences by a narrow part in the concha, and extends downwards to the lobule, but the lower part of the fold or elevation is formed only by integument; the depression or groove beneath it is the *groove* of the helix. Within the helix is a large carti-

Anti-helix. laginous projection, the *anti-helix,* which is wide above, is curved backwards around the concha which it limits behind, and it ends in the projection of the anti-tragus; at its upper part it is divided into two portions or processes, with a slight depression,

Scaphoid fossa. the *scaphoid* or *navicular fossa,* between the two.

Dissection. Remove the integument from the posterior part of the auricle, to trace the nerves and vessels distributed to it. The fibres of the transverse muscle will be found at the back and upper part of the concha, in the depression that corresponds to the anti-helix of the opposite side. Take away the integument from the tragus, to see the small tragicus muscle on it, and from the base of the anti-tragus, for the anti-tragicus muscle, which is best marked. On the front of the helix, in the concha, is a very small muscle, — the small muscle of the helix; and above this, where the helix leaves the concha, is the large muscle of the helix. The muscles that move the ear in different directions have been dissected, and the three ligaments that fix the auricle to the side of the head were removed in dissecting these

muscles; they have the same attachment to the side of the head, except the anterior, which passes to the zygoma from the tragus, and front of the auricle.

Muscle of the Tragus.

The *muscle of the tragus* is placed on the cutaneous surface of the tragus; it *arises* from the lower part, and the fibres run to the upper margin: this is always present.

Muscle of the Anti-tragus.

The *muscle of the anti-tragus*, the most evident of the muscles of the ear, *arises* from the outer part of the anti-tragus; the fibres cross a fissure between the anti-tragus and the pointed extremity of the anti-helix, and they ascend to be *inserted* into the cartilaginous extremity of the anti-helix.

Small Muscle of the Helix.

The *small muscle of the helix* is placed on the commencement of the helix in the concha; it *arises* from the extremity of the helix, and is *inserted*, again, into its posterior margin above this point; it is often very indistinct, or absent.

Large Muscle of the Helix.

The *large muscle of the helix arises* from the helix above the small muscle; the fibres ascend to be *inserted* into the front of the helix, where this becomes free, and curves backwards.

Transverse Muscle.

The *transverse muscle of the auricle*, situated on the posterior part, *arises* from the convexity of the concha, and it is *inserted* into the back of the anti-helix and navicular fossa: the fibres of this are sometimes very indistinct.

Arteries of the Auricle.

The *arteries to the auricle* are derived, in front, from the temporal, but the chief are from the *posterior auricular*, which gives two branches to the ear; the upper one supplies the upper half of the posterior surface of the auricle, some of the branches turning over the helix to the other surface; and the lower is distributed to the lobule, and lower part of the cartilage, and it passes in the fissure between the extremity of the anti-helix and the anti-tragus to the other surface of the ear, on which it is distributed. The *veins* are the same as the arteries.

Veins.

Nerves to the Auricle.

The *nerves to the auricle* are, posteriorly, from the *auricularis magnus*, a branch of the cervical plexus, which sends some branches in front of the lobule, and is then distributed by many filaments to about the lower half of the posterior surface; the upper half being supplied by the *posterior auricular* of the portio dura, which often sends a branch through the cartilage to the other surface of the ear. Arnold describes, also, a small filament from the *auricular branch* of the *pneumo-gastric*, as reaching the meatus by an aperture in its posterior part; it is then distributed to the meatus and back of the auricle. In front, the auricle is supplied by branches of the *great auricular* nerve to the lower part; and by the *auriculo-temporal* branch of the third division of the fifth nerve to the upper, and to the meatus; and by some small branches of the portio dura to the integument of the tragus and meatus.

Cartilage and Ligaments

The auricle may now be removed, and the integument entirely taken off it; the *cartilaginous plate* is seen to resemble

of the Auricle. very much the external form of the ear, and to present nearly the same parts for notice; but the lobule of the ear, and the prolongation of the helix to it, are taken away, since they are only folds of integument which inclose cellular membrane, vessels, and nerves. The helix is marked in front by a projection, to which the anterior ligament is attached, and above this by a small fissure; and it terminates, behind, about the centre of the concha, by a narrow portion that joins the anti-helix. The anti-helix ends, also, at the back of the concha, by dividing into two portions; one terminates in a free tail-like process, to which is joined the helix, and the other is continued into the projection of the anti-tragus: the lobule of the ear is appended to these two processes. The cartilage of the ear is then prolonged downwards, becomes narrow, and is reflected upwards in front of the meatus, whose lower and outer part it forms by this reflection, to give rise to the tragus; it is this prolonged part which is attached to the bony margin of the meatus auditorius externus. Between the margin of this reflected portion of the cartilage and the front of the helix is a large space, filled by fibrous or ligamentous structure, which completes the upper and outer part of the cartilaginous and fibrous portion of the meatus auditorius externus. The portion of cartilage that forms the under and anterior part of the meatus is of a triangular form, and a large fissure crosses it from before backwards, and another fissure separates its outer side from the base of the tragus; these are named the *fissures of Santorini*, and they are filled by fibrous tissue. On the posterior surface of the concha is a strong vertical process of cartilage behind the commencement of the helix, which it crosses. The ligaments of the auricle are the fibrous structures found between the tragus and the helix, completing above the meatus, and between the anti-tragus and the pointed extremity of the anti-helix. The meatus and the remaining parts of the ear are included in the dissection of the ear.

Fissures of Santorini.

Dissection. On the opposite side of the face, a careful dissection is to be made of the branches of the fifth nerve, which terminate in it and impart sensation, and of the ramifications of the portio dura, which communicate motion; these unite at numerous points, but the greater number of communications are found near the middle line, in or beneath the muscles of the apertures, with the three chief branches of the three divisions of the fifth nerve, viz., with the *supra-orbital* above the eye, with the *infra-orbital* below it, and with the *mental* on the side of the lower jaw; a line drawn, vertically, on the side of the face, from the point of junction of the internal third of the margin of the orbit with the middle third, will mark the communications of these nerves. The portio dura is partly contained in the parotid gland, and partly in the face which it covers with its ramifica-

tions; and, to dissect it, raise the flap of skin from the side of the face in the same manner as it was done on the other side, and then carry backwards an incision from the angle of the jaw to the sterno-mastoid muscle, and expose the parotid gland and upper part of the sterno-mastoid muscle by removing the portion of integument that covers them. Dissect first the portion of the nerve contained in the gland; and to find it at its exit from the stylo-mastoid foramen, cut off with a chisel the tip of the mastoid process, without injuring the posterior auricular nerve which lies on it, and let the cut be directed upwards and forwards, by which the origin of the digastric muscle and the nerve it receives will be left untouched. Turn back the tip of the process with the sterno-mastoid muscle attached to it; remove cautiously the process of the parotid which projects beneath the muscle; the nerve is now seen to issue from its foramen, and to give off three small branches; — the posterior auricular which ascends in front of the mastoid process, the digastric branch to the upper part of the muscle of the same name, and a long, slender, stylo-hyoid branch downwards and forwards to the stylo-hyoid muscle. Next follow the nerve and its divisions through the substance of the gland, and find the communications of the great auricular nerve with it, as well as the branches that pass downwards from the portio dura, behind the ramus of the jaw, to join the auriculo-temporal branch of the fifth nerve, which appears behind the articulation of the jaw. In removing the parotid, the deep processes of it that dip between the different important vessels are to be noticed; and in the substance of the gland are the external carotid artery, and external jugular vein with its branches. On the side of the face the nerve divides into many branches that are continued forwards to the middle line; and the chief of these are, an ascending set over the zygoma, a middle with the parotid duct, and an inferior along the side of the lower jaw; the ascending set, when followed, will be found to unite above the zygoma and superficial to the temporal fascia, with the cutaneous temporal branches of the second division of the fifth nerve, and with the auriculo-temporal of the third division of the fifth, with the supra-orbital nerve in the orbicularis muscle, with the lachrymal in the outer part of the upper eyelid, and with the cutaneous malar which passes through the malar bone, on a level with the upper border of the zygoma, and about two lines behind the margin of the orbit; the middle set join with the buccal nerve on the buccinator muscle, with the infra-orbital nerve beneath the elevator of the upper lip, with the nasal on the side of the nose by filaments that pass both through the nasal bones as well as between the bone and cartilage, and with the infra-trochlear nerve at the inner angle of the eye; the lower set join, beneath the quadratus menti muscle, with the mental

nerve, and some branches pass below the base of the jaw to join with filaments from the ascending cervical nerve of the cervical plexus; these last will be dissected with the neck. All these communications, with the exception of those in the neck, take place with branches of either the first, second, or third divisions of the fifth or trifacial nerve.

Portio dura Nerve.

The *portio dura nerve*, or motor portion of the seventh, has been seen to enter the meatus auditorius internus with the portio mollis; it then passes into the aqueduct of Fallopius, which conducts it to the stylo-mastoid foramen, by which it escapes from its canal in the petrous portion of the temporal bone, and it enters the parotid gland. Immediately after its exit, the nerve gives off the three following small branches: the posterior auricular, digastric, and stylo-hyoid nerves.

Posterior Auricular branch.

The *posterior auricular nerve* is a small branch that leaves the front of the portio dura close to the stylo-mastoid foramen; it turns upwards and forwards round the anterior surface of the mastoid process, and it is joined by the great auricular nerve of the cervical plexus, and, according to Arnold, by a filament from the auricular branch of the pneumo-gastric, which lies in the petrous portion of the temporal bone. The nerve then becomes superficial, is accompanied by the artery of the same name, and it divides into its two branches, the one being distributed to the ear, and the other to the occipito-frontalis muscle: the distribution of these has been dissected.

Digastric branch.

The *digastric nerve*, the largest of the three branches of the portio dura, is very short, and it sometimes arises by a trunk common to it and the stylo-hyoid branch; it passes backwards and is distributed by many filaments to the under surface of the posterior belly of the digastric, near its attachment to the skull; one of the filaments, larger than the rest, perforates the digastric muscle, and is directed downwards and inwards, to the base of the skull, to join the glosso-pharyngeal nerve soon after it has passed from the cranial cavity.

Stylo-hyoid branch.

The *stylo-hyoid* branch, the longest and most slender, runs downwards and forwards in the direction of the styloid process, but behind it; it then crosses beneath the posterior auricular artery, comes into relation with the styloid process near its tip, and runs along the upper border of the stylo-hyoid muscle, to the centre of which it is distributed. This nerve is joined by the sympathetic which accompanies the external carotid artery.

After the nerve has given off these branches, it turns forwards through the substance of the gland, below the meatus auditorius externus, and it crosses over the posterior auricular artery and styloid process, the external jugular vein and external carotid artery, and before it reaches the ramus of the jaw it divides into two large branches, the temporo-facial, and cervico-facial, which diverge from each other.

Temporo-

The *temporo-facial division*, the larger of the two, ascends in

front of the meatus, and over the articulation of the lower jaw, and the zygoma, to the side of the head and face; on the masseter muscle and the zygoma it forms a network of branches whose ramifications extend as low as to a line with the meatus, and from this are given off the temporal, malar, and buccal sets of branches. As the nerve ascends in front of the meatus it gives some small filaments to it and to the integument of the tragus, and, on the external carotid, it sends branches backwards to join the auriculo-temporal branch of the third division of the fifth nerve. The *temporal* set of branches ascend over the zygoma, are distributed to the lateral and frontal regions of the head, and they join with the auriculo-temporal nerve, with the cutaneous filaments of the second division of the fifth, also, towards the top of the head, with the ascending filaments of the supra-orbital nerve. The *malar nerves* cross the malar bone as they extend forwards to the outer part of the orbicularis palpebrarum, and, at the outer angle of the orbit, the greater number of the branches enter the orbicularis; some supply this muscle, and join, above the orbit, with the supra-orbital nerve; others enter the structures of each eyelid, and communicate in the upper one with the lachrymal and supra-orbital branches, and in the lower with the infra-orbital filaments. One or two small branches of this set join with the cutaneous malar branch from the second division of the fifth nerve. The *buccal* or *infra-orbital* branches, three or four in number, and the largest in size, accompany the parotid duct, but usually below it, and they continue forwards to the middle line, to supply the muscles that are found between the orbit and mouth, and to communicate with the different branches of the fifth nerve. The most remarkable communication in the face takes place between branches of this set that pass beneath the elevator of the upper lip, and the radiation of the branches of the infra-orbital nerve of the superior maxillary of the fifth; this union is placed beneath the elevator of the lip, and the branches of the portio dura rather cross the large descending branches of the infra-orbital, than unite intimately with them. A very long branch of this set continues upwards, beneath the common elevator of the lip and nose, to the inner angle of the eye, and it terminates by supplying the muscles, and joining the infra-trochlear nerve of the nasal branch of the fifth. Other small nerves pass inwards to the wing of the nose, and join the cutaneous filaments of the nasal nerve, which escape both through apertures in the nasal bones and between the bone and the cartilage. Some branches of this set pass downwards to the angle of the mouth to supply the orbicularis oris muscle; others join branches of the cervico-facial division, and assist to form the network of branches that covers the whole side of the face from above the zygoma to below the jaw.

facial division.

Temporal Nerves.

Malar Nerves.

Infra-orbital Nerves.

Cervico-facial division.

The *cervico-facial division* of the portio dura, smaller than the preceding, runs downwards through the substance of the parotid towards the angle of the jaw, and it divides into supra- and infra-maxillary sets of branches. Before the nerve divides at the angle of the jaw it gives some small filaments to the parotid gland, and these join with the filaments of the great auricular nerve that perforate the substance of the gland. Some few branches also pass forwards on the side of the face; some of these ascend to join with descending branches of the temporo-facial division, others run over the masseter to join the buccal branch of the fifth nerve on the buccinator muscle, and a few reach the commissure of the lips. The *supra-maxillary* set of nerves run forwards above the base of the jaw, and beneath the depressor of the angle of the mouth and platysma; they supply the muscles of the lower part of the face, and join with the mental branch of the third division of the fifth after it has escaped from the mental foramen. The junction of these branches with the mental is very similar to that of the infra-orbital and portio dura; the branches of the seventh cross those of the fifth which are directed upwards to the lower lip, they have but few communications with them, and the branches of the seventh, after crossing the fifth, may be traced through the quadratus menti muscle to the middle line; and their termination is in the muscles of the lower lip and external surface of the jaw.

Supra-maxillary Nerves.

Infra-maxillary Nerves.

The *infra-maxillary*, the lowest set of branches of the portio dura, are placed below the jaw, and beneath the platysma myoides muscle; they are distributed to the upper and lateral part of the neck and platysma, and they join with branches of the ascending cervical nerve of the cervical plexus. Some branches turn upwards over the jaw to join with the supra-maxillary branches: these nerves will be dissected with the neck.

Branches of the Fifth Nerve.

The chief branches of the fifth, now dissected, are the supra-orbital, infra-orbital, and mental, — the terminal portions of the three divisions of the fifth nerve; the auriculo-temporal, buccal, and nasal may be also examined in this dissection, but the remaining small branches of the supra- and infra-trochlear, and malar nerves will be seen with the special anatomy of the nerves of which they are but the cutaneous terminations.

Supra orbital Nerve.

Palpebral Filaments.

Frontal.

The *supra-orbital nerve*, the termination of the ophthalmic or upper division of the fifth, escapes from the orbit by the supra-orbital notch; it sends downwards *palpebral* filaments to the upper eyelid, and upwards *frontal* branches, which have been dissected; other branches turn outwards in the orbicularis muscle to join with the ascending temporal branches of the portio dura. This junction is not so well marked as in some of the other instances of communications between the fifth and the seventh, and it is only in subjects in which the nerves are well

developed that it can be traced. The supra- and infra-trochlear branches, from the same division of the fifth, lie nearer the nose, the supra-trochlear being the larger, and beneath the corrugator supercilii muscle.

Infra-orbital Nerve.

The *infra-orbital nerve*, the cutaneous termination of the superior maxillary or second division of the fifth, appears beneath the elevator of the upper lip, and it divides directly into ascending and descending branches. The descending, the most numerous, radiate from the infra-orbital foramen to the side of the nose and the upper lip. These descend vertically beneath the branches of the portio dura that cross them at right angles, and are united to them by filaments, and they are distributed to the mucous membrane and muscles of the upper lip, and to the integument of it and the side of the nose. The ascending or *palpebral* filaments turn up beneath the orbicularis to the lower eyelid and its conjunctiva, and some are distributed also to the integument of the dorsum of the nose.

Palpebral Filaments.

Mental Nerve.

The *mental branch* of the inferior maxillary, or third division of the fifth, is concealed, after its exit from the mental foramen, by the quadratus menti muscle. The nerve divides into branches which are directed upwards beneath those of the seventh, almost at right angles, and they are distributed to the mucous membrane, muscular structure, and integument of the lower lip. The greater number of the branches are supplied to the mucous membrane of the margin of the lip, and the nerve will be readily exposed, within the mouth, by taking up the mucous membrane.

Superficial Temporal Nerve.

The *superficial temporal branch* of the auriculo-temporal nerve of the inferior maxillary, or third division of the fifth, appears from beneath the articulation of the lower jaw, it then ascends in front of the meatus, and is distributed, as before seen, to the side of the head; the junction of this nerve with the portio dura takes place both on the side of the head above the temporal fascia, and deeply behind the condyle of the jaw. This nerve supplies branches also to the upper part of the auricle of the ear.

Buccal Nerve.

The *buccal nerve*, a branch of the inferior maxillary, or third division of the fifth, appears on the side of the face, passing from beneath the coronoid process and temporal muscle; the nerve then runs downwards along the lower part of the buccinator muscle, joins with filaments of the portio dura on the buccinator, so as sometimes to form a plexus, and it divides into many branches, which continue forwards in the course of the nerve; some of these are distributed to the integument near the angle of the mouth, while other branches pass beneath the depressor anguli muscle, and are distributed to the mucous membrane; some of the branches supply the buccinator and depressor anguli oris muscles.

Nasal Nerve.

The *nasal nerve*, a small branch of the first division of the fifth, leaves the cavity of the nose by passing between the nasal bone and cartilage; it is at first covered by the compressor nasi, and it divides into branches which descend to supply the integument of the ala and tip of the nose, with branches of the infra-orbital. Some of the filaments of the nerve come through the nasal bones, and the nerve joins with the portio dura on the side of the nose.

Deep relations of the Parotid Gland.

The *deep relations of the parotid gland*, and the vessels and nerves that pass through it, can now be observed. The trunk of the portio dura nerve crosses, from behind forwards, through the substance of the gland, and it divides into its great branches in the middle of it. Beneath the nerve, and parallel to the ramus of the jaw, is the external carotid, which ascends, in the gland, as high nearly as to the condyle of the jaw, and it then divides into the temporal and internal maxillary arteries, the former leaves the upper border of the parotid, and the latter winds behind the jaw. Accompanying the artery, but superficial to it, is the plexus of veins of the temporal and internal maxillary, in which the external jugular vein commences; and a vein passes deeply through the substance of the gland to connect together the external and internal jugular veins. The superficial temporal branch of the fifth nerve passes through the upper part of the gland, the posterior auricular artery ascends through it to its posterior part, and the transverse facial artery escapes from its front. The deep interval between the ramus of the jaw and stylo-maxillary ligament, and the mastoid process with the sterno-mastoid muscle, is divided into two parts by the styloid process. The interval behind the process is occupied by a portion of the gland which projects beneath the mastoid process and sterno-mastoid muscle, and extends downwards so as to be in contact with the internal jugular vein, and the eighth and ninth nerves that accompany it. Another large portion of the parotid is situated in the space in front of the styloid process, and it projects behind the articulation of the jaw into the posterior part of the glenoid cavity; it is also prolonged behind the ramus of the jaw with the internal maxillary artery, and when this portion is enlarged, it occupies the interval between the two pterygoid muscles beneath the ramus of the jaw: this same portion of the gland in front of the styloid process passes directly downwards, and comes into contact with the internal carotid artery which is beneath. A careful examination of the processes of the gland sent into the hollows in the bottom of the space in which it lies, and of the number of important vessels that either pass through the gland or are in close contact with it, must convince the dissector of the impracticability of removing it, and also of the dangers attending any operations on this part.

DISSECTION OF THE ORBIT.

Now the dissection of the face is completed, place some strips of calico dipped in a solution of bichloride of mercury on the side on which the nerves were dissected, and fasten the skin over it. Return to the examination of the orbit, and the anatomy of the nerves before dissected by the side of the body of the sphenoid bone; place the head in the same position as for the sinuses in the base of the skull, and remove the roof of the orbit. To accomplish this, make two vertical cuts with a saw through the margin of the orbit, the inner passing rather to the outer side of the internal angular process of the frontal bone, to avoid the pulley attached to this point; and the outer somewhat within the external angular process, that the lachrymal gland, its vessels and nerve, may not be injured. Extend these cuts backwards along the roof of the orbit, by means of a chisel, to a quarter of an inch in front of the optic foramen and a little external to it, or to a slight projection of bone, and then raise and turn forwards the portion of bone included by these incisions. A portion of the roof of the orbit still remains; this is to be cut through with the bone forceps, about two lines external to the optic foramen, and the piece of bone, which is the small wing of the sphenoid, and therefore unattached at the outer extremity, is to be removed. As the vertical portion of bone on the outer side impedes the dissection, remove it by a cut with the saw directed obliquely downwards and inwards, so as not to take away more of the outer wall of the cavity.* Any small impending portion of the roof, on either side, that interferes with the easy dissection, may be removed with the bone forceps, but the small nasal nerve must be avoided on the inner side. The portion of bone forming the roof and margin of the orbit, which is now raised, is not to be cut away. In the orbit are contained the eyeball, and a considerable quantity of a granular fat which fills the space not occupied by the eye. There are four recti muscles, one above, one below, and one on each side of the ball; two oblique, a superior and inferior, with reference to the globe of the eye; and one elevator muscle of the upper eyelid. The nerves are the second, third, fourth, ophthalmic division of the fifth, orbital branch of the superior maxillary division of the fifth, and the sixth. The second is distributed to the eyeball, the third supplies all the muscles of the

Dissection.

* The dissector is sometimes desirous to take away the whole outer wall of the orbit, and part of the middle fossa of the skull, in this stage of the dissection, to obtain a view of the first and second divisions of the fifth; but we cannot recommend this proceeding unless it be wished to dissect *only* these two branches of the nerves.

orbit except two, the fourth supplies one of those two, — the superior oblique muscle, and the sixth, the remaining muscle, — the external rectus: the branches of the fifth only pass through the cavity to be distributed external to it; numerous branches of the ophthalmic vessels are contained, also, in the orbit. All these parts are surrounded by a strong periosteum which is to be first seen.

Periosteum of the Orbit.

The *periosteum of the orbit*, now exposed, is a fibrous membrane prolonged into the cavity from the dura mater, through the sphenoidal fissure; it lines the interior of the orbit adhering but loosely to the bone, and at the anterior margin it joins with the external periosteum, and is prolonged to the tarsal cartilage as the palpebral ligament. This membrane incases the contents of the orbit, like a bag; but it is perforated behind by the optic nerve, and a large aperture exists in it for the nerves that enter through the sphenoidal fissure; on the sides are some smaller apertures for the vessels and nerves that pass from this cavity through the orbital foramina: some of the nerves appear through the membrane.

Dissection.

Divide the periosteum by an incision from front to back, and remove it from each side; the following is the arrangement of the muscles, vessels, and nerves close beneath it. In the middle line is the large frontal nerve of the ophthalmic division of the fifth (for this nerve divides at the sphenoidal fissure into frontal, lachrymal, and nasal), with its accompanying vessels; external to this, and also above the muscles, is the lachrymal nerve with its vessels, and to the inner side, and at the back of the orbit, is the small fourth nerve; these three nerves enter the orbit above the muscles, but all the other nerves that enter this cavity through the sphenoidal fissure pass between the two heads of the external rectus muscle. The muscle beneath the fourth nerve is the superior oblique, beneath the frontal are the levator palpebræ and superior rectus, and below the lachrymal nerve is the external rectus muscle. The lachrymal gland is situated in the outer angle of the orbit, near to its margin, and superficial to its contents; it is perforated by the lachrymal nerve and vessels. Remove some of the fat from the intervals between the muscles, and use the knife with great caution, particularly in the interval between the external and superior rectus muscles, since the small lenticular filaments are found in it, near to the optic nerve. Some small descending filaments from the lachrymal near the gland, and also a small occasional nerve, from the frontal, in the interval between the superior rectus and superior oblique muscles, are to be avoided. It is not necessary to remove all the fat before examining some of the nerves and muscles. Follow back the fourth nerve through the fibrous sheath that surrounds it as it enters the orbit; do the same with the frontal and lachrymal nerves to their point of

origin from the ophthalmic division of the fifth; it is easy to follow the frontal, but it requires great care to succeed in dissecting the small lachrymal nerve, through its sheath of fibrous membrane, back to its origin. If the projecting clinoid process has not been removed, it should now be done, to see the relative position of the nerves, as they pass through the sphenoidal fissure.

Lachrymal Gland.

The *lachrymal gland*, for the secretion of the tears, is a conglomerate gland, situated within the external angular process of the frontal bone, which is hollowed to receive it, and it is superficial to the other contents of the orbit. It is of a lengthened form, convex externally, flat below, like an almond; and, from its front, a portion projects forwards to touch the upper eyelid: the upper surface, in contact with the periosteum, is connected to it by numerous fibrous processes; the lower, surrounded by fat, rests on the external rectus muscle and the eyeball; and through the substance of the gland pass the lachrymal vessels and nerve. The *structure* of the gland resembles other conglomerate glands; it consists of numerous small granules connected together by cellular membrane and efferent ducts: the *ducts* unite to form larger tubes which open on the conjunctiva of the upper eyelid, a little above the outer part of the tarsal cartilage, by ten or twelve very small apertures. Follow the lachrymal vessels and nerve through the substance of the gland to the upper eyelid, and trace the small descending branches of the lachrymal nerve.

Structure.

Ducts.

Fourth Nerve.

The *fourth nerve* enters the orbit by the inner part of the sphenoidal fissure; as it passes through, it is situated above the other nerves that enter by the same aperture, and it is internal to them, since it crosses over the frontal nerve to reach its inner side; but in the wall of the cavernous sinus it was found below the third, and external to it and the sixth. Immediately after it has entered the orbit, it quits the frontal nerve, passes inwards and forwards over the levator palpebræ and superior rectus muscles, near to their posterior attachment, to reach the superior oblique muscle, to which it is distributed by numerous filaments which enter its orbital surface, contrary to the general arrangement of the distribution of the nerves of the orbit to the ocular surfaces of the muscles.

Frontal Nerve.

The *frontal nerve*, a branch of the ophthalmic or orbital division of the fifth, enters the orbit close to the outer side of the fourth and above the muscles, it is rather below the level of the fourth, but above that of the lachrymal nerve which is external to it. The nerve continues forwards over the levator palpebræ and superior rectus muscles, and in the front of the orbit it inclines to their inner side and divides into its two terminal branches, the supra-trochlear and supra-orbital. In this course the nerve lies close beneath the periosteum, and it

is accompanied by the supra-orbital vessels: the point of division of the nerve is very variable; at one time it takes place as soon as it has entered the cavity, and at another near to the margin of the orbit. The *supra-trochlear* nerve, the smallest of the two branches into which the frontal divides, passes obliquely inwards to near the pulley of the superior oblique muscle, and it then leaves the orbit by turning round the superciliary ridge of the frontal bone. The nerve is seen, externally, to ascend between the frontal bone and corrugator supercilii, and it gives off numerous branches, some of which — the *palbebral* — descend to the conjunctiva and orbicularis of the upper eyelid, and others supply the corrugator supercilii and orbicularis muscles; but the greater number of its branches ascend on the forehead, and become cutaneous. Before the nerve leaves the orbit it sends down a branch to join, below the pulley of the oblique muscle, with the infra-trochlear branch of the nasal nerve; and, as it turns round the margin of the orbit, beneath the frontal sinus, it gives a small filament through the bone to the sinus. It is not uncommon to see the branch to join the infra-trochlear given off from the frontal at the back of the orbit; and, in such a case, the nerve passes forwards in the interval between the superior rectus and superior oblique muscles, to join the infra-trochlear nerve at the inner part of the orbit. The *supra-orbital* nerve, the other branch of the frontal, leaves the orbit by passing through the notch or foramen in the superciliary ridge; and beneath the corrugator supercilii and orbicularis it divides into the two branches which were dissected with the cutaneous nerves of the head. Where the nerve leaves the orbit it sends down some small filaments — the *palpebral* branches — to the upper eyelid, and other branches pass transversely outwards in the orbicularis, which they supply, and they join with the portio dura. A filament sometimes enters a canal in the frontal bone, and becomes cutaneous higher up on the head.

Supra-trochlear branch.

Palpebral Filaments.

Supra-orbital branch.

Palpebral Filaments.

The *lachrymal nerve*, a branch of the ophthalmic, is smaller than the frontal, and it enters the orbit above the muscles, but to the outer side of the frontal and a little lower than it; as it passes through the sphenoidal fissure it is enveloped by a distinct and strong process of the dura mater. In the orbit the nerve runs forwards along its outer part, above the external rectus muscle, and close beneath the periosteum, to the lachrymal gland, through which it passes, and to which it gives filaments; it then leaves the gland, perforates the fibrous membrane of the upper eyelid, and it divides into *palpebral* branches, which communicate in the lid with the portio dura, and one filament turns upwards on the forehead to end in the integument. Near the lachrymal gland, the nerve sends downwards one or two filaments to join with the orbital branch of the superior maxillary nerve, or second division of the fifth. The

Lachrymal Nerve.

Palpebral Filaments.

Communicating, to the Superior Maxillary.

lachrymal, like the frontal, is sometimes divided at the back of the orbit into two branches. This nerve is formed, occasionally, by a branch from the fourth, and by another from the ophthalmic nerve.

Dissection. Divide the frontal nerve about its middle, and throw forwards and backwards the ends; raise its posterior part from the muscles beneath it, and the nasal nerve is seen to arise from the inner side of the ophthalmic, behind the origin of the frontal and lachrymal, and it enters the orbit much lower down. The superficial muscles are now exposed.

Levator Palpebræ Muscle. Origin. Insertion. Relations. The *levator palpebræ* muscle is the most superficial of those in the orbit; it is thin and flat, and it *arises* by a narrow pointed portion from the roof of the orbit, close in front of the optic foramen. The muscle widens as it extends forwards to the margin of the orbit; and, at this point, it makes a sudden turn downwards and forwards, in front of the eyeball, to be *inserted*, by a wide and thin tendon, into the upper part of the tarsal cartilage. This muscle lies beneath the periosteum, it is crossed by the fourth and frontal nerves, and the anterior reflected portion lies between the orbicularis and eyeball, but it is separated from the former by the palpebral ligament. It lies on the superior rectus and globe of the eye. Cut it across in front of its centre, and turn it aside, a small nerve enters it.

Rectus Superior Muscle. Origin. Insertion. Relations. The *rectus superior muscle*, one of the four muscles which lie around the globe of the eye, and are named from their relative position to it, *arises* by a common origin with the other muscles, from the process of dura mater that surrounds the optic nerve, as well as from the outer and upper part of the optic foramen; the fibres form a flat muscle, which is continued forwards to near the front of the eye, and ends in a tendon which is *inserted* into the sclerotic coat a little behind its union with the cornea, a small synovial bursa intervening between the two. From the margins of the tendon an aponeurotic expansion is given off, and it joins a similar process from the tendons of the other recti muscles to form a partial covering for the globe of the eye; this is sometimes named the *tunica albuginea*. The upper surface of the muscle is covered by the levator palpebræ and frontal nerve, the lower rests on the nasal and optic nerves, and ophthalmic artery, as well as on the globe of the eye.

Superior Oblique Muscle. Origin. The *superior oblique muscle* is thin and narrow, and it is the longest of any in the orbit. Its course is peculiar, since its direction is changed at the anterior part of the orbit by a pulley through which it passes; so that the line of action of the muscle does not correspond to that of the fibres. The muscle is situated at the inner part of the orbit, and it *arises*, behind, from the sheath of the optic nerve, and from the inner part of the optic foramen; the fleshy fibres proceed forwards to the tendon which enters, at the inner angle of the orbit, a

cartilaginous pulley by which its direction is altered; and it then passes downwards and backwards between the superior rectus and globe of the eye, to be attached to the sclerotic coat, by a wide thin aponeurosis, behind the anterior half of the eyeball, and between the superior, and the external rectus muscle. The muscle is in contact with the periosteum by its orbital surface, and with the nasal nerve and ophthalmic artery by the ocular; the fourth nerve enters the orbital surface about its centre. The tendon is attached to the sclerotic behind the insertion of the recti, and very near the tendon of the inferior oblique, with which it seems to be sometimes united. The *pulley* or *trochlea* through which the tendon of the superior oblique muscle plays, is a fibro-cartilaginous ring attached to the depression in the frontal bone at the inner angle of the orbit; a fibrous prolongation from the margin of the ring surrounds the tendon, and obscures the sight of its motion; but this is to be removed, and a synovial membrane that lines the pulley will be brought into view.

Insertion.

Relations.

Trochlea or Pulley.

Dissection.

Cut across the superior rectus in front of its centre, and turn it backwards with the levator palpebræ, the upper division of the third nerve is observed to supply these muscles. The nasal nerve is also exposed as it crosses the optic; it gives some small ciliary filaments to this nerve: follow it to the inner part of the orbit; the ophthalmic artery and vein run inwards with the nasal nerve: remove more of the cellular membrane from between the external rectus and optic nerve, with the same caution as before, and seek the lenticular ganglion in the space between the nerve and muscle at the back of the orbit; it is closely connected to cellular tissue, is about the size of a pin's head, and it is usually on the outer side of the ophthalmic artery. If the nerves that pass from it along the optic nerve be followed backwards, the ganglion will be readily found. A small nerve from the nasal to the back of the ganglion, and a large but short branch from this to the third, should be also dissected. Separate from each other the nasal of the ophthalmic, the third, and the sixth nerves, as they enter the orbit between the two heads of the external rectus muscle.

Third Nerve.

The *third nerve* was seen to be the highest of all the nerves in the wall of the cavernous sinus, opposite the body of the sphenoid bone; but as it approached the sphenoidal fissure, it descended internally to the other nerves, and below those that enter the orbit above the muscles,—namely, the fourth, and frontal and lachrymal branches of the ophthalmic. The nerve is now found at the sphenoidal fissure, in close contact with the nasal of the ophthalmic, and the sixth nerve, and it passes through the fissure into the orbit between the two heads of the external rectus muscle; but, before it enters, it divides into a small and a large portion, between which is placed the nasal

nerve. The small portion or *upper division* of the third nerve enters with the others between the heads of the external rectus, and above the nasal nerve; it turns directly upwards to the under surface of the superior rectus muscle, and it divides into many branches, the greater number being given to the ocular surface of this muscle; but some long and small filaments pass from beneath its inner border to the under surface of the levator palpebræ, which they supply. The lower division of the nerve is not dissected now, but its anatomy will be examined in another stage of the dissection. Upper division.

The *nasal nerve*, the only remaining branch of the ophthalmic division of the fifth, arises from the inner side of the ophthalmic, behind the sphenoidal fissure; it enters the orbit with the third and sixth nerves, between the two heads of the external rectus, and it lies in the interval between the two divisions of the third nerve. It now ascends over the optic nerve, and beneath the superior rectus and levator palpebræ muscles, and it is directed forwards and inwards along the inner side of the orbit, below the level of the superior oblique muscle, to the anterior of the two foramina in the inner wall of the orbit, at which point it divides into the infra-trochlear and nasal branches. Whilst the nerve is passing between the two heads of the rectus, or even before, it gives off a long slender branch, half an inch or more in length, which runs forwards to the lenticular ganglion, this is sometimes bifurcated at the ganglion; and, as it crosses the optic, it sends along it two or three small branches,—the *ciliary* nerves, which run on the inner side of the nerve, those from the lenticular ganglion being on the outer, and they perforate the sclerotic coat of the eye to be distributed to this organ. Their anatomy will be seen with the dissection of the eye. Nasal Nerve. Nerve to the lenticular Ganglion. Ciliary Nerves.

The *infra-trochlear nerve*, the smallest branch of bifurcation of the nasal, passes forwards, from its point of origin, along the inner wall of the orbit, beneath the tendon and pulley of the superior oblique muscle, and it leaves the cavity below the level of the supra-trochlear, and nearer the nose. It divides, finally, into many small branches to supply the side of the nose and lachrymal sac; and other branches — the *palpebral* — are distributed to the upper eyelid, and join the branches of the supra-trochlear of the frontal. Before this nerve leaves the cavity of the orbit, it is joined by a small communicating branch sent down from the supra-trochlear nerve. The connection between this nerve and the portio dura on the side of the nose has been dissected, and it is only necessary to follow the nerve onwards to it. Infra-trochlear branch. Palpebral Filaments.

The *nasal branch*, the continuation of the nerve, leaves the orbit by the anterior of the two orbital foramina in the inner wall, together with a small artery; it runs through a canal between the articulating surfaces of the frontal and ethmoid bones, and it appears, in the cranium, at the outer border of the ethmoid Nasal branch.

bone, in a groove which conducts it to an aperture in front of the ethmoid, and external to the other foramina in the cribriform plate of this bone; it passes from the cavity of the skull to the nose, through this aperture, and it will be seen in the skull by removing the dura mater which covers it, though, in some subjects, the border of the frontal bone projects over it, so as almost to conceal it. When the nerve has entered the nose, it gives off some small branches on the septum and spongy bones, and it continues downwards and forwards in a groove behind the nasal bone of its own side, as far as to the union of it with the nasal cartilage, it then becomes cutaneous in the face, and communicates with the portio dura: one or two small branches come through the nasal bone, but the nerve does not give any branches to the nose, as it lies above the cribriform plate.

Ophthalmic or lenticular Ganglion.

The *ophthalmic* or *lenticular ganglion*, a small roundish-shaped body, is redder in colour in one subject than in another; it is placed at the back of the orbit, in the interval between the external rectus and optic nerve, near to the posterior attachments of the recti muscles, and it is commonly situated on the outer side of the ophthalmic artery which separates it from the optic nerve. From the disposition of its different nerves, it is said to be square-shaped, and to have four angles, each designated by a particular name. The ganglion is connected behind, by its posterior superior angle, to the nasal as it enters the orbit, by a long, slender branch, and, by its posterior inferior angle, to the branch of the lower division of the third nerve, which goes to the inferior oblique muscle; this connecting nerve is short and thick, sometimes almost as wide as the ganglion, but occasionally it is lengthened and smaller. The posterior part of the ganglion is connected also, sometimes, by a distinct filament to the cavernous ganglion, but this is more commonly absent, or it unites outside the orbit with the nasal of the ophthalmic.

Ciliary Nerves.

From the front of the ganglion two bundles of *ciliary nerves* pass around the optic to the eye; the upper, smallest in size, from the anterior superior angle, consists of about four filaments, and the lower, from the anterior inferior angle, is formed by about six: they pass round the optic nerve to the sclerotic, which they perforate near the entrance of the optic, and they are distributed to the ciliary ligament and iris. The ciliary nerves from the ganglion are placed on the outer and under surface of the optic nerve, and they join with the ciliary, from the nasal, which lie on its inner part: numerous small tortuous ciliary arteries accompany these nerves, and they have nearly the same distribution in the ball of the eye.

Optic Nerve.

The *optic nerve*, in the orbit, extends forwards from the optic foramen to the lower and inner part of the eye, which it enters, to terminate in the retina. It is invested by a tube of dura

mater which gives attachment to the recti muscles, but a considerable quantity of fat afterwards separates it from these muscles. The optic is crossed, above, by the nasal nerve and ophthalmic vessels, and below, by the branch of the lower division of the third nerve, which goes to the internal rectus; it is surrounded by the numerous ciliary arteries and nerves, till it perforates the sclerotic coat of the eye.

Ophthalmic Artery.

The *ophthalmic artery* is a branch of the internal carotid in the skull, and it arises close to the anterior clinoid process; it then passes into the orbit through the optic foramen with the optic nerve, but external and inferior to it. In the first part of its course in the orbit, it lies external to the optic nerve; it then ascends and crosses over to its inner side, and finally, the artery runs with the nasal nerve to the inner angle of the orbit, and it here divides into its terminal branches. The branches of this artery are very numerous, and are divided into those given off external to the nerve, those above, and those internal to it; the latter are the most numerous.

Branches.

External to the Optic.

Lachrymal branch.

The *lachrymal artery*, the first branch of the ophthalmic, is a considerable trunk; it is deep at first, between the external and superior rectus muscles, but it soon becomes superficial, and, placed beneath the periosteum, but above the external rectus muscle, it runs forwards with the nerve of the same name to the lachrymal gland which it perforates, and to which it gives many small branches. After the artery has left the gland it perforates the ligament of the upper eyelid, and it ends by anastomosing with the palpebral arches, as already seen; it gives some branches also to the conjunctiva. In the orbit, it gives a small *malar branch*, through the malar bone, to the temporal fossa to anastomose with the deep temporal arteries; and it is joined, behind, by a small branch, from the middle meningeal artery, which enters by one of the foramina in the back of the orbit.

Malar branch.

Branch to the Retina.

The *central artery of the retina* is a very small branch; it perforates the sheath of the optic nerve near the foramen; it runs in the centre of the nerve to the interior of the eye, and it ends in a vascular membrane that lines the inner surface of the retina.

Above the Optic. Supra-orbital branch.

The *supra-orbital branch* leaves the trunk whilst it is covered by the levator palpebræ and superior rectus muscles, it then emerges from beneath their inner border, accompanies the supra-orbital nerve through the notch of the same name, and it ends in two branches which ascend on the forehead, and supply the muscles and integuments; and some also go to the eyelid, and join with the palpebral. This artery gives filaments to the two muscles by which it is covered, and a small artery to the frontal bone as it passes beneath it.

Ciliary branches.

The *ciliary branches* are derived from many sources, and are

arranged into two sets, anterior and posterior, the latter including long and short branches. The *anterior ciliary* are supplied by small arteries in the front of the orbit; they are not usually seen in a dissection, but when they are minutely injected, or are distended, as in inflammation of the iris, they are seen to form a vascular circle around the front of the ball. These perforate the sclerotic about two lines behind the cornea, and they end by anastomosing, around the margin of the iris, with the branches of the posterior long and short ciliary arteries. The *posterior ciliary* are derived from the ophthalmic, or some of its branches in the back of the orbit; they are tortuous and entwine around the optic with the ciliary nerves, to the posterior part of the ball of the eye; all of these, named the *short posterior ciliary*, except two, and about fifteen in number, perforate the sclerotic coat around the optic nerve, and they then run between this coat and the choroid to the iris; they chiefly supply the choroid coat and anastomose with the anterior ciliary. The *long posterior ciliary* are only two in number, their origin is uncertain, but they run forwards with the short, by the side of the optic nerve; they perforate the sclerotic like the others, but a little farther from the entrance of the nerve, and they extend forwards, one on each side along the middle line of the ball of the eye; they anastomose in front with the other ciliary branches. It is this artery, on each side, that is to be avoided when the needle is used to depress the lens. The distribution of these arteries belongs to the anatomy of the eye.

Anterior.

Posterior.

The *muscular branches* are the arteries for the supply of the muscles; they are divided into superior and inferior. The *superior*, uncertain in origin, sometimes arise by a common trunk, they supply the levator palpebræ, superior rectus, and superior oblique muscles. The *inferior* set, larger than the others, arise from the trunk of the ophthalmic, they pass below and beneath the optic nerve, and divide into branches to supply the other recti muscles and the inferior oblique; and they give off many of the anterior ciliary branches.

Muscular branches.

The *ethmoidal branches* are two, an anterior and posterior. The *anterior*, larger than the other, passes through the anterior of the two orbital foramina in the inner wall of the orbit, with the nasal nerve, it then appears in the cranium on the side of the cribriform plate, gives off some small *meningeal* branches to the dura mater, and it ends by a small branch that passes into the nose. The *posterior* leaves the orbit by the posterior foramen, and, on the surface of the ethmoid bone in the base of the skull, it supplies small *meningeal* branches to the dura mater; some of its branches anastomose with the anterior, and others enter the nose by the foramina in the bone.

Internal to the optic.

Ethmoidal branches.

Anterior.

Posterior.

The *palpebral branches* arise from the ophthalmic opposite the

Palpebral

trochlea of the superior oblique muscle: there is one for each eyelid; the *superior* runs outwards beneath the orbicularis, and in the eyelid it forms an arch with the lachrymal, from which the lid is supplied. The *inferior* descends to the lower lid behind the tendon of the orbicularis, sends a branch to the infra-orbital artery, and it ends in the lower eyelid. These have been dissected on the opposite side. Branches. Superior. Inferior

At the inner angle of the orbit the ophthalmic divides into the nasal and frontal branches. The *nasal* runs forwards above the tendon of the orbicularis to the side of the nose, and it divides into branches that anastomose with the lateral nasal artery, and a small branch, the *angular*, joins with the facial. Nasal branch.

The *frontal* turns round the superciliary margin and ascends on the forehead, as before seen, to supply the muscles and integuments. Frontal branch.

The *ophthalmic vein* commences at the inner angle of the orbit by uniting with the frontal and facial veins; it passes backwards in the course of the artery, and it receives branches which correspond to the arteries, and increase its size. It leaves the orbit by passing between the two heads of the external rectus muscle, below the other nerves, and it opens into the cavernous sinus. Ophthalmic Vein.

Remove the ophthalmic artery, cut across the optic and ciliary nerves about their middle, turn the eye forwards, and fasten it in that position with hooks; some fat and the remaining nerves and muscles are exposed: remove the fat; the three remaining recti muscles lie in the floor of the orbit, the branches of the third nerve lie on them, and the small inferior oblique muscle crosses the direction of the other muscles from within to without. Dissection.

The *lower division of the third nerve* enters the orbit between the two heads of the external rectus muscle, below the nasal and rather above the sixth, but as soon as it has entered the orbit, it lies below the sixth; and, on the outer side of the optic nerve and below it, it divides into three large branches; the internal passes beneath the optic nerve, and in front of the inferior rectus, and is distributed by many filaments to the ocular surface of the internal rectus muscle; the middle branch is given, in like manner, to the ocular surface of the inferior rectus; but the external branch, the longest, extends forwards along the outer border of the inferior rectus, and it is distributed to the inferior oblique muscle, which it perforates at right angles. Soon after its origin the last nerve is joined by the short communicating branch of the lenticular ganglion, and it generally divides into several branches for the inferior oblique muscle. Third Nerve. Lower division.

The *sixth nerve* enters the orbit also between the two heads of the rectus muscle, below the third, and separated by a process of dura mater from the ophthalmic vein which is below it. In Sixth Nerve.

the orbit it rises above the level of the third nerve, and it turns outwards to the ocular surface of the external rectus muscle, to which it is distributed by many filaments.

Inferior Rectus Muscle. Origin. The *inferior rectus muscle arises* in common with the internal and external rectus by a common tendon, which is attached below the optic foramen, and divides into three portions for the muscles. The fibres of the muscle form a fleshy belly, and this

Insertion. ends, in front, in a tendon which is *inserted* into the ball of the eye, opposite to the superior rectus already examined; a synovial bursa is found between the tendon of this muscle and the eye, as is the case in all the recti muscles.

Internal Rectus. Origin. The *internal rectus muscle arises* from the common tendon, and from the tube of dura mater that surrounds the optic nerve; this last attachment joins the superior rectus; the muscle is

Insertion. continued along the inner wall of the orbit, and is *inserted* into the inner side of the eyeball in the same way as the other recti.

External Rectus Muscle. Origin. The *external rectus muscle arises* by two heads, the inferior is attached, below, to the common tendon with the internal and inferior rectus, and the upper is united with the superior rectus; between these two heads is a tendinous arch which gives attachment to muscular fibres, and beneath the arch pass the third and sixth nerves with the nasal of the ophthalmic. The muscle resulting from the union of the fibres lies along the

Insertion. outer wall of the orbit, and it is *inserted* into the outer side of the eyeball. These three muscles lie beneath the optic nerve,

Relations. and to the outer side of it; they are in contact, by one surface, with the ball of the eye, and by the other with the periosteum of the orbit. The third nerve supplies the internal and inferior rectus, and the sixth, the external rectus muscle. An aponeurotic expansion is given off from the tendons near the eye, and the small bursa is found beneath each.

Dissection. Remove the optic nerve from the middle of the posterior attachments of the recti muscles, and open from above the optic foramen, to see the origins of the recti muscles around the nerve and foramen; and to dissect the inferior oblique muscle, replace the eye in its natural position, and raise the conjunctiva from the inner part of the lower eyelid, as well as some fat that conceals the muscle; then, by moving the ball in different directions, the relations of the muscle will be observed.

Inferior Oblique Muscle. The *inferior oblique muscle* is small and thin, it is situated near the anterior margin of the orbit, and it differs from the other muscles, in having its fleshy portion directed almost horizontally outwards, instead of in the axis of the orbit. It

Origin. *arises* from the superior maxillary bone near the groove for the lachrymal sac, and within the margin of the orbit; the muscle is then directed obliquely upwards and outwards across the floor of the orbit, but separated from the eyeball by the inferior rectus; it next passes between the eye and external rectus, and

it is *inserted* into the globe of the eye between the superior and external rectus, with the tendon of the superior oblique, but rather nearer the optic nerve than the attachment of that tendon. Insertion.

The upper surface is in contact with the inferior rectus and globe of the eye, the under with the orbit and external rectus; the borders look backwards and forwards, a tendon being placed on the posterior, and its branch of the nerve meets also the posterior border at a right angle. Relations.

To expose the orbital branch of the superior maxillary nerve or second division of the fifth, detach the connection of the eyelids and tarsal cartilages from the external angle of the margin of the orbit; separate the lachrymal gland from the outer wall, but leave the lachrymal nerve, and its descending branches to join the orbital branch; cut through the external rectus near its posterior extremity, and fasten the eye and its muscles, by means of hooks, to the inner side of the orbit. Seek in the angle of the orbit formed by the outer and lower walls, for the orbital branch of the nerve, which enters through the posterior part of the sphenoidal fissure. Dissection.

The *orbital branch* of the *superior maxillary nerve* is of considerable size; it leaves the trunk of the superior maxillary soon after this nerve has passed from the skull by the foramen rotundum, it then crosses the spheno-maxillary fossa with the trunk of the nerve, but superior and external to it; and it enters the orbit by the sphenoidal fissure, whilst the trunk of the nerve enters the infra-orbital canal and is placed beneath the periosteum. In the orbit the nerve divides into two branches, a malar and temporal. The *malar*, the largest branch, and the continuation of the nerve, runs forwards in the inferior external angle of the orbit to the malar bone, it then passes through an aperture in this bone, and appears in the face beneath the orbicularis palpebrarum, which it supplies; and it communicates with the portio dura. The *temporal branch*, external in position, varies much in size; it ascends along the outer wall of the orbit beneath the periosteum, or in a canal hollowed out in the bone, to about its middle, it is then joined by the communicating branch from the lachrymal, and it passes through the wall into the temporal fossa. By separating, with the handle of the knife, the temporal muscle from the bone, and by cutting away, with the bone forceps, the portion of the outer wall above the exit of the nerve, so as to trace it through; the nerve is seen to ascend in the temporal fossa near the margin of the orbit, and on the surface of the malar bone that looks to the fossa; it then turns outwards to the temporal fascia, perforates it near the edge of the orbit and about one inch above the zygoma, and it ends on the temporal fascia by joining branches of the portio dura, and supplying the integuments as before seen. There is usually a second temporal branch that joins with one Orbital branch of the Superior Maxillary Nerve. Malar branch. Temporal branch.

from the lachrymal, and enters the temporal fossa to communicate with the deep temporal nerve.

Dissection. To see the tensor tarsi muscle, separate the eyelids from the margin of the orbit up to the inner angle, by dividing the palpebral ligaments and orbicularis, place the separated eyelids over the nose, and on the back of the tendon of the orbicularis, which remains untouched on this side, and fixes the tarsal cartilages, some thin pale muscular fibres will be perceived; and, to make it more evident, remove all the fibres of the orbicularis from the front of the tendon.

Tensor Tarsi Muscle. The *tensor tarsi muscle*, small, and oftentimes very indistinct, is situated behind the tendon of the orbicularis. It *arises* from

Origin. the vertical crest which divides the orbital surface of the os unguis into two portions, and slightly from the bone behind the crest; the fibres, which are pale and weak, form a small, flat, muscular band, which divides into two portions that run out-

Insertion. wards along the lachrymal canals, and are *inserted*, one for each eyelid, into the cartilaginous processes in which the puncta lachrymalia are situated, and also into the tarsal cartilage of the

Relations. same lid. The muscle lies behind the tendon of the orbicularis, and against the lachrymal sac.

Dissection. The puncta lachrymalia, lachrymal canals, and lachrymal sac, which constitute the lachrymal apparatus, remain to be dissected. Some bristles have been placed in the canals, so that they are readily seen, and the sac will appear by removing the tensor tarsi and cellular membrane that obscure it, as it lies in the groove in the os unguis in the inner angle of the orbit. The prolongation that the tendon of the orbicularis sends over it is also to be prepared.

Puncta lachrymalia. The *puncta lachrymalia* are the two small apertures, always open, situated in the free margin of each eyelid, about two lines from the inner canthus, and in an elevation that marks the point of union of the two parts of the lid. They are placed opposite each other, and they allow the tears to pass into the lachrymal canals.

Lachrymal Canals. The *lachrymal canals* are small tubes that extend from the puncta to the lachrymal sac, and they convey the tears between these two points; their course is marked by the bristles intro-

Superior. duced into them. The *superior*, rather longer than the inferior, first ascends for about a line, and it then bends downwards and inwards to the sac, forming an arch with the concavity down-

Inferior. wards; the *inferior* descends, and is then continued inwards almost in a straight direction to the sac. Both canals are situated along the sides of the tendon of the orbicularis, and beneath the fibres of this muscle; and they open into the outer part of the sac by distinct apertures rather above its middle. Before their termination the canals are close together, and the only partition between them is their coats.

Extending from the inner part of the orbit to the nose, is a tube which receives the tears, and conveys them into the latter cavity; this is dilated above, is contained only in a half-osseous case, and is named lachrymal sac; but the lower part, which is narrow and encased by bone, is the lachrymal duct. The *sac*, the upper dilated portion of the tube for the tears, is situated within the inner angle of the orbit, in the groove formed by the os unguis and ascending process of the superior maxillary bone; on the outer side the sac is destitute of any bony covering, but it is crossed by the tendon of the orbicularis, which divides it into an upper portion which is round and forms the top of the sac, and a lower, of greater extent, continuous below with the duct. From the margins of the tendon an aponeurotic expansion is given off, and it is connected to the margins of the bony groove, so as to cover the sac contained in this depression; the portion from the upper border is the strongest; opening into the outer side of the sac are the lachrymal canals by which it receives the tears. It is covered externally by the tendon and aponeurotic expansion, and above that by the orbicularis, tensor tarsi, and conjunctiva; its arteries and nerves are from the nasal, which run on its exterior. Raise the fibrous membrane which covers it, and a loose, rather reddish, but thick mucous membrane is visible. The *duct* is the canal which extends from the sac to the inferior meatus of the nose, into the front of which it opens. It is about one inch and a half long, narrower in the centre than at either extremity, and it is directed obliquely downwards and backwards, so as to be convex forwards; it lies between the nasal fossa on the one side and the antrum Highmori, or cavity in the superior maxillary bone, on the other; the partition between it and the nose is very thin and fragile, but that which separates it from the antrum is thick and strong. The osseous boundaries are, in front and to the outer side, the ascending process of the superior maxillary bone which is grooved for it; behind, the ungual bone, which is also grooved, and the part of the inferior spongy bone that ascends to articulate with the ungual bone. The membrane that lines the canal is of a fibro-mucous character, and it is prolonged from the nose.*

Lachrymal Sac and Duct. Sac. Duct.

The dissection of the eye naturally follows that of the orbit, lachrymal apparatus, and appendages of the eye; but since this organ must be examined in the eyes of some animal, as the ox or sheep, it may be omitted with advantage till the head and neck is finished. The dissection is introduced at this part, but it may be passed over.

* The operation of introducing a probe into this canal from the aperture in the inferior meatus should be practised.

DISSECTION OF THE EYE.

Dissection. In dissecting the eye it will be necessary to procure half a dozen eyes of the ox, since they are the largest, and they should be very fresh. A small basin or two, or some saucers, will be required for the dissection of some of the minute structures in water, and into the bottom of one or more some melted wax or tallow should be run. To see the general form of the ball of the eye and the external coat, it will be required to remove only the different muscles attached to it, the loose conjunctiva over the cornea, and the fat that surrounds it; this may be done to all the eyes.

Eyeball. The eye, the organ of vision, is a spherical body situated in the front of the orbit; it is free and moveable in its cavity, and it is formed by membranes or coats which give the form to the ball, and contain the different fluids or media in the interior, by which the rays of light are refracted, so as to produce a correct image on the retina, or the expansion of the optic nerve, which is the nerve of special sense distributed to the eye. The ball of the eye is retained in position by the muscles attached to it, by the vessels and nerves that enter it, and by the eyelids and their lining membrane the conjunctiva; its axis is not parallel to that of the orbit, but to that of the opposite eye. The eye is nearly spherical, but the anterior part or cornea, which forms about the anterior fifth of the globe, is a segment of a smaller sphere than the posterior part of the ball; and the antero-posterior diameter, eleven lines in length, is larger than the transverse by one line. To the back of the globe of the eye is attached the optic nerve, but it enters rather to the inner side of the axis of the ball. The eye is surrounded by its muscles and by much fat. The investing parts of the ball of the eye are the sclerotic coat and cornea, the choroid coat and iris, and the retina; and the internal or central portions, the vitreous fluid and its membrane, the aqueous humour and its membrane, and the lens with its capsule.

Sclerotic Coat. The *sclerotic coat* is named from its strength, and it forms a segment of a sphere extending from the optic nerve behind to the cornea in front. This membrane or coat is of a fibrous structure, it is dense and inelastic, and of a pearly white colour; it gives the form to the eyeball, of which it occupies about the posterior four fifths. At the posterior part of the ball of the eye, and a little to the inner side, this coat is perforated by the optic nerve which passes either through one or through many openings, and the external investing membrane of the nerve joins it; many other small apertures are seen, around this, for the ciliary vessels and nerves. The thickest portion of the scle-

rotic is behind, as will be seen afterwards in removing it; but in front it is thinner, receives more vessels, and it appears as the white of the eye. A fibrous prolongation from the tendons of the recti muscles surrounds the front of the ball near the cornea, and this has been named by some *tunica albuginea*. The circular aperture which receives the cornea is about six lines in diameter, rather elongated transversely, and its margin is extended forwards, so as to cover the cornea which is inserted beneath it. The outer surface is covered, in front, by the reflected fold of the conjunctiva, and, behind, it is in contact with the muscles of the eye and the great quantity of fat contained in the orbit. The inner surface is brownish and connected to the next coat, — the choroid, by cellular membrane, and by the vessels and nerves that perforate it to go to the choroid. The sclerotic is formed by fibres which run in every direction.

Dissection. To see the anatomy of the cornea, it will be necessary to detach it from the eye, and this is to be done in the following manner: — cut, circularly, with a scissors, through the sclerotic, about two lines behind the junction of this membrane and the cornea, and make a vertical incision, on each side of the ball, to the optic nerve; remove then the portions of sclerotic as far back as the nerve; this is accomplished either by fixing the eye to the wax, or by holding it in a forceps, when the weight of the ball breaks through the cellular connections between the sclerotic and the next coat — the choroid: at the back of the eye, the vessels and nerves that perforate the outer membrane must be divided. Separate now the cornea from the front of the ball by detaching a cellular connection between it and a white ring, — the ciliary ligament, which extends round the front of the choroid, and is nearly opposite to the circumference of the cornea. In raising the cornea, still anterior to the ciliary ligament, a thin membrane is seen to be torn through, and if it be done out of water, the fluid contained by this membrane escapes in visible quantity; this is the aqueous humour retained, by the cornea and its own membrane, in a space in front of the iris and lens. A vertical section should be made in another eye, since it will be required for the next coat; and the manner in which the cornea limits, in front, the anterior chamber, will be better seen; this section is difficult to make, and it may be begun by cutting from behind forwards through the different coats of the eye with a scissors, as far as to the cornea; next, place the eye on the cornea, and with a sharp knife complete the section through the hard lens and cornea, the eye being placed in water, either on a surface of wax, or on wood, to allow of its being cut through. The halves must remain in water to preserve the natural position of the parts.

Cornea. The *cornea*, called sometimes *transparens*, to distinguish it

from *cornea opaca*, — a term that has been applied to the sclerotic, — is received into the aperture in the front of the sclerotic, and it completes the front of the eyeball. It is transparent, smooth, convex externally, but concave internally to the anterior chamber, and it forms the anterior fifth of the ball; but it is a segment of a smaller circle than the sclerotic. The circumference of the cornea is not quite circular, since the measurement, from side to side of the eye, is slightly greater than the vertical; the margin is received into the aperture of the sclerotic, like the glass into a watch, the edge of the sclerotic being prolonged a short way over it: this union is very intimate, but they may be separated by maceration. This structure of the eye bounds in front the anterior chamber; and, since the rays of light pass through it to reach the retina, the different degrees of sight, at a distance, will depend, in a great measure, upon the convexity of the cornea. The texture of the cornea is not fibrous, but laminar, and the transparency depends upon the presence of a small quantity of fluid between the laminæ, as well as upon the due distance between them being preserved; for if one of the entire eyes be forcibly compressed, the transparency of the cornea is destroyed, but it is instantly restored when the pressure is removed; the fluid of the anterior chamber transudes through the cornea after death, so as to render this structure dull and flaccid. The structures found in the cornea are, externally, the conjunctiva, continued over the convexity, whose presence is proved by disease, or, anatomically, by macerating an eye in water; internally, the membrane of the aqueous humour, a very thin serous membrane that lines the space between the cornea and the lens; and, between these, the proper cornea which gives strength to the part. On the inner or concave surface of the proper cornea is a thin elastic membrane

Elastic Cornea.

— the "*elastic cornea*"—readily seen, on the inner surface of the removed cornea, by making an incision across it, to be a very thin, shining, transparent membrane that lines the proper cornea, and when removed it curls upon itself; it also remains transparent during maceration in water. The remaining portion of the cornea, or the *proper cornea*, is formed of laminæ,

Proper Cornea.

whose presence may be detected by rubbing the membrane between the finger and thumb, or they may be raised from each other by dissection: the number of the laminæ is about four, and they are connected by thin layers of cellular membrane.

Dissection.

The next coat — the choroid — is exposed in the dissection already made; but, as it will be necessary to see also the inner surface, prepare another eye in a similar way, in order that the membrane may be cut through to expose it. Make also a horizontal section of all the coats of another eye, about two lines behind the cornea, and raise from the ball the cornea, ciliary ligament, and processes, all connected together, in order

that the inner surface of the choroid may be seen in position, as well as the ciliary processes which are connected with it in front, and pass inwards behind the ciliary ligament and iris; these are covered with the black pigment which should be washed from them with a camel's hair pencil. The natural position of these processes can be observed in the vertical section already made.

Choroid Coat.

The *choroid coat,* the next covering of the ball of the eye, is also a segment of a sphere like the sclerotic, beneath which it is placed, and it extends forwards from the optic nerve behind, to the ciliary ligament, or near to the circumference of the cornea, as may be seen in the vertical section; and the aperture, before, is partly closed by the iris which hangs almost vertically in front of it from the ciliary ligament. The membrane does not cease in front by joining the ciliary ligament, as it appears to do, but it is reflected inwards, behind it and the iris, in the form of small triangular folds,—the ciliary processes,—to be afterwards described, but which can be now seen by means of the horizontal section. The choroid is thicker behind than before, and it presents a round aperture posteriorly for the entrance of the optic nerve into the eye; it is dark-coloured externally, since it is stained by the dark pigment on its inner surface, and it is also rough and flocculent; it is connected to the sclerotic by cellular membrane, and between it and the sclerotic are the ciliary vessels and nerves, as well as the veins that issue from the outer surface of this coat. On this surface are also seen the longer branches of the arteries that supply the coat before they perforate to terminate in the inner; the veins are arranged, also, in small parallel arches before they join the trunks of the veins which pierce the sclerotic. These veins occupy the outer surface of the choroid, and are named *vasa vorticosa;* and, posteriorly, the choroid membrane can be separated into an outer venous, and an inner arterial portion; the latter, the thinnest, is named *tunica Ruyschiana.* The inner surface of the choroid is seen by tearing this membrane with two pair of forceps; it is smooth and vascular, the ramifications of the ciliary arteries chiefly ending in it; and it is in contact with the retina. On the inner surface of the choroid is the *membrana pigmenti,* a thin membrane with hexagonal or flattened cells, in which is contained the brown colouring matter,—the *pigmentum nigrum,*—that gives the dark appearance to this membrane. The pigment exists in greatest quantity in front, on the ciliary processes and iris, but in albinos the dark pigment is absent from the cells. In many animals, particularly the Ruminantia, as in the eye of the ox now being examined, the colouring matter is deficient also over a certain spot in the bottom of the eye, and the inner surface of the choroid shines with a metallic lustre; this is called the *tapetum* in these animals, and it is placed to the

Vasa vorticosa.

Tunica Ruyschiana.

Membrana Pigmenti and Pigmentum nigrum.

Tapetum.

Ciliary Processes.

outside of the optic nerve. The *ciliary processes*, or anterior folds of the choroid, with which they are continuous behind, are from sixty to seventy small triangular processes, placed side by side, and they surround the lens like the corolla of a flower.

Ciliary Body.

The whole of these processes are named, sometimes, the *ciliary body*, and it corresponds to the ciliary ligament. Without, this is closely united to the front of the membrane of the vitreous humour, as might have been experienced in removing the processes from the front of that membrane, and it projects into the space between the iris and the lens, or into the posterior chamber, of which it forms the circumference: this may be seen in the vertical section. Each process is about two lines in length, but every alternate one is shorter than the next to it, and each is thin, externally, at its union with the choroid opposite the ciliary ligament, and thick and pointed internally; it ends by projecting into the posterior chamber around the lens, but not so as to touch it, and it is covered by the lining membrane of this cavity. Into the intervals, left behind, between the processes, are inserted the prominences on the front of the membrane of the vitreous humour, and these are intimately united to the ciliary processes; the anterior surface of each looks to the iris, to which it is united externally near the ciliary ligament. These processes consist, like the choroid, of vessels.

Ciliary Ligament.

The *ciliary ligament* or *circle*, which is seen in the eye in which the sclerotic is removed, is a whitish cellular band, from one to two lines wide, situated in the ball of the eye, nearly opposite the junction of the sclerotic and cornea, and it corresponds to the point of union of the choroid and iris; to the outer surface is united the sclerotic by cellular membrane: to the inner, the iris which hangs vertically from it; and, behind, it is in contact with the ciliary processes of the choroid, which turn inwards behind it. The ciliary vessels for the iris divide and anastomose before they perforate this structure; the nerves, also, pass through it to reach the iris. A small groove on the exterior is converted into a canal, — the *canal of Fontana*, by the contact of the sclerotic.

Canal of Fontana.

Iris.

The *iris* is seen in its natural position, and the posterior and anterior surfaces are also exposed in the dissections already made; it is the thin, coloured, vertical septum placed before the aperture in the front of the choroid, which it assists to close. By its position, also, across the space included between the cornea in front, and the lens and vitreous humour behind, it divides this space into two parts of unequal size; the one in front being named the anterior chamber of the eye, and the small one behind, the posterior chamber. The circumference of the iris is fixed to the ciliary ligament, and it is placed nearly opposite the junction of the cornea and sclerotic. In the middle is an aperture, — the *pupil*, — situated rather to the inner side of

Pupil.

the centre of the eye, circular in man, but differing in shape in certain animals; and the size is constantly varying, on account of the contraction or relaxation of the iris, dependent upon the different degrees of light which strike upon the eye, or even, in some cases, the will of the individual. Through this aperture the two chambers of the eye communicate, and by it the rays of light are admitted to the retina. The anterior surface looks to the anterior chamber, of which it is the posterior boundary, and it is covered by the membrane of this cavity: the colour of this surface varies in different individuals, according to the temperament; thus, in those with a fair complexion and light hair, it is blue, and in those with dark hair and complexion, it is dark brown; and the dissimilar-coloured surfaces in different eyes are produced by tints intermediate between these: in the negro it is black, and in the albino, without colour. The posterior surface is in contact with the ciliary processes, it is covered by much pigment, and it forms the anterior boundary of the posterior chamber; this surface, sometimes named the *uvea*, is covered by the thin membrane of the chamber, which is reflected over it and the ciliary processes. If the iris be detached from the ciliary processes, the colouring removed by washing it with a camel's hair pencil, and the anterior surface examined with a lens, "a number of irregularly-shaped masses may be seen projecting from the middle space between the circumference and the pupil. From the convexity of these masses, a number of elevated lines, equally irregular in size and number, proceed towards the pupil, and attach themselves, at the distance of about the twentieth part of an inch from its margin; and from this point of attachment a number of much smaller *striæ* converge to the edge of the central opening."* These fleshy bodies or processes are more distinct in the dark iris, and approach nearer to muscular fibre than the branching of blood-vessels. On the posterior surface are folds or processes resembling the ciliary processes both in form and in their nature, and they reach to near the pupil; and immediately surrounding the pupil on this surface is a narrow flat band of circular muscular fibres. In the eye of the ox, which is generally examined in the absence of a fresh human eye, the anterior surface is marked by circular muscular fibres, and the posterior by vertical or diverging fibres.

Occupying the aperture of the pupil, in the fœtus, is a vascular membrane, — the *membrana pupillaris*, which disappears either about the period of birth, or a short time previous to this. This membrane is said to be formed by the union of two thin

Membrana pupillaris.

* An extract from a paper entitled "Inquiries respecting the Anatomy of the Eye," by Arthur Jacob, M.D., in the 12th volume of the *Medico-Chirurgical Transactions*, p. 510.

transparent layers of membrane, which contain between them some vessels derived from those in the iris.

Ciliary Arteries. Posterior. Long. Short. Anterior.

The *ciliary arteries* are long, short, and anterior, but neither these, nor the veins will be seen unless the eye has been specially injected with fine injection. The long and short posterior ciliary branches of the ophthalmic at the back of the eye perforate near the optic nerve, are about twenty in number, and are accompanied by ciliary nerves. The *long*, only two in number, one on each side of the eye, run forwards to the ciliary ligament between the sclerotic and choroid, and in a line opposite to the centre or axis of the eye; at the ciliary ligament they divide into branches, which anastomose with each other, and form a circle around this body, with which the anterior ciliary also anastomose, and from the circle branches pass inwards to supply the iris; these are said by Ruysch to anastomose a second time near the pupil. The *short ciliary* run a certain distance between the sclerotic and choroid, and they are then distributed to the inner part of the choroid coat. The *anterior ciliary*, given from the ophthalmic in the front of the orbit, perforate the sclerotic near the junction of the cornea with it, and they end by anastomosing with the arterial circle of the long ciliary, before being distributed to the iris. These vessels are well seen only where they are enlarged, as in instances of inflammation of the iris, and they then form a ring around the cornea.

Veins.

The *veins of the choroid*, which correspond to the short ciliary arteries, form arches which converge to a common trunk on the outer surface of the membrane; these are called *vasa vorticosa*, and they unite into four or five larger branches, which perforate the sclerotic behind the middle of the eye, and open into the ophthalmic vein. The veins of the ciliary processes are continuous with these, and those of the iris open into the choroid veins, or accompany the long ciliary arteries.

Nerves.

The *ciliary nerves* come from the lenticular ganglion and from the nasal branch of the fifth; they are about fifteen or twenty in number; they perforate the sclerotic near the optic nerve, and then run forwards, as the arteries, to the ciliary ligament; they divide, at this structure, into branches which may be traced through it to the iris, to which they are distributed.

Chambers of the Eye. Anterior. Posterior.

The *anterior chamber*, or the cavity in front of the iris, will be seen in the vertical section made of the eye; the posterior also appears in the same section. It is a space about three lines in depth, and it is bounded in front by the posterior or concave surface of the cornea, and behind by the iris. The *posterior chamber* is about one line only, in extent, from before backwards; and in front of it is the posterior surface of the iris; behind, the lens, and a small portion of the hyaloid membrane external to the lens or between this body and the ciliary processes; and

the circumference of the cavity presents the apices of the ciliary processes; the two chambers communicate through the pupil. The surfaces of the two chambers are lined by a thin transparent membrane, — the membrane of the aqueous humour, and the quantity of fluid or *aqueous humour* found in the cavities is from four to five grains; its specific gravity is very near that of water. Aqueous Humour.

To expose the next coat, the retina, with the membrane of Jacob, fasten the eye, in which the choroid has been dissected, by placing a pin through the optic nerve, and then tear off the choroid, into which an incision has been made, with two pair of forceps; or it may be exposed, in an entire eye, by passing a thread through the cornea, and fastening this to a pin fixed in wax; the coats of the eye are then to be removed as above directed, till the retina is exposed. Dissection.

The *retina*, or expansion of the optic nerve, is the third or most internal coat which extends forwards from the optic nerve behind, to the ciliary ligament in front; and it is also a segment of a circle, whose aperture in front is rather larger than that of either the sclerotic or choroid. This membrane, during life, and for a short time after death, is transparent, but it soon loses this, and becomes opaque, or of a dull white colour; it closely surrounds the vitreous humour, and although mentioned as a single membrane, it nevertheless consists of two layers separable and distinct from each other; an internal or vascular, and a proper medullary membrane continuous with the nervous substance of the optic nerve; and external to these, again, is a thin serous-like layer, — the membrane of Jacob. Retina.

The *external*, or *Jacob's membrane* *, is a thin transparent layer which covers the outer surface of the medullary or nervous portion of the retina, and extends from the optic nerve behind, to the ciliary processes. It presents, externally, a villous surface, and it is closely united to the choroid coat by vessels and cellular membrane, so that it may be taken up with the choroid, but the connection between it and the retina is generally more intimate than between it and the choroid; it is generally tinged a rather dark colour by the *pigmentum nigrum*. Some have considered this structure to be a serous membrane, of which one layer covers the choroid, and the other the retina. When an eye is dissected within forty-eight hours after death, the ball being fixed by thread passed through the cornea, and the coats removed from behind, Dr. Jacob says, "If the extremity of the ivory handle of a dissecting knife be pushed against this surface (of the retina), a breach is made in it, and Jacob's Membrane.

* This membrane is described in the Philosophical Transactions for 1819, as *An Account of a Membrane now first described*, by Arthur Jacob, M.D., from which the above facts are taken, and to which reference may be made for a more extended knowledge.

a membrane of great delicacy may be separated and turned down in folds over the choroid coat, presenting the most beautiful specimen of a delicate tissue which the human body affords." Or, if "the blunt end of a probe be introduced beneath it, it may be separated throughout without being turned down, remaining loose over the retina." If air be now introduced beneath it, its thickness and transparency will be seen, or a few drops of acid will render the membrane opaque and more visible. In the ox or sheep, this membrane has nearly the same appearance as in the human eye.

Medullary Layer of the Retina.

The *medullary* or *nervous layer* of the retina, placed between Jacob's membrane, externally, and the vascular layer of the same coat on the inner side, is an expansion of the neurine contained in the tubes of the optic nerve; it is soft and pulpy, is separable from the vascular layer in small shreds, when it is hardened in spirit, and maceration in water readily removes it from the vascular. When examined soon after death, it maintains the transparency that it had during life, but it soon becomes opaque. The properties of this layer are best observed when it is rendered opaque by either spirit or acid, and placed beneath a glass globe. The anterior termination of this layer is in front at the ciliary processes, and it presents, here, an undulating line, the projections of which are received into the intervals of the ciliary processes; but in the ox the line is straight, a small vessel runs along it, and it does not extend so far forwards. An examination of this layer beneath the microscope, by Treviranus *, shows that this structure consists of numerous cylindrical nervous fibres, into which the optic nerve divides; that these are placed side by side, and have their free extremities bent inwards towards the vitreous humour, or centre of the ball of the eye.

Vascular Layer.

The *vascular layer* is the thin membrane that lines the medullary layer of the retina, and it is formed by the division of the central artery of the retina into many branches after it has entered the eye. This layer will be exposed by macerating for two or three days an eye dissected, as above advised, to expose the retina, when the medullary layer may be readily scraped from it. This layer supplies the retina and hyaloid membrane with vessels, but particularly the latter, to which it is most closely connected; it extends forwards to the line of union of the ciliary processes with the projections on the front of the vitreous humour, and it is described by Dr. Jacob † as ending at this point, by joining, inseparably, by vascular union, the membrane of the vitreous humour.

Foramen centrale.

If an eye be cut horizontally across, so as to remove the cornea, iris, and ciliary process with the lens, and if the retina

* See *Müller's Physiology*, translated by Dr. Baly, p. 1122.

† In the paper before referred to, in the 12th volume of the *Medico-Chirurgical Transactions.*

be viewed through the vitreous humour, it is seen to be covered with numerous folds, the result of flaccidity of the membrane, because of its loss of support; and in the bottom of a recent human eye, prepared in the same way, will be observed also a *fold* external to the optic nerve; and close to this, and partly concealed by it, is a round yellow spot, — the *limbus luteus*, — situated in the axis of vision, and about a line to the outer side of the entrance of the optic nerve. In the centre of the yellow spot is the *foramen centrale* of Sœmmering, a dark round point, in which the medullary layer of the retina is deficient, and through which the dark choroid may be seen. This structure or foramen exists in the Quadrumana as well as in man, and Dr. Knox has found it in some species of lizards.* The perforation of the optic nerve by the central artery of the retina, which is now seen, is sometimes called *porus opticus*. The foramen and fold may be examined also from the outside by removing Jacob's membrane, as well as the other coats of the eye.

Plica or Fold.

Limbus luteus.

Porus opticus.

The *central artery of the retina*, for the supply of the retina, hyaloid membrane, and lens, is a small branch from the ophthalmic artery in the orbit; it is seen, in the horizontal section of the eye, to enter the globe through the centre of the optic nerve; it then divides into two branches which surround the foramen centrale, and expand into numerous branches which end in the vascular layer of the retina, and supply the membrane of the vitreous humour; a small branch perforates also the centre of the vitreous humour, to reach the posterior part of the capsule of the lens: this is well seen in the eye of the ox.

Central Artery of the Retina.

The vitreous body, and the lens, with the corona ciliaris, will be exposed by taking away the retina, the ciliary ligament, and ciliary processes from an eye on which the retina has been dissected; or the lens and corona ciliaris will be better exposed by a horizontal section through the coats of an eye, about two lines behind the junction of the cornea and the sclerotic, when the ball is fixed upright to wood or wax. This incision allows the cornea, ciliary ligament, and processes, with the iris, to be taken away; but the ciliary processes must be detached with great care from the front of the hyaloid membrane.

Dissection.

The *vitreous body*, named from its resemblance to a mass of solid glass, is a transparent fluid contained in a membrane, — the hyaloid, and it occupies three fourths of the globe of the eye: it fills entirely the posterior part of the ball, and it supports the delicate structure of the retina, which is applied to it. In front, the vitreous body is slightly hollowed out, to receive the crystalline lens to whose capsule its membrane is closely connected, and around the lens is the striated surface of the corona ciliaris. The *hyaloid membrane* is a thin transparent membrane, which

Vitreous Body.

Hyaloid Membrane.

* Transactions of the Royal Society of Edinburgh, vol. x. part i.

contains the vitreous humour, and it sends processes inwards, so as to form different compartments or cells in which the fluid is contained; these cells may be seen by placing the vitreous body on a card and perforating it, when the fluid will escape from the membrane. A fold is described, by Jules Cloquet, as passing through the centre of the vitreous humour around the central artery of the retina. In front, the hyaloid membrane is very closely united to the ciliary processes, and it presents the striated corona ciliaris, together with its prominent folds which are received into the intervals between the ciliary processes; and external to these folds is the junction with it of the vascular layer of the retina; a portion of the membrane close to the lens bounds the posterior chamber of the eye. The distribution of the hyaloid membrane in this part is not quite certain; some describe it as being divided into two layers, one of which passes beneath the lens, and the other to its margin to unite with its capsule, the processes of the corona ciliaris being only folds of this last, or upper layer, and the canal of Petit, the interval between the two, near the margin of the lens; others, as Zinn, describe the membrane to be single in front, and to pass under the lens, the folds and striæ of pigment that compose the corona ciliaris being part of a distinct structure,— the "*membranula*," applied on the hyaloid membrane; and the canal of Petit, the interval between the two. The membrane may be rendered more apparent by putting it, with the contained fluid, into dilute acid, or into spirit. It receives its vessels from the central artery of the retina, chiefly through the medium of the vascular layer, as well as from the artery to the posterior part of the lens, and also from the vessels of the ciliary processes.

Fluid. The *fluid* of the *vitreous body*, enclosed in the hyaloid membrane, consists of water which contains soda and albumen, it is quite transparent, and its specific gravity is rather greater than water; it escapes from its cells when they are punctured.

Corona ciliaris. The *corona ciliaris*, or zonule of Zinn, is the striated appearance on the front of the hyaloid membrane, and around the circumference of the lens; the outer margin is connected to the vascular layer of the retina, and the inner reaches to near the circumference of the lens. The surface presents raised lines covered with dark matter, and, alternating with these, are depressions, so that, from its striæ, it has been resembled to the disk of a flower. The processes, best seen by washing away the colouring matter, are sometimes named the *ciliary processes* of the hyaloid membrane; when they are examined with a lens, they are smaller than the ciliary processes of the choroid, although the folds of the hyaloid membrane commence farther out than those of the choroid: they are attached by one side to the hyaloid, and by the other, which is

Ciliary Processes of the Hyaloid.

free, they are received into the depressions which exist between the ciliary processes of the choroid membrane, whilst the depressions of the corona receive the prominences of the ciliary processes; so that there is an indigitation between the projections of the two membranes, by which the posterior chamber is completed behind; and the layers of the retina are prevented, by this union, from reaching the lens. The processes, when examined with a lens, are found to be fringed on their free margins, and to have a structure very nearly resembling that of the ciliary processes of the choroid.

Canal of Petit.

The *canal of Petit* is demonstrated by dividing, close to the margin of the lens, the membrane on which the corona ciliaris is placed, and by blowing air into it, or by dropping red or black ink into it. It is a small circular canal, from one to two lines in breadth, placed around the circumference of the lens, and when distended with air, it is sacculated at regular intervals, like the form of the large intestine, the depressed lines corresponding to bands that cross it. The structure between which the canal is placed is, as before said, uncertain, one opinion maintaining that it is only an interval left between the separation of the two layers of the hyaloid, into which this membrane divides at its front; and another, that the piece of membrane superficial to the canal, and closing it in, is a distinct structure attached internally to the margin of the lens, and externally to the hyaloid membrane, forming the *membranula of Zinn*, on which are placed the folds and depressions which form the *corona* or *zonula*.

Membranula of Zinn.

Crystalline Lens.

The *crystalline lens*, obtained by opening the capsule that conceals it, is a transparent, doubly-convex body, lodged in a capsule of its own, and it is situated immediately behind the pupil in a depression in the front of the vitreous humour, so that all the rays of light that pass through the pupil must traverse it; by which, with other structures, they are refracted to depict the image on the retina. The posterior surface of the lens is generally more convex than the anterior, but this differs in individuals, and at different ages the shape of the lens presents great varieties in its form; for in the fœtus it is almost round, but its convexity decreases with increasing age, and in old people it is flattened. In the fœtus, the lens is reddish and soft, and in infancy it is rather opaque; it is firm, but quite transparent, in youth and mature age, and it becomes yellowish and dense in old age. The outer layers of the lens are much less dense than those in the interior, and they are readily rubbed off between the finger and thumb. In the recent state, the lens appears an almost homogeneous substance; but, when it is hardened by immersion in alcohol or hot water, its fibrous structure becomes more manifest; it consists of concentric layers, one contained within the other; and these, again, are formed by

fibres which extend from the divergence of three septa on the anterior surface, to the same on the posterior. Sir David Brewster states that the margins of the contiguous fibres are dentate, and digitate with each other.

Capsule of the Lens.

The *capsule of the lens* is a firm, elastic, transparent structure which closely surrounds the lens; it is connected behind to the hyaloid membrane, and on the sides it is joined by the *membranula of Zinn*, or the superficial of the two layers of the front of the hyaloid membrane. Its anterior surface projects into the posterior chamber of the eye, and bounds, behind, this space. The membrane is very elastic, and supports itself after the removal of the lens; and its transparency is retained for some time, even after immersion in spirit or water. When it becomes opaque by disease, it constitutes one form of cataract. Between the capsule and the lens, in an eye that is not recent, a fluid is found, which has been called the *liquor Morgagni*, but this does not appear in eyes examined a few hours after death. The lens is connected to its capsule by vessels that perforate it from the branches of the central artery of the retina, which ramifies freely on the back of the capsule, and which may be injected in the fœtus; and the front of the capsule is supplied by arteries from the anterior ciliary, distributed to the ciliary processes of the choroid coat.

Liquor Morgagni.

POSTERIOR TRIANGLE OF THE NECK.

Dissection.

For the dissection of the neck, remove the blocks from beneath the head, and, the thorax being moderately raised, carry the head backwards, turn it to the left side, and fasten it in this position with hooks; depress the point of the shoulder by placing the arm over the body, in order to obtain a good view of the right side of the neck, on which the dissector is to commence. The surface of the neck now exposed presents a somewhat square form, the lower boundary or line being the prominence of the clavicle, the upper, the base of the jaw and superior transverse ridge of the occipital bone; in front it is limited by a line from the chin to the top of the sternum, and behind by another line from the occipital protuberance to the acromial end of the clavicle. This space is subdivided into two by the prominent sterno-mastoid muscle which extends from the sternum to the mastoid process; the part in front of the muscle corresponds to the great anterior triangle of the neck, and the portion behind, to the large posterior triangle. From the direction of the muscle, the base of the anterior is at the jaw, and that of the posterior at the clavicle; and the surface is most depressed below the

jaw, and above the clavicle, or in the widest parts of the spaces. It is necessary to examine the posterior triangle before the dissection of the back, to see, undisturbed, the relations of the part of the subclavian artery contained in it.* Make an incision along the prominent line of the sterno-mastoid muscle, from the sternum to the mastoid process, another along the clavicle to its acromial end, — if this is not already done, — and raise the flap of skin, from below, to the line that bounds, behind, the space. Some small cutaneous nerves are found entering the integument. The superficial fascia or cutaneous cellular membrane is exposed; it varies much in thickness in different subjects, and it contains the platysma muscle within two layers of it: remove it from the surface of the platysma, in order to see the anatomy of this part of the muscle.

Platysma myoides Muscle.

The *platysma myoides* is a thin muscle, extended across the side of the neck, from the top of the shoulder to the base of the lower jaw, and it is only the lower half of it that covers part of the posterior triangle, that is now exposed. The thin muscular fibres take their *origin* from the integument covering the upper part of the pectoral and deltoid muscles, and this is dissected with the thorax; they are at first thin and scattered, and in some subjects scarcely perceptible, but they become more marked as they ascend; and they form a flat, very thin, cuticular muscle which is placed over portions of both of the triangles of the neck, and is *inserted* into the base of the jaw. The cutaneous surface of the lower half of the muscle is more closely united to the skin than the upper; and this portion of the muscle covers in the lower part of the posterior triangle, as well as the external jugular vein, and the cutaneous nerves of the cervical plexus. Reflect upwards the muscle to the line of incision across the neck; the external jugular vein is exposed in some cellular membrane, and superficial to the deep cervical fascia; the cutaneous descending branches also of the cervical plexus over the clavicle and acromion come into view. The direction of the fibres of the platysma is to be noted with reference to venesection in the external jugular vein, since the vein is to be opened by an incision that will cut across the muscular fibres.

Origin.

Insertion. Relations.

External Jugular Vein.

The *external jugular vein* commences, in the parotid, by the union of the temporal and internal maxillary veins, and it communicates with the internal jugular by a deep branch through the gland. The vein descends superficial to the deep fascia, but beneath the platysma; it crosses over the sterno-mastoid

* If the dissection will not be interfered with by turning the body for the muscles of the back, expose the whole side of the neck by means of an incision along the jaw, another along the clavicle, and the third to connect these two in the middle line. The superficial fascia and platysma will be exposed in the same manner as in the above method, and reference may be made to the description of the anterior and posterior triangles.

muscle, descends parallel to its outer border, nearly to the clavicle, and it then perforates the deep cervical fascia, to open into the subclavian vein. The size of the vein will vary much; it is sometimes double; and it is accompanied by small branches of nerves from the cervical plexus. In its course down the neck, it receives some small cutaneous veins, and generally some from the anterior jugular; and, after it has perforated the fascia, it is joined by the veins that accompany the transversalis colli, and transversalis humeri arteries: this will be dissected in another stage.

Deep Cervical Fascia.

Beneath the platysma, is the *deep cervical fascia*, or proper investing fascia of the neck, which, like the fascia of other parts, consists of a layer to envelope the muscles, and of processes that dip down to separate them from each other. In some subjects, this fascia is very thin and indistinct, but it is always stronger over the anterior than over the posterior portion of the neck. It envelopes the sterno-mastoid muscle in a sheath; and it then passes backwards, over the posterior triangle, and beneath the border of the trapezius muscle, to be united to the spines of the cervical vertebræ, and to the ligamentum nuchæ. At the lower part of the neck, this layer in continued over the clavicle, into the fascia of the pectoral muscle; and, near the clavicle, it is perforated by many cutaneous nerves, and by the external jugular vein. Remove this layer of fascia from the posterior triangle, without injuring the cutaneous nerves that perforate it, and clean the cutaneous surface of the sterno-mastoid muscle. A deep process of the fascia is observed to dip downwards, to envelope the omo-hyoid muscle that crosses the lower fifth or sixth of this space; and, after surrounding it, it is continued beneath the clavicle and subclavius muscle, to form a sheath around this muscle, and the axillary artery and brachial plexus of nerves.

Dissection.

Detach the process of fascia from the omo-hyoid muscle, and take away, with care, the cellular membrane and fascia that closely surround the branches of the cervical plexus in the portion of the space above the muscle; some of the branches of the plexus ascend, the greater number descend; one or two pass forwards and backwards. Below the muscle and in the smaller portion of the space, are the trunk of the subclavian artery, and some of its branches; the brachial plexus of nerves, with the small subclavian branch from it; and the external jugular vein, with its branches.

Posterior Triangle of the Neck.

The *posterior triangle*, or space of the neck, is bounded, in front, by the sterno-mastoid muscle extended from the sternum to the mastoid process; and, behind, by the anterior border of the trapezius muscle: the apex of the space, at the occipital bone, is about two inches behind the mastoid process; and the base, below, corresponds to the middle third of the clavicle.

This space is subdivided by the small omo-hyoid muscle which crosses it about its lower fifth, into a lower or clavicular and an upper or occipital portion. The *clavicular* or lower portion of the triangle — of the most importance to the surgeon, because of its containing the subclavian artery — is to be studied very carefully, to acquire a knowledge of its boundaries and the relations of the parts contained in it. This small space, situated close above the clavicle, is, usually, about one inch and a half long; the base is before, at the sterno-mastoid muscle; the lower side is formed by the clavicle, and the upper by the omo-hyoid muscle, which extends from the sterno-mastoid to the point of union of the trapezius and the clavicle. But the size of the space will vary according to the height at which the omo-hyoid crosses the neck, as well as from the difference in the extent of attachment of the trapezius and sterno-mastoid muscles to the clavicle; for, in some instances, these two muscles are united together, and attached to the whole length of the bone, so that no space is observable between them. The space is covered in by the integument, superficial fascia, platysma, descending branches of the cervical plexus, and by two layers of the proper cervical fascia; all of which must be divided to reach the subclavian artery. Along the clavicular side, and somewhat concealed by the clavicle, is the transversalis humeri artery, a branch of the subclavian, with its vein of the same name; and crossing the apex formed by the contact of the omo-hyoid and sterno-mastoid muscles, is the transversalis colli artery, a branch also of the subclavian, with its accompanying vein; this last artery and vein divide, immediately external to this, into many branches. The external jugular vein crosses over the omo-hyoid, usually near the sterno-mastoid muscle, and it dips into the space to open into the subclavian vein; it is joined in this part by the transversalis colli and humeri veins which run with the arteries of the same name, and also by a small vein, below the clavicle, from the cephalic vein of the arm. The depth of the space depends upon the position of the clavicle; and the dissector will obtain a just perception of its influence by raising and lowering, alternately, the shoulder; for when the arm is carried upwards, and with it the shoulder, the clavicle is raised above the level of the omo-hyoid muscle, and the depth of the subclavian artery from the surface is proportionally increased. In the area of the space, from before backwards, will be found a portion of the anterior scalenus muscle, which descends from the transverse processes of the lower cervical vertebræ to the upper surface of the first rib: the finger is to be passed along the surface of the muscle to the tubercle of the rib, which is so important a guide to the position of the subclavian artery, close above and to its outer side; next to the muscle is the trunk of the subclavian artery, which comes from beneath the scalenus,

Clavicular portion.

runs downwards and outwards over the first rib, and disappears beneath the clavicle. The dissector cannot fail to observe that any attempts to secure the artery in an operation should be directed downwards behind the clavicle, towards the first rib, rather than directly backwards on a level with the clavicle. Above and to the outer side of the artery is the large brachial plexus of nerves, which descends with the vessel, beneath the clavicle, to the axilla; and it approaches to the artery as this leaves the space; behind the artery and the plexus of nerves, is the posterior scalenus muscle. The *occipital* or upper portion of the triangle, of larger extent than the other, contains, for the most part, the ramifications of the cervical plexus. Its boundaries in front and behind are the muscles before mentioned, and it is separated from the clavicular part by the omo-hyoid muscle. The depth of the space is much less above than below, and in the upper part is placed the complicated interlacement of the cervical plexus, which gives off branches in all directions. Crossing the space with a direction downwards and outwards, is the spinal accessory nerve, which leaves the substance of the sterno-mastoid muscle at its upper and under part, and disappears beneath the trapezius muscle, near where it is attached to the clavicle; this nerve is recognised by its direction, and by its size which is greater than that of the branches of the cervical plexus. Close above the omo-hyoid and near the vertebræ, are the large fifth and sixth cervical nerves, which descend beneath the muscle to join the brachial plexus; and in the lower part of the space, are the transversalis colli artery and accompanying vein, which enter it after they cross beneath the omo-hyoid muscle: the artery divides into many branches to supply the space. A chain of lymphatic glands is situated behind and rather beneath the sterno-mastoid muscle, and they are occasionally found enlarged. Beneath the nerves which issue from the foramina, is the posterior scalenus muscle, which is narrow above, but it widens below, and along its outer border some of the muscles of the back are situated; thus, above, are the splenius and levator anguli scapulæ, and in the hollow below, are the continuation of the levator anguli, the serratus magnus muscle, and the upper angle of the scapula.

Occipital portion.

The portion of the trunk of the subclavian, now dissected, is called the *third part of the subclavian artery*, or the part external to the scalenus muscle; for the subclavian artery, whether it arises opposite the articulation of the sternum and clavicle, as on the right side, or from the arch of the aorta, as on the left, is directed upwards and outwards over the first rib to the axilla; and it is divided into a portion internal to the anterior scalenus, another external to it, and one beneath the muscle. The third part of the artery extends from the outer border of the scalenus muscle, to the lower border of the first rib, at which

Third part of the Subclavian Artery.

point it takes the name of axillary; in this course it is directed downwards and outwards over the first rib, and it forms an arch with the concavity directed downwards to the rib on which it rests. It lies in the space already described as bounded, above and to the outer side, by the omo-hyoid muscle, below, by the clavicle, and in front by the sterno-mastoid muscle; and, at its outer or costal extremity beneath the clavicle, it lies deeper than when near to the scalenus muscle. The artery, in this portion of its course, is at first comparatively superficial, since it is covered only by the integuments, superficial fascia, and platysma, with the cutaneous descending nerves from the cervical plexus, and also by the two layers of the deep cervical fascia; but near its termination it is covered by the clavicle and subclavian muscle, and it is crossed by the transversalis humeri artery and vein, and by the small nerve from the brachial plexus to the subclavius muscle. The artery lies at first on the bag of the pleura, which is received into its concavity, and then on the upper surface of the first rib, which it crosses obliquely. To the upper and outer side of the artery is the brachial plexus of nerves, which approaches closely to it on the first rib; and the last cervical and first dorsal nerves, which enter into the brachial plexus, separate the vessel from the posterior scalenus muscle behind it; below and to the sternal side of the artery is the subclavian vein, which is concealed by the clavicle and subclavius muscle, and it is separated from the vessel by the anterior scalenus muscle. This portion of the subclavian is frequently destitute of any branches; but, in those subjects in which the transversalis colli and humeri arteries are small, and therefore do not supply all their normal branches, one or two large arteries that correspond to either the supra-scapular or posterior scapular will be found to arise from it, and to take the place of the deficient branches.

Cervical Plexus.

The *cervical plexus* is formed by the union of the anterior branches of the four first cervical nerves; but only a portion of it, or the union and plexiform arrangement of the third and fourth nerves that escape from beneath the sterno-mastoid muscle, is visible in the triangle; a division may be made of the branches into superficial and deep; the former, only, can be now seen, and they consist of ascending, descending, anterior, and posterior branches.

Ascending branches.

The *ascending set* of branches are two in number, the auricularis magnus, and occipitalis minor nerves.

Great Auricular Nerve.

The *auricularis magnus nerve*, the largest, is derived from branches of the second and third cervical nerves; it turns round the posterior border of the sterno-mastoid muscle, perforates the cervical fascia, and it ascends over the sterno-mastoid, but beneath the platysma, to about one inch below the lobe of the ear, and in this spot it gives some branches inwards

to the integuments over the parotid gland, whilst others perforate the substance of the gland and unite with the portio dura; the trunk of the nerve afterwards divides into auricular and mastoid branches. The *auricular* ascends in the direction of the ear to its lobe, and it divides into numerous filaments which are distributed, in part, to the posterior surface of the lobule, and ascend on it, as already seen, to supply the back of the concha or the lower half of the posterior surface of the ear; and a few run on the front of the lobule to supply it. The *mastoid*, smaller than the other, sends a deep branch through the substance of the parotid, to join the posterior auricular nerve of the portio dura; and it ascends over the attachment of the sterno-mastoid to be distributed to the integuments.

Auricular branch.

Mastoid branch.

Small Occipital Nerve.

The *occipitalis minor nerve* comes chiefly from the second cervical, it lies at first beneath the cervical fascia, and it ascends along the posterior border of the sterno-mastoid to the occiput; it now perforates the fascia, and, become cutaneous, though external in position to the great occipital nerve, it divides into filaments which are distributed to the integument of the occipital region of the head, and they join with the other cutaneous nerves of this part. There is, not uncommonly, a second ascending branch which is parallel to the auricularis magnus nerve, and it supplies the occipital region as well as a branch to the back of the ear.

Descending branches.

Sternal.

Clavicular.

Acromial.

The *descending set* of nerves consists of three or more branches, which pass vertically downwards between the borders of the sterno-mastoid and the trapezius; one of these lies near the sterno-mastoid muscle, and it divides above the clavicle into small branches, the *sternal*, which cross the attachment of this muscle to the sternum, and are distributed to the integument of the thorax near the sternum. Other branches from the same nerve, or from one of the other descending nerves, are named *clavicular*, since they cross the centre of the clavicle, and they supply the integuments over the middle of the great pectoral muscle; some of these may be traced to near the lower border of the muscle to join with branches from the intercostal nerves. The remaining nerves of this set, the *acromial* branches, are the largest, and they are usually two in number; these descend near the border of the trapezius, turn to its cutaneous surface above its attachment to the clavicle, and they divide into branches that ramify in the integuments of the shoulder.

Anterior branch.

Superficial Cervical Nerve.

There is commonly but one anterior branch from the plexus, and it is named the *cervicalis superficialis nerve;* it is formed by branches of the second and third cervical nerves. It turns round the posterior border of the sterno-mastoid, which it crosses about its centre; it is then directed inwards beneath the external jugular vein, perforates the cervical fascia, and it

divides beneath the platysma into an ascending and a descending branch, which perforate the platysma, and are distributed to the integument; some join also the portio dura, but this distribution will be dissected with the anterior triangle. When the trunk of the superficial cervical nerve is small, a second anterior branch is found with the same distribution as the large nerve to the integument.

Posterior branches. Cutaneous. Muscular.

The *posterior set* are cutaneous and muscular:—the *cutaneous* branches are rather small and insignificant filaments that pass backwards over the edge of the trapezius muscle, and are distributed to the integument; the *muscular* branches are larger in size, and they are directed backwards, across the triangle, to the under surface of the trapezius muscle, to which they are distributed; they join in its substance with the spinal accessory nerve.

Glandulæ conglobatæ.

The glands along the border of the sterno-mastoid are the *glandulæ conglobatæ*, and they form the deep lymphatic glands which are continuous with those in the cavity of the thorax. A superficial chain of glands lies along the external jugular vein.

Dissection.

Repeat the dissection of the posterior triangle on the left side of the neck, previously to turning the body for the back; because the relative anatomy of the parts in it is almost entirely destroyed after the trapezius and levator anguli scapulæ muscles are cut away. This proceeding is also necessary when the head and neck is considered two distinct parts, in order that each dissector may derive his share of advantage from it.* When these dissections are completed, replace the flap of skin; cover the dissected part with some portions of calico moistened in a solution of bichloride of mercury, and fasten it with a few stitches.

DISSECTION OF THE BACK.

Dissection.

Turn over the subject on to the face, and raise the trunk by blocks beneath the thorax, until it is sufficiently high to allow the neck to be made tense, by fastening the head to the table by means of hooks. The pelvis is also to be raised a little with blocks, the lower extremities are to hang over the end of the table, and the upper over its sides. Make an incision along the middle line of the back, over the spines of the vertebræ, from the coccyx to the occipital protuberance; opposite the crest of

* In the instances in which it is not necessary to turn the subject, the anterior triangle of the same side is to be proceeded with, and the description of the dissection of the back is to be omitted.

the ilium make a second, about three inches long, on each side of the spine, or to join that made for the dissection of the abdominal muscles; and, from each extremity, carry an incision upwards, along the side of the thorax, to the posterior fold of the axilla. From the last dorsal vertebra, divide the integuments obliquely upwards and outwards to the spine of the scapula, and along this process to the acromion; and, if the posterior triangle of the neck is not already dissected, it will be necessary, in order to raise this upper flap of integument, to make another incision downwards and forwards from the occipital protuberance to the acromial third of the clavicle. Raise the two flaps of integument marked out by the incisions, and seek the cutaneous nerves in the cellular membrane. In the cervical and in the upper part of the dorsal region, they will be found near the spines of the vertebræ, but, in the lower dorsal, and in the lumbar region, in a line with the angles of the ribs; small cutaneous arteries facilitate the finding of these nerves. To dissect them in the sacral region, in which they are very small, the integument is to be raised from this part; this is generally done by the dissectors of the lower extremities. If it is wished to expose only the muscles, the cellular membrane is to be taken up with the integument from the muscular fibre; and, to dissect both the latissimus dorsi and the trapezius, which form the first layer of the muscles, the flaps are to be raised, from below upwards, in the direction of their fibres, which is marked by the oblique lines of incision made along their outer or lower borders; the upper one corresponding to the border of the trapezius, and the lower to that of the latissimus dorsi.

Cutaneous Nerves. The *cutaneous nerves* of the cervical, dorsal, lumbar, and sacral regions of the back are derived from the posterior branches of the spinal nerves, which, after supplying the muscles of this part, become superficial to be lost in the integument. The general distribution of a spinal nerve is, that it divides into two branches in the intervertebral foramen; that the anterior branches supply the parts in front of the spine, either as separate branches, or previously united, at certain spots, into plexuses, from which branches issue; and the posterior branches not united together, with few exceptions in the cervical and sacral regions, are distributed to the parts behind the spine. The cutaneous nerves vary much in size in the different regions, and the individual nerves of each region have not a uniform proportion to each other; the number of those that perforate the muscles is very irregular, as well as their position to the spines of the vertebræ. In the *cervical region*, the cutaneous branches of the posterior divisions of the lower cervical nerves perforate the trapezius near the spines of the vertebræ, and they turn outwards in the integument, in which they divide into many filaments: they decrease in size from above downwards. But

Cervical.

the distribution of the upper nerves forms an exception to this general arrangement, for the first or sub-occipital nerve does not become cutaneous. The posterior branch of the second cervical gives a very large cutaneous nerve — the occipitalis major — which perforates the attachment of the trapezius to the occipital bone, enters the integuments and turns upwards, with the occipital artery, to supply the occipital region of the head. The cutaneous branch of the third nerve, smaller than the second, divides into two portions, an occipital and a cervical; — the occipital, smaller in size than the great occipital of the second nerve, and nearer the middle line than it, ascends to the integuments of the head, to which it is distributed, as before seen; the cervical perforates the trapezius by the side of the spines, and it is directed outwards to the integuments. In the *dorsal region*, the cutaneous nerves do not perforate the trapezius so regularly as in the cervical, those of one or two spaces being often absent, or so small as not to be found in the common dissection. The branches of the eight upper dorsal perforate the trapezius near the spines, and then turn outwards as long slender branches towards the shoulder; the branch of the second is the largest, and it can be followed outwards to the region of the scapula; these supply the integument over the trapezius. The four lower are situated external to the border of the trapezius, or in a line with the angles of the ribs; they perforate the erector spinæ muscle to become cutaneous; and they then divide into small branches which run inwards to the integument near the spines, and into large descending branches for the integuments of the lumbar and gluteal regions. The *lumbar* cutaneous nerves, very variable in number, perforate the tendon of the latissimus in a line with the branches of the lower dorsal nerves, and the greater number of their branches descend also over the crest of the ilium to be distributed in the gluteal region; some of these descend as low as the trochanter major. The cutaneous branches of the arteries that accompany the nerves are larger in the lumbar region than in either of the others. The nerves of the *sacral region* are very small, and they will be found opposite the foramina in the sacrum, with small cutaneous arteries which are the guide to them; these small branches end in the integuments over the sacrum.

Dorsal.

Lumbar.

Sacral.

Take the cellular membrane from the trapezius and latissimus, and begin, as before directed, in the line of the incisions through the skin; viz. in the direction of a line from the last dorsal vertebra to the acromion, for the trapezius, and from the crest of the ilium to the fold of the axilla, for the latissimus. The arm is to be carried forwards when the latissimus is dissected, and either backwards or forwards, as may be necessary, to put on the stretch the fibres of the trapezius. Some of the cutaneous nerves should be left, that their continuation

Dissection.

beneath the muscles may be more readily and certainly traced.

First Layer of Muscles.

The *first layer* of the muscles of the back, which is formed by the trapezius and latissimus dorsi, is now exposed.

Trapezius Muscle.

The *trapezius muscle*, the most superficial muscle of the back, occupies the cervical, and part of the dorsal region; it is triangular in shape, the base at the spine, but the two muscles, when taken together, form a trapezoid figure. The muscle

Origin.

arises by aponeurotic fibres from the spines of all the dorsal vertebræ, and from their supra-spinous ligaments; from the spinous process of the seventh cervical vertebra, and, between this point and the head, from a ligamentous structure;—the ligamentum nuchæ; and, lastly, from the inner third of the superior transverse ridge of the occipital bone by an aponeurotic attachment. From this origin the fibres pass more or less obliquely; the upper being directed downwards and forwards, the middle almost horizontally, and the lower upwards and forwards towards the tip of the shoulder, where they converge together; and

Insertion.

they are *inserted* into the posterior border of the outer third of the clavicle, into the posterior or upper border of the acromion process, and into the upper border of the spine of the scapula. The lower fibres of the muscle end in a small triangular tendon which slides over the smooth surface on the extremity of the spine of the scapula, previously to its insertion into the upper border of this process. The aponeurotic fibres of origin are seen to differ in length at different points, and when both muscles are dissected, they form a tendinous ellipsis by the sides of the spines of the vertebræ, which extends from the sixth cervical to

Relations.

the third dorsal. This muscle is subcutaneous, and it is crossed only by the cutaneous nerves and vessels of the back. The base, or posterior part of the muscle, looks to the spines of the vertebræ, and to its fellow of the opposite side, and the apex corresponds to the attachment of the deltoid muscle; the lower border is free, and the upper, which varies so much in its extent forwards on the clavicle, bounds, behind, the posterior triangle of the neck. The parts that the muscle covers will be exposed when it is afterwards divided.

Latissimus Dorsi Muscle.

The *latissimus dorsi muscle*, named from its size, is situated in the lumbar region, and in the lower part of the dorsal. It

Origin.

arises, by an aponeurosis, from the spines of the six or seven lower dorsal vertebræ, from all those of the lumbar, from the spines of the sacrum, and the lateral grooves external to these, and from the posterior third of the crest of the ilium; it has also three or four fleshy processes of origin from the last ribs. From the aponeurosis of origin, the fleshy fibres ascend, with a direction outwards, and they join with the three or four fleshy processes of the muscle, which are attached to the last ribs, and digitate with similar portions of the external oblique muscle.

All the fibres converge to the inferior angle of the scapula, and they form a thick muscle which passes over this angle of the bone, from which it often receives a distinct fleshy slip; it is then continued forwards round the inferior costa of the scapula and teres major muscle, and behind the axillary space of which it forms the posterior boundary, to be *inserted* in front of the teres, by a tendon about three inches long, into the bottom of the bicipital groove of the humerus. Where the muscle turns round the lower border of the teres major, the fibres cross each other; the lower fibres ascending to the front, and the upper descending to the posterior part of the tendon of insertion which lies in the interval between them. The muscle is subcutaneous, except above, where it is covered by the trapezius; the cutaneous nerves of the dorsal and lumbar region perforate its aponeurosis in a line with the angles of the ribs. The upper border is partly covered by the trapezius, but near the scapula a space is left between these two muscles, in which the ribs are uncovered, and the intercostal muscles and rhomboid muscle exposed; the lower border is either parallel to the free border of the external oblique muscle, or it overlaps this muscle. The base or inner side of the muscle is united to the spines of the vertebræ, and it corresponds to its fellow. The teres major muscle is covered, at the angle of the scapula, by the latissimus; but, as the latissimus winds round it to its front, it is covered only by the integuments.

Insertion.

Relations.

Divide the latissimus about midway between the spines of the ribs and the angle of the scapula, and reflect the inner part as near to the middle line as is practicable, without raising with it the thin tendon of the serratus muscle which is attached to the lower ribs. In the interval between the last rib and crest of the ilium it cannot be raised farther towards the spines, than to the outer border of its tendon, because of its close union to an aponeurosis — the fascia lumborum — which is placed between the last rib and crest of the ilium. When this muscle is raised, the internal oblique of the abdomen is observed to be attached to the same aponeurosis, the external oblique being usually unattached to it, and removed in the dissection of the abdomen; the cutaneous branch of the last dorsal nerve perforates this muscle, and, near the crest of the ilium, the cutaneous branch of the ilio-inguinal of the lumbar plexus. The internal oblique is to be thrown backwards by detaching it, above, from the lower ribs, and, below, from the crest of the ilium; and the tendon of the transversalis muscle, or the fascia lumborum, is exposed.

Dissection.

The *lumbar aponeurosis*, or *fascia lumborum*, which is the posterior aponeurosis of attachment of the transversus abdominis muscle, occupies the interval between the last rib and the crest of the ilium. It is fixed, above, to the lower border

Lumbar Aponeurosis.

of the twelfth, and to the tips of the two last ribs, and it is continuous, in the interval between the ribs, with the thin aponeurosis between the intercostal muscles; below, it is united to the crest of the ilium, in front of the erector spinæ muscle. The cutaneous surface gives attachment to the internal oblique muscle, sometimes to the external, and to the tendon of the latissimus dorsi; and perforating it, are the abdominal portions of the last dorsal and ilio-inguinal nerves from the lumbar plexus. Each of these nerves then gives off an abdominal branch that runs forwards beneath the internal oblique, and a cutaneous, that perforates this muscle, as before seen; the last dorsal is highest, and it is accompanied by a branch of a lumbar artery; in the interval between the two last ribs, is the eleventh dorsal nerve, with its artery, but they are superficial to the aponeurosis. From the posterior part of the aponeurosis two prolongations are given off to connect it to the transverse processes, and to complete the wall of the abdomen; the superficial, or posterior of the two prolongations, stronger than the other, passes backwards beneath the erector spinæ muscle; and to follow it the tendon of the latissimus is to be divided rather nearer the spinous processes of the vertebræ, than the outer prominent border of the erector, and the border of this muscle is to be raised from a tendinous sheath in which it is contained: in doing this, the cutaneous branches of the lumbar nerves and arteries are seen to perforate this sheath. This layer of the aponeurosis is now observed to pass back, between the quadratus lumborum and erector spinæ muscles, to join the tips of the transverse processes of the lumbar vertebræ, and to fill up the intervals between these processes; it is connected above to the last rib, and it unites below, in the interval between the last lumbar vertebra and crest of the ilium, with the ilio-vertebral ligament. The anterior, or deep prolongation of the aponeurosis, passes on the abdominal surface of the quadratus lumborum to be fixed to the roots of the transverse processes, and to the vertebræ; and it forms, by its connection to the last rib, the ligamentum arcuatum externum; this layer is brought into view by cutting through the prolongation connected to the apices of the transverse processes, rather external to its junction with them, and then turning up the outer border of the quadratus muscle now exposed; this layer is very thin, and it is easily torn through. The quadratus lumborum and erector spinæ muscles are thus incased in sheaths; that for the quadratus being formed, on the side of the abdomen, by the deep or anterior prolongation of the aponeurosis, which is inserted into the roots of the transverse processes, and, behind, by the other prolongation to the apices of the same processes; whilst the sheath for the erector spinæ is formed, on the one side, by the prolongation from the aponeurosis to the apices of the trans-

verse process, and, on the other, or behind, by the united tendons of the latissimus and serratus inferior muscles.

Follow the spinal accessory nerve into the substance of the trapezius muscle, near the scapula, and trace also in it the branches of the cervical plexus, as well as the branches of the small superficialis colli artery, which go to the trapezius. Dissection.

The *spinal accessory nerve*, one of the divisions of the eighth pair, after perforating the sterno-mastoid muscle to which it gives branches, enters the great posterior triangle of the neck; it is here joined by a branch from the second cervical nerve, and it gives a branch to the cervical plexus. The nerve now crosses the space obliquely downwards and outwards, comes into contact with the trapezius near its attachment to the clavicle, and it passes beneath this muscle which it enters, and in which it distributes its filaments; some of these ascend to the upper part of the muscle, but the greater number descend in the direction of the trunk to its lower border. Beneath the trapezius this nerve unites with two or more branches of the cervical plexus, derived from the third and fourth cervical nerves; and, in the substance of the muscle, it joins with some of the filaments from the posterior branches of the spinal nerves. Spinal Accessory Nerve.

The trapezius may now be removed from the muscles beneath, and thrown to the spine; and the spinal accessory nerve and the small superficial artery may be cut through. Beneath the muscle, and opposite the base of the scapula, are the two rhomboid muscles; and to dissect these, the arm and scapula should be drawn from the trunk. The levator anguli scapulæ muscle, to be also examined in the next layer, is the most external muscle on the side of the neck, and it descends to the angle of the scapula. On the same level as the rhomboid, but in the lumbar region, is the serratus inferior muscle; and an aponeurosis that extends upwards from it, over the erector spinæ, is not to be removed. Take away the cellular membrane from behind the clavicle, and from the side of the neck, beneath the trapezius; and the posterior belly of the omo-hyoid muscle, with the transversalis humeri artery and vein, and the suprascapular nerve, which run along behind the clavicle, will come into view; the transversalis colli artery and vein, which lie higher in the neck, will be also seen; a nerve to the rhomboid muscle, which crosses beneath the levator anguli scapulæ, giving it a branch, and another larger one for the serratus magnus muscle, will be perceived to perforate the substance of the posterior scalenus muscle. Dissection.

The *trapezius* conceals, in the neck, the splenius muscle, and a small portion of the complexus above it; external to the splenius, the levator anguli scapulæ, and below it, in the region of the back, the rhomboid muscles, and a small part of Deep Relations of the Trapezius.

the serratus posticus superior which projects above them. Below the rhomboid, it lies on the mass of the erector spinæ muscle, and on the upper part of the latissimus dorsi muscle; near the scapula, on the ribs and intercostal muscles; and, on the dorsum of this bone, on the supra-spinatus, and on a small portion of the infra-spinatus muscle. The branches of the spinal nerves perforate this muscle near its attachment to the spines of the vertebræ. The ligamentum nuchæ, attached to the spines of the cervical vertebræ, is now exposed by the removal of the muscle.

Deep Relations of the Latissimus Dorsi.

The *latissimus dorsi* lies on the erector spinæ near the spines of the vertebræ; on the serratus posticus inferior, on the lower ribs and external intercostal muscles; on the serratus magnus muscle, on the inferior angle of the scapula, and the teres major muscle; and it crosses, near the inferior angle of this bone, a part of the rhomboideus major muscle. The cutaneous nerves are seen to perforate it, like the trapezius.

Ligamentum Nuchæ.

The *ligamentum nuchæ* is a narrow ligamentous structure situated in the cervical region between the trapezius muscle of each side. It extends from the tip of the spinous process of the sixth cervical vertebra to the occipital protuberance; its superficial fibres are the strongest, and from the deep surface processes are sent down to be attached to the spines of the other cervical vertebræ, above the sixth. This structure serves as a partition between the muscles of opposite sides; in some subjects it is much stronger than in others.

Second Layer of Muscles.

The *muscles of the second layer* are the levator anguli scapulæ, the rhomboideus major, and the rhomboideus minor.

Levator Anguli Scapulæ Muscle.

Origin.

The *levator anguli scapulæ muscle*, situated on the side of the neck, *arises* by tendinous attachments from the posterior tubercles of the transverse processes of the four or five upper cervical vertebræ, between the scalenus posticus in front, and the splenius colli behind it. The fleshy fibres, which soon succeed to the tendons, pass downwards; and they unite together to form a roundish muscle, which is rather flattened, from

Insertion.

before backwards, in its lower part, and is *inserted* into the outer edge of the base of the scapula, between the superior angle and spine, or down to the attachment of the rhomboideus

Relations.

minor muscle. The muscle is covered by the trapezius, and, at its origin, by the sterno-mastoid; in front of it is the scalenus posticus. The outer part of the muscle is free in the great triangle of the neck; and it lies on the splenius colli, and cervicalis ascendens muscles; and below this it is in contact with the rhomboideus minor. The rhomboid branch of nerve and the posterior scapular artery pass beneath it.

Rhomboideus minor Muscle. Origin.

The *rhomboideus minor muscle*, the smaller portion of the mass of muscle opposite the base of the scapula, is situated above the major. It *arises* from the spinous process of the

seventh cervical vertebra, and from the ligamentum nuchæ; the fibres pass downwards and outwards, parallel to those of the major, but separated from them by a slight interval, to be *inserted* into the base of the scapula, opposite the spine of this bone. Insertion.

The *rhomboideus major*, a flat and thin muscle, *arises* from the spines of the four or five upper dorsal vertebræ, and from the interspinous ligaments; the fibres have the same direction as in the minor, and they form a muscle which is thicker below than above, and is *inserted* into the inferior angle of the scapula, and also into its base for a short distance; but, above this point, the fibres are connected to a tendinous arch which joins the bone, near its spine, and is connected to the base of the scapula by a thin membrane; some small vessels pass between this arch and the bone. Sometimes this arch extends but a short distance; and, in that case, the muscular fibres are inserted into the base of the scapula. The trapezius covers this muscle above, and the latissimus below, but a part near the inferior angle of the scapula is subcutaneous between these two muscles. It covers the ribs and intercostal muscles; near the spine it conceals the erector spinæ, serratus superior and splenius muscles, but these are more fully exposed when the rhomboid are divided. Rhomboideus major: Muscle. Origin. Insertion. Relations.

The *omo-hyoid muscle* consists of two fleshy portions or bellies, connected together by a tendon beneath the sterno-mastoid; both of them differ in direction and relations, and it is the posterior which crosses the great posterior triangle, and forms the upper boundary of the space containing the subclavian artery, that is now to be examined. The *posterior belly arises* from the superior costa of the scapula, close behind the notch, and also from the ligament that converts this notch into a foramen, the serratus magnus lying internal, and the supra-spinatus muscle external to this origin; the fibres form a thin riband-like muscle which is directed forwards, with a slight inclination upwards, to the clavicle, and it crosses over the transversalis humeri artery, and supra-scapular nerve, and brachial plexus. The muscle now changes its direction, and runs forwards, behind the clavicle, to the anterior border of the trapezius; at this point, the muscle diverges from the clavicle, crosses the lower part of the neck, so as to form the upper and outer boundary of the space in which the subclavian artery is contained; and it joins with the anterior belly beneath the sterno-mastoid by means of an intervening tendon. In its course forwards, behind the clavicle, it is fixed to this bone by a prolongation of the deep cervical fascia; it lies above the transversalis humeri artery and vein, and is partly covered by the trapezius. This belly is crossed, also, by the external jugular vein and transversalis colli artery. Posterior Belly of the Omo-hyoid Muscle. Origin. Insertion.

Transversalis Humeri Artery.

The *transversalis humeri artery*, a branch of the subclavian, has been seen, already, to cross the clavicular side of the small space that contains the third portion of the subclavian artery; the remainder of the artery continues outwards and backwards, along the posterior surface of the clavicle, with its vein, below the omo-hyoid muscle, but parallel to it; and, near the insertion of the conoid ligament, it descends by crossing the subclavius muscle and this ligament, and it approaches the supra-scapular nerve. It now passes backwards, with the nerve, beneath the omo-hyoid muscle, to the notch in the superior costa of the scapula, and it here ends by dividing into the supra-acromial and supra-scapular arteries. The small *supra-acromial branch* perforates the attachment of the trapezius, and it ramifies on the acromion, to anastomose with the infra-acromial branch of the acromial thoracic artery from the axillary. The *supra-scapular branch* enters, above the notch, into the supra-spinal fossa of the scapula, and its distribution to the supra- and infra-spinatus muscles will be dissected with the arm.

Supra-acromial branch.

Supra-scapular branch.

Vein.

The small *vein* that accompanies the artery has the same course and anatomy, and it opens into the external jugular vein, as this is entering the subclavian.

Supra-scapular Nerve.

The *supra-scapular nerve*, a branch of the brachial plexus, arises from the trunk formed by the union of the fifth and sixth cervical nerves, and opposite the outer border of the anterior scalenus muscle. It runs downwards and backwards, behind the transversalis humeri artery, and at a distance from it; and, passing outwards, behind the brachial plexus, it comes into relation with the artery which it accompanies, beneath the omo-hyoid muscle, to the notch in the superior costa of the scapula: the nerve then enters the supra-spinal fossa, by passing beneath the ligament, to terminate in the muscles on the dorsum of the scapula, as the artery, and it will be examined with this vessel.

Transversalis Colli Artery.

The *transversalis colli artery*, another branch of the subclavian, was seen in the great triangle of the neck after it passed from beneath the sterno-mastoid; and it crossed the apex of the clavicular portion of this space. The artery now runs outwards across the neck, and over the scaleni muscles and brachial plexus, but higher up than the transversalis humeri; and, under cover of the trapezius, it divides, near the lower part of the levator anguli scapulæ, into the superficialis colli, and posterior scapular arteries. The *superficialis colli branch*, which has been divided in reflecting the trapezius, gives many branches to the cellular membrane and glands in the triangular space, and also to the levator anguli and trapezius: in the last muscle, some of these anastomose with branches from the occipital; and others descend to the acromion, to anastomose with the infra-

Superficialis Colli branch.

acromial artery. The *posterior scapular*, the other branch of division of the artery, turns beneath the levator anguli near its attachment to the scapula; it then descends beneath the rhomboidei, which may be cut to see it, as far as to the inferior angle of the scapula; and it ends by dividing into many branches to supply the serratus magnus and teres muscles, and to anastomose with some of the posterior branches of the intercostal arteries. On the inferior angle of the scapula, it anastomoses also with branches of the dorsal artery of the subscapular. Posterior scapular branch.

The *vein*, with this artery, has the same name as it; it crosses the posterior triangle in which it receives branches, and it opens into the external jugular vein near its termination. Vein.

The *nerve to the rhomboid muscle*, the upper and smaller of the two nerves that perforate the posterior scalenus muscle, is given off from the fifth or the fourth cervical nerve before it joins with the other nerves in the plexus. It passes through the substance of the scalenus posticus muscle, and, at its external margin, it turns outwards and backwards beneath the levator anguli muscle, to which it gives one or two filaments; it now enters beneath the rhomboid muscles, and it ends in these: some of the filaments can be traced to the lower part of the rhomboideus major. Besides the branch to the levator anguli from the rhomboid nerve, this muscle receives small filaments from the cervical plexus, which enter it at different heights. Nerve to the Rhomboid Muscle. To the Levator Anguli.

The *nerve to the serratus magnus muscle*, larger than that to the rhomboid, is formed by filaments from the fifth and sixth cervical nerves in the scalenus muscle; the nerve perforates the muscle lower down than the rhomboid branch, it descends behind the brachial plexus, and crosses the omo-hyoid muscle to reach the superior costa of the scapula and the serratus magnus muscle; it next continues along the axillary surface of this muscle, distributing filaments to it, which extend to near its lower border: these are traced in the axilla. When the nerve comes into contact with the muscle, it gives some large branches to its upper part. Nerve to the Serratus magnus Muscle.

Reflect the rhomboidei towards the spine, dividing, at the same time, the arteries and nerve that enter it; remove some cellular membrane from a small thin muscle, — the serratus posticus superior, — which is beneath the rhomboid; the serratus posticus inferior, below, is previously dissected, together with the vertebral aponeurosis between the two. Beneath the serratus superior is the splenius muscle, which appears above it, and will be afterwards seen by dividing the serratus. The posterior surface of the serratus magnus will be exposed, beneath the scapula, by removing a dense fascia. Dissection.

In the *third layer* are the serratus posticus superior and inferior muscles, with the splenius muscle, which is divided into splenius capitis and splenius colli. Third layer of Muscles.

Serrati postici Muscles.

The *serrati postici muscles* of this layer, named from their serrated attachments to the ribs, are very thin; the upper one is connected to the superior, and the lower one to the inferior, ribs.

Serratus superior.

Origin.

The *serratus posticus superior arises* from the ligamentum nuchæ, and from the spinous processes of the seventh cervical, and of the two or three upper dorsal vertebræ, by an aponeurosis which occupies half the muscle. The fleshy fibres which succeed are directed downwards and outwards, and they

Insertion.

Relations.

are attached by slips to the second, third, and fourth ribs, external to their angles. It is covered by the rhomboidei, by the levator anguli scapulæ, and by the serratus magnus, which is continued backwards and conceals the muscle when the scapula is carried nearer the spine; it covers part of the splenius, the ribs, and some of the intercostal muscles.

Serratus inferior.

Origin.

The *serratus posticus inferior* occupies the lumbar region; it is a wider muscle than the upper, and its aponeurosis of attachment is so closely united to that of the latissimus dorsi, that they cannot be separated. Its *origin* is by an aponeurosis from the spines of the two last dorsal and the three first lumbar vertebræ; the fleshy fibres directed upwards and forwards,

Insertion.

form wide processes which are *inserted* into the lower borders of the four last ribs, in front of their angles. The size of these processes decreases from above downwards, but the extent

Relations.

forwards on the rib increases. The muscle is covered by the latissimus with which its tendon is united, and it lies on the mass of the erector spinæ muscle, between the spines of the vertebræ and the angles of the ribs. The last ribs and intercostal muscles are covered also by it.

Vertebral Aponeurosis.

The *vertebral aponeurosis* is the fibrous expansion which extends upwards from the inferior serratus; and the fibres of which it is composed are mostly longitudinal, though some are transverse. It is attached, internally, to the spines of the vertebræ; externally, to the angles of the ribs; and it confines the erector spinæ in the vertebral groove. This aponeurosis is united, below, to the upper border of the serratus inferior; but, above, it is continued beneath the serratus superior, and it binds down the splenius: occasionally, it is joined to the upper serratus. The upper part of this aponeurosis and the superior serratus muscle are to be taken away to see the splenius.

Splenius Muscle.

Origin.

The *splenius muscle* is flat and rather wide, and it is placed in the cervical region; it is single, below, at its attachment to the spines of the vertebræ, but it is bifid above, and forms the splenius capitis, and the splenius colli muscles: these are named from their points of insertion. The *origin* of the muscle is from the spines of the four or five upper dorsal vertebræ, from that of the seventh cervical, and from the ligamentum nuchæ, as high as the third cervical vertebra: the lower attach-

ment is the most tendinous. The fibres run upwards and forwards, and they form a flat muscle which, at first single, soon divides into two portions; — the upper, *splenius capitis*, almost vertical in direction, and the largest, ascends to the mastoid process of the temporal bone to be *inserted* into the posterior part of this process, and into the outer part of the superior transverse ridge of the occipital bone and the rough space below it: this insertion lies beneath the sterno-mastoid muscle. The lower portion, *splenius colli*, smaller than the upper, and separated from it by a slight interval, winds outwards round the other muscles of the neck, and it is *inserted*, by tendinous portions, into the posterior tubercles of the transverse processes of the three superior cervical vertebræ, with the tendinous processes of the levator anguli scapulæ in front, and those of the transversalis colli muscle behind. The muscle is covered above by the trapezius, but the serratus superior and rhomboidei muscles separate it from this muscle lower down in the neck; the cranial insertion is covered by the sterno-mastoid, and the cervical by the levator anguli scapulæ muscle. It lies on the complexus which ascends above its upper border, on the transversalis colli, trachelo-mastoid, and longissimus dorsi muscles which belong to the next layer.

Splenius Capitis. Insertion. Splenius Colli. Insertion. Relations.

The posterior surface of the serratus magnus muscle is now perceived to be in relation with the ribs, and also with the scapula, in consequence of the folding of the muscle between its origin and insertion. The anterior surface is seen in the axilla. The serratus posticus superior is partly covered by this muscle, when the scapula is carried backwards.

Serratus magnus.

The next layer of muscles is much more difficult to dissect than either of the preceding, since the muscles are more numerous and less distinct. There is so much variation in the attachment of the tendons of insertion of this layer, that their relative anatomy with reference to vessels, nerves, and other muscles, and the capability of readily recognising and dissecting them, are the chief points worthy the attention of the dissector. To expose the fourth layer, divide the splenius near its attachment to the spines of the vertebræ, and throw the muscle outwards; do the same with the serratus inferior, and remove the vertebral aponeurosis. Clean away the cellular membrane from the surface of the erector spinæ muscle, and from its tendons which are attached to the ribs. The muscular mass of the erector spinæ is single below, and it is situated on the side of the spine, in the interval between the spinous and transverse processes; but opposite the last rib a cellular interval begins to separate it into an outer portion, — the sacro-lumbalis; and an inner, — the longissimus dorsi; some small branches of the intercostal vessels and nerves appear in this cellular interval. Between the spines of the vertebræ and the longissimus, in the

Dissection.

dorsal region only, is a thin muscular fasciculus, which lies on the longissimus, and is called the spinalis dorsi. Separate this small muscle from the rest, by beginning about its centre, and continue the separation downwards, through the aponeurosis of origin common to it and the longissimus; turn it aside over the spines of the vertebræ: next separate the sacro-lumbalis, on the outer side, from the longissimus, by carrying the knife upwards in the cellular interval between the two, and leave uncut some of the branches of vessels and nerves that appear in this space. If the sacro-lumbalis be well turned out, a series of muscular processes — the musculus accessorius — are seen to pass from the angles of the ribs to it; and, at the same time, the thin, flat, external processes of insertion of the longissimus are exposed beneath the sacro-lumbalis. Follow the accessorius up into the neck, where it receives the name of cervicalis ascendens. Isolate now the longissimus from the muscles on the inner side; — the sacro-lumbalis, on the outer, having been removed from it — by separating it from the spines of the vertebræ, close to which it lies; on its inner side it is attached by small tendons to the transverse processes of all the dorsal and lumbar vertebræ; and to see the lowest of these, it will be necessary to cut through the attachment of its cutaneous aponeurosis to the lower dorsal and lumbar spines. These tendons end, above, at the transverse process of the first dorsal vertebra; but the muscle is continued into the neck by a fleshy portion, which is more or less united to the muscular fibres of the longissimus, is single below, like the splenius, and it is also divided above, like it, into a portion for the head, — the trachelo-mastoid; and one for the neck, — the transversalis colli muscle. To the inner side of the longissimus and its prolongation, in the region of the neck, is the large complexus muscle, whose fibres are directed upwards and inwards to the occipital bone; and to the inner side, below, is the multifidus spinæ muscle, with the internal branches of the dorsal and lumbar arteries and nerves. The outer portions of insertion of the muscle have been dissected. The vessels and nerves of the back are to be examined with this layer of muscles.

Fourth layer of Muscles.

The *fourth layer* of the muscles of the back consists, for the most part, of the large erector spinæ muscle that occupies the vertebral groove, and divides into sacro-lumbalis, and longissimus dorsi; the former of these two has an accessorius muscle which is continued into the neck as the cervicalis ascendens, and the longissimus divides, above, into the trachelo-mastoid and transversalis colli. In this layer, too, is the spinalis dorsi, close to the spines of the dorsal vertebræ; and in the neck is the complexus muscle.

Spinalis Dorsi Muscle. Origin.

The *spinalis dorsi*, the thinnest of the muscles of this layer, is found only in the dorsal region, and it is placed by the sides of the spines of the dorsal vertebræ. It is fixed, below, by

tendinous processes, which are continuous with the aponeurosis covering the longissimus, to the spines of the two or three last dorsal, and the two first lumbar vertebræ; the fibres ascend on the side of the spines; they form arches whose concavity is directed inwards, and they are *inserted* by tendinous processes into the spines of the dorsal vertebræ, as high as the first. It is covered by the latissimus dorsi and trapezius; and it lies on the longissimus dorsi muscle.

Insertion. Relations.

The *erector spinæ* is the muscular mass that occupies the vertebral groove of each side; it is single below, but divided into separate portions above; and it is aponeurotic on its cutaneous surface, near the sacrum. The superficial muscular fibres *arise* from the cutaneous aponeurosis which is fixed, in the middle line, to the spines of all the lumbar, and of the two or three last dorsal vertebræ, to their supra-spinous ligaments, and to the processes on the sacrum corresponding to the spinous processes of the other vertebræ; on the outer side, it is connected to the posterior third of the crest of the ilium, and to the processes on the back of the sacrum, which are analogous to the transverse processes of the vertebræ: this attachment on the outer side corresponds to the insertion of the gluteus maximus. The deep fibres of the muscle arise also from the posterior surface of the sacrum, in the interval between the two rows of the processes which are analogous to the spines and transverse processes of the other vertebræ, from the sacro-iliac ligaments, and from the posterior part of the iliac crest. The fibres ascend and form a thick muscle which divides, about opposite the last rib, into the sacro-lumbalis and longissimus dorsi muscles, which ascend, side by side, to their insertions.

Erector Spinæ Muscle. Origin.

The *sacro-lumbalis muscle,* which is smaller than the other portion into which the erector spinæ divides, and the cutaneous muscular fibres of which extend lowest down, ends in a series of flat tendons which are connected together by their margins, and are *inserted* into the angles of the six or seven lower ribs. The tendons which are inserted into the angles of the ribs above this point are smaller than the others, and they are connected to the fleshy and tendinous bundles of the *musculus accessorius ad sacro-lumbalem,* which commences at the angles of the ribs internal to the tendons of insertion of the sacro-lumbalis; and its fibres, after passing over one or two intercostal spaces, end in the tendons which are inserted into the angles of the upper ribs, in a line with those of the sacro-lumbalis muscle, and the upper tendon is inserted into the transverse process of the seventh cervical vertebra. The small muscular slip that continues the accessorius into the neck is the *cervicalis ascendens* muscle. It *arises* by tendinous processes, internal to those of the accessorius, but more or less united with them, from the angles of the sixth, fifth, fourth, and third ribs; and it is *inserted*

Sacro-lumbalis Muscle. Insertion. Accessory Muscle. Cervicalis ascendens Muscle. Origin. Insertion.

into the same number of the transverse processes of the vertebræ of the neck, external to the transversalis colli and complexus muscles.

Longissimus Dorsi Muscle.

The *longissimus dorsi*, the remaining portion into which the erector spinæ divides, is situated nearer the middle line of the body than the sacro-lumbalis, and it is also larger than it. As the muscle ascends to the upper part of the thorax, it becomes small and pointed, and it is *inserted*, externally, by flat thin processes which are attached to the ribs, between their tubercle and angle, except to about the three or four upper, and the two lower; and internally it gives off round tendons which are connected to small roundish bundles of muscular fibres, and are inserted into the transverse processes of all the lumbar, and all the dorsal vertebræ. The portion of muscle that continues the longissimus into the neck, is connected, at its origin, to the fibres of this muscle, and, like the splenius, it is single below, but divided, above, into two muscles, — the transversalis colli and trachelo-mastoid. The *transversalis colli muscle arises* from the transverse processes of the sixth, fifth, fourth, and third dorsal vertebræ by long tendinous attachments, to which the muscular fibres succeed, and form a thin muscle that is united, at first, with the trachelo-mastoid, but it is separate from that muscle above; and it is *inserted* into the posterior tubercles of the transverse processes of the cervical vertebræ, except the last and first. The tendons of origin of this muscle cross those of insertion of the longissimus; and in the neck the muscle is placed between the complexus, internally, and the levator anguli and splenius muscles, externally. The *trachelo-mastoid*, the other muscle of prolongation to the longissimus, is situated internal to the transversalis colli. It *arises*, in common with the transversalis, from the transverse processes of the dorsal vertebræ; and, in the cervical region, it has a separate attachment, by distinct tendons, to the transverse processes of the four last cervical vertebræ. The fibres ascend with a direction backwards, and they form a thin muscle which is placed between the complexus and transversalis colli; and it is *inserted*, by a tendon, into the occipital bone, behind the mastoid process of the temporal, and beneath the sterno-mastoid and splenius muscles.

Insertion.

Transversalis Colli Muscle.

Origin.

Insertion.

Trachelo-mastoid Muscle. Origin.

Insertion.

Relations of the Erector Spinæ and its prolongations.

In the lumbar region, the erector spinæ is covered by the latissimus dorsi, and inferior serratus muscle. It lies on the transverse processes; and it is contained in a sheath formed, before, by the prolongation of the lumbar aponeurosis, which goes to the apices of the transverse processes, and, behind, by the tendons of the latissimus and inferior serratus. In the back, the divisions of the muscle, viz. the sacro-lumbalis and longissimus dorsi, are covered by the trapezius, latissimus, rhomboidei, splenius, and serratus posticus superior; and by the vertebral aponeurosis, which is connected to the spines and

angles of the ribs, and confines the muscles in the vertebral groove. These muscles lie in the vertebral groove, and conceal the ribs, intercostal muscles, and levatores costarum muscles. Between the contiguous borders of the sacro-lumbalis and longissimus, appear the cutaneous nerves and arteries of the intercostals; and between the longissimus and spines of the vertebræ are the multifidus spinæ and semi-spinalis muscles, with other branches of the nerves and arteries. The prolongations of these muscles into the neck are covered by the trapezius and splenius, and partly by the levator anguli scapulæ. The cervicalis ascendens is attached below the splenius colli, and these two muscles form the most external layer of the muscles close behind the levator anguli, or internal to it; next to these, or nearer the middle line, are the transversalis colli, and trachelo-mastoid muscles, which lie, at their insertion into the transverse processes, between the complexus, behind, and the cervicalis ascendens and splenius, on the outer side. The insertion of the trachelo-mastoid into the occipital bone is beneath the splenius and sterno-mastoid, and it is crossed by the occipital artery. Turn outwards the prolongations of the erector spinæ to the neck, to see the complexus muscle.

Complexus Muscle

The *complexus muscle*, situated in the cervical, and in the upper part of the dorsal region, converges to the one of the opposite side near the head, but a considerable interval separates them, below. The lower portion of the muscle, narrow and pointed, *arises* by tendons which are often united with those of the transversalis colli, from the transverse processes of the five or six upper dorsal vertebræ, from the transverse and articular processes of the last four or five cervical vertebræ, and frequently from the spinous processes of the last cervical, and of the two upper dorsal vertebræ. From the tendons of origin the fibres pass upwards and inwards, the inferior more vertically than the superior, to form a flat thick muscle which is *inserted* into an impression on the occipital bone, between the superior and inferior curved lines, and external to the vertical crest of this bone. The fibres from the lower transverse processes form a small muscle, — the *biventer cervicis*, — which, tendinous in the middle, and fleshy at each extremity, is situated along the inner side of the complexus; and it is *inserted* into the occipital bone, internal to the other fibres. The complexus is covered, above, by the trapezius and occipital artery, below that, by the trachelo-mastoid, transversalis colli, and splenius. The inner edge is in contact with the ligamentum nuchæ, and spines of the vertebræ, which separate it from the one on the opposite side; but, in the dorsal region, the semi-spinalis colli and multifidus spinæ intervene between it and the spines. The outer border is in contact with the muscles before seen to be inserted into the transverse processes of the cervical vertebræ;

Origin.

Insertion.

Biventer Cervicis.

Insertion.

Relations.

but above the transverse process of the second it is free from these muscles. About the centre of the cutaneous surface of the muscle is a tendinous intersection; and the posterior branches of the second, third, and fourth cervical nerves perforate the muscle, and appear on this surface. Cut across the complexus near its insertion into the occipital bone, as well as its origin from the spines of the vertebræ, and turn the muscle outwards with care; numerous nerves and vessels, with much dense cellular membrane, are found beneath the muscle; and when the cellular membrane is removed, the muscle may be observed to cover, near the occipital bone, the small recti and obliqui muscles; below this it conceals the semi-spinalis colli and dorsi muscles, and the plexus of nerves formed by the posterior branches of the three first cervical nerves, together with the deep cervical artery.

Dissection. The nerves and vessels of the back are perceived by removing only some cellular membrane. In the dorsal and lumbar regions, the nerves will be found with their accompanying vessels between the transverse processes and the tendons attached to them; since the posterior branches of the spinal nerves, which supply this part, pass directly backwards, between the transverse processes, from the trunk of the nerve that lies in the intervertebral foramen: follow the external and internal divisions of a few of these branches. In the sacral region they will be found coming through the posterior foramina in the sacrum into the substance of the erector spinæ; and in the cervical region there is a marked exception to the distribution of the nerves in the other regions; for the branch of the first or sub-occipital nerve lies in the triangular space between the recti and obliqui muscles, in a quantity of cellular membrane, from which it is difficult to separate it; and it leaves the canal by crossing the posterior arch of the atlas. The posterior branch of the second appears above the arch of the second vertebra, and it turns upwards over the inferior oblique muscle, and through the complexus. The remaining branches of the cervical nerves lie either on the semi-spinalis muscle, on which they form a plexus, or in its fibres.

Nerves. Sub-occipital Nerve. Anterior branch. Posterior. The *first* or *sub-occipital nerve* forms a ganglion on the posterior arch of the first vertebra, and from it are given off an anterior and a posterior branch: the *anterior* passes forwards to join the cervical plexus; but the *posterior* is directed backwards over the arch of the atlas, and beneath the vertebral artery, and it appears in the triangular interval between the recti and obliqui muscles, after perforating the ligament between the atlas and occipital bone. In the area of this space the nerve is enveloped in the dense cellular membrane, and it divides into many branches; two or more of these pass downwards and outwards, and divide into filaments to supply the two oblique mus-

cles; another large branch is directed, upwards and inwards, over the surface of the rectus major muscle which it supplies with branches, and it ends in the rectus minor muscle: the recti may have other small branches from the divisions of the nerve. The branch of the nerve to the complexus muscle is long and slender, it turns over the superior oblique muscle, ascends to the under surface of the complexus, and it is distributed to it near its occipital attachment. Another long filament passes downwards either over or through the inferior oblique muscle, to join the posterior branch of the second cervical, in the posterior cervical plexus.*

Second Cervical Nerve.

The *second cervical nerve* resembles the first in its arrangement, since it forms a ganglion on the upper surface of the axis or second vertebra, from which an anterior and a posterior branch proceed. They both perforate, separately, the ligament between the vertebræ, and diverge from each other; the ligament may be partly removed, on one side, to see the ganglion and its branches. The *anterior* branch turns forwards between the transverse processes of the atlas and axis to join the cervical plexus, and it crosses over the vertebral artery, but beneath the different muscles on the side of the neck, viz. the complexus trachelo-mastoid, splenius capitis, levator anguli scapulæ, and the first inter-transversalis muscle. The *posterior* branch, larger than that of any other of the cervical nerves, appears below the inferior oblique muscle, it next turns upwards over this muscle, perforates the complexus, and the occipital attachment of the trapezius; and, on the back of the head, it takes the name of great occipital nerve, and is distributed to the integuments of the scalp with the occipital artery. As the nerve winds round the inferior oblique, it gives a branch to this muscle; and a larger one transversely outwards, through the substance of the complexus which it supplies, to be distributed in the substance of the splenius muscle: this branch has been cut. The nerve is connected to the sub-occipital by the branch of communication sent down to it; and it gives another branch, beneath the complexus, to unite with the third cervical nerve in the posterior cervical plexus. When the nerve perforates the different muscles to become cutaneous, it gives them some branches.

Anterior branch.

Posterior.

Third Cervical Nerve.

The *third cervical nerve* leaves the spinal canal, like all the other cervical nerves, through the foramen between the transverse processes, and it divides into an anterior and a posterior

* In a very careful dissection of this nerve, session 1839–40, Mr. James Harrison found a large branch that ran outwards beneath the superior oblique muscle, near its attachment to the transverse process of the atlas, came into contact with the occipital artery, which it accompanied; and it joined with the great occipital nerve after this had perforated the complexus. In the same subject, some branches were dissected to the pericranium and occipital bone.

Anterior branch. branch; the *anterior* passes forwards to the cervical plexus between the inter-transversales muscles; but this is not dissected.

Posterior. The *posterior* turns backwards behind the inter-transversales muscles, and between the articulating processes of the vertebra, to reach the posterior surface of the neck; and it passes beneath the splenius, levator anguli scapulæ, transversalis colli, trachelo-mastoid, and complexus, which may be divided to see it. The nerve is then directed to the middle line, or to the spines of the vertebræ, between the complexus and semi-spinalis colli; and it here divides into its occipital and cervical branches, whose cutaneous ramifications have been dissected. The *occipital* branch perforates the upper part of the complexus and trapezius, and is distributed, internal to the great occipital nerve, to the integument of the scalp of the occipital region; the *cervical* passes between the ligamentum nuchæ and the inner border of the complexus, it perforates the trapezius, and supplies the integument of the neck. At the outer border of the semi-spinalis muscle the posterior branch of the third cervical nerve joins with branches from the second in the posterior cervical plexus.

Posterior Cervical Plexus. The *posterior cervical plexus* of nerves, formed by the union of the posterior branches of the three first cervical nerves, is situated between the complexus and semi-spinalis colli muscles, near the transverse processes of the upper cervical vertebræ. Numerous arches result from the division and union of the posterior branches of the three first nerves; and the branches given off from the interlacement or plexus, supply the semi-spinalis, complexus, and splenius muscles, between which it is placed.

Posterior branches of other Cervical Nerves. The *posterior branches* of the remaining cervical nerves are similar to each other in distribution. They turn backwards, like the third, between the articulating processes of the vertebræ, and beneath the same muscles; they appear, in the back, at the outer border of the semi-spinalis muscle, and they are continued inwards to the middle line either through or beneath the fibres of the semi-spinalis muscle, to which they give branches. At the multifidus spinæ, the nerves give off their cutaneous branches, which ascend by the sides of the spines, perforate the attachments of the splenius and trapezius to these processes, and they are distributed to the integuments: the other portions of these nerves enter the multifidus spinæ.

Dorsal Nerves. *The dorsal nerves* are twelve in number; and, like the cervical, they divide in the intervertebral foramina into an anterior and a

Anterior branch. posterior branch. The *anterior* are the intercostal nerves, and they are not now visible; but the *posterior*, for the region of the

Posterior. back, pass between the bodies of the vertebræ and the ascending or anterior costo-transverse ligaments which connect the ribs to the transverse processes of the vertebræ above them; and the

first branch lies in the interval between the transverse processes of the two first dorsal vertebræ, and the last in that between the last dorsal and first lumbar vertebræ. The nerves appear in the back between the transverse processes and the tendons attached to them: thus, as low as the tenth vertebra, they are between the tendons of origin of the semi-spinalis muscle, and the remainder are between the tendons of insertion of the longissimus dorsi. In the upper part of the dorsal region, the nerves correspond to the interval between the semi-spinalis and complexus; but, in the lower, to the space between the multifidus spinæ and longissimus dorsi muscles. Each nerve soon divides into an internal and an external branch, and these are separated by a fibrous process. The *internal division*, larger than the external in the eight upper dorsal nerves, is directed inwards either through the fibres of the semi-spinalis or between it and the multifidus spinæ, to reach the spines of the vertebræ; and, in their course, they supply these muscles with branches: in the middle line they become cutaneous, by perforating the rhomboid, latissimus, and trapezius; but they lie, for a short distance, beneath the trapezius before perforating it. In the four lower dorsal nerves the inner branch is smaller than the outer; they do not reach the surface, but are distributed chiefly to the multifidus spinæ muscle. The *external division*, smaller than the internal, in the eight upper nerves, runs outwards between the transverse processes, over the levatores costarum and beneath the longissimus dorsi, to the interval between this last muscle and the sacro-lumbalis; and it terminates by supplying these muscles and the levatores costarum: the upper of these branches pass also beneath the complexus and transversalis colli muscles. But, in the four lower dorsal nerves, the outer division is the largest; its course is the same as the others; it supplies filaments to the muscles between which it lies, and it gives the cutaneous branch, which perforates the aponeurosis of the latissimus in a line with the angles of the ribs, and much external to the cutaneous branches from the external division of the eight upper nerves: these are distributed to the integument of the lumbar and gluteal regions to which they descend.

Internal division of Posterior branch.

External.

The *lumbar nerves*, six in number, are very similar to the dorsal in their distribution: the *anterior* branch enters into the lumbar plexus; and the *posterior* turns backwards between the transverse processes, internal to a membrane stretched between them; and, between the longissimus and multifidus spinæ muscles, it divides into an external and an internal branch. The *external* division is distributed like the same branch of the four lower dorsal, since it runs outwards beneath the longissimus, which it supplies; it perforates the aponeurosis of the latissimus, and it is directed almost vertically downwards over the crest of the ilium, and in front of the erector spinæ, to supply the integu-

Lumbar Nerves. Anterior branch. Posterior.

External division of the Posterior branch.

Internal. ments. The *internal* is small, and supplies only the multifidus spinæ, as is the case with the four lower dorsal nerves.

Sacral Nerves. The *sacral nerves*, six also in number, differ much from the dorsal and lumbar, since they divide, in the spinal canal, into their anterior and posterior branches which pass out through the Anterior branch. foramina in the front and back of the sacrum. The *anterior* branches are dissected with the abdomen; but the *posterior* are Posterior. seen in the substance of the erector spinæ, after they escape from their foramina, the fifth issuing between the sacrum and coccyx, and the sixth by the side of this last bone. After they leave the canal they send filaments of union to each other, they supply the mass of muscle, and they perforate the aponeurotic surface of the erector spinæ, to ramify in the integument over the sacrum. The posterior branches of the sacral nerves diminish in size from above downwards, and the two last, much the smallest, run outwards, and are distributed to the integuments around the anus.

Arteries of the Back. The *arteries in the back* are the posterior branches of the intercostal arteries of the aorta; the posterior branches of the lumbar, of the aorta; the deep cervical artery from the subclavian; the occipital from the carotid, and a part of the vertebral artery; together with some small branches that issue through the sacral foramina with the nerves.

Posterior branches of the Intercostals. The *posterior branches* of the *intercostal arteries* accompany the nerves backwards between the vertebræ and anterior costo-transverse ligaments; and they lie in the back between the complexus and semi-spinalis, above, and between the longissimus and multifidus spinæ, below. Each artery divides, as the nerve, into an external and an internal branch, and the size of these varies with the difference in the branches of the nerves; Internal branch. thus, in the upper branches, the *internal* division is the largest, supplies the muscles, and sends a cutaneous branch with the External branch. nerve; but, in the lower, the *external* division is the largest, and it supplies the outer muscles, and gives the cutaneous branch. As each artery passes by the intervertebral foramen, it sends a small spinal artery into the canal to anastomose with the spinal arteries of the cord, and supply the cord and its investments. Some small arteries from the intercostals perforate the external intercostal muscle, and supply the sacro-lumbalis muscle. The Posterior branches of the Lumbar Arteries. *posterior branches* of the *lumbar arteries* have the same course as the nerves between the transverse processes, and they divide, in the space between the longissimus dorsi and multifidus spinæ, into external and internal branches; the *external*, the largest, give off the cutaneous branch with the nerve. These arteries supply the erector and multifidus spinæ muscles, and they give Sacral Arteries. spinal branches to the spinal canal. The *sacral branches* of arteries are very small, and they escape from the spinal canal by the posterior sacral foramina; they are derived from branches

supplied to the interior of the canal, mostly from the internal iliac artery, and they supply the erector spinæ muscle: small cutaneous branches go to the integuments. Some small vessels from the gluteal and sciatic arteries ramify on the sacrum.

Occipital Artery.

The course and relations of a portion of the *occipital artery*, a branch of the external carotid, may now be examined. The artery comes from beneath the mastoid process of the temporal bone, and the digastric muscle; it runs backwards nearly to the middle line, parallel to the inferior ridge of the occipital bone; it crosses beneath the sterno-mastoid, splenius, and sometimes trachelo-mastoid, and over the attachment of the superior oblique muscle, and upper extremity of the complexus. Near the middle line it changes its direction; it ascends, perforates the trapezius, and it accompanies the great occipital nerve, to be distributed in the occipital region of the head. In this course the artery gives branches to the muscles between which it lies; and others descend beneath the trapezius to anastomose with the superficialis colli,—a branch to this muscle from the transversalis colli artery; but the largest branch is the *princeps cervicis artery*, which descends beneath the complexus, and anastomoses with the deep cervical and vertebral arteries. Occasionally, the superficial descending branch beneath the trapezius is the largest.

Princeps Cervicis branch.

Vertebral Artery.

That portion of the *vertebral artery* which intervenes between the series of foramina in the transverse processes and its entrance into the skull, lies in the triangular space of the recti and obliqui muscles, near the occipital bone. It is placed on the posterior arch of the atlas, behind the articulating process of this bone, after it has passed through the foramen in the transverse process of the first vertebra; the artery then runs inwards in the triangular space between the muscles, perforates the ligament between the atlas and occipital bone, as well as the sheath of the dura mater that descends into the vertebral canal; and it enters the skull by the foramen magnum, to unite, with its fellow, in the basilar, as before seen. This artery is separated from the arch of the atlas by the ganglion of the suboccipital nerve, and the posterior branch of the nerve lies between the artery and the bone: small branches are given from the artery, in this spot, to anastomose with those of the occipital and deep cervical arteries.

Deep Cervical Artery.

The *profunda cervicis artery*, a branch of the subclavian, runs backwards between the transverse processes of the seventh cervical and the first dorsal vertebra, or between those of the fifth and sixth vertebræ; it then ascends between the complexus and semi-spinalis colli muscles, and near the outer border of the latter, to the upper part of the cervical region, and it terminates by anastomosing with branches of the occipital and

vertebral arteries. It supplies the muscles between which it is placed.

Veins. The *veins* of the dorsal and lumbar regions correspond to the arteries that they accompany, both in their branches and distribution; and they open into the intercostal or lumbar veins. Between the complexus and the semi-spinalis is a large vein with the deep cervical artery; it accompanies the artery between the transverse processes, and opens into the posterior part of the brachio-cephalic vein. The vein of each side commences near the skull, and joins with the occipital; it anastomoses with its fellow opposite the axis, and also with the vertebral veins, and veins of the interior of the spine. Besides these veins there are deeper veins, named *dorsi-spinal*, which closely surround the spinous and transverse processes, and the laminæ of the vertebræ, with a plexus. When these are injected, a longitudinal trunk is seen to extend along the spine on each side of the spinous processes; this gives transverse branches, opposite the intervals between the plates of the vertebræ, to anastomose with each other, and with the veins in the interior of the spine through the intervertebral foramina.

Deep Cervical.

Dorsi-spinal.

Dissection. Most of the remaining muscles of the back are already dissected. The recti and obliqui muscles pass from the atlas and axis to the occipital bone: the recti lie in the middle line. Below these is the semi-spinalis muscle, whose fibres pass obliquely upwards and inwards from the transverse to the spinous processes, and in the same direction as those of the multifidus spinæ, but the fibres are longer and more superficial; and on the inner side of this muscle, and in the intervals between the spinous processes of the cervical vertebræ, are the small round inter-spinales muscles. The multifidus spinæ is seen against the spines of the lumbar vertebræ, but it is concealed above by the semi-spinalis muscle. The inter-transversales cannot be seen now in the cervical region; but, in the lumbar, they form thin muscles between the transverse processes: the erector spinæ may be cut across to see them. The levatores costarum are beneath the sacro-lumbalis and longissimus dorsi; they are small fan-shaped muscles which extend from the apices of the transverse processes to the ribs beneath.

Fifth layer of Muscles. The *fifth layer* includes all the remaining small muscles of the back, and in it are found the recti and obliqui muscles, the semi-spinalis, the inter-spinales, the multifidus spinæ, and the inter-transversales muscles. The levatores costarum, and the external intercostal muscles may be reckoned also in this layer.

Inferior Oblique Muscle. The *obliquus inferior muscle* is small and roundish, it is placed obliquely between the axis and atlas, and it forms the lower side of the triangular space which contains the sub-occipital nerve and vertebral artery.

Origin. It *arises*, below, from the spinous process of the second vertebra or axis, external to the rectus major

muscle. The fibres ascend obliquely outwards, and the muscle is *inserted* into the transverse process of the atlas or first vertebra. The muscle is covered by the complexus, and it is crossed by the posterior branch of the second cervical nerve; it lies on the ligament between the two first vertebræ, and, near its insertion, on the vertebral artery.

Insertion. Relations.

The *obliquus superior muscle* reaches from the first vertebra to the occipital bone; it is narrow at its lower extremity, but wide and expanded above. The *origin* of the muscle is from the transverse process of the atlas, at which point it is united to the insertion of the inferior oblique muscle; its fibres ascend obliquely inwards, and they spread out to be *inserted* into a space on the occipital bone, close above the inferior curved line, and near to the mastoid process of the temporal bone. The complexus and trachelo-mastoid cover this muscle; and its insertion into the occipital bone is beneath the splenius, but above the insertion of the rectus major, which it conceals. The vertebral artery is crossed by this muscle.

Superior Oblique Muscle. Origin. Insertion. Relations.

The *rectus capitis posticus major*, the larger of the two muscles seen in the middle line between the occipital bone and the two first vertebræ, is very oblique in direction; and it *arises* by a pointed portion, from the spinous process of the axis, above the attachment of the inferior oblique muscle to this bone. The fibres ascend to the occipital bone, and they are *inserted*, by a wider portion, into the surface of the occipital bone below the insertion of the superior oblique. It is covered by the complexus, and, at its insertion, by the superior oblique; it crosses the arch of the atlas and the ligament between it and the occipital bone, and covers a part of this bone.

Rectus Posticus major Muscle. Origin. Insertion. Relations.

The *rectus capitis posticus minor*, the smallest of the four posterior muscles, and the only one whose direction approaches a straight line, is triangular in shape. It *arises* from the tubercle on the posterior arch of the atlas, by a narrow pointed tendon, from which the muscular fibres radiate upwards to be *inserted* into the occipital bone, between the inferior curved line and the foramen magnum, and to the side of the vertical crest of this bone. The muscle is covered by the complexus, but not by the rectus major, which, from the obliquity of its direction, lies too much to the outer side. This muscle is placed deeper than the major; and it covers the ligament between the occipital bone and atlas.

Rectus Posticus minor Muscle. Origin. Insertion. Relations.

The *semi-spinalis muscle*, situated beneath the complexus, consists of fleshy and tendinous fibres intermixed; and it assists, by its position, to fill the upper part of the vertebral groove. The fibres extend from the transverse processes of the dorsal vertebræ to the spines of the dorsal and the cervical vertebræ; and they are divided into a semi-spinalis colli and dorsi, though a distinct line of separation is seldom visible. The *semi-spinalis*

Semi-spinalis Muscle.

Semi-spinalis Dorsi. Origin. *dorsi*, the lowest portion of the muscle, *arises* by tendinous attachments from the transverse processes of the six lower dorsal vertebræ, but sometimes not lower than the tenth dorsal vertebra; small fleshy bundles succeed to the tendons, and the muscle is *inserted* into the spinous processes of the four upper dorsal and the two lower cervical vertebræ. The *semi-spinalis colli*, situated in a line above the semi-spinalis dorsi, of which it appears the continuation, *arises*, in like manner with the preceding, from the transverse processes of the six upper dorsal vertebræ. The fibres ascend obliquely inwards, and the muscle which they form is thicker and stronger than the lower portion, and it is *inserted* into the remaining spinous processes of the cervical vertebræ, except the first. These muscles are covered by the complexus and longissimus dorsi muscles, and by the profunda cervicis artery, and posterior cervical plexus. To the inner side and beneath it is the multifidus spinæ, but it is separated by cellular membrane, and the branches of nerves and arteries. The interval of separation between the two semi-spinales muscles is largest near the spines of the cervical vertebræ.

Insertion. Semi-spinalis Colli. Origin. Insertion. Relations.

Inter-spinales Muscles. The *inter-spinales muscles* fill the intervals between the spines of the cervical vertebræ, and they are closely united to the semi-spinalis colli. They are small, elongated, cylindrical muscles, attached, above and below, to the bifurcated apices of the spines of the cervical vertebræ; and there is a pair for each space between the spines, except for the first: the pair of muscles between the spines of the second and third vertebræ is the largest. They lie side by side, but they are separated by the thin inter-spinous ligament; and to their outer side is the semi-spinalis muscle.

Dissection. To expose the upper part of the multifidus spinæ muscle, which is covered by the semi-spinalis, this last muscle is to be detached from the spines, and thrown outwards. Begin the separation of it at the lower part, where the difference in the direction of the fibres is most marked; and if the handle of the knife be first introduced between the muscles, their separation will be more easily effected.

Multifidus Spinæ Muscle. Origin. Insertion. The *multifidus spinæ muscle*, situated deeper in the vertebral groove than the semi-spinalis, extends from the sacrum to the axis; it is much stronger below than above, and the surface is marked, near the sacrum, by tendinous portions. It *arises* from the posterior part of the sacrum, internal to the longissimus dorsi, from the articular processes of the lumbar vertebræ, from the transverse processes of the dorsal, and from the articular processes of the four last cervical vertebræ. From the tendons of origin the fibres proceed upwards and inwards; and, varying in length, they form a fleshy mass which is *inserted* into the spines of the vertebræ, from the sacrum to the axis. This

muscle is concealed, in the loins, by the longissimus dorsi, and in the back and neck, by the semi-spinalis. The posterior branches of the nerves and arteries, for the supply of the back, lie on its outer surface; and its inner rests against the spines and plates of the vertebræ. Relations.

The *inter-transversales muscles*, situated, as their name implies, between the transverse processes, are found only in the cervical and lumbar regions. Those of the cervical region are bifid, like the inter-spinales; but they must remain till another stage of the dissection. The muscles in the lumbar region are single in each space, and are five in number on each side; the first being between the transverse processes of the last dorsal and first lumbar vertebræ, and the last muscle between those of the two last lumbar vertebræ; they are attached, above and below, to the transverse processes. The sacro-lumbalis is in contact with them behind, and the quadratus lumborum in front; but this last muscle is separated by a process of fascia. Inter-transversales Muscles. Relations.

The *levatores costarum muscles* are small fan-shaped portions that *arise* above, by their apices, from the transverse processes of the dorsal vertebræ; from these origins the fibres descend, and spread out to be *inserted* into the upper border and outer surface of the rib beneath. The first is fixed to the transverse process of the last cervical vertebra; and the last to the transverse process of the eleventh dorsal vertebra. The fibres of these muscles correspond, in direction, to those of the outer layer of the intercostal muscles. The cutaneous surface is covered by the sacro-lumbalis muscle, and by branches of the nerves and arteries that are distributed to the back; the inner or thoracic surface is in contact with the intercostal nerve and artery, which may be seen by cutting through one. Levatores Costarum Muscles. Origin. Insertion. Relations.

Sometimes these muscles are connected to a second rib by a slip of muscular fibre continued over the first into which the fibres are inserted; and these have been named *longiores levatores* by Haller.

The *inter-costales externi muscles* may be examined in that part of them which is included in the dissection of the back. They are eleven in number, and they occupy the intercostal spaces; their fibres are attached to the lower border of the rib above, and they descend obliquely forwards to the upper border of the rib below. They are continuous in direction with the levatores costarum, and they are interspersed with small tendinous fibres. The outer layer of intercostals is continued back to the tubercle of the rib, and joins the levatores; it is separated from the inner by a process of membrane, and by the intercostal artery and nerve. The anatomy of the fore part of this external set of the intercostal muscles is seen with the dissection of the front of the thorax. External Intercostal Muscles. Origin. Insertion. Relations.

To follow the posterior branches of the dorsal nerves to their Dissection.

origin from the trunk, and the branches of the artery that accompany them to the intercostal arteries, cut through, with care, the levatores costarum, and the external layer of the intercostal muscles, in one or two intercostal spaces. The intercostal nerve and artery, and a thin aponeurotic membrane, will be seen to separate the external layer of intercostals from the internal. Trace back the intercostal branches to the trunks of both the nerves and arteries.

Dorsal Nerves. Each *dorsal nerve* divides, when it has escaped from the intervertebral foramen, into an anterior and a posterior branch; the

Posterior branch. *posterior* passes backwards between the vertebra and anterior costo-transverse ligament, to the back; and its distribution has been dissected.

Anterior. The *anterior* or intercostal runs forwards in the intercostal space, over the costo-transverse ligament and elevator of the rib; it is then placed between the two layers of the intercostal muscles, and divides about the centre of the intercostal space into a middle intercostal cutaneous, and the branch that continues the nerve forwards to the sternum. This branch of the nerve supplies the intercostal muscles.

Intercostal Artery. The *intercostal artery* has an exact correspondence to the nerve in its course and relations; it gives its posterior branch with the posterior branch of the nerve, it then runs forwards in the intercostal space, and divides, about its centre, into two branches which run along the borders of the ribs to the front of the space, as before seen.

DISSECTION OF THE SPINAL CORD, ITS MEMBRANES AND VESSELS.

Dissection. Now the muscles and vessels of the back are finished, remove the multifidus spinæ from the sides of the spines, and open the spinal canal, by sawing through the arches of the vertebræ, close to the articulating processes; and a chisel and mallet will be useful to complete their separation. The section is not to be carried into the cervical region, since the upper part of the cord has been removed with the brain, but it should extend to the lower part of the sacrum or to the coccyx; on the plates that are removed, the ligamenta subflava and ligaments between the spines will be found, and these may be set aside till they are required. When the canal is opened, scrape away, with the handle of the scalpel, the cellular membrane that is placed between the dura mater and the canal, particularly below, amongst the divisions of the dura mater. In the examination of the spinal cord, in a subject not intended for dissection, the

whole of the canal is to be laid open, and the posterior part of the occipital bone removed by two cuts, directed downwards into the occipital foramen.

The cord is enveloped by three membranes like the brain; an external one of the dura mater; an internal investing membrane, similar in position and use to the pia mater of the brain, but more fibrous than it; and an intervening serous membrane, a prolongation from the arachnoid in the skull.

Dura Mater.

The *dura mater* is a strong, firm tube, prolonged into the spinal canal from the membrane investing the interior of the skull; but it differs from this in not being closely united to the osseous boundaries of the canal, or serving as a periosteum; for, although it surrounds the cord and lines the space of the vertebral canal, it is yet separated from the plates of the vertebræ, behind, by the posterior spinal veins, and from the bodies of the vertebræ, in front, by the anterior spinal veins, and by the posterior common ligament, to which it is united by fibrous processes; but in the upper part of the canal, the dura mater is closely united to the margin of the foramen magnum. The capacity of the tube is larger in the cervical and lumbar regions, than in the dorsal, and a considerable space exists between it and the cord for the presence of the fluid contained beneath the arachnoid. The outer surface is not so rough as that of the dura mater in the skull, and it is surrounded with much fat in both the lumbar and sacral regions. On each side it gives off processes that surround the different nerves leaving the canal by the intervertebral foramina; these accompany the nerves through the foramina and are then lost on them; and, below, the tube divides into several processes or sheaths which inclose the sacral nerves, and lie for some distance in the canal. From the central part of the tube, a thin, slender, fibrous process, now impervious, is continued to the posterior part of the coccyx, to end by joining the periosteum on this bone: this central process is the remains of the portion of the dura mater, which in early life was hollow, and extended to the lower part of the canal. One of the lateral prolongations may be opened to see the nerve contained in it with its ganglion, and by opening the dura mater rather higher up, it will be seen that its tube is larger than the contained cord; that each nerve perforates it by two apertures, one for the anterior and one for the posterior root; and that it is continued beyond the cord which ends opposite the first or second lumbar vertebra. Some small arteries are distributed to this membrane from the branches that enter by the intervertebral foramina; and its veins open into the spinal veins.

Dissection.

Remove the tube of the dura mater, with the contained cord, from the canal, by cutting through the lateral process of it with the nerves as they lie in the intervertebral foramina; detach also the central prolongation from the coccyx, and begin the re-

moval of the cord by cutting through the fibrous processes that connect it to the posterior common ligament of the vertebræ. In a body that is otherwise untouched, the brain should be removed in connection with it, the occipital bone having been divided into the foramen magnum. Place the cord on a board or a table, and fix out with pins the lateral prolongations; raise the dura mater, and divide it with a scissors down to the small central fibrous prolongation before mentioned, but do this carefully, so as not to injure the thin arachnoid membrane beneath; fasten back the dura mater to see the interior surface, which is smooth and shining, from being covered by a layer of the arachnoid.

Arachnoid Membrane.

The *arachnoid membrane* is the thin, transparent, serous covering of the cord, and, like all these membranes, it consists of a visceral and a parietal layer; the *parietal* is inseparably united to the dura mater, and gives to it its smooth appearance; the *visceral* surrounds the cord, but is placed at some distance from it, so as to leave a space, — the sub-arachnoid space of the cord, — which contains the sub-arachnoid fluid. The membrane gives to each side, along the cord, large funnel-shaped prolongations around the roots of the nerves, and smaller ones, between these, around the fibrous prolongations of the ligamentum dentatum; these join the parietal portion on the dura mater, and maintain the continuity of the two. In the lower part of the canal the tube formed by the visceral layer is much larger than above, and it surrounds in one fold the cord, and its different nerves that form the *cauda equina;* but it gives, still, to each nerve, a sheath that accompanies it, and joins the parietal layer when the nerves perforate the dura mater.

Dissection.

A small portion of the cord is to be cut off, and the dura mater having been laid open both before and behind, place it in water with the dura mater pinned out on a piece of board, and with the posterior surface uppermost. If air be gently blown beneath the visceral layer of the arachnoid, the sub-arachnoid space is perceived, and it is found to be divided into a right and left portion by a septum extending along it.

Sub-arachnoid Space.

The *sub-arachnoid space* is the interval between the cord, covered by its proper investing envelope, and the visceral layer of the arachnoid, and across it the vessels and nerves extend as they pass between the cord and intervertebral foramina; and the processes also of the ligamentum dentatum, which intervene between the pia mater and dura mater, are found to be situated in the space. It is much larger in the lower than in the upper part of the cord, it contains the sub-arachnoid fluid, and is divided, as Majendie has shown, by a partition along the middle line; and it communicates with the interior of the brain, by the aperture in the fourth ventricle, as proved by Majendie. Dr. Sharpey considers this space to be lined by a thin membrane

that he describes as a loose serous sac; this is reflected around the cord by its visceral layer, and on the arachnoid by its parietal; it is separable from the arachnoid, and it may be raised with care, as a thin membrane, from the cord, roots of the nerves, and ligamentum dentatum. He suggests, also, that the partition extending along the posterior part of the space is formed by a reflection of this thin membrane, inwards, to the cord; that the sub-arachnoid fluid is secreted by this and contained in it; and that it is continued into the ventricles of the brain, which it lines, by the aperture of the fourth ventricle into the posterior sub-arachnoid space of the brain.*

Pia Mater.

The *pia mater* of the cord is exposed by taking away the arachnoid, after the dura mater has been divided along the extent of the cord, both before and behind. It is a fibrous and vascular membrane that closely surrounds and supports the cord, but its fibrous nature diminishes, above, on the medulla oblongata and pons, and it assumes the character of the cranial portion of the pia mater. The outer surface is rough; to it are attached fibrous processes which connected it to the arachnoid, and numerous vessels run on it; it gives sheaths to the different roots of the nerves, these form their neurilemma and are lost on them. In the front of the cord, and on the outer surface of the pia mater, is a distinct fibrous band which is placed over the anterior spinal artery, and over the anterior central fissure of the cord; on each side is another fibrous band, extending the whole length of the cord, and from it the pointed ligamentum dentatum is derived. From the termination of the cord opposite the first lumbar vertebra, the pia mater is continued, as a round fibrous portion, to the central prolongation of the dura mater, with which it joins, inseparably, in the adult, opposite the upper part of the sacrum, and the cord is thus fixed, below, by means of it to the coccyx. The upper part of this fibrous process contains some medullary matter, but the lower is impervious, and it is accompanied by a vein and an artery, which assist to distinguish it from the surrounding nerves. In early fœtal life, the tube of the pia mater is pervious to the lower part of the spinal canal; it then contains the spinal cord which extends as far, and it is separate from the tube of dura mater that lines the canal to the same extent; but, with the change of position of the cord, the tube diminishes, becomes impervious, and it is finally united, inseparably, to the contracted dura mater. The vessels of the cord ramify in this membrane before they enter the substance of the cord, and it gives from its inner surface vascular prolongations to line both the anterior and the posterior central fissures of the cord, and to supply vessels to it.

* From the MS. notes of Dr. Sharpey, before referred to.

Ligamentum dentatum.

The *ligamentum dentatum*, named from its appearance, consists of a white fibrous band, which is situated along each side of the cord, between the anterior and the posterior roots of the nerves, and it is united, internally, with the fibres of the pia mater, and externally, by a series of pointed, tooth-like processes to the dura mater; this band terminates, above, on the medulla oblongata; it is narrow below, and it gradually ends on the lower extremity of the cord. There are twenty or twenty-one of these tooth-like processes, the first being fixed to the dura mater opposite the margin of the occipital foramen, between the vertebral artery and hypoglossal nerve, and the last opposite the twelfth dorsal or first lumbar vertebra. Each is triangular in shape, the base being connected to the fibrous band on the cord, and the apex to the dura mater, in the intervals between the apertures of transmission for the roots of the nerves; each is covered by the tube of the arachnoid, and it is nearer to the anterior than to the posterior roots of the nerves.

Spinal Cord.

The *medulla spinalis* or *spinal cord*, the spinal portion of the great nervous centre, is a symmetrical, and a somewhat cylindrical body, situated in the spinal canal, and enveloped by the membranes before examined. Its size is not equal to that of the canal, so that the different motions of the vertebræ do not compress or injure the cord; and it is maintained in its position by the processes of the ligamentum dentatum, and by the central prolongation from the lower part. The extent of the cord is from the level of the first vertebra, or — if the medulla oblongata is considered a part of the cord — from the lower border of the pons, to the level of the first or second lumbar vertebra; and it ends, at this part, in a pointed process which is prolonged, by the remains of the tube of the pia mater, to the lower part of the spinal canal; but, in the early periods of uterine life, the cord descended to the extremity of the canal. The size of the cord varies in the different regions of the spine: thus, it is dilated above in the medulla oblongata; in the cervical region, a second enlargement is found on it, opposite the nerves given off for the supply of the upper extremities, and this extends from the third cervical to the third dorsal vertebra; and the last increase in size, which is not so considerable, commences opposite the eleventh dorsal vertebra, and it corresponds to the origin of the nerves of the lower extremities from the cord. The anterior surface of the cord, enveloped by its sheath of pia mater, is marked by oblique and transverse lines or folds; and it is distinguished from the posterior by the fibrous band extending along it; by the central anterior spinal artery; and by the origins of the anterior roots of the nerves, which are smaller than the posterior, and nearer the middle line, particularly below. On the posterior surface are seen small

arteries that enter the canal, at different distances, by the intervertebral foramina.

Roots of the Spinal Nerves.

The *spinal nerves*, thirty-one in number, are divided into eight cervical,—the sub-occipital being included in this number,—twelve dorsal, five lumbar, and six sacral. They arise from the cord by anterior and posterior roots, which resemble each other in the general arrangement of origin, course, and distribution; but those of one region differ, more or less, from those of another: the processes of the ligamentum dentatum are placed between the anterior and posterior roots.

Posterior.

The *posterior* or *gangliated roots*, larger, and formed by more filaments than the anterior, are attached by numerous filaments to the lateral part of the posterior surface of the cord, in a line which will be afterwards seen to be opposite the division of the cord into a posterior and an anterior portion, and they continue to the lower part of the cord without deviation to either side. The filaments of origin pass outwards to the intervertebral foramen, and they converge, to unite into two bundles for the posterior root of each spinal nerve: these are surrounded by a fold of the arachnoid, in common with the anterior root, which extends as far as the dura mater, on which it is finally reflected. The posterior root of the nerve then passes through an aperture in the dura mater, distinct from the one for the anterior, and it enters the intervertebral foramen, and forms a ganglion; the root finally unites, beyond the ganglion, with the anterior root, to give rise to a spinal nerve. The two bundles of this root, into which the filaments of origin are collected, do not enter indiscriminately into all the ganglia; but in the lumbar and sacral nerves there is a small ganglion on each bundle, and these are united together by their outer extremities in the large ganglion of the posterior root.*

Anterior.

The *anterior roots*, consisting of filaments fewer in number, and smaller than the posterior, arise from the lateral part of the front of the cord, but not in a straight line; for in the lower part of the cord they approach close to the median line. The filaments of origin pass outwards in the common tube of arachnoid, converge, as the posterior, to their aperture in the dura mater opposite the intervertebral foramen, and they unite into one bundle for each nerve; this passes outwards by the ganglion, being closely applied to it, and in some instances united to it, to join with the posterior root beyond the ganglion; and by their union they form a spinal nerve which divides, in the foramen, into an anterior and a posterior branch for the supply of the trunk and the extremities. In the lower part of the spinal canal the filaments of origin of the roots do not converge to their apertures of transmission, but they lie parallel to each other, because of the distance they run in the

* This is noticed by Swan, in vol. xiv. of the *Medical Gazette*, p. 848.

canal; and from the resemblance of the lower part of the cord, when surrounded by these, to a horse's tail, it is named *cauda equina:* the ganglia, also, are placed in the interior of the canal. Occasionally, the filaments of origin of the anterior roots join with those of their own root, or with those of the nerve above or the nerve below, but not with the filaments of the posterior root: the same takes place with the posterior filaments.

Filaments of the Roots in the Cervical Region.

The *filaments of origin* of the roots of the nerves, *in the cervical region*, increase in size from the first to the last; they are directed downwards and outwards, the obliquity increasing with each nerve, so that the lower filaments arise a vertebra above their point of exit, whilst the upper are transverse; and the posterior filaments are larger than the anterior. In the first, or suboccipital nerve, there is an exception to the arrangement of the filaments of the other nerves, since they are directed upwards and backwards to join the ganglion of the nerve on the arch of the atlas; its posterior filaments are smaller than the anterior, and they are connected to the spinal accessory nerve. The second nerve, in like manner, forms its ganglion on the arch of the axis, instead of in the space between the transverse processes, and the filaments are directed back to it as in the first nerve.

In the Dorsal.

In the *dorsal nerves* the filaments are fewer than in either the lumbar or the cervical nerves, their attachment to the cord is irregular, and the difference in size between the anterior and the posterior roots is scarcely marked; but their obliquity is greater than in the cervical region, and the lower filaments extend for the distance of two vertebræ before they leave the canal. The filaments of the upper nerve resemble those of the last cervical; and those of the last nerve are slightly larger than the rest.

In the Lumbar and Sacral.

The filaments of origin of the anterior and posterior roots in the *lumbar* and *sacral nerves* are, with the exception of some of the last sacral, larger and more numerous than those of the other regions, but the different filaments of the anterior set are of nearly the same size as the posterior; the filaments do not come in so regular a line from the cord, for the anterior arise close to the median groove, but the posterior are separated from it by an interval, and they arise in a continued line along the cord. The extent of canal occupied by these filaments is much greater than in the nerves of the other regions, since they reach from the lower part of the dorsal region to the lumbar vertebræ and sacrum: the filaments in this course are vertical and parallel to each other, and the ganglia belonging to them are found in the interior of the canal. In the two last sacral nerves the filaments are much smaller than in the rest.

Spinal Arteries. Anterior.

The *spinal arteries* are anterior and posterior: the *anterior* is a single artery, placed, in the middle line of the cord, beneath the fibrous band on the anterior surface. It commences, above,

at the medulla oblongata, by the union, in one trunk, of the two anterior spinal arteries which are branches of the vertebral; and, in its course along the cord, it receives accessory branches from the ascending cervical and vertebral arteries in the neck; from the intercostal in the back, and from the lumbar in the loins: these branches enter through the apertures in the dura mater for the nerves, and they continue the anterior median artery to the extremity of the cord, and along the central fibrous prolongation of the pia mater. This artery gives some branches to the median fissure, and others to the surface of the cord, from which small arteries are distributed to its substance. The *posterior* arteries, one on each side of the cord, are derived, above, from the vertebral, and they are continued along the cord by the branches sent into the spinal canal from the same vessels that supply the anterior in the neck, back, and loins. These branches enter with the nerves, and on the side of the cord they divide into ascending and descending arteries that anastomose with branches above and below, and so the trunk of each posterior spinal is continued to the extremity of the cord; other branches ramify on the surface of the cord around the roots of the nerves, and they anastomose with the arteries of the opposite side. The upper dilated part of the cord, or the medulla oblongata, receives its two posterior spinal branches from the vertebral arteries; and these anastomose, below, with the lateral branches sent through the intervertebral foramina. Posterior.

The *veins* on the surface of the cord are very tortuous, the greater trunks are behind, and most of them issue from the posterior median fissure. Opposite each pair of nerves, a branch passes outwards, with the roots, to join the veins of the spinal canal in the intervertebral foramina. Veins.

The portion of the cord obtained from the spinal canal in this stage of the dissection is too decomposed to serve for the examination of the structure of the cord; and therefore a very fresh portion of cord is to be taken, or a portion hardened in spirit is preferable. Detach the pia mater from the surface of the cord to see its structure, and leave connected to it some of the filaments of the roots of the spinal nerves. Dissection.

The *medulla spinalis* or *spinal cord*, when deprived of its investing membrane, is seen to be divided, by an anterior and a posterior fissure, into two halves which are united in the middle line by a central connecting portion; and to each half the nerves are attached. The *anterior fissure* or sulcus, wider and larger than the posterior, is occupied by a fold of the pia mater, and it penetrates to about one third of the thickness of the cord. A thin medullary layer lines the fissure, it is perforated by many apertures, for the transmission of the vessels which enter the substance of the cord, and, in the bottom, its Divisions of the Spinal Cord. Anterior Fissure.

fibres are transverse: this medullary layer has been called the anterior commissure. The *posterior fissure*, as deep as the anterior, but not so wide, contains also a thin fold of pia mater; and in it, the fibres of the medullary layer that lines it are longitudinal. Each half of the cord is divided into two portions by a sulcus along the line of attachment of the posterior roots, the part in front of the sulcus is the *antero-lateral division* and the part behind the *posterior division* of the cord. The posterior division is marked by a slight groove near the posterior median fissure, which, according to some, separates from it a small band,—the *posterior median cord;* this cord, placed on the side of the median fissure, is continued upwards into the posterior pyramid. Along the line of attachment of the anterior roots to the antero-lateral division, before the pia mater is removed, there is a slight groove, but this disappears afterwards. Some distinguished physiologists, as Bell and Bellingeri, have divided each half of the cord into three nearly equal portions; an anterior, comprised between the anterior median fissure and the anterior roots; a posterior part, between the posterior median fissure and the posterior roots; and a lateral portion, between the lines of attachment of the anterior and the posterior roots. The functions of the separate divisions of the cord are not satisfactorily ascertained.

Posterior Fissure.

Antero-lateral Division.

Posterior Division.

Posterior median Cord.

A horizontal section of the cord shows each half to be a cylinder of white medullary substance, which contains in its centre grey or cineritious matter; and the two halves of the cord to be united, in the middle line, by a central portion or commissure. The sulci and divisions of the cord are now better seen; the anterior two thirds of it forming the antero-lateral division; the posterior third of it, the posterior division; and a part of this last, near the middle line, constituting the posterior median cord. The *grey matter* contained in the centre is disposed in the form of two semilunar masses, one for each half, and these are connected by a central transverse portion. Each semilunar portion is convex internally towards the one in the opposite half of the cord, and the two are united together by the transverse portion of the grey matter, or by the grey commissure; the anterior extremity of each, larger than the posterior, and round, is directed forwards to the line of attachment of the anterior roots, without however reaching these; and the posterior, small and pointed, projects back to the lateral groove which divides the half of the cord into its two unequal portions, or to the origin of the filaments of the posterior roots.* The *commissure* or transverse portion between the halves of the cord

Structure.

Grey Substance.

Commissure.

* Mayo describes these portions of grey matter as having a dentate margin, and in their interior white matter, from which circumstance he calls each a *corpus dentatum.*

is formed, in the centre, by the transverse grey band or commissure which intervenes betweeen the grey masses in the halves of the cord; and this is covered, before and behind, by a layer of the medullary matter that lines the anterior and posterior fissures of the cord. The exterior medullary substance of the cord consists of plates or laminæ, with longitudinal fibres, placed side by side, and which Rolando supposes to be but a single layer bent in a sinuous or wavy manner.

Deep Origin of the Spinal Nerves.

The *deep origin* of the filaments of the roots of the spinal nerves from the cord is uncertain, and the opinions of the best authorities on this subject do not coincide. Thus Bell says that the filaments of the anterior roots arise from his anterior division of the cord, or from the part between the anterior median fissure and the line of attachment of the filaments of this root; and that the filaments of the posterior come from the lateral division of the cord or the part between the attachments of the anterior and the posterior roots: so that the filaments of both roots are united to the antero-lateral division of the cord. Bellingeri states that the filaments of each root have three points of connection to the cord: the anterior being attached to the same anterior and lateral divisions of the cord that Bell describes, as well as to the anterior part of the semilunar grey mass; and the posterior filaments being connected to the posterior and lateral divisions of the cord, and also to the posterior peak of the semilunar grey mass.*

Dissection.

The spinal arteries and veins may be partially seen, in the canal, but they have been unavoidably injured in opening it and in removing the cord. The veins of the spine are not very visible unless they are congested; but to make a perfect dissection of these, they should be injected, before opening the canal, by means of the lumbar, intercostal, and vertebral veins.

Intra-spinal Arteries.

The *intra-spinal arteries*, branches of the vertebral and ascending cervical in the neck, of the intercostal in the back, and of the lumbar in the loins, enter the spinal canal by the intervertebral foramina; and they divide, after giving off a branch to supply the cord, into an ascending and a descending branch, which anastomose with corresponding branches both above and below; and from the convexity of the arches formed in this manner, two branches pass transversely inwards, one above and one below the apertures in the posterior part of the bodies of the vertebræ, to anastomose with similar branches from the opposite side: branches are given off to the bodies of

* Mr. Grainger, in his *Observations on the Structure and Functions of the Spinal Cord*, London, 1837, states that the filaments of both the anterior and the posterior roots are united to the middle division of the cord; that those of the anterior roots arise also from the front of the grey mass; and that those of the posterior roots are connected, in addition, to the posterior peak of grey matter.

the vertebræ from these transverse arches, and they anastomose with small arteries that enter the anterior surface of the bone.

Intra-spinal Veins. The *intra-spinal veins* are very numerous, and they consist of two anterior longitudinal veins which extend from the occipital bone to the base of the coccyx, and are connected together by transverse branches,—the transverse plexuses; and of posterior spinal plexuses in contact with the plates of the vertebræ. In the cervical and sacral regions these veins are the smallest.

Anterior Longitudinal. The *anterior longitudinal,* two in number, are placed close to the posterior surface of the bodies of the vertebræ, one on each side of the posterior common ligament; they are connected together, opposite the body of each vertebra, by the *transverse* Transverse. *plexuses* which pass beneath the ligament, and receive the small veins from the bodies of the vertebræ; the longitudinal veins are joined by transverse branches from the posterior plexus, opposite the intervertebral foramina, and branches are sent through these apertures to join the lumbar, dorsal, and cervical veins, on the exterior of the spine. The *posterior spinal* Posterior Plexuses *plexuses,* one on each side, beneath the plates of the vertebræ, are smaller than the anterior veins; they communicate with each other by transverse branches,—the *posterior transverse* Transverse. *plexuses,* and also with the anterior longitudinal veins, by lateral branches.

THE ANTERIOR TRIANGLE OF THE NECK.

Dissection. The subject is now turned again on the back, the shoulders are to be raised by blocks, and the head is to be turned to the left side, and fixed backwards with hooks, as before directed for the dissection of the posterior triangle, in order that the remaining part of the neck may be completed. If the thorax should have been already finished, the head and neck may be separated from the trunk, by dividing the spine, in the interval between the second and third dorsal vertebræ, so as to leave the clavicles and first ribs undisturbed in their relations, and the neck is to be rendered tense by fastening it with hooks, over a small narrow block, in the position explained above. In either case, continue with the dissection of the anterior triangle of the neck: raise the portion of skin in front of the sterno-mastoid to the middle line, the incision along the base of the jaw readily allowing this. Close beneath the skin is the superficial fascia, and the ramifications of the superficial cervical nerve which perforates the platysma, are found in it: dissect out the nerve, and then clean the fibres of the platysma, and beneath the platysma is the cervical

portion of the portio dura, which joins with the superficial cervical nerve.

The *cervicalis superficialis nerve*, one of the anterior cutaneous branches of the cervical plexus, passes forwards over the sterno-mastoid, and divides beneath the platysma into its ascending and descending branches; the *ascending*, the larger of the two, divides into branches which perforate the platysma, and subdivide in the superficial fascia into many filaments, which radiate over the upper part of the anterior triangle, and extend as high as the chin and side of the jaw. Some of the filaments of this nerve join with cutaneous filaments of the portio dura, which perforate the platysma, and one or two remain beneath the muscle, and run with the external jugular vein. The *descending branch* perforates also the platysma, and divides into branches that are distributed to the integuments of the lower part of the front of the neck. This nerve is more superficial than the portio dura which is situated beneath the platysma. Superficial Cervical Nerve.

The *platysma myoides muscle* will be seen if the cellular membrane that covers it has been removed from it. It covers the side of the neck, from the sterno-mastoid to the jaw, in the same manner that it did, by its lower portion, the interval between this muscle and the shoulder. The fibres have the same appearance also, in this upper half, as they had in the lower; but they are rather stronger; they are directed obliquely upwards and inwards, and at the base of the jaw, the most internal fibres are *inserted* into the integument near the middle line; the most external, to the oblique line on the side of the jaw, and the intervening ones join the depressor anguli, and quadratus menti muscles, at their insertion into the side of the lower jaw. This part of the muscle is subcutaneous, and it is crossed by the cutaneous nerves of the superficial cervical nerve. It covers in the upper part of the anterior triangle, across which it is stretched, and it conceals the branches of the portio dura. Raise this muscle to the line of the jaw, and the ramifications of the portio dura, and the deep cervical fascia come into view. Platysma Myoides Muscle. Insertion. Relations.

The *cervical branches* of the *cervico-facial* division of the portio dura nerve, which passed below the level of the jaw, are now exposed, and, with these, the anatomy of the cutaneous part of the portio dura is completed. The nerves pass downwards and inwards over the side of the upper part of the neck, and they descend as low as the os hyoides; many turn forwards to the chin, and form arches parallel to the branches of this nerve above the base of the jaw. The divisions of this nerve lie superficial to the deep cervical fascia, but beneath the platysma, to which most of the branches are distributed; one or two branches, from it, descend beneath the platysma, to join the superficial cervical nerve of the cervical plexus, and some perforate also the platysma, to join, by very minute filaments, the Cervical branches of the Portio dura.

ramifications of the same nerve. This nerve chiefly supplies the muscle, whilst the preceding was distributed mostly to the integument.

Deep Cervical Fascia.

The *deep cervical fascia* is continued forwards from that covering the posterior part of the neck, and it incases the parts in front of the sterno-mastoid. In the upper part of the neck the fascia is thin and weak at its attachment to the jaw; but in the middle line, near the sternum, it is a white firm band, which is fixed to the upper part of this bone, and occupies the interval between the sterno-mastoid muscles. It sends processes inwards between the muscles, which become, for the most part, thin and cellular, and serve only as partitions between them: the layer which lies beneath the sterno-mastoid is stronger, it is connected to the sheath of the vessels beneath it, and passes upwards to be attached to the styloid process and ramus of the jaw, to form the stylo-maxillary ligament. A deep layer of the fascia descends also into the upper part of the thorax, and is lost on the brachio-cephalic vessels.

Dissection.

Raise the fascia to the middle line; the anterior jugular vein will be observed near the middle line, and the great anterior triangle will be partially seen; but, to obtain a good view of it, all the cellular membrane that it contains must be carefully removed, so as not to injure the numerous nerves and arteries, or displace the relations of any of the parts. A large artery — the carotid — with its accompanying vein, appears from beneath the muscles, and lies in the centre of the space, and the sheath that conceals them is to be taken away; but, in doing this, the dissector will find a small nerve — the descendens noni — which is a branch of the ninth, and lies, generally, in front of the sheath; it distributes small filaments to the muscles on the inner side. Opposite the thyroid body, the artery divides into two large branches, and many smaller branches are given from the internal one, particularly in the upper part of the space. A large nerve — the hypoglossal — crosses the artery a little above the os hyoides, with the digastric and stylo-hyoid muscles; a plexus of veins, that joins the jugular vein, covers also the artery. Close beneath the side of the jaw, is the submaxillary gland; and, on the inner side, below the os hyoides, are the superior thyroid vessels, with the superior laryngeal nerve; this nerve gives off a small branch — the external laryngeal — which descends with the artery, and it will be found beneath the muscles in the middle line. The upper part of the triangle has been cleaned out, by removing the parotid, in the dissection of the portio dura nerve.

Anterior Jugular Vein.

The *anterior jugular vein*, the small vein beneath the fascia in the middle line of the neck, commences in some small veins below the chin, and it descends to the sternum; it is then directed transversely outwards beneath the clavicular origin of the sterno-mastoid muscle, and it joins the subclavian vein,

nearer the middle line than the opening of the external jugular into the same vessel. This vein receives some small branches from the front of the neck, and small laryngeal veins, and it has branches of communication with the external jugular vein. The veins of opposite sides are joined by a small transverse branch, at their point of divergence from each other to open into the jugular veins. There are usually two anterior jugular veins, but it often happens that only one is much developed.

Anterior Triangle.

The *anterior triangle* of the neck is not so deep as the posterior, but its surgical importance is greater, since the carotid artery or its branches extend through it from base to apex, instead of through only a portion, as in the other triangle. The extent of this space is, from the jaw to the sternal end of the clavicle; the anterior boundary is the middle line, the posterior the sterno-mastoid; the base is the side of the jaw, and a line prolonged from this to the mastoid process; and the apex is, below, at the sternal end of the clavicle and sternum. The upper part of the space beneath the angle of the jaw is deep, but it is filled below, by the omo-hyoid, sterno-hyoid, and sterno-thyroid muscles, which conceal the carotid artery. Across it are placed the skin, superficial fascia, platysma, branches of the portio dura and superficial cervical nerves, which have been removed. The space is divided, like the posterior, into an upper and a lower portion, by the digastric and stylo-hyoid muscles, which extend obliquely across it from the styloid process to the os hyoides. A line drawn obliquely from the mastoid process to the os hyoides would indicate this division. The *lower portion* of the space, larger than the upper, is bounded behind by the sterno-mastoid, in front by the middle line, and above by the digastric and stylo-hyoid muscles, and the cornu of the os hyoides. In the area of the space, below, are the small muscles that ascend to the os hyoides, and they reach as high as the cricoid cartilage of the larynx, and conceal the common carotid artery which is still beneath them; but, above this cartilage, they leave the artery exposed, since the omo-hyoid and muscles from the sternum to the os hyoides pass inwards, and the sterno-mastoid outwards, and the vessel is covered only by the superficial parts that extend across the space. Above the muscles, the trunk of the common carotid is very superficial in this portion of the triangle, and it divides, opposite the upper border of the thyroid cartilage, into two large trunks which lie side by side, and ascend, beneath the digastric and stylo-hyoid, into the other portion of the space; the internal of the two is called external carotid, since it supplies the outer parts of the head and neck; and the external in position is named internal carotid, because it is distributed to the parts within the skull. These arteries have the same relation to each other till they have passed beneath the digastric,

Lower portion.

but above this muscle the external carotid is more superficial than the internal. In close contact with the internal carotid artery, and contained in a sheath with it, is the large internal jugular vein, which partly lies over the artery, and receives branches which pass beneath the digastric, but are superficial to the external carotid: these correspond to branches of the external carotid, which are supplied to the neck. Between the internal carotid and jugular vein, but deeper than they, is the pneumo-gastric nerve of the eighth pair, which lies in the same sheath as the vessels; to the outer side of the vessels and their sheath, is the spinal accessory nerve of the eighth, it appears from beneath the digastric muscle, descends for a short distance along the outer side of the vessels, and it leaves the space by perforating the sterno-mastoid muscle, in its upper third, to reach the trapezius. Crossing both carotid arteries, so as to form an arch below the digastric muscle, is the hypoglossal nerve; this comes forwards between the internal jugular vein and internal carotid artery, turns round the occipital artery below the digastric, and it is then directed forwards and inwards superficial to both vessels; it leaves the space, in front, by ascending, with the lingual artery, beneath the digastric, to enter beneath the small muscles between the jaw and os hyoides. As this nerve crosses the neck, it gives off the small descendens noni, which lies in front of the sheath of the vessels, though sometimes in it, and supplies the small muscles ascending to the os hyoides. The external carotid gives off numerous branches for the supply of the head and neck, and some of these arise in this lower portion of the anterior triangle, and others in the upper; the first branch is the superior thyroid, which runs inwards and downwards to the thyroid body; it is accompanied by the superior laryngeal nerve, — a branch of the pneumo-gastric, — which escapes from beneath the large vessels, and enters the larynx. The descending branches of this artery are accompanied by a very delicate nerve — the external laryngeal, — a branch from the superior laryngeal to the thyroid body. From the inner side of the artery, above this, is the lingual branch which passes, with the hypoglossal nerve, beneath the digastric muscle; from the front of the artery arises the facial, and it runs also beneath the digastric, and through the submaxillary gland to the face; and from the back of the artery comes the occipital branch: this ascends parallel to the external carotid, but behind it, and round it the hypoglossal nerve turns. In front of the vessels are the cricoid and thyroid cartilages of the larynx, and on the side of the thyroid, which is the highest, is the thyroid body, covered by the thyro-hyoid muscle; between the thyroid cartilage and the os hyoides is the thyro-hyoid membrane, and it is perforated by the superior laryngeal nerve and artery. The *upper portion* of the triangle

Upper portion.

is small, when compared with the lower, its boundary above is formed by the side of the jaw, the parotid gland, which is now removed, and the mastoid process; the lower boundary, by the digastric and stylo-hyoid muscles and cornu of the os hyoides; and the inner, by the middle line of the neck. This space is deeper behind than before, and ascending through it, nearer the posterior than the anterior part, to reach the interval between the ear and ramus of the jaw, is the external carotid artery, which enters above into the parotid gland, and its relations in this have been seen; deeper than the external carotid is the internal carotid artery with its vein and the nerves that accompany it, and crossing downwards and inwards to the angle of the jaw between both carotids is the stylo-glossus muscle. In the front of this portion of the triangle, near the side of the jaw, are the small muscles between the jaw and os hyoides, the most superficial being the anterior belly of the digastric, and the mylo-hyoid; close beneath the side of the jaw, and somewhat covered by it, is the submaxillary gland which lies on the mylo-hyoid muscle; and, passing through the substance of the gland, is the facial artery that makes some remarkable turns to reach the face. When the gland is rather pulled from its position, the mylo-hyoid branch of nerve and the sublingual artery are seen on the surface of the mylo-hyoid muscle; and lower and deeper than the facial artery, the lingual branch of the external carotid, which enters beneath the mylo-hyoid and hyo-glossus muscles; together with the hypoglossal nerve which lies on the hyo-glossus muscle, and above the level of the artery.

Sterno-cleido-mastoid Muscle.

The *sterno-cleido-mastoid muscle*, so named from it attachments, is situated on the side of the neck, and forms the prominence of this part; it is narrower in the centre than at either extremity, and it is divided, below, into two portions or heads. The muscle *arises* by two heads; the internal, pointed, thick, and tendinous on the anterior surface, from the anterior part of the sternum; the external, wide, by aponeurotic fibres from the anterior border and upper surface of the clavicle, for the sternal third of this bone, or sometimes the half. The two portions of the muscle, separated at first by a cellular interval, ascend, the anterior passing backwards, and the posterior almost vertically and overlapped by the anterior, and they meet about the middle of the neck, to form a roundish muscle, whose fibres are prolonged upwards and backwards to be *inserted* into the whole outer surface of the mastoid process, and by a tendinous attachment into the outer two thirds of the superior curved line of the occipital bone. A tendon is placed on the anterior border of the occipital attachment, and the insertion has been seen and partly detached in dissecting the portio dura nerve. By the position of this muscle across the side of the neck it divides

Origin.

Insertion.

Relations.

this into two triangular spaces; its cutaneous surface is very superficial, and is covered only by the integument, platysma, and anterior branches of the cutaneous nerves of the cervical plexus; the external jugular vein also crosses the muscle, and lies on it for the greater part of its extent. The posterior border which limits, anteriorly, the posterior triangle, is in contact with the cervical plexus, and spinal accessory nerve, after this has perforated it; and, below this, with the brachial plexus, the omo-hyoid muscle, and the external jugular vein; the subclavian artery is deep, and it is separated from this border by the anterior scalenus muscle. Along the anterior border are the parotid gland and portio dura nerve, the digastric and stylo-hyoid muscles, the internal jugular vein, and the parts already mentioned as lying in the portion of the anterior triangle below the digastric muscle, — namely, the carotid arteries, jugular vein, and spinal accessory nerve; the relations of these vessels to this portion of the border of the muscle below the digastric should be attentively considered, since it is the guide to these vessels in case a ligature should be required to be placed on them. Still lower down than the carotids, are found the cricoid cartilage, omo-hyoid and sterno-hyoid muscles, and these are slightly covered below by the sternal origin of the muscle. Cut across this muscle near its clavicular attachment, and turn it upwards and outwards, but preserve as many of the arteries and nerves that enter it as can be done, until they have been seen. The muscle conceals many important parts;— the sternal portion or origin lies over the sterno-clavicular articulation and anterior jugular vein, the sterno-hyoid, thyroid, and omo-hyoid muscles; and, above these, on the common carotid artery, jugular vein, and accompanying nerves, as high as the cricoid cartilage. The clavicular portion covers the anterior scalenus muscle and phrenic nerve, and the transversalis colli and humeri arteries and veins, which separate it from the subclavian artery. This origin is usually distant from the trapezius the length of the middle third of the clavicle, but sometimes the two muscles are united at their origin, and they conceal altogether the subclavian artery, — so that, in an operation on this vessel, the muscular fibres would be required to be divided. After the two origins of the muscle have united, the muscle lies on the cervical, and part of the brachial plexus, on the posterior scalenus, levator anguli, and splenius muscles; and near its cranial attachment on the parotid gland, portio dura nerve, and posterior aural artery, and on the digastric muscle with the occipital artery. The spinal accessory nerve perforates the muscle about its upper third, and supplies it with branches; and some small arteries are supplied to it from the carotid.

Omo-hyoid Muscle.

The *omo-hyoid muscle*, exposed by raising the sterno-mastoid, is a digastric muscle, and its two fleshy portions are united by

a small round tendon beneath the sterno-mastoid muscle. The posterior belly, dissected with the posterior triangle and the back, has been seen to lie across the lower part of the posterior triangle of the neck, to *arise* from the superior costa of the scapula beneath the trapezius, and to end in the connecting tendon beneath the sterno-mastoid. The anterior belly, commencing in the tendon, runs upwards and forwards, beneath the sterno-mastoid, and it extends from the anterior border of this muscle to the os hyoides, nearly parallel to the sterno-hyoid, with which it is *inserted* into the os hyoides, at the junction of its body and cornu. The relations of the posterior belly are examined, but the anterior crosses the common carotid artery and jugular vein, and it marks the point at which the artery is superficial; it is covered by the integuments and fascia, and lies on the sterno-thyroid muscle and thyroid body; the descendens noni nerve and superior thyroid artery lie beneath it. This muscle is occasionally attached to the clavicle, as well as to the superior costa of the scapula.

Origin. Insertion. Relations.

The *sterno-hyoid muscle*, situated nearer the middle line than the preceding, is flat and thin, and it will be readily exposed by removing any cellular membrane that may cover it. It *arises*, below, from the posterior surface of the sternum, near the articulation with the clavicle, and from the posterior ligaments of this articulation; the fibres ascend and form a flat thin muscle which is *inserted* into the lower border of the body of the os hyoides, close to the median line, and internal to the omo-hyoid, with which its fibres are united. In the lower portion the muscle is covered by the sternum and sterno-mastoid, but it is subcutaneous above this; its cutaneous surface is marked by a tendinous intersection a little above the clavicle. The inner border corresponds to the middle line of the neck, and it is separated from the one of the opposite side by a slight interval; the outer is in contact with the sterno-thyroid, which projects beyond it, and with the omo-hyoid. Cut through the muscle near the sternum and turn the ends up and down; it lies on the sterno-thyroid muscle, on its continuation upwards — the thyro-hyoid, and on the superior thyroid vessels; it rests also over the crico-thyroid membrane, but separated from it by a small synovial bursa. The origin of the muscle varies, — sometimes it is from the cartilage of the first rib, and sometimes from the posterior surface of the clavicle.

Sterno-hyoid Muscle. Origin. Insertion. Relations.

The *sterno-thyroid muscle*, situated beneath the sterno-hyoid, is wider and shorter than it. It *arises* inferiorly from the posterior surface of the sternum, opposite the cartilage of the first or the second rib, and sometimes from the cartilage of the rib; the fibres ascend, constitute a thin but wide muscle, and they are *inserted* into the oblique line on the ala of the thyroid cartilage, to which the inferior constrictor muscle of the pharynx

Sterno-thyroid Muscle. Origin. Insertion.

is attached. The muscle appears to be continued upwards to the os hyoides by a short thick muscular portion, — the thyro-hyoid muscle. The cutaneous surface is covered by the sternum, sterno-mastoid, hyoid, and omo-hyoid muscles, and by the anterior jugular vein. The inner border corresponds to the middle thyroid vein; and the outer to the carotid artery. The muscle lies on the trachea, the brachio-cephalic artery, on the right side, and on the common carotid artery; on the thyroid body, with its vessels and the external laryngeal nerve, and on the small crico-thyroid muscle. The descendens noni nerve supplies the muscle. It is marked also by a tendinous intersection.

Relations.

Thyro-hyoid Muscle.

The *thyro-hyoid muscle*, sometimes considered one of the muscles of the larynx, is short and flat. It arises from the oblique line on the outer surface of the thyroid cartilage, to which the inferior constrictor is inserted; the fibres ascend to the os hyoides, and they are inserted into the body of the os hyoides, and into the lower border of the inner half of the great cornu of this bone. It is covered by the sterno-hyoid and omo-hyoid muscles, and it lies on the thyro-hyoid membrane, and the superior laryngeal artery and nerve.

Dissection.

Take away any cellular membrane or fascia from the surface of the anterior scalenus muscle, and remove a fascia that is continued from its inner border, to expose the subclavian artery with its branches, in the part of its course before it reaches the scalenus muscle; and, in doing this, and cleaning the trunk of the artery, be careful not to cut away the numerous branches which descend from the sympathetic nerve to the chest. On the inferior thyroid branch of artery which is directed upwards and inwards to the thyroid body, is oftentimes placed the middle cervical ganglion of the sympathetic, and from it are small nerves descending also to the thorax. On the left side, the thoracic duct is to be avoided, as it lies internal to the subclavian, and crosses outwards over the thyroid axis to join the subclavian vein. The cellular membrane and fascia are to be removed more completely from the meshes of the cervical plexus, and one or two small branches that pass inwards to the descendens noni are to be dissected out; the phrenic nerve from the plexus lies on the anterior scalenus muscle. Follow downwards the lower cervical nerves to the brachial plexus, and remove the cellular membrane from the large trunks of nerves that enter into this plexus; and take care of the small subclavian branch which turns forwards to this muscle: the branches that pass backwards through the posterior scalenus were mostly dissected with the back, and the large posterior scalenus muscle, which lies behind the brachial plexus, is to have the fascia and cellular membrane cleared from it.

Scalenus anticus Muscle.

The *scalenus anticus muscle* is conical in shape, the base below on the first rib, and the apex is connected to the transverse processes of the lower cervical vertebræ. It is situated at

the anterior and lateral part of the neck, and it *arises* by aponeurotic fibres from the internal border and upper surface of the first rib, about its middle, and in front of a depression on this surface of the rib for the subclavian artery: a tubercle, easily felt with the finger, which is the guide to the position of the artery when it is to be ligatured, marks the point of attachment of this muscle to the rib. The fibres ascend, and form a fleshy belly which divides, above, into pointed processes, to be *inserted* into the anterior tubercles of the transverse processes of the sixth, fifth, fourth, and third cervical vertebræ. More deeply seated below than above, the muscle lies beneath the clavicle, subclavius muscle, and subclavian vein; above this it is covered by the clavicular origin of the sterno-mastoid, and on it are the phrenic nerve, and transversalis colli and humeri arteries and veins. The muscle is not so wide as the posterior scalenus muscle; its outer border is in contact with the large cervical nerves to the brachial plexus, and the inner is parallel to the internal jugular vein, and, deeper still, to the longus colli muscle, the large vertebral artery intervening between the two. The insertion of the muscle corresponds to the origin of the rectus capitis anticus major, and the small ascending cervical artery is between the two. Beneath the muscle are the large nerves of the brachial plexus and the subclavian artery, which separate it from the posterior scalenus muscle. The lower part of the muscle is thus interposed between the subclavian artery and vein, the vein being superficial to the muscle and the artery beneath it.

Origin. Insertion. Relations.

The *scalenus posticus muscle*, larger than the anterior, behind which it is placed, is bifid below, and it *arises* by one attachment, from the upper surface of the rib behind the depression for the subclavian artery, and this extends backwards to the tubercle of the rib; and by the other, which is wide and placed behind the first, from the second rib between its tubercle and angle. The fleshy fibres are directed upwards, and they form a thick muscle which ends by being *inserted*, by means of pointed processes, into the posterior tubercles of the transverse processes of the six last cervical vertebræ. The anterior surface of the muscle is covered by the brachial plexus and subclavian artery, and, higher up, by the cervical plexus and sterno-mastoid muscle. The inner border is connected to the transverse processes of the cervical vertebræ, and to the two first ribs, and is in contact with the first intercostal muscle; the outer border, which is free in the posterior triangle, is crossed by numerous branches of the cervical plexus, by the transversalis colli artery and vein, and by the supra-scapular nerve; and it is covered by the sterno-mastoid muscle, and, near the ribs, by the serratus magnus muscle; this border is perforated by the two nerves to the rhomboid and serratus muscles. The pos-

Scalenus posticus Muscle. Origin. Insertion.

terior surface is in contact with the muscles of the back, viz. the levator anguli scapulæ, cervicalis ascendens, and transversalis colli, muscles.

Scalenus minimus Muscle.

Between the scaleni is very commonly found a small muscular slip, — the *scalenus minimus* of Sœmmering, which is attached to the upper edge of the first rib, and ascends to the transverse process of the seventh, or of the two last cervical vertebræ. This muscular bundle separates the subclavian artery from the united trunk of the eighth cervical, and the first dorsal nerve, which is somewhat posterior and external to the artery.

Subclavian Artery.

The *subclavian artery**, one of the branches of division of the brachio-cephalic trunk behind the sterno-clavicular articulation, runs outwards across the lower part of the neck to reach the upper extremity, which it supplies with blood; and the continuation of this vessel through the limb receives different appellations according to the names of the regions through which it passes. The name, subclavian, given to this vessel from its position beneath the clavicle, is applied to that part of it which extends from the sterno-clavicular articulation, or point of division of the brachio-cephalic artery, to the lower border of the first rib. In its course the artery does not pass transversely, but it ascends to reach the upper surface of the first rib, where it lies between the scaleni muscles, and it then descends, being inclined obliquely outwards, to the lower border of this rib, so as to form an arch whose concavity is directed to the first rib, and the pleura and lung of this side. This extent of the artery is divided into three parts, to facilitate the description of their relations, which are very different; the first portion extends from the sterno-clavicular articulation to the inner or tracheal border of the anterior scalenus muscle; the second is the part between the scaleni muscles; and the third is the continuation of the trunk, from the external or acromial border of the scalenus, to the lower border of the first rib: the first and second portions are the deepest in position and the least accessible.

First portion.

The *first portion* of the artery, internal to the scalenus muscle, ascends slightly, from its commencement, to the first rib, and it is covered by the integument and fasciæ, by the sternal portion of the sterno-mastoid, and beneath it by the anterior jugular vein; by the sterno-hyoid and thyroid muscles, and beneath these, by a fascia prolonged over the artery from the inner border of the scalenus muscle to the brachio-cephalic trunk. The internal jugular vein crosses the artery at right angles, and near the inner border of the scalenus muscle, and beneath it is the vertebral vein which joins the brachio-cephalic vein; and the anterior branches of the sympathetic nerve lie in close con-

* For the differences between the right and left subclavian arteries, refer to the dissection of the left side: this is to be done, especially, in the dissection of the opposite side.

tact with the artery; between the jugular vein and the commencement of the artery, the trunk is crossed by the large pneumo-gastric nerve that sends behind it the recurrent nerve. This portion of the artery is in contact with the pleura, which ascends, above the first rib, into the concavity of the artery, and into the interval between the two scaleni muscles; it lies over the longus colli muscle, though at a considerable distance from it, and separated from it by cellular membrane and some glands; the recurrent branch of the pneumo-gastric, and the trunk of the sympathetic nerve, are behind the artery and in close contact with it. On the left side the subclavian arises in the chest, and therefore the relations of the first portion of the artery will differ much from this of the right side. The *second portion*, or the transit of the artery between the scaleni, is much shorter, and is more superficial than the first. It is covered by the integument and fascia as the first portion, by the clavicular part of the sterno-mastoid muscle, by the omo-hyoid, and the anterior scalenus muscle; the phrenic nerve crosses the scalenus muscle, obliquely, from the outer to the inner border which it reaches at the insertion of the muscle into the rib, and it therefore crosses the line of the artery. The subclavian vein is not in close proximity to the artery, since it is placed in front of the scalenus and below the level of the artery. Behind this part of the artery is the posterior scalenus muscle, but the trunk of the eighth cervical and the first dorsal nerve lies between the muscle and the artery; and above the artery in the interval between the scaleni is the large brachial plexus which descends to come into contact with it. The *third and last portion* of the artery, which extends from the acromial border of the scalenus to the lower border of the first rib, lies in the clavicular portion of the posterior triangle, in which it is very superficial, and its anatomy has been referred to in the dissection of that space, to which reference may be made.

Second portion.

Third portion.

The branches of this artery are very irregular in their origin, and they are five in number: three are given off from the portion of the artery internal to the scalenus, or from the first part of the artery, and they are the vertebral, thyroid axis, and internal mammary; and two branches — the superior intercostal and deep cervical, arise from the second part of the artery. In those instances in which the branches of the thyroid axis are small, one or more branches will be given off from the third part of the artery; and their distribution will be to the parts that would have been otherwise supplied, in the normal distribution, by the branches of the thyroid axis.

Branches.

The dissection of the origins and first portions of the branches of this artery is very easy, and it has been done in great part in exposing the trunk; it will require only the removal of any cellular membrane, with the precaution of not cutting away the

Dissection.

nerves. It is only portions of the branches of the subclavian that can now be examined, since the arteries leave this part of the neck, and they either have been or will be dissected to their terminations in other stages of this part, or in dissections of the other parts of the body. To see the two branches beneath the scalenus, this muscle must be afterwards divided.

Vertebral Artery. The *vertebral artery*, generally the first and largest branch of the subclavian, arises from the upper and posterior part of the artery, and it ascends a little outwards behind the inferior thyroid artery, but above the level of the inferior cervical ganglion of the sympathetic; and between the contiguous borders of the scalenus and longus colli muscles, it enters the aperture in the transverse process of one of the cervical vertebræ, generally the sixth, anterior to the nerve that escapes from it. The artery then ascends through the series of foramina in these processes of the vertebræ, winds behind the articulating process of the atlas, perforates the ligament between the atlas and occiput, and it enters the skull to be distributed to the brain. The cervical portion of the artery is partly concealed by the jugular vein, behind which it turns, and it is accompanied by branches from the inferior cervical ganglion of the sympathetic, which accompany it and form on it the vertebral plexus. On the left side the artery is crossed by the thoracic duct. This branch gives off small muscular branches in the neck, before it enters into the foramina.

Vein. The *vertebral vein* lies with the artery in the foramina, but when it appears in the neck it lies superficial to its artery, and it descends over the subclavian artery to end in the brachio-cephalic vein; this vein is joined by the ascending cervical vein, and sometimes by branches from the deep cervical.

Internal Mammary Artery. The *internal mammary artery*, a large and regular branch, leaves the lower part of the trunk opposite the thyroid axis, it descends vertically beneath the clavicle, subclavius muscle, and the subclavian vein near where it joins with the internal jugular in the brachio-cephalic, and it enters the chest between the bag of the pleura and the first rib. As this artery enters the chest it is crossed, in front, by the phrenic nerve that lies between it and the commencement of the brachio-cephalic vein; but when the vessel has entered the cavity it changes its direction, and runs inwards to the first piece of the sternum along the cartilage of the rib and over the phrenic nerve and brachio-cephalic vein; and its course by the side of the sternum to the abdominal wall, to anastomose with the epigastric, will be dissected with the thorax.

Vein. The *internal mammary vein* opens into either the brachio-cephalic or the superior cava: it is not visible.

Thyroid Axis. The *thyroid axis*, the next branch of the subclavian, is a short thick trunk that arises from the front of the artery near the

inner border of the scalenus muscle. It soon divides into four branches of unequal size; two, the transversalis humeri and colli arteries, run transversely outwards across the scalenus muscle; and the other two ascend;—one, very small, is the cervicalis ascendens, which is directed obliquely outwards, and the other, the inferior thyroid, runs inwards to the thyroid body. The vertebral and internal jugular veins lie in contact with the inner side of the artery, and the anterior scalenus and phrenic nerve with the outer; on the left side the thoracic duct crosses in front of the trunk, as it is directed downwards and outwards to open into the angle of union of the internal jugular and subclavian veins. The *transversalis humeri branch* runs downwards and outwards over the scalenus muscle to the clavicle, it is then continued outwards behind this bone and the subclavius muscle, to the superior costa of the scapula, and it divides into the two branches, named supra-acromial and supra-spinal, as before seen. The *transversalis colli branch*, larger than the preceding, crosses the scalenus muscle and phrenic nerve, the posterior scalenus muscle and the brachial plexus, and it divides beneath the levator anguli into the superficialis colli and posterior scapular. This artery crosses the apex of the space in which the subclavian artery is contained, and it gives off some small branches to the posterior triangle of the neck. The *inferior thyroid artery*, the largest branch of the thyroid axis, ascends obliquely inwards, behind the common carotid artery and jugular vein, and the pneumo-gastric and sympathetic nerves, to the thyroid body, to which it is distributed. In this course the artery makes a remarkable turn behind the carotid artery; it lies, at first, superficial to the vertebral and in front of it, it is then placed on the longus colli muscle, and crosses the recurrent nerve, and, at the lower part of the thyroid body, it divides into an ascending branch, that joins with the descending of the superior thyroid; a transverse, directed across the trachea, below the transverse communicating portion of the thyroid body, to anastomose with a similar branch from the opposite side; and many branches for the supply of the structure of this body. The middle cervical ganglion of the sympathetic is frequently placed on this artery. The anastomosis between the thyroid arteries is very large and free. The *ascending cervical artery* is a small branch from the inferior thyroid or from the axis; it ascends on the scalenus, then in the interval between the insertion of this muscle and the origin of the rectus capitis anticus major, and it terminates by dividing into branches; some of these enter the spinal canal, along the spinal nerves, to anastomose with the other arteries of the canal; and others supply the muscles in front of the spine. This small artery is sometimes considered a branch of the inferior thyroid.

Transversalis Humeri branch.

Transversalis Colli branch.

Inferior Thyroid branch.

Ascending Cervical branch.

The *veins* that correspond to these branches of the thyroid

Veins.

axis have the same names as the arteries. Those with the transversalis colli and humeri arteries open into the external jugular vein, near its junction with the subclavian. The *ascending cervical* joins the vertebral; but the *inferior thyroid* is at a distance from the artery, it commences in a plexus of veins connected with the thyroid body, and descends, in front of the trachea, and beneath the muscles of the middle line, to open into the angle of union of the two brachio-cephalic trunks. The vein on the left side opens into the left brachio-cephalic vein.

Superior Intercostal Artery.

The *superior intercostal artery* arises from the under part of the artery between the scaleni, it passes backwards, and suddenly bends downwards to enter the thorax over the first rib. The artery then extends along the side of the spine, over the two or three first intercostal spaces, to each of which it gives a branch, and it ends by anastomosing, in one of the intercostal spaces, with an aortic intercostal artery. The artery is seen in the interior of the thorax when it is opened, and, as it enters this cavity, it crosses the neck of the first rib, between the inferior cervical ganglion of the sympathetic on the inner side, and the first dorsal nerve on the outer.

Vein.

When the *vein* is present, it opens on the right side, into the subclavian vein; but, on the left, into the brachio-cephalic.

Deep Cervical Artery.

The *profunda cervicis artery*, the last branch of the subclavian, leaves the trunk near the superior intercostal, if not in common with it, beneath the scalenus. The artery turns backwards to the posterior part of the neck, between the transverse processes of the sixth and seventh cervical vertebræ; and between the complexus and semi-spinalis colli muscles it anastomoses with the occipital.

Vein.

The *vein* with this artery has the same course, it joins with the vertebral, and it opens into the brachio-cephalic vein.

Subclavian Vein.

The *subclavian vein** extends from the lower border of the first rib to the sterno-clavicular articulation, and, at this spot, it joins with the internal jugular vein in the brachio-cephalic. This vein is the continuation, upwards, of the axillary, which ceases at the lower border of the first rib; and, to see it more completely, the centre of the clavicle and subclavius muscle should be removed, if it has not been done. It does not form an arch as the artery, but its course is nearly straight behind the clavicle and subclavius muscle, and below the level of the artery, from which it is separated by the anterior scalenus muscle; it rests on the first rib and pleura. Very few branches join the subclavian vein; and, of all the veins that correspond to the branches of the subclavian artery, only one—the *superior intercostal* of the right side,—opens into it, and this vein is often absent. The external and anterior jugular veins open

* In dissecting the left side, refer to the description of the left side for the differences between the veins of opposite sides.

into its front, as well as a small vein from the cephalic; into the angle of union of it and the internal jugular the lymphatic duct of the right upper extremity and right side of the head and neck opens; and into the angle of union, on the left side, the thoracic duct enters.

Brachial Plexus.

The *brachial plexus* is readily exposed by removing, sufficiently, the anterior scalenus muscle. It is formed by the union of the anterior branches of the four lower cervical nerves with that of the first dorsal; it is joined above by a branch sent down from the fourth nerve in the cervical plexus, and the nerves are joined also by filaments from the lower cervical ganglion of the sympathetic, which unite with them close to the intervertebral foramina. The plexus, formed by the divisions, subdivisions, and unions of the different nerves and their branches, extends from the lower part of the side of the neck to the coracoid process in the axilla; its upper part is wide and is opposite the three lower cervical vertebræ, the lower is pointed and surrounds the axillary artery; it lies, above, between the scaleni muscles, to the upper and outer side of the artery, it then descends, with a closer relation to the artery, beneath the clavicle and subclavius muscle, and it will be seen in the dissection of the axilla. In the neck, it is crossed by the transversalis colli artery and vein, by the omo-hyoid muscle, and by the transversalis humeri artery and vein. The nerves that enter into the plexus have the following disposition in it: — the anterior branches of the fifth and sixth cervical nerves unite soon after they leave the intervertebral foramina, and whilst between the scaleni muscles, to form one trunk which descends to the insertion of the posterior scalenus muscle, and it there joins the trunk of the seventh nerve, which runs, alone, to this point; the eighth cervical and first dorsal unite also between the scaleni, and soon after they leave the foramina, into one trunk that lies in contact with the artery, but posterior to it, and it descends with the vessel into the axillary space, in which part it remains as a trunk, distinct from that formed by the union of the fifth, sixth, and seventh nerves; the two large cords or trunks lying side by side in the upper part of the axilla. Thus, in the neck, and on the posterior scalenus, the plexus consists of three trunks; the upper one formed by the fifth and sixth, the middle one by the trunk of the seventh nerve, and the lower, by the union of the eighth cervical and first dorsal nerves; at the insertion of the scalenus into the rib the trunk of the seventh joins that formed by the fifth and sixth, so that only two trunks remain, and these pass with the artery into the axillary space, and give off all the branches for the supply of the upper extremity: these two cords are occasionally joined by a cross or connecting branch.

Branches.

The *branches* of nerves of this plexus may be divided into

those above and those below the clavicle; those, above, are the branches to the rhomboid and levator anguli scapulæ muscles, to the phrenic nerve, to the serratus and subclavius muscles, and the supra-scapular nerve; and those, below, supply the upper extremity and its muscles, and will be dissected with these.

To the Rhomboid Muscle.

The *branch to the rhomboid muscle* will be found, by tracing it back through the scalenus, to come from the fifth or fourth cervical nerve, as soon as it has left the canal; it runs outwards through the substance of the scalenus, supplies the levator anguli, and is distributed to the rhomboid muscle.

To the Phrenic Nerve.

The *branch to the phrenic nerve* comes from the fifth, it runs downwards and inwards over the outer border of the scalenus muscle, and it joins the phrenic on the front of this muscle.

To the Serratus magnus Muscle.

The *nerve to the serratus magnus*, the external respiratory of Bell, or the posterior thoracic, is sometimes formed by branches from the fifth and sixth cervical nerves as soon as they pass from their foramina, and in the substance of the scalenus which it perforates; at others, by a branch from the sixth, which is joined by a branch from the rhomboid nerve, external to the scalenus muscle. The nerve descends, in front of the levator anguli and behind the brachial plexus, to the axillary surface of the serratus, to which it is distributed.

To the Subclavius Muscle.

The *branch to the subclavius muscle* is a very delicate and small nerve; it is given off from the front of the trunk formed by the fifth and sixth nerves, and near to where this joins the seventh nerve; it is directed downwards and forwards, over the subclavian artery, to the subclavius muscle which it enters by the under surface, and about its middle.

Supra-scapular Nerve.

The *supra-scapular nerve* arises from the posterior part of the trunk formed by the fifth and sixth nerves, near to the origin of the subclavian branch from it. The nerve is larger than either of the preceding branches, and it descends obliquely outwards and backwards, over the border of the scalenus, and levator anguli scapulæ muscles, and beneath the trapezius, to the notch in the upper costa of the scapula, through which it passes to supply the muscles on the dorsum of this bone.

To the Scaleni Muscles.

Numerous muscular branches are supplied to the scaleni muscles from the nerves before they enter the plexus.

Common Carotid Artery.

The *common carotid arteries*, one on each side, are the chief vessels for the supply of the head and neck with blood, and they are remarkable in not giving off any collateral branches. The vessel of the right side extends, from the division of the brachio-cephalic artery, opposite the sterno-clavicular articulation, into right carotid and right subclavian, to the upper border of the thyroid cartilage, where it divides into the external and the internal carotid artery. On the left side the common carotid is longer than this on the right, since it arises, as did the left subclavian, from the arch of the aorta in the thorax, and therefore

its relations in this part will differ from those of the right side, but after it has entered the neck the relations are the same on both sides.* The direction of the artery is vertically upwards and outwards in front of the bodies of the cervical vertebræ, and by the side of the trachea and larynx; it is more deeply situated in the lower than in the upper part of its course; and by the dilatation of the air tube into the larynx, the arteries are much more distant from the middle line, and therefore from each other, opposite this body, than in the lower part of the neck. The course of the artery is marked by a line drawn from midway between the angle of the jaw and ear to the sterno-clavicular articulation, or the anterior border of the sterno-mastoid muscle is generally taken as the guide to the vessel in surgical operations. The artery is confined in a sheath of cervical fascia with the internal jugular vein and pneumo-gastric nerve, to which the surrounding parts have the following relations: — in front, the sheath is covered by the integument and superficial fascia, the platysma and deep fascia, the sternal origin of the sterno-mastoid muscle, the anterior jugular vein, the sterno-hyoid, sterno-thyroid, and omo-hyoid muscles, which cover the artery as high as to the cricoid cartilage; but above this, to its termination, the artery is covered only by the cutaneous structures and fasciæ, with the superficial nerves and veins. In close contact with the front of the sheath is the small descendens noni nerve which crosses the sheath from the outer to the inner side; but it is sometimes contained in the sheath; and crossing the sheath, near the lower part of the artery, is the small middle thyroid vein which opens into the jugular. On the inner side are placed the œsophagus, trachea, and larynx, with the recurrent nerve and thyroid body, and this last partly overhangs the artery, particularly when it is enlarged. To the outer side are the transverse processes of the cervical vertebræ, the anterior tubercle on the fifth being named the carotid tubercle, since it is the guide to the artery in operating. A chain of conglobate glands lies along the outer part of the sheath, beneath the sterno-mastoid muscle, and when they are enlarged they press on the artery. Behind the sheath are the longus colli muscle and bodies of the vertebræ, with the inferior thyroid artery and recurrent nerve that run upwards and inwards to the middle line; and behind the whole extent of the sheath is the sympathetic nerve with its branches. The sheath of the vessels consists of a process of fascia which contains the artery to the inner side, the internal jugular vein to the outer, and the pneumo-gastric nerve between the two, and rather behind them. The proximity of the jugular vein to the artery is not equally close in its whole extent, for at the lower part of

* The difference in the relations of the vessel of the left side will be found with the description of the dissection of that part.

the neck the vein inclines outwards and forwards, and leaves a space between it and the artery, in which is found the vagus nerve; on the left side the vein is much nearer the artery, but in front of it. The pneumo-gastric nerve is concealed by the artery and vein to near the lower part of the neck, but it then diverges slightly from the artery, and lies midway between the vein and the carotid; it is much nearer to the artery of the left side in the lower part of the neck.

Cervical Plexus.] The *cervical plexus* is formed by the anterior branches of the four first cervical nerves, which unite with each other after they are joined by filaments of the sympathetic. The appearance of this plexus differs much from that of the brachial, since it resembles more a network than a bundle of large cords. The general arrangement of the nerves is, that each divides on the scalenus muscle into an upper and a lower branch which unite with similar branches from the other nerves, and that, from the point of union, other branches are given off to form other arches, and in this manner to give rise to the cervical plexus, which is situated opposite the four upper cervical vertebræ, on the scalenus posticus and levator anguli scapulæ, and beneath the sterno-mastoid muscle. The third and fourth nerves seem to enter more largely into the plexus than the other nerves; and the anterior branches of the two upper cervical nerves that enter into this plexus, are an exception in their course to the anterior branches of the other spinal nerves, since they do not escape from the canal by means of the intervertebral foramina, but they turn forwards from the posterior part. The following is the disposition of the nerves that enter into this plexus: — the anterior branch of the first comes forwards, above the transverse process of the atlas, from the ganglion placed on the posterior arch of this vertebra, and it descends in front of the process to join with an ascending branch of the second. The anterior branch of the second comes, in like manner, from the ganglion on the arch of the axis, and it appears in the interval between the transverse processes of the two first cervical vertebræ, after it has passed beneath the different muscles of the back. It now divides into an ascending and a descending branch; the ascending joins the descending nerve of the first so as to form a loop in front of the transverse process of the atlas, which gives branches to join with the sympathetic, and cranial nerves at the base of the skull; and the descending branch unites with the third, and gives off other branches to assist in forming the superficial cervical and great auricular nerves, and one long and slender filament descends to the descendens noni nerve. The third nerve leaves the spinal canal by the intervertebral foramen, it sends its anterior branch forwards round the vertebral artery to appear between the inter-transversales muscles, and it divides into an ascending and a descending portion; the ascend-

ing gives off the small occipital nerve, and joins with the great auricular, and superficial cervical nerves, it sends some branches to the substance of the trapezius, and unites with the spinal accessory as soon as this nerve has perforated the sterno-mastoid. The descending portion of this nerve joins the fourth, and gives another filament to the descendens noni nerve. The anterior branch of the fourth nerve, with the same relative anatomy as the third, gives off a small nerve — the phrenic — over the anterior scalenus, and it then divides into branches from which the descending cutaneous clavicular, and acromial branches are derived. A small branch goes from this nerve to join the brachial plexus.

The *branches* are divided into superficial and deep; the superficial consisting of ascending, descending, anterior, and posterior branches, which were seen in the dissection of the posterior triangle of the neck; and the deep, now exposed, are again divided into internal, which include the phrenic, and branches to the descendens noni, eighth, ninth, and sympathetic nerves; and into external or muscular branches, with which are some nerves to join the spinal accessory. Branches.

The *phrenic nerve*, a branch, for the most part, of the fourth cervical nerve, receives sometimes a filament from the third; it descends obliquely inwards on the anterior scalenus muscle, and is joined by a branch from the fifth cervical or first nerve of the brachial plexus. The nerve crosses from the outer to the inner side of the scalenus, and at the insertion of this muscle into the rib, it enters the thorax behind the subclavian vein *, and in front of the internal mammary artery. The final distribution of the nerve is to the diaphragm, and it has been named internal respiratory. Deep Internal. Phrenic.

The *nerve to join the descendens noni* is formed by filaments from the second and third cervical nerves, which pass inwards beneath the sterno-mastoid, unite together, and join the descendens noni in front of the sheath of the common carotid artery. These small nerves are irregular in their distribution. Nerve to the descendens Noni.

The deep internal branches from the loop of the atlas to the eighth, ninth, and sympathetic nerves, and to the muscles in front of the spine, must be omitted till a future dissection. To the Eighth and Ninth Nerves.

The *branches to the spinal accessory* nerve are numerous; thus, as soon as this nerve has perforated the sterno-mastoid, it receives a large branch from the second or third cervical nerve, which increases its size, and it is not unusual for the spinal accessory to be connected to the great auricular nerve by another branch. In the trapezius muscle this nerve joins, as before seen, with two or more nerves that pass backwards from the Deep External or Posterior. To the Spinal Accessory.

* In the dissecting room of the College, this last season, my attention was directed, by Professor Quain, to a subject in which the nerve passed in front of the vein.

third nerve to supply the trapezius; and in the sterno-mastoid muscle it joins with other branches from the plexus.

Muscular. The remaining branches of the plexus are the *muscular* to the scalenus posticus and rectus anticus major muscles, to the levator anguli and sterno-mastoid muscles, and in this last they join with the spinal accessory nerve.

Dissection. Continue with the anatomy of the external carotid artery and its branches, and with the digastric and stylo-hyoid muscles which are superficial to it: these are dissected with the anterior triangle and portio dura nerve, but any cellular membrane that is present may be removed from them.

Digastric Muscle. The *digastric muscle*, named from its division into two bellies which are united by an intervening tendon, is situated in the upper part of the neck, and it forms an arch, convex downwards, below the lower jaw.

Origin of the Posterior Belly. The posterior belly *arises* from the digastric fissure or groove beneath the mastoid process, and from the anterior border of the process; the fibres descend obliquely forwards, and form a roundish fleshy belly which ends in a tendon that is partly concealed by the fibres of the stylo-hyoid muscle, and is *inserted* into the os hyoides, in front of the stylo-hyoid muscle, by an expansion from the lower border of the tendon; the attachment to the os hyoides is sometimes by a cartilaginous ring that is lined by a synovial membrane.

Insertion.

Origin of the Anterior. The anterior belly *arises* from the depression in the lower jaw on the side of the symphysis, the fibres constitute a fusiform bundle which is shorter and more vertical than the posterior, and ends below in the tendon of insertion.

Insertion. Relations. The posterior belly is covered near its attachment to the cranium by the trachelo-mastoid, splenius, and sterno-mastoid muscles, and by the parotid gland; more anteriorly than this, it is almost subcutaneous, it is covered by the platysma, and is crossed by the external jugular vein and branches of the portio dura; the fibres of the stylo-hyoid surround the tendon of the muscle, and it is partly concealed by the submaxillary gland. This portion of the muscle crosses the carotid, facial, and lingual arteries, the internal jugular vein, the pneumo-gastric, spinal accessory, and hypoglossal nerves; and the two latter are more superficial below than above it. Parallel to the lower border are the occipital artery, and hypoglossal nerve,—the artery occupying the outer half, and the nerve the inner. The anterior belly is very superficial, and is covered only by the integuments and fasciæ; it lies on the mylo-hyoid muscle, and bounds in front the submaxillary gland. The line of the digastric is the lower boundary of a space which extends upwards in front of the ear, and is limited above by the jaw, and by the temporal bone as far back as the mastoid process. This space is divided into two by the stylo-maxillary ligament; in the posterior part are found the parotid gland and portio dura, the external carotid artery and

external jugular vein, with the styloid process and its muscles, and deeper than these the internal carotid artery, and internal jugular vein, with their accompanying nerves; in the anterior, are the submaxillary gland and facial artery, the mylo-hyoid muscle, and beneath its outer border the hyo-glossus muscle, with the lingual artery and hypoglossal nerve on it.

Stylo-hyoid Muscle.

The *stylo-hyoid muscle*, thin and slender, has the same position as the posterior belly of the digastric that it surrounds.

Origin.

It *arises* from the outer side of the styloid process near it base; the fleshy fibres are directed downwards and inwards, they are almost always perforated by the digastric tendon, and are

Insertion.

inserted, by means of a tendon, into the body of the os hyoides near the middle line.

Relations.

The muscle has the same relations as the posterior belly of the digastric, and between it and this muscle is a small nerve from the portio dura, which enters the stylo-hyoid about its middle. In many subjects this muscle is absent.

The portion of the hypoglossal nerve, now dissected, may be examined in this stage, since the relations of this,— its superficial part, will be destroyed before the anatomy of the whole nerve can be referred to.

Ninth Nerve.

The *hypoglossal* or *ninth nerve*, that leaves the cranium by the anterior condyloid foramen, is deep, at first, between the carotid artery and internal jugular vein, it is then superficial across the neck, and it takes, finally, a deep position beneath some of the small muscles between the jaw and os hyoides. The superficial part of the nerve comes forwards between the internal carotid artery and jugular vein, at the lower border of the digastric muscle, and it lies on the outer side of the occipital artery and in front of the jugular vein; it then winds round the artery, and is directed upwards and forwards across both carotid arteries, but beneath the veins joining the jugular, so as to form an arch across the anterior triangle, a little below the digastric muscle. At the cornu of the os hyoides the nerve crosses the lingual artery, ascends behind the tendon of the digastric, is placed above the lingual artery that it accompanies, and it enters between the mylo-hyoid and hyo-glossus muscles to reach the tongue. As the nerve crosses the neck, it gives off the descendens noni, and the thyro-hyoid branches.

Branches.

Descendens Noni Nerve.

The *descendens noni nerve* arises near the occipital artery; it is a small branch which is placed to the outer side of the sheath of the carotid artery near its commencement, but as it descends it passes in front of the sheath to its inner side, and about the middle of the neck, or even lower, it is joined by the branch or branches from the cervical plexus in an inverted arch that gives off the different branches to the muscles; this union is not by a single filament, but by two or more cross branches between the nerves. This nerve is sometimes placed in the sheath of the carotid artery; and it is not very rare to see it arise altogether from

the pneumo-gastric, or from this nerve and the ninth. The branches to the muscles from this nerve, and from the plexus between it and the branches of the cervical nerves, are, internal, to the anterior belly of the omo-hyoid, to the sterno-hyoid and sterno-thyroid muscles; external, to the posterior belly of the omo-hyoid; and descending in front of the vessels, one of these is called a cardiac branch by Arnold, and he describes it as joining the cardiac nerves in the thorax.

Thyro-hyoid branch.

The *thyro-hyoid branch* is given off near the cornu of the os hyoides, and descends inwards to the thyro-hyoid muscle, to which it is distributed.

External Carotid Artery.

The *external carotid artery*, one of the branches of the bifurcation of the common carotid, opposite the upper border of the thyroid cartilage, is destined to supply the face, neck, and outer parts of the head. It ascends to the interval between the ramus of the jaw and the ear, and, opposite the junction of the upper third of the ramus of the jaw with the lower two thirds, it divides into internal maxillary and temporal arteries. The artery lies, soon after its origin, on the inner side of the internal carotid artery, but as it ascends, it is more superficial, and is placed over the internal carotid; the direction of the vessel is not straight, for it first ascends obliquely inwards towards the angle of the jaw, and it next bends backwards to the interval between the jaw and ear; but a line extended from the front of the meatus of the ear to the cricoid cartilage would mark out sufficiently the course of the artery. The position of the digastric muscle across the artery, in the direction of a line extended from the mastoid process to the os hyoides, seems naturally to divide this vessel into two portions very different in their relations, and depth from the surface; the part below the muscle is superficial, and easily reached from the surface, but the portion above is deep in the substance of the parotid gland, in the interval between the ear and jaw. The carotid artery is covered by the integument, superficial and deep fasciæ, by the platysma, by some cutaneous nerves, and by the veins crossing it to join the jugular, and in the line before mentioned it is crossed by the digastric and stylo-hyoid muscles, and by the hypoglossal nerve; it enters the parotid gland above these muscles, and is crossed by the portio dura, and by the veins that form the external jugular. To the inner side is the os hyoides, with the muscles passing from this bone to the jaw, and above the angle of the jaw it lies against the stylo-maxillary ligament that separates it from the internal pterygoid muscle; to the outer side, below the digastric, are the internal carotid artery and the jugular vein, and above it, the artery enters the parotid. The artery lies on the inferior and middle constrictors of the pharynx, on the superior laryngeal nerve that crosses behind it to the larynx; above the angle of the jaw it crosses the styloid

process, and stylo-glossus and pharyngeus muscles, with the glosso-pharyngeal nerve, which lie between it and the internal carotid artery, and it next enters the substance of the gland with the external jugular vein. This artery is not accompanied by any vein, since the internal jugular serves as the vein for the external and the internal parts of the head, and receives, for the most part, the veins that correspond to the branches of the external carotid.

Branches.

The *branches* of this artery are very numerous, and to facilitate the learning them, they have been classed into those that pass forwards to the middle line, the superior thyroid, lingual, facial, and internal maxillary; those that are directed backwards, the muscular to the sterno-mastoid, the occipital, and the posterior aural; and those upwards, the ascending pharyngeal and temporal, the latter giving off the transverse facial. Some of these branches are comparatively superficial, and may be examined without more dissection; but others, as the ascending pharyngeal, lingual, and internal maxillary, require complicated dissections to expose them, and they will be taken with the anatomy of the regions in which they are found. Few arteries of the body present greater varieties than the branches of the external carotid.

Superior Thyroid Artery.

The *superior thyroid artery*, the first of the anterior series, is small in size, and passes forwards to the cornu of the os hyoides; it then turns downwards internal to the common carotid, and descends obliquely inwards beneath the omo-hyoid, sterno-hyoid, and thyroid muscles, and it ends by being distributed to the thyroid body. This artery is superficial and gives off branches to the larynx and thyroid body. The first branch, the *hyoid*, is very small, and often absent, it arises near the cornu of the os hyoides, runs inwards below it, on the thyro-hyoid membrane, and it anastomoses with the one of the opposite side, and supplies the membrane. The next branch, the *laryngeal*, varies in its origin and course; it may be given off either where the artery makes its turn opposite the cornu of the os hyoides, to run forwards on the thyro-hyoid membrane, which it perforates to enter the larynx; or it may arise lower down, to pass through an aperture in the thyroid cartilage. It is accompanied by the superior laryngeal nerve,—a branch of the pneumo-gastric, which is distributed with the artery to the interior of the larynx. The *sterno-mastoid branch* is a small muscular artery which arises a little below the preceding; it descends on the sheath of the carotid, and ends in the sterno-mastoid muscle. The *thyroid branch*, the continuation of the artery, descends beneath the sterno-thyroid muscle with the external laryngeal nerve, and at the side of the thyroid body, it divides into many branches; one descends along the outer border of the gland, to anastomose with an ascending branch from the inferior thyroid, another

Hyoid branch.

Laryngeal branch.

Sterno-mastoid branch.

Thyroid branch.

passes inwards to join the artery of the opposite side; and others spread out over the surface of the gland to supply it. A small artery from one of the branches runs transversely inwards over the crico-thyroid membrane, to join with the one of the opposite side, and to supply the muscles of the larynx.

Thyroid Vein. The *vein* with this artery has the same name; it commences in the larynx and thyroid body, and opens either into the internal jugular, or into the united trunk of the lingual and facial veins.

Facial Artery. The *facial artery* arises from the front of the carotid, above the lingual, which is seen to pass transversely inwards, though these two branches are frequently united in one trunk at their origin. The course of the artery is upwards and inwards, beneath the digastric and stylo-hyoid muscles, to the submaxillary gland, in the substance of which it makes a remarkable sigmoid turn to reach the jaw and face; in this latter part it continues obliquely upwards to the angle of the eye: this has been dissected with the face. The cervical portion of the artery, the shortest, gives off some branches to the pharynx and the parts

Inferior Palatine branch. beneath the jaw; the first branch is the *inferior palatine*, which ascends beneath the jaw, between the stylo-glossus and stylo-pharyngeus muscles, to reach the pharynx; it here divides into many branches which are distributed to the muscles and mucous membrane of this tube, and some go to the amygdala and soft palate, in which they anastomose with the superior palatine and tonsillitic arteries: this branch frequently arises from the ascending pharyngeal. The

Tonsillitic branch. *tonsillaris branch*, smaller than the preceding, from which it sometimes arises, takes the same direction as the inferior palatine, but it is nearer the jaw, and between the stylo-glossus and internal pterygoid muscles; it perforates the superior constrictor opposite the tonsil, and distributes branches to this body to anastomose with the branches from the ascending pharyngeal and internal maxillary arteries. These two small branches supply the styloid and internal pterygoid muscles.

Glandular branches. The *glandular branches* arise from the facial in the substance of the gland, and they are distributed to it. The

Submental branch. *submental artery*, the largest branch from the facial below the jaw, arises as this vessel is about to turn over the side of the jaw; it passes forwards on the mylo-hyoid muscle, and near the inferior maxilla, as far as to the anterior belly of the digastric, where it ends by dividing into branches; some of these turn over the jaw, supply the muscles of the chin, and anastomose with the mental; others supply the mylo-hyoid muscle and parts below the chin, and anastomose with the mylo-hyoid branch of the inferior dental; and one or two of them perforate the mylo-hyoid muscle, to anastomose with the sublingual. The mylo-hyoid branch of the inferior maxillary nerve lies on this muscle with the artery, together with a chain of lymphatic glands.

The *facial vein* opens either into the external jugular or it joins in a common trunk with the lingual, to open into the internal jugular. Facial Vein.

The remaining anterior branches, or the lingual and internal maxillary, are not dissected in this stage.

The *muscular branch* is very uncertain in its origin, and it may arise either as a distinct trunk from the carotid, or with one of its branches. When it is a branch of the carotid, it is near the superior thyroid, and turns downwards beneath the sterno-mastoid to supply it. Some small branches from it supply the chain of glands. Posterior branches. Muscular.

The *occipital artery* is of considerable size, and has complicated relations. It arises from the posterior part of the carotid, opposite the facial, and at the lower border of the digastric muscle; it ascends obliquely backwards parallel to the muscle, but below it in the neck, to pass above the transverse process of the atlas, and beneath the digastric muscle, to the inner surface of the mastoid process of the temporal bone; it now turns horizontally backwards along the occipital bone, and then upwards to become cutaneous; the remaining portions of the artery have been dissected with the head and back. The cervical portion is crossed by the hypoglossal nerve, by the digastric muscle, and part of the parotid gland, and it crosses the internal carotid and jugular vein, and the spinal accessory and hypoglossal nerves. The only branch from the artery in the front of the neck, is one of the *meningeal* branches to the dura mater in the middle fossa of the base of the skull; it ascends on the internal jugular vein to the foramen lacerum, through which it enters into the skull. Occipital Artery. Meningeal branch.

The *occipital vein* accompanies the artery in the neck, and opens into the internal jugular vein; it receives a large vein from the lateral sinus by the mastoid foramen. Occipital Vein.

The *posterior auris artery*, much smaller than the occipital, arises from the posterior part of the external carotid, above the digastric muscle, it ascends in the same direction as the occipital to the interval between the ear and mastoid process, and it divides, in this spot, into an auricular and a mastoid branch. In the neck the artery crosses the styloid process and its muscles, and it is crossed by the portio dura which is superficial to it, and by the spinal accessory behind it; it is covered also by the parotid gland. A small branch — the *stylo-mastoid* — ascends from this artery to enter the stylo-mastoid foramen, it anastomoses with the vidian branch of the middle meningeal artery, and supplies branches also to the tympanum. The *mastoid* division of the artery is distributed to the back of the head, whilst the *auricular* supplies the ear. Posterior Aural Artery. Stylo-mastoid branch.

The *vein* with the artery is joined by the *stylo-mastoid branch*, Vein.

it enters the parotid, and opens into the trunk formed by the temporal and internal maxillary veins.

Ascending branches. Temporal.

The *temporal artery*, a branch of the external carotid near the condyle of the jaw, is one of the two arteries into which the carotid divides; its direction is that of the trunk, and it appears to be the continuation of the artery. It ascends through the parotid, in the interval between the ear and articulation of the jaw, over the posterior root of the zygoma, and, about two inches above this process of bone, and on the temporal fascia, the artery divides into an anterior and a posterior temporal branch, which were dissected with the external parts of the head.

Transversalis Faciei branch.

Opposite the condyle of the jaw the *transversalis faciei artery* quits the temporal to run inwards over the masseter; and it ends by supplying the muscles of the face and anastomosing with the facial artery.

Parotid branches.

Some *parotid branches* are given to the parotid, and some to the articulation of the lower jaw; some of the parotid branches, larger than the rest, arise separately from the carotid, and extend forwards to the face, beyond the border of the gland.

Middle Temporal branch.

As soon as the temporal has crossed the zygoma, it gives off the *middle temporal artery*, that perforates the temporal aponeurosis, enters the muscle, and anastomoses with the deep temporal from the internal maxillary. A small artery from the temporal is sometimes found between the layers of the temporal aponeurosis, and near the orbicularis muscle it perforates the aponeurosis to supply the muscle.

Temporal Vein.

The *temporal vein* commences on the side of the head, it runs with the artery, and is joined by the middle temporal vein from beneath the fascia; it then descends, superficial to the artery, into the substance of the parotid gland, and joins, on the artery, with the internal maxillary and posterior aural veins, to form the external jugular vein.

The temporal artery is the only branch of the ascending set that can be examined, since the ascending pharyngeal is deep, and in relation with the internal carotid.

Dissection.

The pterygo-maxillary region*, with the internal maxillary artery, and the three divisions of the fifth nerve, follow next in the dissection. Reflect backwards the portio dura and branches of arteries that cover the masseter muscle, and take away any cellular membrane which conceals the muscle, in order that this may be fully exposed. If any cotton wool remains in the mouth, remove it.

Masseter Muscle. Origin.

The *masseter muscle* is situated on the side of the face, and conceals the ramus of the lower jaw. It *arises* from the lower border and external surface of the zygomatic arch by aponeurotic fibres, and from the inner surface by fleshy; the cutaneous

* The description of the right side is not to be taken as a guide in the dissection of the left farther than this point; and the dissector will refer, now, altogether, to the description of the left side.

surface of the origin is marked also on the anterior border by an aponeurosis, which projects into the muscle and divides it into two portions. The fibres of the muscle take different directions from their points of origin; those from the two anterior thirds of the arch pass downwards and backwards to be *inserted* into the angle and ramus of the jaw, and they form the largest and most superficial portion of the muscle; those from the posterior third of the arch, shorter than the anterior, are directed downwards and forwards, beneath the superficial, to be attached to the outer surface of the ramus of the jaw, above the other fibres; whilst the deepest fleshy fibres from the posterior surface of the arch, not so strong as the others, go almost horizontally inwards to be inserted into the outer surface of the coronoid process: these last can be seen only when the arch is raised. The upper part of the muscle is covered by the orbicularis and zygomatic muscles, and the parotid gland extends forwards on it, particularly the part called socia parotidis; it is crossed a little above its middle by Steno's duct, by branches of the portio dura nerve, and by the transverse facial artery; the lower part of the muscle is subcutaneous. The anterior border is in relation with the facial artery and vein, with the buccinator muscle over which it projects, but the buccal nerve and artery appear between the two. Much fat resembling that of the orbit is situated beneath the upper part of the muscle. The posterior border is parallel to the ramus of the jaw, and is in contact with the parotid. The muscle lies on the ramus of the jaw and coronoid process, and conceals the masseteric branch of the fifth nerve and the artery of the same name, which escape by the sigmoid notch to enter the muscle; it conceals also part of the temporal and buccinator muscles.

Insertion.

Relations.

Raise the zygoma by means of two cuts, with the saw, at its extremities; the anterior being inclined downwards and forwards, so as to divide the lower border of the arch close to the superior maxillary bone; and the posterior close in front of the tubercle on the lower border anterior to the articulation of the lower jaw; divide the fascia above it, if it is not done. In raising the arch, the origin of the masseter from its posterior surface, and the insertion of the same into the outer surface of the coronoid process, will be evident. Detach the masseter from the ramus of the jaw to a little below its middle, and follow the masseteric nerve and artery into the muscular fibres. Remove the cellular membrane and fascia from the surface of the temporal muscle, which may be examined at its insertion.

Dissection.

The upper attachment of the temporal muscle was before seen to occupy the temporal fossa, to arise from it as high as the semicircular line bounding it above, and from the outer surface of the great wing of the sphenoid, as low as to the crest

Insertion of the Temporal Muscle.

which separates the temporal from the zygomatic fossa. From this origin the fleshy fibres converge to a tendon which is placed in the centre of the muscle; it is thin and wide above, and receives muscular fibres on both surfaces, but it is thick below and free from muscular fibres, and is inserted into the inner surface of the coronoid process, from the apex to near the last molar tooth; this is better seen when the coronoid process is sawn off. Behind the posterior border of the tendon, between it and the jaw, is the masseteric branch of the nerve and the artery, and in front of the tendon the buccal nerve and artery, which frequently perforate the deep fibres of the tendon of the temporal muscle, and should therefore be carefully avoided in cutting through the coronoid process in the next dissection.

Relations.

Dissection. Saw off the coronoid process by a cut directed downwards and forwards, from the centre of the sigmoid notch to as near the last molar tooth as is convenient, so as to include, if possible, the whole of the insertion of the temporal muscle. Raise up the coronoid process with the temporal muscle attached; the internal maxillary artery is observed beneath it, and the fibres of the temporal muscle, which arise low down, may be seen coming forwards to the deep surface of the tendon: the fibres placed close below these, but directed from within outwards, belong to the external pterygoid muscle. Detach with care part of the temporal muscle from the bone, and the deep temporal arteries and nerves, in the front and posterior part of the fossa, will be found in the fibres of the muscle. The buccal branch of the fifth nerve perforates the external pterygoid muscle. The branch of the same nerve to the masseter muscle is placed between the pterygoid muscle and the bone, and in passing to the masseter runs behind the tendon of the temporal muscle: branches of arteries from the internal maxillary accompany these nerves. On the upper jaw is the superior dental nerve and artery, and between the jaws is situated the pterygo-maxillary ligament, to which the buccinator is attached before, and the superior constrictor behind. Continue the dissection by removing a part of the ramus deprived of its coronoid process, and to do this, make one incision across it near to the condyle, and another through a small tubercle about half an inch below this, on the outer surface of the ramus, which will leave untouched the dental nerve and artery in contact with its inner surface. If the dissector is unable to recognise this elevation, pass the handle of a scalpel beneath the ramus, and, carrying it down as far as the entrance of the nerve and artery into their canal, saw the bone on it: the masseteric branch of nerve and artery are liable to be divided in doing this, and if they cannot be avoided, cut them across and turn them upwards. Take away the loose portion of bone, free the part from cellular membrane, but do not remove the thin membrane of the internal lateral liga-

ment which is beneath the jaw; the pterygoid muscles in this region, and the nerves that come from beneath the upper, can be now observed. The two deep muscles, the pterygoid, in this region, are named internal and external, from their attachments to the internal and external pterygoid plates of the sphenoid bone, and not from their relative position to the surface. The external pterygoid, placed higher than the internal, is directed horizontally outwards, and is attached to the condyle of the lower jaw, but the internal is parallel in direction to the masseter, and extends from beneath the external to the angle of the jaw. The large dental and gustatory nerves, the latter more internal, escape from beneath the border of the external pterygoid. The internal maxillary artery is situated between the jaw and internal pterygoid, separated from the muscle by the internal lateral ligament of the jaw, it then runs over the external pterygoid, or between it and the temporal muscle; but, occasionally, the internal maxillary artery lies beneath, instead of above the external pterygoid.

Internal Pterygoid Muscle.

The *internal pterygoid muscle* is placed beneath the ramus of the jaw, to which it is nearly parallel, and it has almost the same relation to this bone on the inside, as the masseter has on the outside. Its fibres are longer than those of the external pterygoid muscle. It *arises* from the whole pterygoid fossa, but chiefly from the lower part of the inner surface of the external pterygoid plate; the fibres descend obliquely outwards, and are *inserted* into the angle of the jaw. The muscle is placed behind the ramus of the jaw, but separated from it by the internal lateral ligament, by the dental nerve and internal maxillary artery; the gustatory nerve crosses the front of the muscle. It lies against the superior constrictor of the pharynx and the tensor palati muscle, and it corresponds to the tonsil: the insertion of the muscle is in relation with the submaxillary gland. The deep portion of the parotid projects behind the ramus of the jaw, so as to touch the upper border of this muscle.

Origin.

Insertion.

Relations.

External Pterygoid Muscle.

The *external pterygoid muscle* extends outwards and backwards, from the zygomatic fossa, to the condyle of the lower jaw. Its origin is from the outer surface of the external pterygoid plate, from the wing of the sphenoid, below the crest on this bone, and slightly from the tuberosity of the palate bone, and by a pointed process also from the upper margin of the spheno-maxillary fissure; the fibres are directed almost horizontally outwards and backwards — the upper and anterior forming a small bundle separated from the rest by cellular membrane — to end in a thick roundish muscle, which is *inserted* into the condyle of the lower jaw, and into the inter-articular cartilage. It is covered externally by the temporal muscle, from which it is separated by the internal maxillary artery, when this passes over

Origin.

Insertion.

Relations.

the muscle, and near its origin the buccal nerve perforates the muscular fibres. The upper border is in contact with the temporal nerves and arteries; the lower with the dental and gustatory nerves, the internal lateral ligament, and the middle meningeal branch of the internal maxillary artery. Behind the muscle are, the internal pterygoid, the fifth nerve which divides into its branches, the middle meningeal artery, and a plexus of veins, with the internal lateral ligament of the articulation of the lower jaw; but to see these parts the muscle must be turned forwards, and therefore before disarticulating the condyle, dissect the articulation of the lower jaw.

Articulation of the Lower Jaw.

In the articulation of the lower jaw with the temporal bone, which is a hinge joint, the convex condyle of the jaw is received into the anterior concavity of the glenoid fossa of the temporal bone. It is chiefly by the strong muscles attached to the lower jaw, that the surfaces of the bones are retained in contact, since the strength of the ligaments is very inconsiderable. The articular surfaces of the bones are covered with cartilage, and the ligaments that unite them together, are internal and external lateral, with an inter-articular cartilage.

External Lateral Ligament.

The *external lateral* is the small ligament situated on the outer side of the articulation; it is attached, above, to the tubercle at the point of divergence of the two roots of the zygoma, and it descends on the outer surface of the jaw, to be fixed, below, to the outer side of the neck of the inferior maxillary bone. This ligament consists of short thin fibres, wider above than below; its external surface is covered by the parotid, and its internal is in contact with the synovial membranes, and inter-articular cartilage of the articulation.

Internal Lateral Ligament.

The *internal lateral ligament* is a long, thin, membranous process, not closely united to the articulation, nor serving, very materially, as a retaining part. It is attached, above, to the spinous process of the sphenoid, and to the contiguous portion of the temporal bone, but this part is concealed by the external pterygoid, it descends behind this muscle, and in front of the internal pterygoid, to be inserted into the inner and fore part of the orifice of the inferior dental canal of the lower jaw. By the outer or superficial surface it is in relation with the external pterygoid and the articulation, and with the dental vessels and internal maxillary artery, which it separates from the internal pterygoid. It lies on the internal pterygoid muscle.

Besides these ligaments, there are some irregularly scattered fibres which surround the articulation, and serve the part of a capsular ligament.

Dissection.

Remove the external lateral ligament, as well as the scattered fibres surrounding the articulation, so as to open the joint; and an inter-articular cartilage, with a synovial membrane above and below it, will be exposed.

The *inter-articular cartilage* is a moveable plate of fibro-cartilage between the articular surfaces, and it receives their shape; thus it is elongated transversely, is concave below, to receive the convexity of the condyle of the jaw, and convex above, to fit into the concavity of the glenoid fossa; the margins are thicker than the centre, in which spot an aperture sometimes exists. On the outside it is connected to the external lateral ligament; in front, to the external pterygoid; and, on the inner side, to the fibres of the investing capsule. Inter-articular Cartilage.

The *synovial membranes* in this articulation are two; the one above the cartilage lines its upper surface, and the articular cavity of the temporal bone; and the one below the inter-articular cartilage covers the under surface of this process and the convexity of the condyle, and from the condyle it extends on the bone beneath, particularly behind. Synovial Membranes.

Another structure, described as a ligament to this articulation, is the *stylo-maxillary ligament*, or process of the cervical fascia, which is extended from the styloid process to the lower part of the ramus of the jaw, between the attachments of the masseter and internal pterygoid muscles. It separates the parotid and submaxillary glands from each other, and gives attachment to the stylo-glossus muscle. Stylo-maxillary Ligament.

Disarticulate the condyle of the jaw, with the external pterygoid muscle attached to it; and by the careful removal of some cellular membrane, the internal lateral ligament, the fifth nerve and its branches, the middle meningeal artery, the chorda tympani nerve, and the internal maxillary artery, when this runs beneath the external pterygoid, will be seen to be covered by this muscle. The chorda tympani is a very small nerve that descends obliquely forwards, to the gustatory branch of the fifth. By replacing and removing, alternately, the condyle, the relative anatomy is retained, and the dissector is enabled to follow the parts beneath, better than if the muscle were divided. Dissection.

The *internal maxillary artery*, one of the terminal branches into which the external carotid divides at the junction of the upper third of the ramus of the jaw with the two lower thirds, passes directly inwards beneath the jaw, between its ramus and the lateral ligament, and it crosses the dental nerve and internal pterygoid muscle; the artery now winds over the external pterygoid, placed between it and the temporal, and, ascending to the spheno-maxillary fossa, enters it by passing between the two processes of origin of the external pterygoid muscle. In the fossa the artery divides into its terminal branches; but, as the dissection of these requires a vertical section of the head, the examination of them will remain till a view of Meckel's ganglion can be obtained: not unfrequently the artery passes beneath the external pterygoid instead of over it, to enter the spheno-maxillary fossa. When this variety exists, the relations Internal Maxillary Artery.

of it beneath the muscle will be different, and the muscle must be turned forwards to see it.

Branches. The *branches* of the internal maxillary are classed into those which leave the artery between the internal lateral ligament and the jaw, those from this point till it enters the fossa, and the terminal in the fossa.

Internal to the Ramus. Inferior Dental Artery. The *inferior dental*, one of the first of the arteries from the trunk, descends from the lower part of the artery between the internal lateral ligament and the jaw, enters the inferior dental foramen along with the nerve of the same name, and continues with it beneath the teeth, supplying them with branches as far as to the mental foramen, where it divides into two branches, the mental and incisor; the *incisor* continues in the canal beneath the incisor teeth, supplying them with arteries, and it joins with the one from the opposite side; the other, the *mental*, escapes by the mental foramen, along with the branch of the nerve, to ramify in the structures over the lower jaw, and to anastomose with the coronary and inferior labial arteries. A small branch—the *mylo-hyoid*—is given from the artery as it enters the foramen, it descends with the nerve of the same name in a groove on the under surface of the jaw, to the mylo-hyoid muscle, and it anastomoses with the submental artery of the facial.

Incisor branch.

Mental branch.

Mylo-hyoid branch.

Middle Meningeal Artery. The *middle meningeal artery* is of considerable size, and arises from the upper part of the artery between the ligament and the jaw, it ascends beneath the external pterygoid, and crosses to the posterior border of the internal lateral ligament to enter the skull by the foramen spinosum of the sphenoid bone. In the base of the skull it divides into two branches which run between the dura mater and the bone; one grooves the inferior angle of the parietal, the other runs on the temporal bone and finally ascends on the parietal; the branches of both extend to the vertex of the head, and supply the bone and the dura mater. Before the artery enters the foramen spinosum, it gives a small artery, the *tympanic*, which enters the skull through the Glasserian fissure, and anastomoses in the tympanum, with branches from the stylo-mastoid artery, and from the vidian in the hiatus Fallopii. Another small branch, is the *small meningeal*, which enters through the foramen ovale with the fifth nerve, and is distributed to the dura mater in the middle fossa of the skull.

Tympanic branch.

Small Meningeal branch.

Between the Muscles. In the part of the artery between the muscles the branches are nearly all muscular; and their names of masseteric, temporal, buccal, and pterygoid, are derived from the four muscles they supply.

Masseteric Artery. The *masseteric* is a branch which leaves the artery whilst it is covered by the temporal muscle; it passes outwards behind the tendon of this muscle and with the branch of nerve of the same

name; it next runs through the sigmoid notch of the lower jaw into the substance of the masseter muscle, in which it ramifies, and it anastomoses with the other branches that the muscle receives from the carotid.

The *deep temporal arteries*, seen by following them into the fibres of the temporal muscle, are generally two in number, one in the anterior, and the other in the posterior part of the fossa. They turn up into the fossa beneath the temporal muscle, and they ramify in it, anastomosing with branches from the superficial temporal artery. The anterior joins, through the malar bone, with branches of the lachrymal, and through the great wing of the sphenoid, with branches of the middle meningeal artery. When the internal maxillary artery lies beneath the external pterygoid, the posterior branch of the deep temporal turns over the pterygoid muscle to reach the temporal fossa, and it gives off the masseteric branch, but the anterior is altogether beneath this muscle. Deep Temporal Arteries.

The *buccal branch* is long and small, and quits the artery near the upper jaw, it descends obliquely forwards beneath the temporal muscle and coronoid process with the nerve, it is distributed to the buccinator muscle and parts of the face, and anastomoses with the other facial arteries. When the internal maxillary is beneath the pterygoid, this branch perforates this muscle. Buccal Artery.

Numerous small arteries are supplied to the pterygoid muscles, and they have received the name of *pterygoid;* they come either from the trunk, or from some of the branches. Pterygoid Arteries.

The *superior dental artery* arises near the tuberosity of the superior maxillary bone, whilst the internal maxillary is covered by the temporal muscle; it is a very tortuous branch, it descends on the outer surface of the superior maxillary bone, accompanied by branches of nerves from the superior maxillary nerve, and it divides into many branches which enter the foramina in the bone, and supply the molar and bicuspid teeth with blood; some branches from it descend outside the bone to the gums. Superior Dental Artery.

The *infra-orbital branch* is, in direction, the continuation of the internal maxillary, it enters the infra-orbital canal, with the superior maxillary division of the fifth nerve, and it passes to the face to supply it, and to anastomose with the facial. This artery is dissected with the nerve. Infra-orbital Artery.

The *internal maxillary vein* receives the veins that correspond to the branches of the artery in the two first portions of its course, except the *superior dental* and *infra-orbital veins* which join with the veins in the spheno-maxillary fossa, and open into the facial, by means of the *alveolar vein* which appears in the face from beneath the malar bone: two veins accompany the middle meningeal artery, and they open into the trunk of the internal Internal Maxillary Vein. Alveolar.

maxillary vein. The different veins of this part form the *pterygoid plexus*, which is situated, in part, between the pterygoid, and in part between the temporal and pterygoid muscles, it communicates with the superficial temporal veins, and with the veins on the exterior of the skull by the deep temporal veins; and with the facial by the alveolar vein. Small branches of veins from it communicate also through the apertures in the base of the skull, with the sinuses in the interior. The internal maxillary vein passes backwards with the artery, and unites with the superficial temporal in the parotid gland; the common trunk formed by their union receives, in the parotid, the anterior and posterior auricular veins, with the transverse facial and some parotid veins, and it is then named the external jugular vein.

Inferior Maxillary Nerve.

The *inferior maxillary nerve*, the largest of the three divisions of the Gasserian ganglion, leaves the skull through the foramen ovale of the sphenoid bone. In the skull this nerve consists of two portions; a large one from the ganglion, and a small part which is unconnected to the ganglion, and joins with the other portion of the nerve, only after it has passed through the foramen. When the trunk of the inferior maxillary nerve has passed from the skull, and lies in the zygomatic fossa beneath the external pterygoid muscle, it divides into an anterior smaller portion for the supply, chiefly, of the muscles of the jaw, to which the small white band or motor portion of the nerve, found beneath the ganglion in the skull, can be traced; and into a posterior, which, after a short course, divides into three great branches, the inferior dental, gustatory, and auricular or superficial temporal. By turning forwards the external pterygoid, the nerve is seen to lie on the small muscles of the palate, and on the Eustachian tube above the upper border of the internal pterygoid; and to be covered by the external pterygoid, beneath which it divides into branches. From the dissection already made, the distribution of the muscular branches, to be first examined, can be readily followed; they correspond to the arteries of the same name, and they are deep temporal, masseteric, buccal, and pterygoid branches. The internal maxillary artery may be removed if it obstructs the sight of these nerves.

Branches.

Deep Temporal Nerves.

The *deep temporal nerves* are two branches of unequal size, which may arise as separate nerves from the third division of the fifth nerve; or the anterior, which is the larger, may come alone from the trunk of the nerve, and the posterior from the masseteric or the buccal branch. The nerves pass outwards between the bone and the external pterygoid muscle, cross the crest of bone that limits, above, the origin of the pterygoid muscle, and they ascend in the temporal fossa beneath the temporal muscle. The *anterior* nerve frequently communicates with the buccal branch above the external pterygoid muscle,

Anterior.

and divides in the temperal muscle into two branches, whose divisions spread out in its substance to supply it; and the anterior of its two divisions joins, near the orbit, with the branch that enters the temporal fossa from the union of the lachrymal with the orbital branch of the superior maxillary nerve. The *posterior* nerve, sometimes very small, is very irregular in its origin, and is distributed to the posterior part of the temporal fossa: it is frequently absent. Posterior.

The *masseteric nerve* is a large branch that leaves the inferior maxillary nerve, as soon as this has passed into the zygomatic fossa. It runs upwards and backwards between the bone and the external pterygoid muscle, so as to appear at its upper border; the nerve is next directed outwards over the upper surface of this muscle, and passes through the sigmoid notch, or between the articulation of the jaw and the posterior border of the temporal muscle, to enter the under surface of the masseter with the branch of the artery to it. In the masseter the nerve is continued obliquely downwards and forwards, and can be followed to the lower part of the anterior border; it distributes its branches to this muscle as it perforates between the muscular fibres. When the nerve appears above the upper border of the pterygoid it gives a small branch to the temporal fossa, and, near the articulation of the jaw, supplies one or two filaments to this joint. One of the deep temporal nerves occasionally arises from it near its commencement. Masseteric Nerve.

The *buccal branch* arises, by one or two roots, from the inferior maxillary nerve whilst it is covered by the external pterygoid muscle; it is longer than the other branches, passes obliquely downwards and inwards, and perforates the fibres of the external pterygoid; the nerve still continues its direction beneath the coronoid process and the temporal muscle, or frequently through the lower fibres of this muscle, to reach the buccinator, along the lower border of which it runs, distributing filaments to it, and the mucous membrane of the mouth. On the buccinator muscle the nerve lies by the side of the buccal branch of the artery, and divides into its branches of distribution; some of these turn upwards and anastomose in a kind of plexus with the portio dura on the buccinator, and others pass before and behind the facial vein to join also with the portio dura: one of this ascending set of branches sometimes accompanies the duct of Steno to the mucous membrane of the mouth; other filaments are continued downwards towards the angle of the mouth, supplying the integuments; and its lower branches pass beneath the depressor anguli to supply the mucous membrane. As the nerve perforates the external pterygoid muscle it gives filaments to its substance; and after it appears on the surface of the muscle sends upwards a branch to the temporal muscle which it supplies; this joins often with the deep Buccal Nerve.

temporal nerve. This nerve gives few muscular branches in the face.

Pterygoid branches.

The *pterygoid branches* are two or more in number; one branch may be seen entering the under surface of the external pterygoid when it is turned forward, and this muscle receives some other filaments from the buccal nerve. The branch to the internal pterygoid is not seen now, since it is distributed to the under surface of this muscle, and will be dissected on the other side; this branch is connected to the *otic ganglion*, placed on the inner or deep surface of the inferior maxillary nerve. The branches of the other division of the nerve, to which the motor portion is not connected, are the dental, gustatory, and superficial or auriculo-temporal.

Auriculo-temporal Nerve.

The *auriculo-temporal nerve* is a large flat trunk often arising by two portions, between which passes, occasionally, the middle meningeal artery. Its course is almost horizontally backwards beneath the pterygoid muscle, and between the internal lateral ligament and the neck of the lower jaw; and behind this portion of the bone it divides into a superficial branch or superficial temporal, and a deep or auricular branch. The *superficial temporal* turns upwards behind the articulation of the lower jaw, or between it and the ear, then crosses the posterior root of the zygoma, and becomes superficial above the parotid gland; it ramifies on the side of the head: the branches of these have been traced to the vertex. This branch supplies the temporo-maxillary articulation, and where it is about to turn upwards it is joined by two or more branches of the portio dura, which pass backwards around the external carotid artery; and which are now visible, since this part of the portio dura was thrown backwards in order that the union might be seen in this stage. One or two branches, from the point of union of this nerve and the portio dura behind the articulation, perforate between the cartilage and bony portion of the meatus, and are distributed to the lining membrane of this tube. Where the nerve is placed in front of the ear it gives branches to supply the anterior part of the tragus and the pinna above the meatus. The other branch — the *auricular* — descends behind the jaw, forming an interlacement around the internal maxillary artery; it gives a branch to join the dental before it enters the dental canal, and some branches outwards through the parotid, to be distributed to the lobule of the ear, and parts below the meatus: these join with filaments of the auricularis magnus nerve.

Superficial Temporal branch.

Auricular branch.

Inferior Dental Nerve.

The *inferior dental nerve*, a larger and shorter trunk than the gustatory nerve which accompanies it, is directed obliquely downwards and outwards between the two pterygoid muscles, and it lies more externally, or nearer the surface, than the gustatory, whilst they are between the muscles. At the lower border of the external pterygoid, the nerve inclines outwards,

passes in front of the internal lateral ligament, and so enters the dental foramen in the inferior maxillary bone, along with the artery of the same name. In the canal the nerve extends forwards beneath the teeth, supplying them with branches, as far as the mental foramen, where it divides into the mental and incisor branches. The *mental* branch has been seen in the dissection of the face to leave the dental canal by the mental foramen, beneath the depressor anguli, to divide then into branches to supply the structures of the lower lip, and to join with the portio dura: the *incisor* is the continuation of the nerve to the middle line beneath the incisor teeth, and it supplies them with filaments. When the nerve is about to enter the dental canal, a long slender branch, the *mylo-hyoid nerve*, arises from it, passes downwards and inwards in a groove in the bone, in which it is bound down by an expansion of the lateral ligament, and is accompanied by the artery and vein of the same name; at the lower border of the internal pterygoid muscle it quits the groove, and descends to the surface of the mylo-hyoid, to the upper part of which it distributes many filaments, as well as to the submaxillary gland, and anterior belly of the digastric muscle; and some branches perforate the mylo-hyoid to supply the genio-hyoid muscle. *Dental* branches are given from the inferior dental nerve to the teeth beneath which it is placed, the same as in the arteries by which it is accompanied. In some old edentulous subjects, in which the jaw is soft, the nerve may be traced in it, but in other circumstances a piece of the jaw must be immersed in dilute nitric acid till it is softened, if it be wished to follow the branches to the teeth.

Branches.

Mental branch.

Incisor branch.

Mylo-hyoid branch.

Dental branches.

The *gustatory* or *lingual nerve*, the remaining branch of the inferior maxillary, is covered, like the others, by the external pterygoid, and lies on the small muscles of the palate, and on the internal pterygoid. On this last muscle it is placed nearer the middle line than the dental, and at the insertion of the muscle into the angle of the jaw the nerve escapes from between it and the bone, and is continued, under cover of the side of the jaw, to the tongue. A cross branch of considerable size connects the dental and gustatory nerves, but it is often absent. The remainder of the course of the lingual will be resumed with the dissection of the region beneath the jaw.

Gustatory Nerve.

The *chorda tympani*, a small branch of the portio dura, leaves the tympanum by an aperture near the Glasserian fissure, descends forwards from beneath the upper attachment of the internal lateral ligament, to join the outer side of the gustatory at an acute angle, whilst this nerve lies between the pterygoid muscles. It is soon united inseparably to the gustatory nerve. On the surface of the inferior maxillary nerve, which looks towards the muscles of the palate, and immediately below the foramen ovale, is the small otic ganglion of Arnold, which is

Chorda Tympani Nerve.

connected to the nerve; but, as only the outer or cutaneous surface of this nerve is exposed, and the ganglion lies on the inner, its examination must remain till a section of the head and neck can be made; its anatomy will be studied on the other side of the head.

Dissection. The region under the jaw follows next in the dissection. Place the subject over a narrow block with the head thrown backwards, and the side of the jaw raised by some hooks; remove the cellular membrane from the submaxillary gland and mylo-hyoid muscle.

Submaxillary Gland. The *submaxillary gland*, one of the salivary glands, and smaller in size than the parotid, near to which it is placed, lies beneath the side of the jaw in the anterior part of the space circumscribed by the digastric muscle. The shape of the gland is irregularly ovoidal, and it is separated into two parts by the facial artery which is imbedded in it. It is covered on its cutaneous surface by the platysma and cervical fascia, and above this by the side of the jaw and internal pterygoid muscle; over this surface of the gland winds the facial artery in a very tortuous course from the posterior to the anterior border. In front of it is the anterior belly of the digastric, towards which it extends; and, behind, the stylo-maxillary ligament which, in the natural state of parts, separates this gland from the parotid; but the glands touch across this process of membrane when either of them is enlarged. The gland lies on the mylo-hyoid, and round its posterior or free border it sends a process to accompany the excretory duct. Where it projects beyond the mylo-hyoid muscle it lies on the hyo-glossus muscle, and on the hypoglossal nerve. The duct of the gland, called Whartonian, commences by numerous small processes in the granules of the gland, and these unite into larger tubes which form the duct by their union; this lies beneath the mylo-hyoid muscle, and extends to the side of the frænum of the tongue to open into the mouth.

Dissection. Dislodge the submaxillary gland from its natural position under the jaw, so as to expose the mylo-hyoid muscle; leave the process of the gland, which winds round the border of the mylo-hyoid, but its superficial part may be cut off; detach the anterior belly of the digastric from the jaw and throw it downwards. The sublingual artery and mylo-hyoid branch of the inferior dental nerve ramify on the cutaneous surface of the mylo-hyoid muscle: these have been dissected.

Mylo-hyoid Muscle. The *mylo-hyoid muscle* is thin and triangular in shape, it is situated between the jaw and os hyoides, and conceals the muscles and parts in this region. The muscle is wide above where it joins the jaw, and narrow below, at the os hyoides. It

Origin. *arises* from the mylo-hyoid ridge, which begins on the inner surface of the lower jaw behind the last molar tooth, and ex-

tends forwards to near the symphysis of the chin; the fibres pass obliquely downwards and inwards, — the more anterior, shorter than the others, uniting in the middle line of the body, in a "*raphé*" with the upper fibres of the muscle of the opposite side, but the posterior extend to the body of the os hyoides to be inserted into it. On the subcutaneous surface are found the digastric muscle, the submaxillary gland and facial artery, the submental artery and mylo-hyoid branch of the dental nerve, with some lymphatic glands. The inner border is united to its fellow of the opposite side by means of the "*raphé*," but, near the jaw, this is frequently deficient, so as to allow the muscles beneath to be seen; the outer or posterior, the longest, is free, and has winding round it the deep process of the submaxillary gland, which accompanies the Whartonian duct. The parts that the mylo-hyoid covers will be perceived when it is detached.

Insertion. Relations.

To examine the region between the jaw and os hyoides make the following dissection: — cut through the facial vessels where they cross the jaw, remove them with some of the superficial portion of the submaxillary gland, and divide the mylo-hyoid branch of the fifth nerve, and its artery. Separate the origin of the mylo-hyoid from the bone, and the muscle from its fellow along the middle line, and throw it down to the os hyoides; but do this with care, so as not to raise with it a small muscle — the genio-hyoid — which lies close to it, but beneath it. Divide the lower lip in the middle line, and extend the incision to the base of the jaw: saw through the lower jaw a little to the right of its centre or of the tubercles, on the inner surface, to which the muscles are attached, instead of in the middle line, by which the muscles would be injured: seize the apex of the tongue with a pair of hooks, draw it from the mouth over the upper teeth, and fasten it in this position. The side of the jaw is now loose, for it has been previously sawn in the ramus; but it is retained by the mucous membrane which passes from it to the side of the tongue, supports the sublingual gland, and separates the cavity of the mouth from the parts beneath. This portion of bone should not be removed, since much of the relative anatomy would be destroyed, but it is to be turned upwards; and, to enable the dissector to raise this detached piece, divide the mucous membrane which retains it in front, by carrying the knife forwards, between the sublingual glands, to the tip of the tongue, along the side of the frænum: a small artery is divided in cutting the mucous membrane. The portion of the jaw can now be readily turned upwards, and it is to be retained in this position by hooks; the os hyoides may be also fastened down: remove the cellular membrane from the muscles, vessels, and nerves, but take care of a plexus between the gustatory and hypoglossal nerves on the hyo-glossus muscle, and of the small

Dissection.

submaxillary ganglion between the upper part of the gland and the gustatory nerve. The following is the disposition of the parts now exposed beneath the mylo-hyoid muscle: extending upwards from the cornu of the os hyoides to the side of the tongue is a square muscle — the hyo-glossus — which is joined above by a slender muscle — the stylo-glossus — directed downwards and forwards to it; the other styloid muscle — the stylo-pharyngeus — being placed lower down in the neck. On the hyo-glossus is seen the ninth or hypoglossal nerve, the lingual artery being below this level and beneath the muscle, but at the anterior border they come into relation; above the nerve is the Whartonian duct, with the prolonged part of the submaxillary gland, and crossing the duct, so as to be placed below it, is the gustatory nerve: a plexus of nerves connects the trunks of the ninth and gustatory on the hyo-glossus muscle. Above the muscle is the mucous membrane of the mouth, fixed to the jaw, with the sublingual gland and gustatory nerve; a small ganglion — the submaxillary — situated on the deep process of the submaxillary gland, is connected to the gustatory as it passes above this part of the gland. To the posterior part of the mylo-hyoid ridge, and covering the mucous membrane, is the attachment of the superior constrictor. In the middle line, extended from the chin to the os hyoides, is the genio-hyoid muscle, and, deeper than this, a muscle radiating from the jaw to the tongue and the os hyoides, — the genio-hyo-glossus. Along the outer side of this last muscle is placed the continuation of the gustatory nerve to the tip of the tongue, together with the ranine artery, the latter being placed the nearest to it. The ninth or hypoglossal nerve enters the fibres of the genio-hyo-glossus at the inner border of the hyo-glossus, and runs in them as far as to the tip, where it may be again seen. An artery — the sublingual — passes directly outwards to the sublingual gland. Examine first the muscles of this region.

Relations of the parts beneath the Mylo-hyoid.

Hyo-glossus Muscle. Origin. Insertion.

The *hyo-glossus muscle* is thin and square-shaped, and is situated between the side of the tongue and the os hyoides. It is attached below, which is considered its *origin*, to the body, and to the great and little cornua of the os hyoides; the fibres ascend to the side of the tongue, and they are *inserted* into this organ, mingling with the fibres of the stylo-glossus and lingualis. The fibres of origin of this muscle from the hyoid bone are separated into three portions, which has occasioned the division of it, by Albinus, into three distinct muscles: — the portion attached to the great cornu of the os hyoides is called the *cerato-glossus* muscle; that to the body of the bone the *basio-glossus;* and that to the small cornu and cartilage between it and the great cornu, the *chondro-glossus* muscle. The muscle is covered by the anterior belly of the digastric, and by the mylo-hyoid, and near its insertion it is crossed by fibres of the

Relations.

stylo-glossus. On its cutaneous surface are placed the gustatory nerve, Whartonian duct, and process of the submaxillary gland, which often joins the sublingual, and below this is the ninth or hypoglossal nerve; the plexus of nerves between the gustatory and hypoglossal also lies on the muscle near its front. The posterior border covers the origin of the middle constrictor muscle; and the lingual artery, glosso-pharyngeal nerve, and stylo-hyoid ligament pass beneath it; the anterior is close to the genio-hyo-glossus muscle, and the lingual artery escapes from beneath it, and divides into its branches. The muscle covers the attachment of the genio-hyo-glossus to the tongue, the origin of the superior constrictor, with the lingual artery, glosso-pharyngeal nerve, and stylo-hyoid ligament; and at its attachment to the tongue, the lingualis muscle.

Stylo-glossus Muscle. Origin. Insertion. Relations.

The *stylo-glossus muscle*, long and slender, is extended from the styloid process to the side of the tongue. It *arises*, behind, by an aponeurosis, from the lower half of the styloid process, and from the anterior part of the stylo-maxillary ligament. The muscle descends to the side of the tongue, which it joins at the insertion of the preceding into it; at this point it is flattened, and sends forwards a superficial set of fibres, which unite with some of the hyo-glossus, and are prolonged from the base to the point of the tongue: the other fibres are deep, and join the muscular structure of this body. The muscle lies between the two carotid arteries, and is covered by the parotid gland, stylo-maxillary ligament, and by the facial artery; by the mylo-hyoid muscle, by the gustatory nerve and Whartonian duct which cross it, and by the submaxillary gland. It lies on the superior constrictor, on the internal carotid artery, with the jugular vein and its accompanying nerves, and on the hyo-glossus muscle.

Genio-hyoid Muscle. Origin. Insertion. Relations.

The *genio-hyoid* muscle, situated in the middle line, close beneath the mylo-hyoid muscle, and between the lower jaw and os hyoides, *arises* from the lower of the two tubercles on the inner surface of the base of the jaw, above the attachment of the digastric. The fibres form a roundish belly in passing downwards and backwards to be *inserted* into the middle of the upper part of the body of the os hyoides. This muscle is covered by the mylo-hyoid, and lies on the genio-hyo-glossus; the inner border is close to its fellow of the opposite side, and is often united with it. The upper part of this muscle is frequently subcutaneous, by reason of the deficiency in the mylo-hyoid.

Genio-hyo-glossus Muscle.

The *genio-hyo-glossus muscle*, named from its attachment, is the largest of the small muscles of this region, it is fan-shaped, is in close contact with the one of the opposite side, and it radiates from the chin to the under surface of the tongue and

Origin. the os hyoides. The muscle *arises* from the upper tubercle behind the symphysis of the lower jaw, by a tendon from which the fibres radiate backwards; the most anterior extending to
Insertion. the tip of the tongue; those farther back to the under surface of this organ; and the most posterior pass downwards beneath the hyo-glossus muscle to the small cornu of the os hyoides, and are united, beneath this muscle, with the fibres of the middle constrictor, thus assisting to close the pharynx in this position. This attachment is better seen when the hyo-glossus is afterwards divided. The muscle is in contact internally with the
Relations. one of the opposite side, so as to form a septum along the middle line. The lower border touches the genio-hyoid muscle, and the upper is turned forwards beneath the tip of the tongue, and is covered only by mucous membrane. On its outer side are the hyo-glossus and mylo-hyoid muscles, the sublingual gland, the ranine artery which is in close contact with it, and farther out the gustatory nerve; the ninth nerve perforates its fibres and runs forwards between them. At its insertion into the tongue it lies nearer the middle line than any other muscle which joins this organ. A fibrous membrane is situated near the os hyoides, between the lower attachments of the muscles of opposite sides.

Lingualis Muscle. The *lingualis muscle*, placed on the under surface of the tongue and to the outer side of the genio-hyo-glossus, where some longitudinal fibres mark its position, is wide behind but
Origin. narrow in front. It *arises*, posteriorly, from the base of the tongue, and its longitudinal parallel fibres run forwards to the
Insertion. tip, in which they terminate. This muscle is better seen when
Relations. the tongue is removed. It lies between the genio-hyo-glossus, internally, and the stylo-glossus, externally; and the lingual nerve and artery are in contact with it in their course forward to the tip of the tongue. Each half of the tongue is formed, for the most part, by the fibres of this muscle, and the other muscles of the tongue join it.

Lingual Artery. The *lingual artery* is one of the anterior or internal branches of the external carotid, which were omitted in the description of this vessel, because of their deep relations. It arises from the inner side of the external carotid between the superior thyroid and facial arteries, or even by a common trunk with the facial; it runs forwards and inwards above the cornu of the os hyoides, the superior thyroid lying below this bone, to be placed beneath the hyo-glossus. The artery now runs obliquely upwards and forwards beneath this muscle to the under surface of the tongue, and divides at the anterior border of the hyo-glossus into its terminal branches, the ranine and sublingual arteries. Between the origin of the artery and the border of the hyo-glossus muscle, it lies on the middle constrictor of the pharynx; it is at first superficial, and is covered only by the

skin, platysma, and fasciæ; but it is soon crossed by the tendon of the digastric, by the stylo-hyoid muscle, and also by the ninth nerve, which, placed below it in the neck, crosses above it previously to its passing beneath the hyo-glossus muscle. In the second part of its course, or from the border of the hyo-glossus to the base of the tongue, it is more deeply seated beneath the hyo-glossus and mylo-hyoid muscles, and the hyo-glossus separates it from the ninth nerve which is placed on the cutaneous surface of the muscle, but higher up than the artery. At the anterior border of the hyo-glossus the nerve and artery are again found together, but the nerve is the lowest; so that they have crossed each other whilst in contact with the muscle, and have changed, at the inner or anterior border, the relations that they had at the outer. This portion of the artery lies on the constrictor and genio-hyo-glossus muscles: the glosso-pharyngeal nerve is situated nearer the os hyoides, and therefore above the artery beneath the hyo-glossus muscle. The branches of this artery are the following: — A small branch from it, as it passes above the os hyoides, is the *hyoid;* this runs along the upper border of the os hyoides, as the other hyoid branch from the superior thyroid artery did along its lower border; it passes beneath the digastric muscle, and anastomoses with the one of the opposite side, and with the branch of the superior thyroid, and supplies the muscles attached to this bone. The *dorsalis linguæ branch* leaves the artery when it is covered by the hyo-glossus muscle, and to see it some of the fibres of the hyo-glossus must be separated. It runs vertically upwards about the middle of the muscle to the side of the tongue, and gives branches for the supply of this organ, and the tonsil. The *sublingual artery* is one of the terminal branches into which the lingual divides at the anterior border of the hyo-glossus muscle. This artery runs outwards to the sublingual gland under cover of the mylo-hyoid, and divides into numerous branches for the supply of the gland and for the mylo-hyoid muscle; and it sends a small artery inwards to the middle line above the frænum, to anastomose with a similar one from the opposite side: this was divided with the mucous membrane of the mouth. Some small branches also pass outwards to supply the gums and lower jaw. The artery to the sublingual gland is often derived from the submental artery of the facial, and perforates the mylo-hyoid muscle to reach the gland. The *ranine*, the longest and largest branch, appears the continuation of the artery, and runs forwards from the anterior border of the hyo-glossus to the tip of the tongue, where it ends by anastomosing with the ranine artery of the opposite side. This branch lies external to the genio-hyo-glossus, and is closely applied to the lingualis on the under surface of the tongue; the gustatory branch of the fifth nerve, which ac-

Hyoid branch.

Dorsalis Linguæ branch.

Sublingual branch.

Ranine branch.

companies it, is nearer the lateral portion of the tongue: in its course it distributes many branches to the muscular structure of this organ.

Veins. The *lingual vein* commences in plexuses which occupy the upper and under surfaces of the tongue; the latter are the larger, and are called *ranine*. The trunk accompanies the artery, and opens either into the internal jugular vein, or joins with the facial.

Gustatory Nerve. The *gustatory* or *lingual* nerve has been seen to be a branch of the inferior maxillary after it has passed through the foramen ovale, and it has been traced to the point where it passes between the jaw and internal pterygoid muscle. The continuation of the nerve can now be observed to escape, posteriorly, from the internal pterygoid muscle, then to pass downwards and forwards to the side of the tongue along the upper border of the deep process of the submaxillary gland, and to cross the attachment of the superior constrictor to the posterior part of the mylo-hyoid ridge, as well as over the mucous membrane of the mouth; the nerve now changes its direction, and runs forwards below the sublingual gland, and along the lingualis muscle to the tip of the tongue. In this last part, the nerve crosses the Whartonian duct which ascends behind it to the sublingual gland; it is external to the cavity of the mouth, from which it is separated by the mucous membrane, and it lies to the outer side of the ranine artery. Numerous small filaments leave the nerve whilst it is placed beneath the tongue; these ascend, forwards, through its substance, and are distributed to the conical and fungiform papillæ which occupy the anterior part of the tongue, and some join with filaments of the hypoglossal nerve: the nerve ends at the apex in a single filament.

Branches to Superior Constrictor. Submaxillary Ganglion. When the nerve lies on the attachment of the superior constrictor it gives some small filaments to it, to the mucous membrane of the mouth, and to the tonsil. Near the submaxillary gland it is joined to a small plexus, the *submaxillary ganglion*, one of the scattered ganglia of the sympathetic in the neck, which is situated at the upper and posterior part of the deep process of the gland. It is a small, hard, reddish body, sometimes seen to be oblong in shape, and is rather smaller than the ophthalmic or lenticular ganglion. By the upper part it is connected to the gustatory, by means of filaments, in the form of loops, attached to the lower part of the nerve; from the lower, numerous long branches pass downwards to the submaxillary gland to which they are distributed; and from its anterior part the longest and largest branches pass forwards and upwards, beneath the gustatory, to be distributed to the mucous membrane of the mouth. Near the inner border of the hyoglossus muscle numerous filaments descend to join with filaments of the ninth nerve, to form a plexus in front of it.

To join with the Ninth.

From the upper part of the nerve as it passes by the sublingual gland many filaments are distributed to this gland and the mucous membrane of the mouth. Those to the gland appear to form a plexus. The nerve then terminates by being distributed to the papillæ of the tongue. To the Sublingual Gland.

The *ninth* or *hypoglossal nerve* has been dissected in that part of its anatomy which crosses the neck, and is superficial; and it is now exposed in the third part, where it is again deep as in the first, and extends forwards and upwards to the tongue. At the os hyoides the nerve crosses beneath the tendon of the digastric, but is above the level of the lingual artery; it next passes beneath the posterior border of the mylo-hyoid muscle to reach the hyo-glossus, and on the cutaneous surface of this last muscle it lies below the Whartonian duct and gustatory nerve, and superficial to the artery which is beneath the muscle. At the anterior border of the muscle the nerve lies below the artery, enters the fibres of the genio-hyo-glossus muscle, and continues forwards along the middle line of the tongue, threading the fibres of this muscle, as far as the apex, where it is placed much nearer the ranine artery than it was at the base of this organ. This nerve is not near the gustatory in its position along the tongue, since it is placed in the middle line, and low down in the fibres of the genio-hyo-glossus muscle, whilst the gustatory is on the lateral part of the tongue, and close beneath the mucous membrane. The ninth nerve supplies the muscular structure, and the gustatory the papillæ of this organ. The Ninth or Hypoglossal Nerve.

Beneath the mylo-hyoid, and on the hyo-glossus muscle, the nerve is flattened, and gives branches to the hyo-glossus muscle, and some ascending filaments to the stylo-glossus; it then gives numerous filaments from its upper part, which ascend on the hyo-glossus, to join with the gustatory, and form a kind of plexus on this muscle near its inner border. At the inner border of the hyo-glossus the nerve gives some filaments to the genio-hyoid muscle, it then sinks between the fibres of the genio-hyo-glossus, and supplies the structure of the tongue, giving off many long filaments, which run upwards and forwards, with the anterior branches of the ranine artery, to enter the under surface of the tongue, and some of these join with filaments of the gustatory nerve. Branches. To the Hyo- and Stylo-glossus. To the Gustatory Nerve. To the Genio-hyoid. To the Tongue.

The *sublingual gland* is another of the salivary glands; it is situated beneath the anterior part of the tongue, external to the mucous membrane, and is lodged in a fossa on the inner surface of the jaw, close to the symphysis; its shape is that of an almond, and its longest measurement is obliquely outwards and backwards. The gland touches, above, the mucous membrane of the mouth, which is raised beneath the tongue in a crescentic fold, and separates it from the cavity of the mouth; the gustatory nerve winds round the lower part. The outer surface is Sublingual Gland.

in contact with the ramus of the jaw, and the inner with the genio-hyo-glossus muscle, but it extends to the middle line across the border of this muscle, and touches the gland of the opposite side. The gland consists of numerous small granules, in which excretory tubes commence; these unite together to form the ducts of the gland, which, about seven in number, open in the fold of mucous membrane beneath the tongue.

Duct of the Submaxillary.

The *duct of the submaxillary gland*, or the Whartonian duct, is accompanied by the deep process of the gland that turns round the free border of the mylo-hyoid muscle. It is formed by the junction of the small excretory ducts from the grains of the gland, runs upwards and forwards between the mylo-hyoid and the hyo-glossus, placed at first below the gustatory nerve, but it crosses above the nerve before it reaches the gland, and opens on the side of the frænum in the centre of a papilla; if a bristle be passed along the duct into the mouth, its aperture beneath the tongue will appear. The duct consists of a fibrous and a mucous coat, like other excretory tubes. The process of the gland that is found with the duct extends often as far as the sublingual gland.

Dissection.

The anatomy of the third division of the fifth nerve and of the submaxillary region being completed, the remaining second division of this nerve, or the superior maxillary nerve, may be taken next, since it can be dissected now without destroying the relations of any other part. This nerve passes from the great Gasserian ganglion, through the foramen rotundum, and across the spheno-maxillary fossa, to enter the orbit before it appears in the face; so that to obtain a complete view of this nerve will require the orbit to be opened, and a portion of the middle fossa of the skull to be removed. As the orbit is open, cut along the floor of the middle fossa of the base of the skull, with a chisel, from the sphenoidal fissure in front, to the foramen spinosum behind, and direct the incision immediately external to the line of the foramen rotundum and of the foramen ovale; the division of the bone is not to extend farther back than the foramen spinosum, or the superficial petrosal nerve will be destroyed. Make an oblique cut through the side of the skull, in front of the meatus auditorious externus and Glasserian fissure, into the foramen spinosum, to meet the one in the base, and without dividing the chorda tympani nerve. Saw almost horizontally backwards into the spheno-maxillary fossa, through the outer wall of the orbit, and a little above the zygoma; this incision should leave untouched the malar branch of the superior maxillary nerve, but the temporal branch of this same nerve will be taken away with the outer wall of the orbit. The portion of bone forming part of the middle fossa of the skull and outer wall of the orbit can now be removed in one piece, with the temporal muscle attached to it, and the deep temporal

nerves and arteries are to be divided. This dissection exposes the second and third divisions of the fifth, leaving the skull through their respective apertures, together with a view of the spheno-maxillary fossa and side of the orbit. If any portion of bone should conceal the nerve as it crosses the spheno-maxillary fossa, remove it with a bone forceps, and leave only a ring of bone to surround the nerve at its exit: take away the cellular membrane from the fossa, avoiding the orbital branch of this nerve, some small branches sent up to it from Meckel's ganglion, which lies deeply in this space, and also some small nerves that descend on the upper maxillary bone to the teeth. Lay open the canal in the floor of the orbit, in which the nerve lies in its course to the face, and follow the anterior dental branch that descends in a bony canal in the front of the superior maxillary bone. To dissect only this nerve in a subject, the orbit is to be opened, the pterygoid region dissected, and then the incisions made in the bone as described above: these different steps may be referred to.

Superior Maxillary Nerve.

The *superior maxillary nerve*, or second division of the fifth, intermediate in size and position between the ophthalmic and inferior dental nerves, commences in the Gasserian ganglion, leaves the cranium by the foramen rotundum, and crosses the upper part of the spheno-maxillary fossa, to enter the infra-orbital canal with the artery and vein of the same name; at the anterior part of the orbit the nerve escapes from this canal beneath the elevator of the upper lip, and is distributed, as was seen in the face, to the muscles, mucous membrane, and integuments, whilst other branches join with the portio dura in a kind of plexus.

Branches. Orbital branch.

The *orbital branch* arises as soon as the trunk of the nerve has passed through the foramen rotundum; it then crosses the spheno-maxillary fossa with the trunk, but superior to it, enters the orbit through the spheno-maxillary fissure, and in its outer and inferior angle divides into a malar and a temporal branch: these have been traced to the face and the temporal region.

Branches from Meckel's Ganglion.

In the spheno-maxillary fossa the superior maxillary nerve is connected to Meckel's ganglion, which is placed beneath it, by two or more short ascending branches that join it.

Posterior Dental branches.

The *posterior dental nerves*, two or more in number, leave the nerve as it is about to enter the infra-orbital canal; they descend along the tuberosity of the superior maxillary bone, and give off filaments to supply the gums and the buccinator muscle; the nerves then enter the canals in the bone, and run above the posterior teeth, sending off filaments for the supply of the mucous membrane of the antrum, and for the different roots of the molar and bicuspid teeth. One of these, the *posterior superior dental*, enters a canal above the teeth, runs forwards round the malar tuberosity, and joins with a filament from the anterior

Posterior Superior.

Posterior Inferior. dental opposite the canine fossa; another, the *posterior inferior dental*, larger than the superior, runs forwards below the malar tuberosity, and ends by joining the superior opposite the canine fossa. It is from these two nerves that the branches for the teeth, bones, and antrum arise; but to follow these minute branches requires a recent bone, softened in dilute nitric or hydro-chloric acid.

Anterior Dental branch. The *anterior dental branch* quits the nerve whilst in the infra-orbital canal, and about one inch before this appears in the face. The branch runs, at first, outwards from the trunk of the nerve, enters a canal in the superior maxillary bone in front of the antrum Highmori, in which it descends as far as to the floor of the nasal fossa, and here divides into numerous filaments; some of these are directed inwards in the bone beneath the nasal aperture, supplying the incisors in the middle line, as well as some small filaments to the lining membrane of the nose; and others turn outwards, and supply the remaining incisor and canine teeth, and one long filament joins with the posterior superior dental nerve. Whilst the nerve lies in its canal, some very fine filaments pass downwards, through canals in the bone, to supply the lining membrane of the antrum. The anterior dental nerve may be traced for some distance in its canal in the bone, but to follow it satisfactorily the bone requires to be softened.

Infra-orbital Nerve. When the nerve reaches the face, it is called *infra-orbital*, and it divides into numerous branches; ascending to supply the eyelid, conjunctiva, and side of the nose; nasal to the lateral part of the nose, and around its aperture; and descending to the muscles, integuments, and mucous membrane of the upper lip: these unite with branches of the facial.

Infra-orbital Artery. The *infra-orbital artery*, with the superior maxillary nerve, is a branch of the internal maxillary artery before this enters the spheno-maxillary fossa to divide into its final branches. The artery enters the infra-orbital canal with the superior maxillary nerve, continues along it to the face, and when it leaves the bony canal by the infra-orbital foramen, is covered by the elevator of the upper lip; it then divides into many branches that supply the integuments and muscles of the face, and the gums of the teeth, and anastomose with the facial and transverse facial arteries. In the canal it gives small branches downwards to the bone, lining membrane of the antrum, and the teeth, with the anterior dental nerve; the branch that accompanies the anterior dental nerve anastomoses with the posterior dental arteries.

Vein. The *vein* with this artery does not open into the internal maxillary vein; but it unites with the veins that accompany the branches of the internal maxillary artery in the spheno-maxillary fossa, to form the large alveolar vein which joins the facial.

Dissection. Return to the dissection of the remaining styloid muscle be-

fore exposing the internal carotid and ascending pharyngeal arteries, and the nerves at the base of the skull. Detach the posterior belly of the digastric, and the stylo-hyoid muscle from the styloid process, and throw them down; the communicating filament of the portio dura nerve, which perforates the digastric muscle to join the glosso-pharyngeal nerve soon after it has left the skull, will be observed to pass downwards. Divide the trunk of the external carotid rather above where it is crossed by the ninth nerve, and cut through the branches of the artery already dissected, so as to take away this portion of the artery. The veins that form the external jugular, or join the internal, may be removed if necessary. Remove the cellular membrane from the stylo-pharyngeus muscle, and dissect out the glosso-pharyngeal nerve in contact with it.

Stylo-pharyngeus Muscle. Origin.

The *stylo-pharyngeus muscle* is small and elongated, like the other styloid muscles, but it is situated deeper than they, and also lower down in the neck. It *arises* from the inner side of the base of the styloid process and from its vaginiform process; the fibres descend, expanding, and the muscle formed by them enters between the superior and middle constrictors of the pharynx, in which position it terminates by some of its fibres uniting with those of the constrictors, and by others being *inserted* into the posterior border of the body of the thyroid cartilage. The muscle is covered by the external carotid, the parotid gland, and, below, by the hyo-glossus muscle; it crosses the internal carotid artery and jugular vein, with the eighth and ninth nerves. Its position in the neck is lower than the stylo-glossus; and the stylo-hyoid ligament, which has the same direction, lies between it and the stylo-glossus. The glosso-pharyngeal nerve crosses the lower border of the muscle to reach its front, and then passes beneath the hyo-glossus muscle; some of the filaments of the nerve supply it.

Insertion. Relations.

Stylo-hyoid Ligament.

The *stylo-hyoid ligament* is a fibrous structure that extends from the tip of the styloid process to the small cornu of the os hyoides; its direction is obliquely downwards and inwards between the stylo-glossus and stylo-pharyngeus muscles, and, near its lower attachment, it lies beneath the hyo-glossus muscle and the lingual artery. It passes with the styloid muscles between the two carotid arteries; to its posterior border is attached the middle constrictor muscle, and it supports the facial artery: it is frequently ossified.

Dissection.

Detach the styloid process at its base, and throw it downwards and inwards to the middle line with its muscles attached; raise upwards and forwards the loose portion of the jaw, the external carotid artery and parotid gland having been previously removed. Beneath the dense fascia that now appears, are the internal carotid and ascending pharyngeal arteries, with the internal jugular vein; the eighth, ninth, and sympathetic nerves

between the internal carotid and jugular vein, near the base of the skull; and external to these is the loop of the first and second cervical nerves around the transverse process of the atlas. Cautiously remove this fascia, without destroying the portions of the eighth nerve which diverge from each other, or the branches from these contained in the fascia; the glosso-pharyngeal nerve of the eighth, and its numerous pharyngeal branches cross downwards and inwards over the artery; the spinal accessory division of the same nerve backwards, either over or under the jugular vein; and the pneumo-gastric descends with a deep position, in the middle line, between the vein and artery: it is chiefly the glosso-pharyngeal and its branches, with the nerves of the pneumo-gastric to the pharynx and larynx that are likely to be removed, for the other nerves are deeper, and will be dissected after the removal of the artery. The ninth nerve appears between the vein and artery. To expose the portion of the internal carotid artery in the petrous portion of the temporal bone, and to observe the relations of the nerves as they pass through the different apertures in the base of the skull, remove the projecting part of the temporal bone that conceals them, by the following division of the bone: — Place the saw above and behind the mastoid process in the horizontal section made to remove the brain, and carry it obliquely downwards and forwards through a part of the mastoid process, the stylo-mastoid foramen, the root of the styloid process already removed, through the vaginal process in front of the foramen lacerum jugulare, and along the outer part of the carotid foramen, which is not to be opened by the incision, as far as to the foramen spinosum in the great wing of the sphenoid, to which point the side of the skull has been taken away.* The portion of bone marked off by the saw is now detached, and is to be removed; and the turns of the carotid artery in its course through the temporal bone are rendered apparent by cutting away, with a bone forceps, the bone that conceals it. In dissecting the artery in the canal, it will be found to be enveloped by large reddish filaments of the superior cervical ganglion of the sympathetic, which ascend with the artery to the cavernous sinus, and form the carotid plexus; joining the plexus, behind, is a very small filament that perforates the wall of the canal, and comes from Jacobson's nerve in the tympanum; at the front and lower part of the plexus is another small nerve from the vidian; this enters the carotid canal by the foramen lacerum, and is concealed by the spicula of bone between the foramen ovale for the fifth nerve, and the foramen lacerum: this is to be taken away to see it. The description of this plexus is deferred till the

* This section should not be attempted without a prepared base of the skull as a guide.

examination of the superior cervical ganglion of the sympathetic; and the other nerves will be afterwards followed through their canals. Place the portion of temporal bone that is sawn off into dilute acid, in order that the meatus, the tympanum, with its chain of bones and chorda tympani nerve, which are contained in it, may be dissected.

Internal Carotid Artery.

The *internal carotid artery*, the other branch of bifurcation of the common carotid, and designated internal from its supplying the parts within the head, extends from the upper border of the thyroid cartilage to the front of the sella turcica of the sphenoid bone, and it ends by dividing, internal to the anterior clinoid process, into cerebral branches which ramify in the brain. The extent of the artery may be divided into a cervical, a temporal, and a cranial portion, in consequence of the difference both in its direction and relations, whilst placed in these different parts of its course: the cranial portion of the carotid by the side of the body of the sphenoid bone, in which part it makes a remarkable turn, was dissected with the base of the skull. In the neck the vessel ascends vertically, from its point of division, in front of the three or four upper cervical vertebræ to the foramen caroticum in the petrous portion of the temporal bone, and it is accompanied, as the common carotid, by the internal jugular vein, and by the pneumo-gastric and sympathetic nerves that have nearly the same relation to it. It is situated, at first, on the outer side of the external carotid and on the same level; but as these ascend in the interval between the ear and mastoid process, this artery is placed beneath the external carotid, and much deeper than it. The depth of the artery from the surface differs, like the external carotid, much in its course, and the digastric muscle, or a line marking its direction and situation, may be taken as the index of this change of its position; for, below the muscle, the artery is very superficial in the anterior triangle of the neck, it is covered only by the integuments, platysma, and fasciæ, and is crossed by the hypoglossal or ninth nerve, by the occipital artery, and by some small veins and cutaneous nerves, so that this part of the vessel may be readily secured by a ligature. Above this muscle it is situated deeply on the spine, beneath the digastric and stylo-hyoid muscles, and the trunk of the external carotid artery and the parotid gland; and crossing the artery, in contact with it, are the stylo-glossus and stylo-pharyngeus muscles, with the stylo-hyoid ligament, the glosso-pharyngeal nerve and its branches, the pharyngeal branch of the pneumo-gastric nerve, though this is sometimes behind it; and the deep portion of the parotid gland dips down and touches it: these parts separate it from the external carotid artery which is superficial to it. The carotid lies on the rectus capitis anticus major muscle, and on the superior laryngeal nerve, which separate it from the spine; above this, on the superior cervical

Cervical portion.

ganglion of the sympathetic, and when it is about to enter the skull, on the eighth and ninth nerves. On the inner side of the carotid are situated the pharynx and ascending pharyngeal artery; the tonsil lies also internal to the artery, and when it is enlarged, passes backwards and comes into contact with it. To the outer side are the internal jugular vein and the pneumo-gastric nerve: the vein has the same relation to the internal as to the common carotid artery, till near the base of the skull, where it separates slightly from it, and in the interval are seen the eighth and ninth nerves. In passing through the carotid canal, in the petrous portion of the temporal bone, the artery makes a curve that is similar to the bend by the side of the body of the sphenoid. It first ascends in front of the cavity of the tympanum and the cochlea, from which it is separated by only a very thin plate of bone, it next turns horizontally inwards and forwards, on the inner side of the Eustachian tube, which has been removed by the dissection for the artery, then rests on the cartilaginous substance that closes the foramen lacerum basis cranii, between the body of the sphenoid bone and the petrous portion of the temporal, and finally turns upwards to enter the cavity of the skull and the cavernous sinus, by perforating the dura mater. The ascending filaments of the superior cervical ganglion of the sympathetic nerve surround this part of the artery, and form, by their union, the carotid plexus. The internal carotid trunk remains much the same size from its commencement to its termination, and it usually gives off no branch till it has entered the skull: occasionally, it will be found very tortuous in the neck.

Temporal portion.

Internal Jugular Vein.

The *internal jugular vein*, the principal vein for the return of the blood of the arteries of the head and face, — the external jugular receiving the blood of about only three of the veins of all those that accompany the branches of the external carotid artery, — is a continuation of the lateral sinus which ends at the lower border of the foramen lacerum jugulare; it extends vertically through the neck to the sterno-clavicular articulation, and ends by joining the subclavian vein in the brachio-cephalic trunk. As far as to the thyroid cartilage it accompanies the internal carotid, but below that point the common carotid artery, and it lies to the outer side of both these vessels, but separated, in its whole course, by the pneumo-gastric nerve. Its position to the artery is not equally close from the commencement to the termination, for as soon as it has passed from the skull it is dilated, and is separated from it by a small interval in which are the eighth and ninth nerves. At the lower part of the neck there is a larger space, and in it lies the pneumo-gastric nerve; the vein too, in this part, crosses the subclavian artery, and is in front of the position of the carotid; and on the left side, the vein is still nearer the sterno-clavicular articulation than the

artery, and is parallel to the subclavian trunk instead of crossing it at right angles. The relations of the vein, with reference to muscles, are so similar to the arteries that they do not require a special notice; the nerves that come forwards between the vein and artery, to reach the front of the body, are directed inwards over the artery, and the spinal accessory that is directed backwards passes either over or under the vein. The internal jugular receives the blood of the sinuses of the interior of the skull, by means of the lateral sinuses, and remains of much the same size till near the os hyoides, it is then joined by the branches from the outer part of the head and face, and is increased in size. The branches that it receives are the veins that accompany the arteries of the external carotid, but do not join the external jugular, viz. the *superior thyroid, lingual, facial, occipital*, and *ascending pharyngeal veins:* it has a branch of communication with the external jugular, and in its lower part is joined by a small vein, — the *middle thyroid*, — which crosses the common carotid artery. Branches.

The *ascending pharyngeal artery*, the only remaining branch of the external carotid, is a long slender artery, and it generally arises from the point of division of the common carotid, or very near the commencement of the external carotid artery. It is placed at first between the two carotid vessels, and it then ascends on the spine, near to the internal carotid, or between this and the pharynx, and it approaches the skull, to terminate by dividing into branches for its base and for the pharynx. Near the skull this artery is very tortuous, and lies in a quantity of loose cellular membrane, and in its course it gives external branches to the recti muscles on the spine, as well as to the sympathetic and the nerves which lie on it: these anastomose with the ascending cervical artery; and the internal branches, larger and more numerous than the external, are directed inwards to the middle and inferior constrictors of the pharynx: they supply these muscles with the stylo-pharyngeus, and ramify in the mucous membrane. Its final branches of distribution, near the skull, are a meningeal and a pharyngeal artery: the *meningeal branch* ascends beneath the carotid artery, and gives off small branches close to the skull to supply the muscles of the spine and the nerves near the base, and one of these enters by the foramen lacerum basis cranii, to supply the dura mater in the middle fossa of the skull; the *pharyngeal branch*, larger than the other, turns downwards and inwards to the side of the pharynx, and divides into many branches; some of these enter the upper constrictor, whilst others perforate the fibrous structure that attaches the pharynx, are distributed in the mucous membrane, and ramify on the Eustachian tube. The size of this artery is very irregular, for when the inferior palatine is small, its capacity is increased, and *vice versâ;* or Ascending Pharyngeal Artery. Meningeal branch. Pharyngeal branch.

this artery may supply branches which have a distribution similar to the inferior palatine.

Vein. The *vein* with this artery commences in a plexus on the pharynx; this is joined by meningeal and vidian branches, and receives pharyngeal branches from the pharynx; it joins the internal jugular vein.

Dissection. The three divisions of the eighth nerve, — viz. the pneumo-gastric, spinal accessory, and glosso-pharyngeal — are now to be followed through the foramen lacerum jugulare; and to expose the small branches of these in the foramen will require very great care, even if the subject is not so much decomposed as to destroy their texture; but to make a perfect dissection of these small nerves requires a fresh subject, and the bone to be softened in acid. Cut across the internal jugular vein near the skull, and remove it or draw it down; the internal carotid may be also cut through if necessary, and a portion of it be taken away without injuring the branches of the sympathetic nerve. Remove, bit by bit, with a bone forceps, the osseous ring that bounds externally and in front the foramen lacerum, as far as to the ridge of bone that separates the foramen lacerum from the carotid foramen; in taking away the bone the auricular branch of the pneumo-gastric is found on its inner surface, it extends backwards, between the bone and coats of the vein, to enter a small foramen near the styloid process.* The pneumo-gastric forms a flat semilunar ganglion, like the Gasserian of the fifth, in the canal, and to it the spinal accessory is united by two or more filaments from it. Below the foramen the pneumo-gastric is joined, in a plexiform body, with the ninth nerve, and it has branches of communication with the spinal accessory and glosso-pharyngeal — the other two divisions of the eighth — and with the sympathetic, and loop of the atlas. The spinal accessory nerve is in close contact with the pneumo-gastric, as it passes through its foramen, and is united to the ganglion of this nerve; below the foramen it joins the pneumo-gastric by a large communicating branch. The glosso-pharyngeal nerve passes through a part of the foramen separate from the other two divisions of the nerve, and in doing so it also forms a ganglion, but this cannot now be seen, since it lies deeply in a depression — the receptaculum ganglii petrosi — on the lower border of the petrous portion of the temporal bone; but, as soon as it escapes from this depression, it gives off a very small nerve — the nerve of Jacobson — which enters the foramen in the crest of bone separating the carotid foramen from the foramen lacerum, and to reach it, it will be necessary to cut away small portions of this osseous ridge until the small nerve is arrived at. The dissector may be unable to find the nerve, because

* The assistance of the base of a skull will be necessary to complete this dissection.

of the variety in the position of its aperture; for it is oftentimes on one side of the crest, instead of in its centre, or it may be exceedingly minute. Below the foramen, the glosso-pharyngeal nerve also joins the portio dura, and gives off a branch to the pneumo-gastric. The ninth nerve is beneath the eighth, and is united to the pneumo-gastric, to the sympathetic, and to the loop of the atlas. The arch around the transverse process of the atlas, and the ganglion of the sympathetic will be afterwards dissected.

Eighth Nerve.

The *eighth nerve*, consisting of the three divisions of glosso-pharyngeal, pneumo-gastric, and spinal accessory, arises from the medulla oblongata and spinalis, and leaves the skull by the foramen lacerum jugulare, — the glosso-pharyngeal passing through an aperture in the dura mater distinct from that for the pneumo-gastric and spinal accessory. As soon as these divisions have left the skull, they lie side by side between the internal jugular vein and internal carotid artery, but rather behind them and concealed by them; they soon separate from each other, the glosso-pharyngeal crosses over the artery and descends obliquely inwards to the pharynx; the spinal accessory passes backwards, over or under the vein, to the sterno-mastoid and trapezius muscles; and the pneumo-gastric descends vertically between the artery and vein to the thorax and abdomen.

Glosso-pharyngeal division

The *glosso-pharyngeal nerve*, the smallest division of the eighth, in its passage through the foramen lacerum, lies external and anterior to the other nerves, and is contained in the depression in the posterior or lower border of the petrous portion of the temporal bone: at this point the nerve is enlarged, and forms a gangliform body — the *petrous ganglion* or ganglion of Andersh. After the nerve has passed from its foramen, it is more superficial than the other two divisions, comes forwards between the vein and artery, and is directed downwards and inwards to the middle line, over the carotid artery, and beneath the styloid process and the muscles that arise from it, to the lower border of the stylo-pharyngeus muscle; the nerve now changes its direction, runs forwards to the front of this muscle, crosses it so as to be placed between it and the stylo-glossus, and forms an arch across the neck, by the side of the stylo-pharyngeus, and above the superior laryngeal nerve; it then enters beneath the hyo-glossus muscle, and, if this is divided, it will be found to lie below the tonsil, and to divide into its branches for the supply of the tonsil and tongue. Whilst it lies beneath the hyo-glossus it is intermediate in position between the gustatory nerve above and the hypoglossal below, but it is deeper than either.

Branches.

The branches of this nerve are numerous, and may be divided into those of union with other nerves, and those of distribution to the neck.

Of union. With the Otic and Meckel's Ganglion by Jacobson's Nerve.

Jacobson's nerve, the first branch of the glosso-pharyngeal, arises close below the petrous ganglion; it runs upwards and outwards on the crest of bone that separates the carotid foramen from the foramen lacerum, contained either in a groove or a partly bony canal, enters the canal in this crest, is conducted by it to the inner wall of the tympanum, and in this cavity it divides into its final branches; one joins with the large petrosal nerve of the vidian, from Meckel's ganglion, and another — the small petrosal — connects it to the otic ganglion. To trace the ultimate distribution of this branch requires the bone to be softened in acid: its anatomy will be given with the ear. As soon as the nerve has passed through the skull, it receives the branch of communication with the portio dura; this perforates the digastric muscle, and passes downwards and inwards, behind the styloid process, to join with it. After the preceding branch, the glosso-pharyngeal is joined to the pneumo-gastric by a small branch that is inclined downwards and outwards to it: this connection is sometimes absent. The *carotid filaments* are many long branches that arise whilst the nerve crosses the carotid; they descend on the artery and join on it with branches of the sympathetic that ramify on its coats, and also with the pharyngeal branch of the pneumo-gastric nerve: this junction with the pharyngeal branch is, oftentimes, the only union between this nerve and the pneumo-gastric.

With the Portio dura.

With the Pneumo-gastric.

With the Sympathetic.

Of distribution. To the Styloid Muscles. Pharyngeal branches.

The nerve supplies the digastric and stylo-hyoid muscles by a branch that arises near the base of the skull, descends beneath the styloid muscles, and divides into filaments to supply their structure. Numerous filaments are given to the stylo-pharyngeus muscle from the nerve in front of it. When the nerve comes into contact with the stylo-pharyngeus muscle it gives off numerous branches to the pharynx, these descend obliquely inwards to the upper and middle constrictor muscles, and, opposite the latter, they form, with the other nerves of the pharynx, the pharyngeal plexus. Beneath the hyo-glossus muscle it gives off many filaments that descend to near the os hyoides and supply the mucous membrane of the base of the tongue, and of the epiglottis; it gives many branches to the amygdala by the side of which it lies, and these form a kind of plexus around this body. The continuation of the nerve then ascends, and, by the side of the tongue, divides into two branches; one is distributed on the dorsum of this body, and the other reaches the under part, and then perforates its structure to reach the upper surface: the distribution of these nerves to the mucous membrane of the tongue is limited to the portion of this organ occupied by the papillæ circumvallatæ, and some of the filaments can be followed into the papillæ. The branches to the tongue are dissected with this organ.

To the Mucous Membrane. To the Tonsil. To the Tongue.

Pneumo-gas-

The *pneumo-gastric* or *vagus nerve*, the largest division of the

eighth, remarkable for its extent and important functions, extends through the neck and thorax into the abdomen. The nerve passes through the central compartment of the dura mater in the foramen lacerum, between the inferior petrosal vein and lateral sinus, and in the foramen it is enlarged, and forms a distinct plexiform ganglion, to which the spinal accessory is connected as it passes in the same sheath of dura mater. When it leaves the canal it is enlarged a second time, is united to the hypoglossal, gives branches to the other nerves found in this part, and is situated between the jugular vein and internal carotid artery, but concealed by the two; with this relation it descends through the neck as low as the thyroid cartilage, but it then continues between the vein and common carotid artery to enter the thorax between the subclavian vein and artery; at the lower part of the neck the nerve separates from the carotid, and crosses the subclavian in a space between this vessel and the jugular vein. The pneumo-gastric lies on the rectus capitis anticus minor muscle, then on the lateral part of the body of the atlas, which is uncovered by muscular fibre, over the rectus capitis anticus major muscle, from which it is separated by the ganglion of the sympathetic, and lower down in the neck, it is placed on the longus colli muscle. The relations of this nerve in the lower part of the neck, on the left side, are examined with that side, and the portions of the nerve in the thorax and abdomen are dissected with the cavities in which they are found.

tric division.

The branches of union of this nerve with others are numerous, and take place whilst it is both within and without the foramen lacerum. From the ganglion formed on the nerve in the canal some filaments pass to unite it and the spinal accessory together, which has caused this nerve to be considered, by some, as analogous to a spinal nerve, of which the cranial portion of the pneumo-gastric would be the sensitive, and the cranial portion of the spinal accessory the motor root. Below the foramen, too, the nerve receives another very large communicating branch from the spinal accessory. In the aperture the nerve gives off, below its ganglion, the *auricular branch* of Arnold, — this runs on the outer wall of the jugular foramen, between the bone and the vein, enters a small foramen near the root of the styloid process, and joins the portio dura nerve whilst it is in the aqueduct of Fallopius; a small filament from this branch joins the nerve of Jacobson, but this is frequently destroyed. When the pneumo-gastric has passed through the foramen it is united inseparably to the ninth nerve which winds round it from the posterior to the anterior part, and the two are so closely joined that they appear, oftentimes, as one gangliform mass. Near the base of the skull the pneumo-gastric sometimes receives a small communicating filament from the glosso-pharyngeal: it is

Branches of union.

With the Spinal Accessory.

With the Portio dura by the Auricular branch.

With the Ninth.

With the Glosso-pharyngeal.

With the Sympathetic and Loop of the Atlas

joined by one or more filaments from the ganglion of the sympathetic, which is behind it, and also by some filaments from the loop of the first and second cervical nerves around the transverse process of the atlas.*

Branches of distribution.

The branches of distribution more important than the others arise from the inner side of the nerve, and are directed to the middle line of the neck.

Pharyngeal Nerve.

The small *pharyngeal nerve* leaves the inner side of the pneumo-gastric opposite the upper border of the body of the atlas, and it arises either from the trunk of the nerve or from the communicating branch between it and the spinal accessory; it descends obliquely inwards over the internal carotid, though sometimes behind this vessel, and forms an arch across the neck, from which are given off carotid branches to join, on the artery, with filaments of the glosso-pharyngeal, and surround it with an interlacement. The nerve then descends to the side of the pharynx, and, opposite the middle constrictor muscle, it joins with branches of the glosso-pharyngeal, laryngeal, and sympathetic nerves, in the *pharyngeal plexus*.

Plexus.

Superior Laryngeal Nerve.

The *superior laryngeal nerve*, much larger in size, arises from the inner side of the nerve opposite the interval between the first and second cervical vertebræ, it descends beneath both carotid arteries, and in front of the longus colli muscle, to the pharynx and larynx, and forms an arch across the side of the neck lower down than the glosso-pharyngeal nerve; it now crosses the upper border of the middle constrictor of the pharynx, runs forwards on the thyro-hyoid membrane beneath the thyro-hyoid muscle, with the laryngeal branch of the superior thyroid artery; the nerve then perforates the membrane, enters the larynx, and its distribution is followed in the dissection of the larynx: it supplies, for the most part, the mucous membrane. The nerve occasionally enters the larynx by an aperture in the side of the thyroid cartilage. Whilst this nerve is covered by the internal carotid artery it gives off the *external laryngeal branch* for the outside of the larynx; this descends below the superior laryngeal, but in the same direction, communicates with the descending cardiac branches of the sympathetic which it crosses, and at the side of the larynx it gives some small filaments backwards to supply the inferior constrictor and join with the pharyngeal plexus; the continuation of the nerve then turns forwards with the descending branch of the superior thyroid artery, but lower than it, beneath the omo-hyoid, sterno-hyoid, and thyroid muscles, to be distributed to the outer surface of the thyroid body; and one long filament descends to supply the crico-thyroid muscle.

External Laryngeal branch.

Cardiac Nerves.

The small *cardiac branches* of this nerve, which join with

* The pneumo-gastric sometimes sends a filament to the descendens noni, or this nerve may come altogether from the pneumo-gastric.

the cardiac nerves of the sympathetic, are derived from two sources; some small filaments arise high in the neck, and join the descending cardiac nerves from the sympathetic ganglia; and in the lower part of the neck, about one inch, or rather more, above the brachio-cephalic artery, the pneumo-gastric gives off its large cardiac branch, which descends, in close contact with this vessel, to join, in the thorax, with other cardiac nerves, and with the superficial cardiac plexus. On the left side, this lower branch enters the chest by the side of the left carotid artery.

Inferior Laryngeal Nerve

The *inferior laryngeal* or *recurrent nerve*, the last branch of the pneumo-gastric in the neck, leaves the trunk of the nerve, on the right side, as it enters the thorax, and it will be dissected by taking away the cellular membrane that surrounds it. It passes from before backwards round the subclavian artery, and then ascends obliquely inwards to the larynx, beneath the common carotid and inferior thyroid arteries, and along the trachea, lying between it and the œsophagus; and it enters the larynx beneath the inferior constrictor, and ala of the thyroid cartilage. On the left side, the nerve arises in the thorax opposite the arch of the aorta, and ascends between the trachea and œsophagus to the larynx. The recurrent gives off many branches in its course; thus, where it turns round the subclavian, it sends off cardiac nerves which descend to join, in the thorax, with the cardiac nerves of the sympathetic, and with the deep cardiac plexus. As the nerve ascends along the trachea, it gives numerous filaments backwards to the œsophagus and posterior part of the trachea; and when it is about to enter beneath the constrictor muscle it supplies filaments to it.

Cardiac Filaments.

To the Trachea.

Œsophagus.

Constrictor.

Spinal Accessory division.

The *spinal accessory portion* of the eighth nerve is intermediate in size between the two others, it passes through the same aperture in the dura mater as the pneumo-gastric, and is united by one or two filaments with the ganglion of this nerve. At its exit from the skull it is internal to the jugular vein, and rather concealed by it; the nerve is then directed obliquely downwards and backwards, either over or under the vein, and when beneath, it lies on the rectus capitis lateralis muscle, and the transverse process of the atlas. It now passes beneath the styloid process and muscles, and, at the lower border of the digastric muscle, it is superficial along the anterior border of the sterno-mastoid, placed in the great anterior triangle of the neck, and lies on the levator anguli scapulæ; about one inch below the digastric, it perforates the sterno-mastoid, as before seen, crosses the posterior triangle, joining with the cervical plexus, and it is distributed to the trapezius near its clavicular attachment.

Branches of union.

Besides the union between this nerve and the ganglion of the pneumo-gastric in the foramen lacerum, it gives off, soon after

With the Pneumo-gastric. passing through the skull, a second communicating branch to the pneumo-gastric, which is sometimes very large, and may be traced to join with the pharyngeal branch of this nerve. In the Cervical Plexus. posterior triangle, the nerve also joins with the cervical plexus.

Of distribution. The branches of distribution of this nerve are, to the sterno-mastoid and trapezius muscles, as before dissected.

Ninth or Hypo-glossal Nerve. The *ninth* or *hypoglossal nerve*, the motor nerve of the tongue, has been dissected in two parts of its course, so that it remains only to observe its relations whilst placed in the first part of its course, or before it reaches the lower border of the digastric muscle. The nerve consists of two portions that arise from the medulla oblongata, and unite together as they escape from the anterior condyloid foramen, by which it passes from the skull. External to the skull it is situated beneath the pneumo-gastric, and somewhat nearer the middle line, it then passes backwards beneath this nerve but over the sympathetic, which separates it from the spine, comes forwards round the outer side of the pneumo-gastric, closely or inseparably united to it, and it appears between the internal carotid artery and the jugular vein. The trunk of the nerve now descends beneath the digastric muscle, hooks round the occipital artery, becomes superficial, and crosses the neck to enter beneath the mylo-hyoid, and so it reaches the tongue, to which it is distributed.

Branches of union. With the Pneumo gastric. Sympathetic and Loop of the Atlas This nerve is united, like the divisions of the eighth, to some of the nerves in this part. Whilst it is winding round the pneumo-gastric, it is closely joined to it by an inter-communication of filaments, and oftentimes they appear to form but one ganglion. The nerve receives also some filaments of union from the superior cervical ganglion of the sympathetic, and from the loop in front of the atlas, formed by the first and second cervical spinal nerves.

Of distribution. The branches of distribution of this nerve to the muscles of the os hyoides and tongue, and to the substance of this body, are included in the dissections of the anterior great triangle, and the submaxillary region.

Dissection. Between the transverse process of the atlas and the base of the skull is a small muscle, the rectus capitis lateralis; the cellular membrane is to be removed from it. A small branch of nerve, the anterior branch of the sub-occipital, appears at its inner border; the loop that this forms with the second, in front of the atlas, and the branches of communication from it to the other nerves at the base of the skull are to be dissected out, if this has not been sufficiently done.

Rectus lateralis Muscle. Origin. Insertion. The *rectus capitis lateralis muscle* is small and thin, and it is analogous in position to the inter-transversales muscles of the cervical region. It *arises*, below, from the upper part of the transverse process of the atlas; the fibres ascend, and are *inserted* into the jugal eminence of the occipital bone, close behind the

foramen lacerum. The anterior surface of the muscle is covered by the internal jugular vein, and by the spinal accessory nerve, and the posterior is in contact with the vertebral artery; to its inner border is the anterior branch of the first cervical nerve which appears from beneath it. Relations.

Remove the rectus lateralis muscle, observing, at the same time, the filaments to it from the first nerve; the vertebral artery is now seen to pass through the aperture in the transverse process of the atlas, and then to lie on the posterior arch of this bone. Cut off the tip of this process to lay open the foramen in it, and remove the vertebral artery to expose the anterior branch of the first cervical nerve, which is beneath, and concealed by it; the nerve sends down one or two filaments, with the artery, through the foramen, and these are not to be destroyed in removing it. Dissection.

The *anterior branch* of the first cervical, or sub-occipital nerve, commences in the ganglion on the arch of the atlas: it is a long slender branch, and runs horizontally forwards on this bone beneath the vertebral artery; it crosses the aperture in the transverse process, internal to the ascending part of the artery, and appears in front, at the inner border of the rectus lateralis muscle. The nerve now turns down in front of the lateral part of the first vertebra, and joins with an ascending branch from the second nerve to form a loop around the bone, which distributes many branches of communication to the other nerves: this is the portion of the first cervical nerve that joins the cervical plexus, and was concealed when the plexus was dissected. From the convexity of the arch formed in front of the transverse process, numerous branches are given off, and they pass inwards beneath the internal jugular vein: two or more of these filaments join with the pneumo-gastric nerve, and with the ninth; some short greyish filaments connect the loop to the superior cervical ganglion, and other branches ascend to supply the rectus capitis anticus major muscle. Opposite the foramen in the transverse process, the nerve sends down one or more filaments in the canal with the artery; these join with the ascending filaments of the sympathetic which surround it, and form on it the vertebral plexus; one of these filaments unites with the trunk of the second cervical nerve, as this passes forwards over the vertebral artery. The nerve supplies some branches to the rectus lateralis and rectus capitis anticus minor muscles. Anterior branch of the Sub-occipital. Branches from the Loop. To the Pneumo-gastric, Ninth, and Sympathetic. To the Vertebral Plexus and Muscles.

The *sympathetic system of nerves*, characterised by their greyish colour, and gangliform enlargements in different situations connected together by intervening cords or filaments, is found in the head and neck, thorax, and abdomen. In the two great cavities of the body, certain large centres or plexuses are formed by these nerves, in front of the vertebral column, to The Sympathetic Nerve.

supply branches to their contained viscera; and along each side of the spine is a gangliated cord to join with the spinal nerves as they leave their intervertebral foramina. Although this system does not extend, as distinct nerves, to the extremities, it yet joins the branches of the spinal nerves that enter into the cervical, lumbar, and sciatic plexuses, for the supply of these. In the head and neck the sympathetic nerve consists of a chain of ganglia, placed at certain distances from each other, either on the spine or in intervals between the bones of the head; and these are connected together by filaments which, in some situations, are large and easily traced, but in others very small, and difficult to follow. In this portion of the body the ganglia are united, by branches, to all the cervical spinal nerves, and to most of the cranial nerves; and the complicated distribution of these filaments of connection constitutes the greater part of the minute anatomy of the head and neck. The following are the ganglia and plexuses which are found in the head and neck, and serve as centres of communication with the other nerves: — three cervical ganglia,—superior, middle, and inferior; the carotid plexus in the carotid canal, the cavernous in the sinus of the same name in the interior of the skull; the ganglion of Ribes on the anterior communicating artery of the brain; and the lenticular ganglion in the orbit: these four last may be considered but as prolongations from the superior cervical ganglion. The remaining ganglia are the spheno-palatine, or ganglion of Meckel, in the pterygo-maxillary fissure; the sub-maxillary ganglion on the submaxillary gland; and the otic or ganglion of Arnold on the fifth nerve.*

Dissection. It will require greater care to dissect out the filaments of this system of nerves than to follow the branches of the spinal nerves, for they are softer, and therefore more easily torn, and are generally smaller in size; the branches and ganglia in the neck are, in a great measure, exposed by the previous dissection, but the number of filaments that remain depend upon the care with which the neck has been dissected. The three ganglia of the neck are situated on the spine, the superior being close to the base of the skull, the inferior on the neck of the first rib, and the middle about midway between the other two: a connecting cord is found between the ganglia, and from their inner side are given off the cardiac nerves that descend to the thorax beneath the carotid artery. The upper cervical ganglion is partly exposed, but to see its branches, it will be necessary to cut across the filaments that connect the eighth and the ninth nerves to the loop of the atlas, and these nerves should be raised with hooks; if the carotid has not been cut through, remove now a portion of it: the internal jugular vein has been

* Another ganglion was said, by Cloquet, to exist in the anterior palatine foramen; but this has since been found to be incorrect.

cut across. The middle ganglion is found in the cellular membrane beneath the sheath of the vessels of the neck, when these have been taken away; it usually lies on the inferior thyroid artery, or it is very near to it: this ganglion is sometimes absent. To obtain a view of the inferior ganglion, the clavicle and greater part of the first rib are to be taken away, part of the subclavian artery removed, without destroying the branches that pass over the artery; and the ganglion, with its branches, will be found on the neck of the first rib.

Superior Cervical Ganglion.

The *superior cervical ganglion* is an oval or fusiform body, varying in length and shape, of a reddish grey colour, and it is situated opposite the bodies of the second and third cervical vertebræ. This ganglion is the largest of the sympathetic ganglia of the head and neck, and gives off most branches of communication to the other nerves. It is covered by the carotid artery, jugular vein, and by the eighth and ninth nerves, and it lies on the rectus capitis anticus major muscle which separates it from the bodies of the vertebræ; external to it are the anterior branches of the cervical nerves, with which it communicates. The branches of the ganglion are very numerous, some joining with the other nerves at the base of the skull, and others supplying the pharynx and heart: they are classed into ascending and descending, outer and inner, and anterior branches.

Ascending branches.

The *ascending branches*, two very large nerves, appear to be a prolongation upwards of the ganglion; they ascend with the carotid into its osseous canal, extend through this space with the artery, one on each side of it, and they give off numerous filaments that surround the vessel, and form the carotid plexus. At the upper aperture in the skull the nerves still accompany the vessel, and give rise, in the cavernous sinus, to the cavernous ganglion; minute filaments from this also extend along the trunk of the artery and its branches to the brain, and form the ganglion of Ribes on the anterior communicating artery. The cavernous ganglion, and its branches of communication with some of the cranial nerves, were dissected with the base of the skull.

Carotid Plexus.

The *carotid plexus*, formed by the ramifications of the ascending branches of the superior cervical ganglion around the carotid artery in its canal, sends branches of union to certain nerves, or it receives branches of union from these. Thus a small branch passes from the posterior part of the plexus, through the osseous boundary of the canal, to join on the inner wall of the tympanum with Jacobson's nerve, or this filament may be considered as a filament from Jacobson's nerve to join the plexus. The anterior part of the plexus is united to the vidian nerve by a small branch that diverges from it as this nerve is about to enter the cranium by the foramen lacerum basis cranii, and it is close against the spicula of bone that sepa-

Branch to Jacobson's Nerve.

To the Vidian Nerve.

rates the foramen ovale from the foramen lacerum: this branch may be considered, thus, a nerve from the carotid plexus to the vidian, and, through its medium, to the second division, or superior maxillary nerve of the fifth, or it may be taken, in the opposite way, as a branch of the vidian. From the upper and outer part of the plexus, two small filaments are given off to join the sixth nerve as it crosses the outer side of the carotid artery in the cavernous sinus.

To the Sixth Nerve.

From the lower part of the ganglion descends the large cord that appears to be the continuation of the nerve to the next ganglion; it varies in size and length, and descends vertically beneath the internal carotid, jugular vein, and pneumo-gastric nerve, to opposite the fifth or sixth cervical vertebra, to end in the middle, or, if this be absent, in the inferior cervical ganglion. In its course in the neck, the nerve sends, externally, filaments which pass between the scalenus anticus and longus colli muscles, to join the anterior divisions of the fourth and fifth cervical nerves, and at this spot it is enlarged in size; internally it gives small filaments to join the cardiac nerves, and the external laryngeal of the pneumo-gastric.

Descending branch.

The *external filaments* join with the anterior divisions of the spinal nerves, and connect them to the sympathetic. They pass transversely outwards over the rectus capitis major muscle, and the greater number join the loop of the atlas; the third spinal nerve sometimes receives its filament from the ganglion and sometimes from the descending branch. The difference in colour between these nerves and those of the cerebro-spinal system is very marked.

External branches.

The *internal branches* from the ganglion are numerous, and are pharyngeal and cardiac. The *pharyngeal* are directed obliquely inwards, with the pharyngeal branch of the pneumo-gastric, to the back of the pharynx; and opposite the middle constrictor these branches unite with the pharyngeal nerves in the plexus, and supply the pharynx. The *cardiac* nerves, so named from supplying the heart, are three in number on each side, — one coming from each ganglion, and named superior, middle, or inferior, according to the ganglion from which it arises. The *superior* or *superficial cardiac nerve* of the right side, formed by the internal branches of the superior ganglion, and joined, generally, by some small filaments from the connecting cord between the upper and the middle ganglion, descends to the lower part of the neck, beneath the great vessels, and in front of the longus colli muscle and the inferior thyroid artery and recurrent nerve; it now enters the thorax by passing either before or behind the subclavian artery, and descends, along the brachio-cephalic trunk, to the posterior part of the arch of the aorta to join the deep cardiac plexus. This nerve receives some small filaments from the cardiac branches of the pneumo-

Internal branches.

Pharyngeal.

Cardiac.

Superior Cardiac Nerve.

gastric, and gives others to the pharynx and the recurrent nerve; frequentiy, it divides into filaments near the inferior thyroid artery; some of these pass over, and some under this vessel.

The *anterior filaments* from the front of the ganglion are connected to the pneumo-gastric, and to the ninth cranial nerve. The other branches of this set—the *nervi molles*—pass forwards to the carotid arteries, and join with the carotid filaments of the glosso-pharyngeal to the coats of the vessels; these nerves are distributed on the branches of the external carotid, and they form small secondary plexuses on the different branches, which receive the same names as the arteries that they surround. The plexus that accompanies the facial artery is said to supply the submaxillary gland, and to join the submaxillary ganglion. These nerves are destroyed in dissecting the branches of the arteries.

Anterior branches. Nervi molles.

The *middle cervical* or *thyroid ganglion* is situated opposite the fifth or the sixth cervical vertebra, near to the inferior thyroid artery, or it is placed in contact with either its superficial or deep surface. It is roundish in shape, is beneath the large vessels of the neck; and the filaments from it are divided into external, internal, and inferior. In some subjects this ganglion is absent.

Middle Cervical Ganglion.

Two or more *external filaments* pass outwards between the contiguous borders of the scalenus, and the longus colli muscles, to join the sixth and seventh spinal nerves as soon as they escape from their foramina. When this ganglion is absent, the filaments of communication to the spinal nerves arise from the connecting trunk between the upper and the lower ganglion.

External branches

The *internal filaments* are the most numerous; some of these form ramifications around the inferior thyroid artery and its branches, and are distributed to the thyroid body and œsophagus, joining with the external laryngeal and recurrent nerves; other filaments unite to form the *middle* or *great cardiac nerve*, which descends to the thorax beneath the great vessels of the neck, and continues along the brachio-cephalic trunk to the posterior surface of the arch of the aorta, to join the cardiac plexus. This nerve is generally joined by branches from one or both of the other cardiac nerves, also by cardiac branches of the pneumo-gastric, and by filaments from the recurrent nerve which it crosses.

Internal branches. Middle Cardiac Nerve.

The *inferior* or *descending filaments* are many; some of these pass before and some behind the subclavian artery, and they join, below, the inferior ganglion.

Inferior branches.

The *inferior cervical ganglion*, irregular in shape, occupies the interval between the transverse process of the last cervical vertebra and the first rib, and it frequently extends in front of the neck of the rib to join the first thoracic ganglion. It is

Inferior Cervical Ganglion.

situated behind the vertebral, and internal to the superior intercostal artery; filaments are given off from the different parts of this ganglion, as in the two others; thus there are ascending, descending, anterior, internal, and external.

Ascending branch. The *ascending filament* connects this ganglion with the one above, and forms the communicating cord between them.

Descending. The *descending filaments* consist of two short cords which connect this to the first thoracic ganglion; these branches are sometimes absent, and the substance of the ganglion extends to the first thoracic, and joins it.

Anterior. The *anterior* arise from the front of the ganglion, they come forwards to encircle the subclavian, and some filaments extend along the branches of this artery.

External. The *external filaments*, from the outer part of the ganglion, join the lower cervical nerves which enter into the cervical plexus; these should be followed outwards to their union with the nerves. Other branches of this set enter the foramen in the transverse process of the cervical vertebra, with the vertebral artery, and form, around this vessel, the *vertebral plexus*, which joins with some of the cervical nerves.

Vertebral Plexus.

Internal. Inferior Cardiac Nerve. The *internal branch* or the *inferior cardiac nerve* is the chief branch from the ganglion, it descends beneath the subclavian artery, and joins with filaments from the recurrent nerve; it then enters the thorax, and joins the cardiac plexus, behind the arch of the aorta, and in front of the trachea.

This completes the anatomy of those parts of the right side that can be advantageously examined, and it now remains to dissect the lower portion of the other half of the neck, in which the difference between the relations of the two sides will be found; and also the other parts of the head and neck which have not yet been seen.* In the following description of the left side, it is chiefly the differences between it and the right that are noticed, and the dissector will be directed to turn to the description of the right, when that will suffice.

DISSECTION OF THE LEFT SIDE OF THE HEAD AND NECK.

Dissection of the Orbit. The dissection and the anatomy of the orbit are to be proceeded with as on the right side, if this has not been done at the same time as the other orbit.

Of the Posterior Triangle. For the dissection of the neck, make this part tense over a

* It is impossible that some of the remaining dissections can be made on each side; if, therefore, there should be two dissectors to the head and neck, they must join in the performance of them.

narrow block, and if the posterior triangle has been omitted, examine it; then continue with the dissection of the anterior part of the neck, and anterior triangle, and use the description of the right side as far as to the subclavian artery. Of the Anterior.

The *subclavian artery* of the left side differs greatly, in the first part of its course, from that of the right side, since it arises as a separate branch from the arch of the aorta in the thorax, instead of from a trunk, common to it and the carotid, opposite the sterno-clavicular articulation. The artery forms an arch over the first rib to reach the upper extremity, and it is divided, as the right, into a portion internal to the scalenus, one beneath this muscle, and one which extends from its outer border to the lower margin of the first rib. It is the portion internal to the scalenus that differs so much from the similar part in the vessel of the opposite side, since it ascends vertically out of the chest, to reach the first rib, is longer than on the right side, and does not extend to so high a level in the neck, but lies deeply in the thorax and lower part of the neck, in contact with the œsophagus and spine. The portion of this first division of the artery, contained in the thorax, will be described with the dissection of that cavity, and the relations of the part in the neck are the following: — in front of the artery, but at a distance from it, are the integuments and fasciæ, the sterno-mastoid, hyoid, and thyroid muscles, the anterior jugular vein, sternum, first rib, and clavicle; superficial to the vessel, but parallel and somewhat internal to it, is the common carotid, which, on this side, arises by a single trunk from the arch of the aorta. The pneumo-gastric nerve, instead of crossing it at right angles, lies parallel to it and in front of it, and enters the thorax between the internal carotid and jugular vein; the internal jugular vein, in like manner, is parallel to the artery but superficial to it, and at the lower part of the neck inclines outwards to join with the subclavian in the brachio-cephalic vein of this side. The artery is accompanied by branches of the sympathetic, or by the cardiac nerves of this side, — the superior being in front, the middle on its outer side, and the inferior nerve beneath. Behind the artery are the longus colli muscle, and the inferior cervical ganglion of the sympathetic, which separate it from the spine; to the inner side is the œsophagus, and between it and the vessel, the thoracic duct; to the outer side is the neck of the first rib, over which the subclavian turns, and the pleura envelopes the vessel on this side. Sub-clavian Artery.

The two remaining portions of the artery, beneath the scalenus and beyond it, are the same on both sides of the neck; the branches, too, resemble so closely those of the right side that they do not require a separate description; they arise sooner from the vessel, lie rather deeper in the chest, and are longer in contact with the pleura. For the description of these parts of the

artery, see the dissection of the opposite side. After the subclavian artery, take the thoracic duct, which is now exposed.

Thoracic Duct. The *thoracic duct**, so named from the greater portion of it occupying the cavity of the thorax, is the channel by which the nutritive and effete particles enter the general circulation. It escapes through the upper aperture of the thorax, along with the subclavian artery, to open into the venous system near the union of the left subclavian and jugular veins. In the neck it lies between the subclavian vein and the œsophagus, ascends as high as the seventh or the sixth cervical vertebra, and then turns downwards and outwards, forming an arch whose concavity looks downwards, to open into the subclavian vein, external to its junction with the internal jugular. It is situated at first beneath the carotid artery, though not in contact with it, except it rises very high in the neck, and it is placed on the longus colli muscle; it is between the œsophagus and subclavian artery, below, but after this vessel is directed outwards, it is between the œsophagus and vertebral artery. Opposite the seventh or sixth cervical vertebra, the duct is directed outwards to the vein, and this transverse part crosses in front of the vertebral artery and vein, the thyroid axis, and the anterior scalenus muscle and phrenic nerve; and beneath the internal jugular vein and pneumo-gastric nerve, but separated from the subclavian artery by the scalenus muscle. The arch that it forms is placed higher than that of the subclavian, but below the arch of the inferior thyroid artery. The duct is frequently divided into many portions before entering the vein.

Brachial Plexus. Take next the brachial plexus described on the other side, and then the difference between the left and right common carotid arteries.

Common Carotid Artery. The *left common carotid artery* differs from the right, in commencing in the thorax, as a single vessel, from the arch of the aorta, whilst the vessel of the right side begins in the bifurcation of the brachio-cephalic trunk, into carotid and subclavian, opposite the sterno-clavicular articulation. It is therefore longer than the right, lies deeper in the chest, and ascends almost vertically from it to reach the sterno-clavicular articulation; the portion of the artery, between its origin and the upper part of the sternum, has relations different from the vessel of the right side, but above this they are the same. In front of the carotid is the sternum, with the origins of the sternal muscles, but these are not close to the artery; and in the thorax it is crossed by the left brachio-cephalic vein. The artery lies on the trachea which it crosses to reach its left side, and beneath it, above this, but not usually in contact with it, is the thoracic duct; to the inner side of the carotid is the trachea, and to the

* The duct should be injected from the thorax or abdomen.

outer, the subclavian artery which is nearly parallel to it, but situated deeper in the neck. The jugular vein and the pneumogastric nerve lie to the outer side of the vessel, but nearer to it than on the right side, because the trunk of the left carotid is not directed so obliquely inwards, inasmuch as it arises from the arch much nearer in a line with the side of the neck which it supplies.

The description of the right side will serve for the remainder of the relations of the common carotid artery; and after the common carotid continue with the anatomy of the thyroid body, and the relative anatomy of the trachea and œsophagus in the neck, as described below.

Thyroid Body.

The *thyroid body*, whose use is unknown, is a reddish, glandular-looking organ, situated on the sides of the larynx and upper part of the trachea. It consists of two lateral portions or *lobes* united together by a transverse portion — the *isthmus* — which extends across the upper part of the trachea over its two or three first rings, and is very variable in size and shape. Each lobe is conical in form, the apex, above, reaches as high as the thyroid cartilage and lies between this and the common carotid artery; the base, below, is contiguous to the sixth ring of the trachea, and it separates also the artery from this tube; its surface is convex and projects forwards by the side of the larynx and trachea, as well as backwards towards the spine, so as to come into contact with the carotid artery, jugular vein, and accompanying nerves, which it conceals more or less, according to its size; and it is covered by the omo-hyoid, sterno-hyoid, and thyroid muscles, the latter being in close contact with it, and stretched laterally by the projecting gland beneath. On the side next the isthmus each lobe is hollowed out, and in contact with the thyroid and cricoid cartilages, the upper part of the trachea with the lower portion of the pharynx, and, on the left side, with the projecting œsophagus. From the upper part of the thyroid body a process — the *pyramid* — ascends to be connected to the os hyoides or to the thyro-hyoid membrane; this structure is sometimes only fibrous, at others, it resembles the structure of the thyroid body, and it is described, by Sœmmering, as a muscle — the *levator glandulæ thyreoideæ* — which is attached above to the os hyoides, and below to the gland. The thyroid body is of a brownish red or purple hue, its size is larger in women than in men, and when it is much increased in volume, it presses on the trachea, and the vessels on each side; it is composed of a spongy texture, the cells of which communicate together, and contain a viscid yellowish fluid: the intimate structure and the uses of this body are not ascertained, though it has some resemblance to other glands, in being formed of small lobules connected into larger lobes by an enveloping cellular tissue destitute of adipose matter, but no excretory tube has

Lobes.

Isthmus.

Relations.

Pyramid.

Structure.

Vessels. hitherto been found to convey away the fluid it contains. The arteries that this body receives are four in number, two on each side; they are named thyroid, the superior coming from the carotid, and the inferior thyroid from the subclavian: these divide into many branches for its supply, and anastomose very Veins. freely together. The *veins* are also very numerous, there being a superior, middle, and inferior thyroid for each side; the superior and middle veins have been seen to open into the internal jugular vein on each side; and the inferior thyroid veins leave the lower part of the thyroid body, descend on the trachea beneath the sterno-thyroid muscles, and by their union and anastomosis form a plexus in front of the trachea. From the lower part of the plexus issue the right and the left inferior thyroid vein, the former opens into the superior cava near its commencement, and the latter into the left brachio-cephalic vein.

Relations of the Trachea in the Neck. The *trachea*, or air tube for the lungs, continuous above with the larynx, ends below in the thorax by dividing into a branch for each lung. It is an almost cylindrical tube, situated in the middle line, and extended from the fifth cervical, to the third dorsal vertebra; it is always open or pervious, by reason of its cartilaginous rings, and it is very moveable. In front of the trachea are the sterno-thyroid muscles, which leave an interval in the middle line, and by means of this the deep cervical fascia comes into contact with its surface; the brachio-cephalic and left carotid arteries lie on the trachea near the top of the sternum, above this is the plexus of the inferior thyroid veins, and near the larynx, the isthmus of the thyroid body crosses it. This tube lies on the œsophagus, and partly on the recurrent nerves that lie between it and the œsophagus. On each side is the thyroid body and the common carotid arteries. The part of the trachea that touches the œsophagus wants the cartilaginous rings, and is flat and muscular.

Relations of the Œsophagus. The *œsophagus*, named from its use, is a muscular cylindrical tube between the pharynx and stomach; it commences above, as the trachea, opposite the fifth cervical vertebra, and it joins the stomach opposite the tenth. This tube extends through part of the neck and through the thorax, occupying for the most part the middle line of the body, but in some parts of its course it slightly projects to one side or the other; thus, in the lower part of the neck it inclines to the left of the trachea and vertebral column, and in the thorax it changes also its position, but this will be verified with the dissection of this cavity. In front of the œsophagus is the trachea, but in the lower part of the neck, on the left side, it projects beyond the trachea, and comes into contact with the thyroid body, the sterno-thyroid muscle, and the inferior thyroid artery. It lies on the longus colli muscle and the vertebral column. On each side are the common carotid

arteries, the proximity of the left being greatest, because of the position of the tube of the œsophagus on the left side; it is crossed also by the inferior thyroid arteries, and by the right recurrent nerve, but the left is placed in front of it. The thoracic duct is in contact with its left side in the lower part of the neck.

Use the description of the right side to dissect the cervical plexus, the trunk of the external carotid artery, and some of its branches; but when the dissector has proceeded as far as to the dissection of the pterygo-maxillary region (p. 184.) he must cease altogether to take it as a guide, since to follow the same order would destroy the anatomy of parts specially left to be examined.

Dissection.

Continue with the dissection of the recurrent nerve of the left side, and also with the middle and inferior cervical ganglia, and their branches. Much the same dissection is to be made as on the other side; remove the carotid arteries by cutting across the common carotid in the lower part of the neck, and the external and internal where they are crossed by the digastric muscle. In taking away the portion of the artery, be careful of the nerves of the sympathetic which lie behind it. Take away the upper part of the sternum, clavicle, and part of the first rib, by sawing through the latter about its middle, the same rib on the right side having been sawn through, and set aside these portions of bone for the examination of the sterno-clavicular articulation: divide the subclavian artery to see the inferior cervical ganglion on the neck of the first rib; the middle ganglion is found on or near the inferior thyroid artery, beneath the great vessels; and the recurrent lies between the trachea and œsophagus after it has turned round the arch of the aorta.

Recurrent Nerve.

The *inferior laryngeal* or *recurrent nerve* of the left side arises from the pneumo-gastric in the thorax, opposite the arch of the aorta which it turns round; it then ascends to the larynx between the trachea and œsophagus, parallel to the subclavian artery, and crosses beneath the common carotid, and the inferior thyroid arteries; opposite the cricoid cartilage, the nerve enters into the larynx by passing beneath the side of the thyroid cartilage, and the lower border of the inferior constrictor muscle. This nerve lies altogether in front of the œsophagus, and therefore anterior to the one of the right side. When it turns round the arch, and even whilst it lies on the trachea below, it gives numerous filaments to the cardiac plexus; it gives, in like manner with the right, branches to the trachea, œsophagus, and inferior constrictor muscle.

The middle and inferior cervical ganglia of the sympathetic are so similar to the same ganglia of the right side, that the same description is sufficient. (Refer to page 223.) The cardiac branches are slightly different.

Left Superior Cardiac Nerve. The *superior cardiac nerve* of this side descends beneath the great vessels, and as it enters the thorax lies between the carotid and subclavian arteries, and parallel to them, instead of crossing the subclavian at right angles. In the thorax it passes over the arch to join the superficial cardiac ganglion.

Left Middle Cardiac. The *middle cardiac nerve* is joined by many filaments that descend to it from the middle ganglion, it commonly joins the inferior cardiac nerve and passes beneath the subclavian, then along its outer side, and ends in the deep cardiac plexus.

Left Inferior Cardiac. The *inferior cardiac*, on this side, is small, it is frequently united with the middle, and enters the cardiac plexus; it joins with the recurrent nerve.

Cardiac of the Pneumo-gastric. The lower *cardiac branch* of the *pneumo-gastric* resembles the right in its origin above the end of the clavicle, but it enters the chest by the side of the carotid, and passes over the arch of the aorta to join the superficial cardiac ganglion.

DISSECTION OF THE PHARYNX.

Dissection. To separate the pharynx in order to dissect it, cut through the trachea and œsophagus, opposite the first rib, if this has not been done by the dissectors of the thorax. The pneumo-gastric and sympathetic nerves are to be divided about the middle of the neck, and, with the internal carotid and ninth nerve of the left side, they are to be carried forwards with the pharynx, so that they may remain connected to this part after it is removed: separate these parts from the spine as far as to the base of the skull. Instead of sawing vertically through the base of the skull, by which proceeding the pneumo-gastric and sympathetic nerves and the internal carotid are removed from the pharynx, and the ear, portio dura, and chorda tympani nerves destroyed, — the pharynx, and that part of the skull to which it is connected, are to be separated from the portion to which the spine is articulated, so as to leave entire the anatomy of both. To do this, saw vertically through the left side of the skull, in the depression for the lateral sinus, close behind the mastoid process of the temporal bone, as far as to the foramen lacerum jugulare; this will leave untouched the margin of the foramen magnum and the articulation of the atlas with the first vertebra: on the right side this will not be required, as the bone is taken away in the dissection of the eighth nerve. From the extremity of the incision on the left side, cut forwards with a chisel, through the occipital bone — in a line internal to the foramen jugulare and inferior petrosal sinus — to the centre of the basilar process of this bone; this leaves undisturbed the

eighth nerve in its foramen; on the other side, if it is necessary, the chisel may pass along the line of union of the occipital bone and the petrous portion of the temporal. Turn upwards, now, the base of the skull, and support the basilar process of the occipital bone on a block in contact with its inner surface; seek, on the under surface of the basilar process, for the line of separation between the attachment of the pharynx and the muscles of the spine, and cut through the bone at this part with a small Hey's saw or with a chisel: the pharynx, with its contiguous nerves and vessels, and the anterior part of the skull are now taken away in one piece; and the posterior part of the skull with the spine articulated to it in another. The anterior portion is to be first dissected, but the posterior must be preserved for an after examination.* Fill the pharynx with cotton wool or hair, both from the mouth and from the aperture in the œsophagus; fasten it with hooks to a block, with the pharynx pendent and towards the dissector. Remove a thin fascia from the muscles on the right side, and in the direction of their fibres which radiate from the front to the middle line. There are three constrictor muscles,—a superior, middle, and inferior; beneath the inferior near the larynx is the inferior laryngeal or recurrent nerve, between the middle and inferior, is the superior laryngeal nerve, and between the middle and superior is the glosso-pharyngeal nerve and stylo-pharyngeus muscle. On the left side the nerves mentioned above, as well as the pharyngeal plexus, opposite the middle constrictor, are to be particularly dissected; another view of the eighth nerve issuing from its foramen, and of the branches given off by it and the ninth and sympathetic nerves, will be obtained by detaching the digastric muscle, the styloid process and its muscles, and by removing some cellular membrane. The region beneath the base of the jaw may be again examined, without sawing the bone; or the glosso-pharyngeal nerve may be dissected, onwards, to its position beneath the hyo-glossus, by cutting through the mylo-hyoid muscle, and turning aside the submaxillary gland. As the different muscles and nerves are brought into view, the dissector should turn to the description already given of them, — since a view of them, under different circumstances, gives a clearer conception of their relations and anatomy.

The *pharynx* is the upper dilated portion of the tube of the œsophagus, and by means of it the mouth and nose communicate with the cavities of the stomach and lungs. Its extent is from the base of the skull to opposite the fifth cervical vertebra or cricoid cartilage of the larynx, and it ends at this point by becoming contracted and joining the œsophagus; it is fixed Pharynx.

* It is advantageous to wrap this, as well as the sterno-clavicular articulation and portion of the temporal bone, in calico moistened with a solution of bichloride of mercury.

in its position, by its attachment above, on each side, to the basilar process of the occipital bone to the petrous portion of the temporal, to the internal pterygoid plate of the sphenoid; below and in front of this, to the pterygo-maxillary ligament, to the posterior part of the mylo-hyoid ridge of the inferior maxillary bone, and to the side of the tongue; and in front it is fixed to the os hyoides and sides of the larynx. The shape of the pharynx is conical, the base above and the apex below. It is situated behind the nose, mouth, and larynx, which open into it; and it is placed in front of the vertebral column, longus colli, and rectus capitis anticus major muscles, some cellular membrane only intervening. On each side are the styloid process and muscles, with the parotid gland, the carotid arteries, — the internal nearer than the external, — the internal jugular vein, and the eighth, ninth, and sympathetic nerves with their branches; more anteriorly still the angle of the jaw and internal pterygoid muscle project over its upper part, but they are separated by an interval filled with cellular membrane: in the lower part of the pharynx the common carotid artery, jugular vein, and thyroid body are on each side. The bag of the pharynx is formed by the three thin constrictor muscles, and they are so arranged, that the upper fibres of the inferior muscle ascend, externally, higher than the lower border of the middle constrictor; and the upper fibres of the middle constrictor cover, in the same manner, the lower of the superior muscle. The upper and posterior part of the bag is completed by an aponeurotic expansion which is fixed to the occipital and temporal bones, and degenerates into cellular membrane as it descends.

Inferior Constrictor Muscle. Origin.

The *inferior constrictor muscle*, the lowest and most superficial of the three muscles of the pharynx, because of their imbricated arrangement, *arises*, by a fleshy process, from the side of the cricoid cartilage between the attachment of the crico-thyroid in front, and the crico-arytænoideus posticus behind; from the oblique ridge on the side of the thyroid cartilage, to which the sterno-thyroid and thyro-hyoid muscles are fixed, and also from the side of the cartilage behind this ridge. The origin is small, when compared with the insertion; for the fibres radiate to the middle line, the inferior being nearly straight, the superior ascending high above the lower fibres of the middle constrictor, and the central ones being intermediate between the two, and they are all *inserted* into the *raphé* of the middle line behind. The cutaneous surface of the muscle is covered by the sterno-thyroid muscle, by the thyroid body, common carotid artery, and jugular vein; and, posteriorly, it is in contact with the muscles of the spine. The inner surface is covered by the lining membrane of the pharynx. The lower border is straight, and marks the line of division between the œsophagus and pharynx, and near the attachment of the muscle to the larynx,

Insertion. Relations.

the inferior laryngeal nerve crosses beneath this border; the upper border, oblique, overlaps the middle constrictor, and is crossed by the superior laryngeal nerve and artery which enter the larynx.

Middle Constrictor Muscle. Origin. Inser-tion. Rela-tions.

The *middle constrictor muscle*, situated deeper than the inferior, is conical in shape, the apex in front and the base at the middle line behind. The fibres *arise* from the great cornu of the os hyoides, from the small cornu and stylo-hyoid ligament, joining with fibres of the genio-hyo-glossus muscle, but the lingual artery separates this attachment from the hyo-glossus muscle which should be divided to see it; from this origin the fibres diverge backwards, the superior passing obliquely upwards to end in the aponeurosis of attachment of the pharynx, the inferior downwards beneath the lower constrictor, and the middle almost transversely backwards to be *inserted* with the rest into the *raphé* in the middle line. In contact, externally, with the side of the muscle, are the carotid arteries, jugular vein and accompanying nerves, and the lingual artery and hypoglossal nerve lie on it for a short distance. The inner surface of the muscle is covered by mucous membrane. The upper border is separated from the superior constrictor by the stylo-pharyngeus muscle and glosso-pharyngeal nerve; and the superior laryngeal nerve is between the lower border and the inferior constrictor.

The anatomy of the stylo-pharyngeus muscle may be repeated on this side.

Superior Constrictor Muscle. Origin. Inser-tion. Rela-tions.

The *superior constrictor muscle* is the least marked of the three, and it differs from the rest in its shape, for, although the fibres are directed backwards, the muscle does not retain the conical form. The *origin* of the muscle is from the lower third of the inner surface of the internal pterygoid plate, from its hamular process, and from the lower part of the tuberosity of the palate bone; from the pterygo-maxillary ligament which gives attachment in front to the buccinator muscle, and behind to this muscle, and this will be exposed by dividing the internal pterygoid on the right side; from the posterior part of the mylo-hyoid ridge behind the attachment of the mylo-hyoid muscle, also from the side of the tongue, the fibres joining those of the hyo-glossus. From these numerous points of origin the fibres pass backwards; the superior ascend, forming an arch below the skull, to be *inserted* into the fibrous membrane that attaches the pharynx to the petrous portion of the temporal bone and base of the skull, and the others run beneath the middle constrictor to end in the *raphé* of the middle line, and some also end in the aponeurosis. The outer surface of the muscle is in close proximity, on each side, to the internal carotid artery and jugular vein, the eighth, ninth, and sympathetic nerves, with their branches, the styloid process and its muscles, the internal pterygoid muscle which is in contact with it at its

insertion, but, as the pterygoid is directed downwards and outwards to the angle of the jaw, an interval is afterwards left between them; still farther back, this surface is partly covered by the middle constrictor, and it is in contact with the muscles of the spine. Above the arched border of the fibres passing backwards from the pterygoid plate to the aponeurosis of attachment, are seen the small levator and tensor palati muscles, which arise external to the cavity of the pharynx, and enter it at this spot. Beneath the basilar process, near the middle line behind, the aponeurosis is uncovered by muscular fibres in a small space, — the sinus of Morgagni. The inner surface of the muscle is lined by the mucous membrane, and by the prolongation of the aponeurosis. The lower border is overlaid by the middle constrictor, but separated from it, in front, by the stylo-pharyngeus muscle and glosso-pharyngeal nerve.

Aponeurosis of Attachment.

The *aponeurosis of attachment*, which connects the pharynx, posteriorly, to the base of the skull, and completes its cavity behind, is connected in the centre to the basilar process of the occipital bone, and laterally to the petrous portion of the temporal, and to the Eustachian tube; the strongest fibres are fixed to the point of the petrous portion of the temporal bone, and to the basilar process of the occipital, and the muscular fibres of the constrictor end on this membrane. The aponeurosis joins, above, with the periosteum, and, below, it is thin and cellular, and extends between the mucous and the muscular portion of the pharynx.

Pharyngeal Plexus.

The *pharyngeal plexus of nerves*, dissected on the left side of the pharynx, consists of an interlacement of branches from the pharyngeal branch of the pneumo-gastric, from the external laryngeal branch of the same nerve, from the glosso-pharyngeal nerve, and from the superior cervical ganglion of the sympathetic. It is situated on the lateral part of the posterior surface of the pharynx, and opposite the middle constrictor; numerous filaments are given off from it, in different directions, to supply the muscles and mucous membrane of the larynx; small branches of the pharyngeal artery accompany these nerves to the pharynx.

Dissection.

Open the pharynx by a vertical incision, behind, along the centre, remove from it the cotton wool or the hair, and fasten back the sides of the tube; a better view of the upper part is obtained by dividing the occipital attachment. The following are the objects to be noticed in the interior of the pharynx; beginning above, the openings of the nares, separated by the septum nasi; on each side of this, and rather behind it, is the trumpet-shaped aperture of the Eustachian tube*; and below it, is the moveable curtain of the soft palate, which partly closes

* The dissector may practise passing a bent probe along the floor of the nose into the aperture of this tube.

the large aperture of the mouth. The opening between the mouth and pharynx is named the isthmus of the fauces, and on each side is a collection of mucous follicles — the tonsil — situated between two prominent folds of mucous membrane, or the pillars of the soft palate, which descend from this structure to the side of the tongue and the pharynx. The aperture into the larynx is the next in order below the mouth; and close in front of it is the epiglottis, to which are attached, in front, three folds of the mucous membrane, which connect it to the tongue. The aperture into the œsophagus, below, is the last opening into the pharynx.

Openings of the Nostrils.

The *posterior openings of the nostrils* into the pharynx are two in number, and they are separated from each other by the septum of the nose, which extends backwards to the posterior part of the bony portion of the roof of the mouth. Each aperture is oval in shape, its longest measurement being from above downwards, and it is formed by the osseous parts that bound it in the dried skull, covered by mucous membrane; thus above is the body of the sphenoid bone, below the palate plate of the palate bone, internally the vomer, and externally the internal pterygoid plate.

Soft Palate.

The *velum pendulum palati*, or soft palate, is a square-shaped moveable part, attached to the posterior margin of the hard palate, and it increases the surface of the roof of the mouth. It is suspended almost vertically above and behind the isthmus of the fauces, the aperture of which it can entirely close when it is drawn down, and during deglutition it is placed horizontally, and separates the upper from the lower portion of the pharynx. By the position of the soft palate, the anterior surface is directed downwards and forwards, and is continuous with the roof of the mouth; the posterior looks, in the opposite direction, to the pharynx; both surfaces are marked by a line which indicates the original separation into two lateral halves. The upper border is fixed to the posterior margin of the palate plate of the palate bone; the lower is free, and presents in the middle line an elongated pendulous portion, — the *uvula*, and on each side of this, an arched part, — the *half arch* of the palate. The velum consists of an aponeurotic portion which is moved in different directions by muscles, together with some mucous glands, vessels, nerves, and cellular membrane, which are enveloped by the mucous membrane.

Uvula.

Half Arches.

Dissection.

Raise the mucous membrane from the pharyngeal surface of the soft palate to expose the muscles; the removal of it from the uvula must be done carefully, so as not to take away the pale fibres of the azygos uvulæ muscle, situated in the centre, in the form of two small bands. On each side are two other muscles, — the levator, and tensor palati; the former only is now visible; but to see the tensor, as well as the origin of the levator,

take away, on the right side, the portion of the superior constrictor, which is attached to the internal pterygoid plate, as well as the upper attachment of the pharynx on this side, then, by removing some cellular membrane, it will be found between the internal pterygoid plate and muscle; trace the tendon of the muscle round the hamular process, and follow it into the soft palate to join the aponeurosis: the tendon would be better seen by raising the mucous membrane from the front of the soft palate. The Eustachian tube is closely united to these muscles, and should have the mucous membrane removed from it; this is to be done on the right side, if it should not be too much injured, because some nerves may be destroyed on the left.

Aponeurosis of the Palate. The *aponeurosis* of the soft palate is a white, shining, fibrous structure, fixed above to the hard palate, and joined by the fibres of the tendon of the tensor palati; it becomes thinner as it descends in the palate.

Levator Palati Muscle. Origin. The *levator palati*, or internal peristaphyline muscle, situated half within and half without the pharynx, is a thick roundish muscle, which *arises* from the under surface of the petrous portion of the temporal bone, between its apex and the carotid canal, and also from the pharyngeal or under surface of the Eustachian tube. The fibres descend vertically, enter the pharynx above the curved fibres of the superior constrictor, and continue onwards, between this muscle and the mucous membrane, as low as to the posterior margin of the hard palate; at this spot they spread outwards, occupying the greater part of the half of the soft palate, and some are *inserted* into the aponeurosis, whilst others join those of the opposite side along the centre, and beneath the motor or azygos uvulæ muscle.

Insertion.

Relations. The origin of the muscle is external to the pharynx, and it enters above the arched fibres of the superior constrictor; it is situated behind the Eustachian tube, or lies on it in the present position of the subject. The outer surface is in contact with the fifth nerve, and superior constrictor muscle; the inner or pharyngeal is contiguous to the mucous membrane, but, at its termination, the motor uvulæ muscle lies on it.

Tensor Palati Muscle. Origin. The *tensor* or *circumflexus palati*, or external peristaphyline muscle, like the preceding, consists of a vertical and a horizontal portion; the muscle is much thinner than the levator, and is tendinous by its deep margin. It *arises* from the scaphoid fossa at the root of the internal pterygoid plate, from the surface of the sphenoid bone adjoining, and from the anterior and under part of the Eustachian tube which crosses between it and the levator. The fibres form a thin riband-like band, which is situated in the pterygoid fossa, between the internal pterygoid plate and muscle, and descends as far as to the hamular process of bone, that terminates below the internal pterygoid plate; the muscle now becomes tendinous, turns inwards round

the hamular process, to which it is bound down by a fibrous membrane provided with a synovial sac, and it finally ends in a wide aponeurotic expansion which is situated deeper, in this position, than any of the other muscles, is attached, above, to a ridge on the under surface of the palate process of the palate bone, and joins also the aponeurosis of the palate. By the outer surface, it is in contact with the fifth nerve, with the internal pterygoid muscle, and with a small branch of the inferior palatine artery between the two muscles; the inner or pharyngeal surface is close to the Eustachian tube, and internal pterygoid plate. As the tendon passes round the hamular process it is thrown into folds.

Insertion. Relations.

The *levator* or *azygos uvulæ muscle* is situated in the middle line of the soft palate, and extends vertically to the tip of the uvula. It consists of two narrow slips of muscular fibres, separated above by a slight interval, and fixed to the spine in the centre of the posterior border of the hard palate; the fibres descend to end in the tip of the uvula. This muscle is the most superficial on the posterior surface of the soft palate, and, with some mucous glands, forms the uvula.

Levator Uvulæ Muscle. Origin. Insertion. Relations.

The *Eustachian tube*, more distinctly seen by removing the levator palati, is a canal, partly osseous, and partly cartilaginous and membranous, by which the air in the cavity of the tympanum communicates with the atmosphere. The *osseous part* of the canal, to be seen with the ear or in a dry bone, is about three fourths of an inch in length, and small in diameter; but the *cartilaginous* and *membranous part* external to the skull is rather longer than an inch, is attached above, at the base of the skull, to the irregular margin of a bony groove formed by the petrous portion of the temporal bone, and the spinous process and great wing of the sphenoid, and is directed downwards and inwards to open into the pharynx by a wide trumpet-shaped aperture, opposite the inner surface of the internal pterygoid plate, and rather above and behind the inferior spongy bone of the nasal fossa of the same side. In this extent this part is firmly connected to the cartilage placed in the foramen lacerum basis cranii, also to the internal pterygoid plate, which it crosses; it is covered by mucous membrane, and lies between the two long muscles of the palate, — the levator being placed on its pharyngeal surface, and the tensor on the external or cutaneous side. The tube is formed by two cartilaginous plates united above, but separated below, and the interval between them is filled by a fibrous membrane continued back to the attachment of the cartilage to the temporal bone, the internal plate, much the largest and thickest, projects farthest forwards, and, being dilated, hangs over the other, and forms the trumpet-shaped mouth. Its cavity is angular, since it is formed by the juxta-position of two flat pieces of cartilage; by this tube

Eustachian Tube. Osseous part. Cartilaginous.

the mucous membrane of the pharynx is continued into the cavity of the tympanum.

Dissection. Descending from the soft palate are two prominent folds of the mucous membrane, or the pillars of the soft palate, which bound, before and behind, the tonsil; the anterior passes to the side of the tongue and the posterior to the pharynx. Raise the mucous membrane from these, and their prominence will be seen to be occasioned by muscular fibres contained in them, — the palato-glossus muscle occupying the anterior, and the palato-pharyngeus the posterior fold.

Palato-glossus Muscle. Origin. Insertion. Relations. The *palato-glossus muscle* or constrictor isthmi faucium is a small fleshy band of fibres, extended from the soft palate to the side of the tongue. Its *origin* above is united, in the soft palate, with the palato-pharyngeus, and, at its *insertion* into the side of the tongue, the fibres are mixed with those of the stylo-glossus; each extremity of the muscle is wider than the centre. The muscle assists to form on each side the isthmus of the fauces, it is situated in front of the tonsil, and is covered only by mucous membrane.

Palato-pharyngeus Muscle. Origin. Insertion. Relations. The *palato-pharyngeus muscle*, forming the prominence of the posterior pillar of the velum, is expanded above in a muscular layer in the soft palate beneath the levator palati; its fibres are mingled below with the muscles of the posterior part of the pharynx, and they are said to reach the posterior border of the thyroid cartilage. It bounds, behind, the tonsil; it is covered by mucous membrane, and gives rise to the prominence of the posterior pillar of the soft palate.

Tonsil. The *tonsil* is a collection of mucous follicles, situated between the pillars of the soft palate, above the side of the tongue, and below the velum. The aggregate of the follicles forms a body of an oval shape, but very variable in size; and the apertures of the follicles are generally apparent on its surface. By its outer surface the tonsil is contiguous to the superior constrictor, and external to this, the internal pterygoid muscle and angle of the jaw are opposite to it; posterior to it is the internal carotid artery, as this lies against the superior constrictor, and, when the tonsil is enlarged, it passes backwards far enough to touch this vessel.

Isthmus Faucium. The *isthmus faucium* is the opening of communication between the mouth and pharynx, it is narrower than either of the cavities between which it is placed, and its size depends upon the position of the soft palate, since it can be entirely closed by the descent of this structure or curtain. The aperture is bounded, below, by the tongue; above, by the lower border of the soft palate, which presents the uvula in the centre, and a half arch on each side; and, laterally, by the anterior pillar of the velum, containing the constrictor isthmi faucium muscle.

Aperture The *aperture of the larynx* is below the isthmus of the fauces,

and by it the air inspired, either by the mouth or nose, passes to the lungs; it is wide in front at the epiglottis, and pointed behind in the interval between the arytænoid cartilages of the larynx. The sides are sloped off obliquely downwards and backwards, and are formed by the arytæno-epiglottidean folds of mucous membrane, which connect, as their name implies, the arytænoid cartilages to the epiglottis. This is closed by the epiglottis. of the Larynx.

The *epiglottis*, placed in front of the aperture of the larynx and above it, is a leaf-shaped portion of fibro-cartilage, pointed below at its attachment to the thyroid cartilage of the larynx, and rounded and expanded above. It is retained at a distance from the aperture it is intended to close, by means of folds of mucous membrane which attach it to the tongue, in order that the aperture of the larynx may remain open for the passage of the air; for it is only during deglutition, when the larynx is carried upwards and forwards, that the epiglottis closes the aperture. The folds of mucous membrane between it and the tongue are, a central and two lateral; and between it and the arytænoid cartilages, behind, are the arytænoid folds before seen. Epiglottis.

The *opening into the œsophagus*, or the point at which the pharynx ends and the œsophagus begins, is opposite the cricoid cartilage or fifth cervical vertebra. On the outer surface, the line of separation is marked by a contraction and change in the direction of the muscular fibres; and the mucous membrane of the inside is paler in the œsophagus than in the larynx. Opening of the Œsophagus.

The *mucous membrane of the pharynx* is continuous with that lining the cavities of the mouth and nose, it descends over the palate inclosing numerous small follicles, especially in the uvula, and on each side it dips into the apertures of the tonsil; from the dorsum of the tongue it is continued to the epiglottis and forms its anterior folds, and in the upper part of the pharynx it is prolonged by the Eustachian tube into the cavity of the tympanum. The membrane lines the pharynx, forms the arytæno-epiglottidean folds on the sides of the aperture of the larynx, and sends a prolongation into the larynx, by means of its opening, to line this tube and extend into its divisions in the lungs; it is then continued, by the œsophagus, into the stomach and intestinal canal, so that this portion of the mucous membrane is named the gastro-pulmonary, because of its lining the lungs and digestive organs. The mucous membrane is thicker above than below, and its character, near the different apertures, approaches much to that lining the cavities; numerous small follicles are situated in it in the upper part of the pharynx. An epithelium is still found to cover the membrane, and is continued with the prolongations sent from it to the lungs and stomach. Mucous Membrane.

Œsophagus. The relative anatomy of the *œsophagus* in the neck is examined, and as the greater part of this tube is found in the thorax, the particular dissection of its structure will be undertaken in that cavity. It may be remarked, however, that it commences opposite the cricoid cartilage by a constricted ring, that the calibre of the tube is less than that of the pharynx, and that the walls are flaccid, and approach each other. It consists of two layers of muscular fibres, an external, of longitudinal, fixed by some fibres to the back of the cricoid cartilage, and an internal of circular fibres: these are lined by the mucous membrane.

CAVITY OF THE MOUTH.

Cavity of the Mouth. The *cavity of the mouth* may be examined on the left side, since the jaw is not sawn; its size and shape depend upon the position of the lower jaw, and its boundaries are partly osseous and partly muscular. When the mouth is moderately opened the cavity is of an oval shape, is situated below the nose, communicates behind, through the isthmus, with the fauces, and in front it is closed by the lips. The upper boundary or *roof* is concave, and is formed by the upper lip, the alveolar arch with its teeth, the palate processes of the superior maxillary and palate bones, covered by mucous membrane, and behind this, by the soft palate; from the different directions of the soft and hard palate the aspect of the front of the roof is directly downwards, but that of the back forwards and downwards. The *floor* is formed by the lower lip and corresponding row of teeth; behind this, by an interval, in which is the sublingual gland, and by the dorsum of the tongue; between the lower arch of teeth and the tongue is the frænum linguæ, attached to the posterior part of the alveolar arch, and to the under surface of the tip of the tongue, and it separates the sublingual glands of opposite sides, on the side of this fold is the papilla, in which the submaxillary or Whartonian duct opens, and into which a bristle has been passed from the duct; and extending laterally from the frænum is a raised fold of mucous membrane over the sublingual gland, and in it the ducts of this gland are placed. Each *lateral boundary* is the commissure of the lips, with the cheeks and the ramus of the lower jaw; on this part near the second molar tooth is the opening of the parotid duct, marked also by a bristle introduced into it, and the openings of one or more small ducts from the molar glands are opposite the last molar tooth.

Roof. Floor. Lateral Boundary.

Mucous Membrane. The *mucous membrane* of the mouth presents a very different appearance to that of the pharynx, and on the bony parts of the

cavity it resembles fibro-mucous membrane in its character: the epithelium or epidermis is very distinct on its surface. At the margins of the lips it joins the skin on the exterior of the body, the transition between the two being gradual, and after lining the cavity of the mouth, it extends into the pharynx by the isthmus. If it is traced on the roof it is found to present a fold — the frænum — between the lip and alveolar arch; to surround the teeth and form projections between them, and it here changes much its character, becomes thick and hard, and sends a prolongation into each socket of the teeth to join the lining membrane; it then extends over the hard palate, on which it is thick, and thrown into transverse folds in front, and it is separated from the bone by palatine glands, which are most numerous posteriorly: it closes the apertures of the palatine foramina in the roof. In the floor are the frænum of the lip and tongue, and, on each side of this last, is the raised fold which marks the position of the sublingual gland; it is prolonged also into the Whartonian duct which it lines, and at the posterior part of the tongue it gives rise to the folds of the epiglottis. Between it and the lips are numerous small *labial glands*, easily seen, by raising the mucous membrane, to be conglomerate salivary glands, whose ducts perforate the membrane behind the lips; there is a greater number in the lower than in the upper lip. On the cheeks the membrane is separated from the buccinator muscle by the *buccal glands*, and is continued into the parotid duct.

Labial Glands.

Buccal.

Each *cheek* consists of the muscular layer of the buccinator with integument, cellular membrane, vessels and nerves, on the outer side, and with the mucous membrane and buccal glands on the inner; each is limited in front by the commissure of the lips, behind by the ramus of the lower jaw and isthmus, and it is fixed above and below to the outer surfaces of the alveolar borders of the jaws; on the inner surface is the opening of the parotid duct, and the small apertures of the malar and buccal glands. The *arteries* to this part come from the facial, transverse facial, buccal, and posterior dental arteries; the *nerves* from the fifth and seventh.

The Cheeks.

Vessels.

Nerves.

The *lips* are two moveable muscular parts that close, in front, the opening of the cavity of the mouth, in the same way as the eyelids did their intervening aperture; the lower is the largest and most moveable. They consist of the muscular layer of the orbicularis, covered externally with skin, and internally with mucous membrane; and their labial glands lie between the muscular and the mucous layers. The arch of the coronary arteries is situated in each nearer the inner than the outer surface; and the other small *arteries* that supply the lips are derived from the inferior labial, mental, and infra-orbital arteries, and

The Lips.

Vessels.

Nerves. some small branches come also from the facial: the *nerves* are from the fifth and seventh.

The Teeth. The *teeth*, the agents in the mastication of the food, are placed in the alveolar margins of the jaws in the form of two arches — the dental arches — convex forwards, and concave to the cavity of the mouth. The posterior part of the upper arch meets the lower in the back of the cavity, in order that the food may be ground, but in front they are used only as cutters, and pass each other as the blades of a scissors. The arch of the upper jaw usually projects in front, over that of the lower, so that the upper teeth pass before the lower when the mouth is closed; but the under arch oftentimes passes in front of the upper, in the like circumstances. The teeth are named, from their form or use, incisor, canine, and molar or grinding teeth. In the adult there are sixteen in each jaw, and they are symmetrical on both sides; thus, in each half of the jaw, there are two incisors in front, one canine behind this, and farther back five grinding teeth which differ in shape and size, — the two anterior being named bicuspid, and the three last, molar teeth: the molar are again spoken of as first, second, and third, and the last has received the appellation of dens sapientiæ, from the late period at which it appears.

The tongue will be examined with the larynx.

DISSECTION OF THE NOSE.

Dissection. The portion of the base of the skull may be sawn through, vertically, on the right side of the crista galli, and close to this process, the loose portion of the lower jaw and the remains of the cheek having been previously removed from the upper jaw of this side. Instead of completing the section from above, it will be preferable to saw only a certain distance in this direction, so as to cut through, in front, the cribriform plate of the ethmoid, the frontal and nasal bones, and, behind, part of the body of the sphenoid; and then to turn bottom upwards the skull, and, after dividing the soft parts of the mouth, to saw the roof of the palate on the right side of the septum nasi, and the sphenoid bone in such a manner that the cut shall join the incision made above; by this proceeding, the spongy bones, and the nasal septum which generally inclines to one side or the other, are left uninjured. After the separation into two parts, the right will be used to see the meatuses, and the left for the septum; the roof has been sawn through, but a view of it may be obtained on the left side after the removal of the septum, or the dissector may trace it in the dried skull. It is more

convenient for the after-dissection to separate the tongue, os hyoides, and larynx, from the portion of the lower jaw on the left side, and to place them with the other reserved parts, till the dissector is ready to commence them.

Cavity of the Nose.

The *cavity of the nose* is situated below the bodies of the ethmoid and sphenoid bones, above the mouth, and between the maxillary sinuses and the orbits; its anterior boundary is cartilaginous, but in the dried skull there is a large space left by its removal. The nose is divided into two parts or nasal fossæ, by a vertical septum; each fossa opens, behind, into the pharynx, and in front, in the face, by the nostril. The *nasal fossa* of each side presents a roof, a floor, and an inner and an outer wall: — the *roof* is arched, and is formed, in front, by the lateral nasal cartilage and by the nasal bone of the same side, this portion looks downwards and backwards, is somewhat concave, and is grooved by the nasal nerve; in the centre, by the cribriform plate of the ethmoid bone, which looks directly downwards, is perforated by numerous apertures for the branches of the olfactory nerve, and one of these, larger than the rest and close to the crista galli, is for the nasal nerve of the ophthalmic division of the fifth; and behind, by the body of the sphenoid, by the sphenoidal spongy bone, by the lateral part of the vomer and the sphenoidal process of the palate bone applied on the body of the sphenoid: the portion formed by the sphenoidal spongy bone looks downwards and forwards, but the remainder of the roof directly downwards, and it is grooved by the pterygo-palatine canal. The *floor*, slightly hollowed from side to side, consists of the palate processes of the superior maxillary and palate bones — a suture marking the union between the two; and near the front is the aperture of the anterior palatine canal, with a very small foramen posterior to it for the naso-palatine nerve. The *inner wall* or septum of the nose is partly osseous and partly cartilaginous, and the lining membrane of the cavity is to be removed to see it. The osseous part consists of the perpendicular portion of the ethmoid bone, of the vomer, and of the ridge formed by the union of the palate and superior maxillary bones of opposite sides along the floor; and along the roof, in front of the vertical portion of the ethmoid bone, is the projection of the crests or spines of the nasal and frontal bones: this portion of the septum is usually bent to the right side. The irregular space left, in the prepared skull, between the descending bony layer of the ethmoid and the vomer, is occupied by the *triangular cartilage of the septum*, which assists to form the partition between the nostrils, and supports the other cartilages of the apertures of the nose. Its upper border is uneven, and is joined to the irregular lower margin of the vertical plate of the ethmoid, and, in front of this, to the crest formed by the nasal spines; the lower is united to the

Nasal Fossa.

Roof.

Floor.

Inner Wall.

Triangular Cartilage.

vomer, and the ridge in the floor, in front of this, formed by the crests of the superior maxillary bones; and it extends, beyond the floor, by a rounded portion, which is situated between the inner extremities of the cartilages of the apertures of the nose; its anterior border or the base, is in contact with the cartilages of the side of the nose and of the aperture, and projects to the surface between them. It is often inclined to one side like the bone, and is covered on both surfaces by mucous membrane. In the *outer wall* is the greatest extent of surface, and this is the part of the nose on which the nerves for the sense of smell are chiefly spread. This surface is not flat, as the other boundaries, but is irregular, from the presence of three convoluted portions of bone named *spongy* or *turbinate* bones, which project into the cavity, the two upper being only processes of the ethmoid, but the lower one is a separate bone; and the spaces between the outer wall and the turbinate bones are named meatuses. The bones that enter into the outer wall are, beginning in front, the superior maxillary, the small os unguis, the ethmoid with its two turbinated bones, and, below, the inferior turbinate bone; and behind this are, the palate plate of the palate bone, and the internal pterygoid plate of the sphenoid. The *meatuses*, or spaces between the turbinate bones and the outer wall, appear like three longitudinal canals. The *upper meatus*, the smallest of the three, and beneath the superior turbinate bone, occupies but about the posterior half of the outer wall; it communicates with the posterior cells of the ethmoid by an aperture in its front, and behind is the spheno-palatine foramen which allows the nerves and arteries to enter the nose from the spheno-maxillary fossa: there is also an aperture into the back of the nose from the sphenoidal cells. The *middle meatus*, longer in extent than the upper, and situated below and beneath the middle spongy bone, has in its anterior part a funnel-shaped opening — the infundibulum — which leads into the frontal sinus and the anterior ethmoidal cells, the opening from the antrum maxillare is about the middle of the meatus, but in the recent subject its aperture is much smaller than in the dried bone, since the lining membrane of the nose diminishes the capacity. The *inferior meatus*, still more extensive than the middle one, reaches nearly across the whole outer wall of the nasal fossa, it is beneath the inferior spongy bone, and in its front is the aperture of the nasal duct.*

Outer Wall.

Meatuses.

Upper.

Middle.

Lower.

Fibro-mucous Membrane.

The *fibro-mucous membrane* that lines the nasal fossæ, called pituitary or Schneiderian, joins, in front, the integument at the aperture of the nose, and, behind, the mucous membrane of the pharynx; it is continuous also with the conjunctiva, and with the lining membrane of the frontal, ethmoidal, and sphen-

* A probe can be passed more readily into this, now the nose is opened.

oidal sinuses, and of the antrum of the upper maxillary bone, by the foramina opening into the meatuses. Near the anterior apertures of the nose the membrane resembles the skin, and is provided with numerous small hairs called *vibrissæ*. The membrane is closely united to the bony surfaces, and in lining the floor and inferior meatus it closes the foramen of the anterior palatine canal, and sends a prolongation into the nasal duct, which narrows its aperture, and joins above the conjunctiva through the lachrymal canals: on the margin of the lower spongy bony, as well as on the margin of each of those above, it forms a fold which increases their extent of surface. In the middle meatus a process passes by the opening of the infundibulum into the frontal and ethmoidal cells, and another into the antrum by the aperture from it: the size of the opening into the antrum, as it appears in the dry bone, is much diminished by this prolongation into it. It lines likewise the superior meatus, is continued from it into the posterior ethmoidal cells, and as it passes across the spheno-maxillary foramen which it closes, is joined by a layer of the periosteum, and receives some vessels and nerves. On the roof it closes the different apertures in the cribriform plate, and is joined by the dura mater which surrounds the nerves to the membrane of this part; behind this it enters the sphenoidal sinus. On the septum it is very thick, and its colour is a reddish tint. The membrane is thick and dense in structure, and consists, internally, of a mucous layer provided with follicles for the secretion of the mucus, and externally, of a fibrous layer which is united with the periosteum of the bones; and if it be separated from these, its white shining character will be apparent. The part that lines the different cells and canals is pale, thin, and destitute of mucous follicles. Numerous vessels and nerves are distributed to it; the *arteries* are branches of the internal maxillary, ophthalmic, and facial; and the *nerves* from the olfactory — the nerve of special sense; from the ophthalmic and superior maxillary divisions of the fifth, and from Meckel's ganglion.

Vessels.

Nerves.

The branches of the olfactory nerve will be exposed for a short distance after they pass through their apertures, by removing the septum nasi from the layer of pituitary membrane that lines its left surface, so as to leave entire this covering; the filaments of the nerve will appear on the surface of the membrane near the cribriform plate; and a long descending nerve — the naso-palatine from Meckel's ganglion, crosses lower than this to the anterior palatine canal; it is accompanied by a vessel from the internal maxillary artery, and, unless the subject be in good preservation, it may not be found. Other branches of the olfactory may be exposed by separating the membrane from the front of the outer wall. The remaining

Dissection.

branches of vessels and nerves will be dissected in an after stage. (See page 254.)

Olfactory Nerve.

The *olfactory nerve*, the nerve of the sense of smell, whilst in the skull, gives off from its bulb, on the cribriform plate, many filaments that descend through the apertures in the bone to the nose; each is accompanied by a process of dura mater that joins the Schneiderian membrane; by one of pia mater that joins the filaments; and by one of arachnoid that is reflected back into the skull. The filaments of distribution of the nerve are divisible into three sets; an internal which descend in grooves on the septum nasi, spread out, and branch in the pituitary membrane; a middle, smaller and shorter, distributed to the membrane of the roof; and an external, on the superior spongy bone and the square plate of the ethmoid in front of it. The filaments on the outer wall are to be traced to the middle spongy bone, and those on the inner to about its middle; the branches of division of the nerve are united at an angle approaching the ramifications of arteries, and they terminate between the fibrous and mucous layers of the pituitary membrane by separating into bundles of very fine filaments.

DEEP NERVES AND VESSELS OF THE HEAD.

Dissection.

Meckel's ganglion is situated in the pterygo-maxillary fissure, and it may be reached from the outside, by removing with a chisel the osseous boundaries; but this proceeding is not so satisfactory as exposing it from the inside, since the nerves to the nose and palate cannot be traced to their destination. If a vertical section of the base of a skull be examined, it will be seen that the fissure that contains the ganglion is separated from the cavity of the nose by a very thin plate of bone, and that it will be required only to break through this to expose the ganglion and its large descending palatine nerves. To dissect the ganglion from the inside, take the left or untouched portion of the divided skull, isolate the naso-palatine nerve and artery, that run in the covering of the septum, from the surrounding membrane; remove this loose portion of membrane, follow back the nerve and artery to the spheno-palatine foramen, and dissect out some other branches of nerves and arteries that enter by this foramen, and spread out on the membrane covering the spongy bones in the back of the fossa. The projecting portion of the body of the sphenoid, which overhangs the aperture and impedes the dissection, is to be sawn off in a line rather internal to the small pterygo-palatine foramen; remove

the mucous membrane from the wall of the nasal fossa, close behind the extremities of the spongy bones, and below the aperture through which the vessels and nerves enter; some small nerves and vessels perforate the bone to supply the lining of the nose, and they are broken through in doing this. With a chisel cut through the thin vertical plate of the palate bone into the pterygo-maxillary fissure, and the descending palatine nerves and arteries come into view; follow these down to the soft palate and roof of the mouth by laying open the posterior palatine canal, and then along the roof of the mouth, in the cellular structure and glands, beneath the mucous membrane and close to the bone. The ganglion itself is placed opposite the spheno-palatine foramen, by which the nerves enter the nose, and the bone around it is to be freely removed with a bone forceps; the cellular membrane is to be carefully taken away, and as many branches as possible, both of the nerves and arteries, are to be preserved. The vidian nerve —the posterior branch of the ganglion, might be dissected now, but it is more convenient to trace first the other nerves already dissected.

Spheno-palatine Ganglion.

The *spheno-palatine ganglion* or ganglion of Meckel lies in the pterygo-maxillary fissure, behind the tuberosity of the superior maxillary bone, in front of the pterygoid process of the sphenoid, below the body of the same, and on the outer side of the vertical plate of the palate bone. There is seldom the appearance of a ganglion, but rather an enlargement from which the nerves spring; some of these pass inwards through the spheno-palatine foramen to the nose; some upwards to join the superior maxillary division of the fifth nerve; the greater number, and the largest, downwards to the palate; and a small nerve — the vidian — backwards, through the pterygoid foramen: all of these, except the posterior, are dissected.

Internal branches.

The *internal* or *spheno-palatine branches*, varying in number from three to five, pass directly inwards to the nasal fossa, through the spheno-palatine foramen; they are for the most part extremely small, and appear on the outer surface of the pituitary membrane, when it is detached from the wall of the fossa. The greater number of these are distributed on the posterior part of the two upper spongy bones, and in the membrane lining the meatuses; one long nerve — the *naso-palatine* — crosses the roof of the nasal fossa to reach the septum nasi, along which it descends to near its front, with an artery of the same name from the internal maxillary; the nerve then enters a small foramen peculiar to it, behind the anterior palatine canal for the artery, by this it is conducted to the roof of the mouth, and is distributed to the mucous membrane behind the incisor teeth. To follow the nerve to its termination, the canal in the roof of the mouth should be laid open.

Naso-palatine.

Ascending. The *ascending filaments* from the ganglion to the superior maxillary nerve are usually two in number, and they were seen, in the spheno-maxillary fossa, to join the under part of this nerve.

Descending. The *descending* or *palatine nerves* pass, vertically, from the ganglion to the palate, in the posterior palatine canals, and they are usually three in number,—an anterior, middle, and posterior; the anterior and middle are most frequently found in the large posterior palatine canal; and the posterior, in a small one behind this.

Anterior Palatine. The *anterior*, the largest, descends in the posterior palatine canal, with the palatine artery, to the roof of the mouth; at its lower aperture the nerve changes its direction, runs almost horizontally forwards, in a groove on the inner surface of the alveolar process, and divides into internal and external branches which continue the nerve onwards in the roof, and are distributed to the glands, mucous membrane, and gums. Whilst in the canal the nerve gives off a nasal filament through an aperture in the vertical plate of the palate bone, to supply the mucous membrane of the middle meatus: this was seen in removing the mucous membrane; another filament supplies the soft palate.

Middle. The *middle palatine nerve*, the next largest in size, sometimes descends in a canal distinct from that for the anterior nerve; and in the roof of the mouth it divides to supply the tonsil, soft palate, and mucous membrane.

Posterior. The *posterior* or *small palatine nerve* runs in a canal by itself, behind the others, and when it escapes, below, is distributed to the soft palate and uvula.

Dissection. The vidian nerve runs backwards through the vidian or pterygoid canal to join the carotid plexus; it enters the skull and the hiatus Fallopii to unite with the portio dura in the aqueduct of Fallopius. Another small branch from the ganglion is said to be sent backwards through the pterygo-palatine canal to the pharynx; this should first be looked for with the small artery that occupies the canal. To follow the vidian, lay open with a bone forceps or chisel the canal in which it lies; at the posterior extremity of the canal the nerve turns outwards to the petrous portion of the temporal bone, beneath the carotid artery, but to the outside of it, and it will therefore be necessary to remove, with the bone forceps, the posterior projecting angle of the body of the sphenoid, which partly conceals the carotid, as well as the point of the petrous portion of the temporal bone, on which is placed the Gasserian ganglion of the fifth nerve. Cut across with care the carotid artery, and remove it; take away, also, the small spicula of bone, which projects backwards from the body of the sphenoid to the tip of the petrous portion of the temporal, bounds the artery on the outer side, and conceals the vidian entering the skull below, and rather external to it. At this spot the nerve divides into two branches; one is

directed backwards and inwards to the carotid plexus on the artery; and the other passes backwards and outwards, close against the spicula of bone that separates the foramen ovale of the sphenoid from the superior opening of the carotid canal, enters the skull through the cartilaginous substance in the foramen lacerum, and it is seen lying on the upper surface of the petrous portion of the temporal bone: these branches are difficult to follow through the cartilaginous substance. The junction of this with the portio dura will be seen with the dissection of that nerve.

Posterior branch or Vidian.

The *posterior branch** or *vidian nerve* is directed backwards from the ganglion, and sometimes consists of two filaments at its commencement; it then enters the vidian or pterygoid canal in the root of the pterygoid process, and is enveloped by a strong fibrous sheath, which is closely united to the bone, but is loose around the nerve and its artery; and near the posterior extremity of the canal the nerve divides into two branches; — the carotid, and large superficial petrosal nerve; or when there are two filaments to the nerve, they separate to form these.

Carotid branch.

The *carotid* branch, larger, but shorter than the other, and reddish-looking, passes backwards and outwards, below the superficial petrosal, to join, on the outer side of the carotid artery, with the carotid plexus that surrounds it, thus uniting together the carotid plexus and Meckel's ganglion.

Large Petrosal Nerve.

The *large superficial petrosal nerve*, the other division of the vidian and the continuation of the nerve, is smaller and longer than the carotid branch; it enters the cranium through the cartilaginous substance in the foramen lacerum basis cranii, close against the portion of the sphenoid which bounds anteriorly and externally the foramen, and is then situated in a groove between the contiguous borders of the posterior angle of the great wing of the sphenoid, and the petrous portion of the temporal bone, on the outer side of the carotid artery, and beneath the Gasserian ganglion; it is still continued backwards, escapes from beneath the ganglion, and is received into the groove on the anterior and upper surface of the petrous portion of the temporal bone, by which it is conducted to the hiatus Fallopii to join the portio dura nerve. As the nerve lies on the temporal bone it is covered by the dura mater, is parallel but internal to the small superficial petrosal nerve, — a branch from Jacobson's nerve in the tympanum to join the otic ganglion; in the hiatus it is joined by a small filament from Jacobson's nerve; and its junction with the portio dura, where this nerve changes its direction to pass backwards, is marked, as shown by Arnold, by a gangliform enlargement. The vidian connects Meckel's

* Bock and Arnold describe another posterior branch — the *pharyngeal* — which accompanies the pterygo-palatine artery in its canal, and is distributed to the pharynx.

ganglion with the portio dura, and with the glosso-pharyngeal nerve, by means of Jacobson's nerve.

Dissection. The part of the portio dura that remains to be dissected is that which is contained in the temporal bone,—the portion both internal to the bone and external to it having been examined. If the middle fossa of the base of the skull of this — the left — side has not been divided with a saw, the nerve will be easily exposed with a little care. The nerve extends in a serpentine course from the foramen auditorium internum to the stylo-mastoid foramen, and the dissection may be begun at either end, but it is more convenient to commence at its point of exit from the skull: it would greatly facilitate the tracing this nerve to have at hand a dry temporal bone, with the course of the portio dura and cavity of the tympanum exposed. Saw vertically through the side of the skull between the meatus externus and anterior border of the mastoid process, but close to the latter, and also through the posterior part of the stylo-mastoid foramen; this incision opens the posterior part of the aqueduct of Fallopius, and removes the portion of the skull behind it. The nerve is now seen to be directed upwards and forwards through the petrous substance of the temporal bone with a considerable portion situated above it; remove this projecting part by repeated cuts of the saw and bone forceps, until the nerve in its canal is reached. By the removal of the bone the mastoid cells are exposed, the superior vertical and horizontal semicircular canals are opened, — the portio dura lying below the horizontal one, together with the posterior part of the cavity of the tympanum, a space situated between the squamous and petrous portions of the temporal bone; break away the thin bony plate that forms the roof of the tympanum, and the cavity and its osseous chain are exposed, and one of its bones — the incus — is supported in the mastoid cells, so that these are not to be unnecessarily removed to weaken the slender chain. Along the line of union of the inner wall and roof of this cavity is a hard bony canal that contains the nerve; the overhanging portion is to be taken away with the bone forceps, and the canal to be opened. In the front of the tympanum the nerve suddenly changes its direction, and runs inwards to the foramen auditorium internum; the bone above it is to be removed, and the junction of the vidian with it at this point exposed.* After the internal auditory foramen has been laid open, the portio mollis is seen in its bottom.

Portio dura Nerve. The *portio dura* of the seventh nerve accompanies the portio mollis to the foramen auditorium internum, into which both pass; but the portio dura, that supplies the face, enters an

* The chisel and mallet are not to be used in the dissection of this nerve, since a sudden shock often breaks the bone to pieces and destroys the whole dissection.

aperture in the upper part of the foramen, and lies above the other division. The nerve has a serpentine course, through the aqueduct of Fallopius, in the petrous portion of the temporal bone, and reaches the stylo-mastoid foramen, to be distributed to the face, as before dissected. It first runs horizontally outwards, to the inner wall of the tympanum, and close behind the cochlea of the internal ear; at this part it turns backwards at a right angle, and takes an arched course above the cavity of the tympanum, situated along the upper part of its internal wall in the prominent bony canal above the foramen ovale, and it is next placed between the horizontal semicircular canal, above, and the pyramid below; the nerve now turns almost vertically downwards behind the cavity of the tympanum, or between it and the mastoid cells, and leaves the aqueduct of Fallopius by its lower aperture, or the stylo-mastoid foramen.

Branches.

The *branches* of the nerve in this part of its course are not very many. In the bottom of the internal auditory foramen it joins the portio mollis by some small filaments; and where it makes its sudden turn backwards, in front of the tympanum, receives the vidian or large superficial petrosal nerve which lies in the hiatus Fallopii: the union between the two is inseparable, and a reddish gangliform enlargement is situated at the point of junction. About half an inch before the exit of the nerve from the stylo-mastoid foramen it gives off a delicate branch, — the *chorda tympani*, — which runs upwards and forwards in a canal in the posterior wall of the tympanum, external to, and somewhat in front of the aqueduct of Fallopius in the same wall, then enters the cavity by an aperture close to the ring of bone to which the membrana tympani is attached, about two lines on the outer side of the pyramid, and in the angle of union of the floor and posterior boundary of the space, and, to see it in the tympanum, the incus may be removed from between the malleus and stapes. The nerve is now much increased in size by the mucous membrane reflected around it, crosses the membrana tympani from behind forwards, above its middle, and is closely applied to the long process of the malleus; it leaves the front of the tympanum, on a level with the Glasserian fissure but internal and anterior to it, in a small canal formed partly by the temporal bone and partly by the spinous process of the sphenoid, and situated between the Glasserian fissure and the Eustachian tube; when it escapes from the canal, it is situated deeper than the spinous process of the sphenoid and internal lateral ligament of the jaw, and descends, after a course of about an inch, to join with the gustatory nerve of the inferior maxillary division of the fifth, as seen in the dissection of the other side.

To the Portio mollis.

Junction with the Vidian.

Chorda Tympani.

The *portio mollis*, the larger division of the seventh nerve, distributed to the internal ear, enters the internal auditory

Portio mollis Nerve.

foramen with the portio dura, but inferior to it, and joins with this nerve by some small filaments. In the foramen it divides into two branches; the superior, the smaller, enters the cochlea by the small aperture seen in the bottom of the meatus, and is distributed by many filaments to this part of the ear; the lower portion subdivides into three branches which pierce, separately, the wall of the vestibule in the bottom of the meatus, and supply the sacs of the vestibule and semicircular canals. The anatomy of this nerve is given with the ear.

Dissection. The dissection of the otic ganglion may be taken next in order; but to expose it requires great care, even in a very recent subject, and in this late period of the dissection of the head and neck there is seldom much seen of it. The ganglion is situated on the inner side of the inferior maxillary or third division of the fifth nerve, almost close to the base of the skull, and must therefore be arrived at from within. By the removal of the mucous membrane from the posterior part of the nasal fossa, behind the position of Meckel's ganglion, the Eustachian tube and muscles of the palate are exposed on this — the left— side of the skull. Take away the levator palati; do the same with the Eustachian tube, but with great care, because it crosses the ganglion, and the posterior branches from it lie in close contact with the outer side of the tube; much cellular membrane surrounds the fifth nerve between the skull and upper border of the internal pterygoid muscle, and descending to the inner surface of the muscle is the internal pterygoid branch of the fifth nerve, which could not be reached, from without, on the other side. It is in this cellular membrane that the ganglion will be seen, covered by a fascia; but the readier way to find it is to saw vertically through the portion of the petrous substance of the temporal bone that remains, a little to the inner side of the inner wall of the tympanum, and so as to leave untouched both it and the small superficial petrosal nerve: of course the bone must be supported whilst it is divided. The Eustachian tube and levator palati being removed, follow down the small petrosal nerve to the ganglion, between the petrous portion of the temporal bone and the sphenoid; another small nerve to the ganglion is beneath this, has the same direction on the outer side of the Eustachian tube, and supplies the tensor tympani muscle; the small canal of the muscle is to be opened from the carotid canal which is cut into by the division of the bone: the branches that unite it to other nerves, and the branch to the tensor palati muscle, are not so difficult to follow.

Otic Ganglion. The *otic* or *maxillo-tympanic ganglion*, first dissected by Arnold, is situated on the inner side of the inferior division of the fifth nerve, soon after it has left the skull; and from the resemblance of the nerves joining the ganglion, to those which

come to the ophthalmic in the orbit, its two chief branches of communication with other nerves are named the long and the short root or branch. The ganglion is of a reddish colour, closely united to the internal pterygoid branch of nerve, and above the origin of the auriculo-temporal nerve from this division of the fifth; it is covered on the inner side by the levator palati and Eustachian tube, and is in front of the middle meningeal artery. The ganglion has branches of union with other nerves, and branches of distribution to muscles.

Branches of union. With the Fifth.

The ganglion is united by numerous filaments to the trunk of the inferior maxillary nerve, and to the pterygoid branch of this nerve on which it is placed; these have been named the *short root*, and are analogous to the branch of communication, in the orbit, between the ophthalmic ganglion and the inferior oblique branch of the third nerve. Some small filaments are sent to the auriculo-temporal nerve.

With the Glosso-pharyngeal.

The branch of connection with the glosso-pharyngeal nerve, by means of the nerve of Jacobson, is the *small superficial petrosal nerve*, which commences in the tympanic plexus on the inner wall of the tympanum, escapes from this cavity by a canal appropriated to it, and appears on the anterior surface of the petrous portion of the temporal bone, anterior and external to the large petrosal nerve; it leaves the cranium between the petrous portion of the temporal bone and the spinous process of the great wing of the sphenoid, below the large petrosal nerve, and descends with a direction forwards, parallel to the branch to the tensor tympani muscle, but above it, to join the posterior part of the ganglion: this is the *long root* of the ganglion, and corresponds to the branch, in the orbit, from the nasal nerve to the ophthalmic ganglion.

With the Sympathetic.

Arnold describes, also, some branches of the sympathetic, as accompanying the middle meningeal artery, and joining the ganglion.

Of distribution. To the Tensor Tympani.

One of the branches of distribution is the nerve to the tensor tympani muscle; it arises from the upper and posterior part of the ganglion, ascends obliquely backwards on the outside of the Eustachian tube, below the small petrosal nerve, but with the same direction, and, internal to the spinous process of the sphenoid bone, enters the canal which contains the tensor tympani muscle, to which it is distributed.

To the Tensor Palati.

Another small branch comes from the front of the ganglion, and enters the tensor palati muscle.

Branch of the Fifth to the Internal Pterygoid.

The *internal pterygoid branch* of the fifth nerve, now exposed, arises from the inner side of the upper division of the inferior maxillary branch of the fifth nerve, as soon as it has passed through the foramen ovale, and descends to the under surface of the internal pterygoid muscle, in which it ends; it is a long thin branch, and is joined above by filaments of the otic ganglion.

Dissection. Let the dissector return to the examination of the nasal nerve; and the terminal branches of the internal maxillary artery, and the other arteries to the nose. The nerve enters the cavity through the aperture in the front of the ethmoid bone, and to trace it remove the pituitary membrane from the os nasi, and take away as much of the projecting nasal bone as may conceal it: the filaments of this nerve to the septum are destroyed.

Nasal Nerve. It is only the portion of the *nasal nerve* contained in the cavity of the nose that remains to be seen, since the commencement in the orbit and the termination in the face are dissected. It passes into the nose through an aperture appropriated to it by the side of the crista galli, and when it has entered divides into a branch for the septum, and the continuation of the nerve or the nasal. The *branch to the septum* divides into filaments that ramify on its anterior part, and may be traced to about its middle; and the *nasal branch* or continuation of the nerve runs forwards and downwards, in a groove for it, beneath the spines of the frontal and nasal bones, and at the lower part of the nasal, perforates the membrane joining the cartilage to it, and is distributed to the integuments of the side of the nose. This nerve gives a branch that ramifies in the mucous membrane of the upper part of the outer wall, and on the spongy bones; and as it lies beneath the nasal bone, some small filaments through the apertures in it to the integuments.

Branch to the Septum.

Nasal.

To the Spongy Bones.

Branches of the Internal Maxillary. The *internal maxillary artery* divides in the spheno-maxillary fossa into spheno-palatine, pterygo-palatine, vidian, and superior palatine arteries, which run with the nerves of the same names.

Spheno-palatine Artery. The *spheno-palatine artery* enters the nose through the spheno-palatine foramen, and divides into many branches; some of these are distributed on the wall of the nasal fossa, and on the spongy bones, and some very small branches are supplied to the membrane lining the cavities that receive prolongations from the pituitary membrane of the nose. One long branch, the artery of the septum, descends on the partition between the nostrils as far as to the foramen into the anterior palatine canal, and it here anastomoses with a branch from the superior palatine in the roof of the mouth. This branch accompanies the naso-palatine nerve, and covers the septum with numerous ramifications.

Pterygo-palatine. The *pterygo-palatine* is a very small branch, and often arises from the preceding, it passes backwards through the pterygo-palatine canal, and is distributed to the upper part of the pharynx and Eustachian tube.

Vidian Artery. The *vidian* or *pterygoid branch* is a small artery that enters the pterygoid canal with the nerve of the same name, and, at

its posterior extremity, ends by being distributed to the pharynx.

The *superior palatine*, the largest branch of the internal maxillary, descends in the posterior palatine canal to the roof of the mouth, it now turns forwards along the inner surface of the alveolar arch, with the palatine nerve, and extends forwards to the anterior palatine canal to anastomose with the artery of the septum, which descends to the roof of the mouth, and with the branch of the opposite side, behind the incisor teeth. In the posterior palatine canal the artery gives some branches, through the plate of the palate bone, to the lining membrane of the nose; it gives off other palatine branches for the palatine canals behind it, and these continue with the palatine nerves to the soft palate and tonsil; and as it extends along the roof of the mouth it supplies the glands, mucous membrane, the gums, and alveoli. Superior Palatine Artery.

The *veins* with these branches of the internal maxillary artery join, in the spheno-maxillary fossa, with the infra-orbital vein, to form a plexus that opens into the facial by means of the *alveolar* vein. Veins.

The *other arteries to the nose* are chiefly some branches from the facial near the nasal aperture, and the anterior and posterior ethmoidal; the *anterior* with the nasal nerve supplies the mucous membrane behind the nasal bones, and on the anterior part of the septum; and the *posterior ethmoidal*, only some small branches to the septum: these anastomose with branches of the spheno-palatine. Arteries to the Nose. Anterior Ethmoidal. Posterior.

The dissection of the pterygoid region may be repeated on the portion of the skull that remains; and any portions of either the upper or lower jaws may be immersed in dilute nitric or hydro-chloric acid*, till they are softened, to dissect the nerves in them. Dissection.

DISSECTION OF THE TONGUE.

Take the tongue connected to the larynx, cut off the ends of the muscles, but leave enough to follow them afterwards to their insertion. Dissection.

The *tongue*, the organ of taste, is a muscular and moveable body situated in the interior of the mouth, and it is fixed in its position by muscles, and by the reflection of the mucous membrane to the sides of the cavity. It is somewhat pyramidal in shape, the apex in front and the base behind to the pharynx. The Tongue.

* The strength of this may be about two drachms of the acid to one ounce of water, and this is to be changed at intervals till it is softened.

The upper surface or dorsum of this body, free in the cavity of the mouth, is divided into two equal parts by a median depression that terminates near the base, in an aperture — the foramen cæcum, and when the cavity is closed it is placed in contact with the arched roof. Now the tongue is removed, the dorsum seems horizontal, but before it is taken from its natural position the anterior portion only is horizontal, the posterior being oblique from before backwards. This surface is studded with numerous small papillæ, of which there are three kinds, — the conical, fungiform, and circumvallatæ or caliciform; and near the base it is occupied by some lingual glands. The epiglottis is connected to its posterior part by a central, and by two lateral folds of mucous membrane.

Papillæ circumvallatæ. The *papillæ circumvallatæ* or caliciformes, situated near the base of the tongue, are from sixteen to twenty in number, and are placed in two lines; each of these extends backwards from the side, converging, to meet in front of the epiglottis, and they form thus a V with the legs directed forwards. These papillæ are larger than the others of the dorsum, they have a truncated summit, and are surrounded by membranous cups or collars from which they have obtained their names. In the angle of union of the two legs of the V is the small depression of the foramen cæcum, but this is oftentimes not marked sufficiently to be apparent.

Conical Papillæ. The *conical papillæ,* the most numerous and the smallest, occupy the whole upper surface of the tongue in front of the circumvallatæ; they are connected by their bases, which are placed downwards, and are free by their apices, which are directed rather backwards.

Fungiform Papillæ. The *fungiform papillæ* are larger than the conical, amongst which they are scattered; they are dilated at their free extremities, narrow and pointed at their attachment to the surface, and are readily recognised amongst the conical by their greater size.

Lingual Glands. The *lingual glands* are small glandular bodies, similar to those of the cheek and lips, they are situated at the posterior part of the tongue, and extend as far forwards as the large papillæ with the membranous investments. The borders of the tongue are thick and round behind, but they gradually become smaller near the apex. By the under surface it receives the different muscles that attach it posteriorly, and in front of these it is fixed by the frænum, or fold of mucous membrane beneath the tip.

Dissection. Place the tongue on its dorsum, dissect out the different muscles that are connected to it and enter into its structure; the glosso-pharyngeal nerve is to be preserved on each side, and traced to the side and base of the tongue.

Structure. The tongue consists of the fibres of the different muscles that end in it, a fatty substance being placed between their

Muscles. fibres, together with vessels and nerves. Along the outer side of this body are the fibres of the stylo-glossus directed for-

wards, and internal to these the fibres of the hyo-glossus, which mix with those of the stylo-glossus muscle. In the middle line, from the base to the apex, are the vertical fibres of the genio-hyo-glossus, — the muscle of the right side being separated from the one of the left by a fibrous partition; and between the genio-hyo-glossus and the hyo-glossus is the muscular fasciculus of longitudinal fibres of the lingualis. The fibro-cartilaginous *septum* that divides the tongue into two lateral halves is seen in the middle line between the two genio-hyo-glossi muscles; it is wider and stronger, behind, where it is attached to the os hyoides, than before; its upper border reaches to the dorsal surface of the tongue, the lower appears in the interval between the genio-hyo-glossi muscles, and to its sides are attached the muscular fibres of this body. The *papillæ* are constituted by a filament of a nerve, and by a vascular plexus, surrounded by the mucous membrane with its epithelium: into the conical and fungiform papillæ, the filaments of the gustatory nerve can be traced; and to the circumvallatæ the filaments of the glosso-pharyngeal nerve.

Septum.

Papillæ.

The *nerves of the tongue* are, on each side, the glosso-pharyngeal, gustatory, and hypoglossal; the two latter are dissected, but follow the glosso-pharyngeal into the mucous membrane which covers the base, and trace up also other branches from it through the fibres to the papillæ. The *glosso-pharyngeal nerve* gives off many branches beneath the hyo-glossus muscle; some of these pass through the side of the pharynx, supply its mucous membrane, and descend nearly to the os hyoides, whilst others go to the mucous membrane of the base of the tongue and of the epiglottis; others are supplied to the amygdala, forming a kind of plexus for it. The trunk of the nerve divides near the border of the tongue into two branches; — the upper turns to the dorsum, and supplies the mucous membrane; the lower passes beneath the lingualis, and divides into filaments that perforate its fibres to enter into the muscular substance, and some of these ascend to the papillæ circumvallatæ. This nerve is the smallest of those distributed to this organ, and occupies the posterior part or the portion marked by the extent of the papillæ circumvallatæ. As the *gustatory nerve* passes forwards beneath the lateral part of the tongue, it gives upwards numerous filaments; some of these perforate its substance, to enter the conical and fungiform papillæ, and some turn inwards to unite with the filaments of the hypoglossal or ninth nerve. The *hypo-glossal* or ninth nerve gives filaments, from its upper part, for the supply of the muscular substance: these become suddenly small and disappear; but some filaments join those of the gustatory nerve.

Nerves of the Tongue.

Glosso-pharyngeal.

Gustatory.

Hypoglossa Nerve

The *vessels* to the tongue are dissected; the arteries are derived, chiefly, from the large lingual artery of each side.

Vessels.

DISSECTION OF THE LARYNX.

Dissection. Separate the tongue from the os hyoides, by cutting across its root, without injuring the epiglottis.* Extend the larynx and fasten it in this position with hooks or pins, and dissect on the one side the muscles, but leave the other for the nerves and vessels. On the side for the muscles, cut away from the cricoid and thyroid cartilages, and from the os hyoides, the attachments of the constrictors, as well as the sterno-hyoid and thyroid muscles, and clean, on the front of the thyroid cartilage, a small muscle — the thyro-hyoid — which is attached to the thyroid cartilage and os hyoides; and below this, the crico-thyroid muscle, between the cricoid and thyroid cartilages: the recurrent nerve is seen beneath the lower border of the inferior constrictor. Remove the mucous membrane from the posterior part of the same half of the larynx, to expose a large muscle — the crico-arytænoideus posticus — on the cricoid cartilage; and above this, concealed also by the mucous membrane and on the posterior surface of the arytænoid cartilages, is the arytænoid muscle; but, before the mucous membrane is removed from its pharyngeal surface, dissect out the branch to it from both the superior and inferior laryngeal nerves of the opposite side: some glands are situated on this surface. On looking into the larynx, a depression — the ventricle — is seen on each side, and if a probe or blow-pipe be passed into this, it is found to escape into a small pouch or bag, by an aperture in its front; this bag is called the ventricular pouch, and it is to be filled by introducing small portions of cotton wool, about as large as a pea.

The Larynx The *larynx*, the organ of voice, is the upper dilated portion of the trachea or air tube which conveys air to the lungs, and is situated in front of the spine and pharynx, below the os hyoides and tongue; and by its superficial position it forms the prominence of the front of the neck. Its shape is pyramidal,— the base uppermost, opening into the pharynx by means of the superior aperture, and the apex below, truncated, is continuous with the trachea; the cartilages that enter into the larynx are united together by ligamentous or fibrous membrane, so as to form a moveable body which is elevated or depressed, during deglutition, by the muscles attached to it. The front of the larynx is most prominent, and this projection depends upon the size of the thyroid cartilage, which is larger in males than

* As the cartilages cannot be dissected before the muscles and nerves, so as to leave these untouched, their description will be inserted after; it being presumed that a knowledge, sufficient to comprehend the attachments of the muscles and ligaments, can be easily acquired on a dried preparation of the larynx.

females; below the thyroid is the cricoid cartilage, and between them the crico-thyroid membrane; this surface is covered by the sterno-hyoid, thyroid, and thyro-hyoid muscles, by a part of the inferior constrictor muscle, and by the thyroid body: the prominent angle of the thyroid cartilage in the middle line, or the pomum Adami, is subcutaneous. The posterior part, less convex, is covered by the mucous membrane of the pharynx; the thyroid cartilage is deficient behind, and the ring of the cricoid, which is narrow in front, becomes wide, and is surmounted by the arytænoid cartilages, which reach as high as the upper border of the thyroid. The crico-arytænoidei postici muscles lie on the back of the cricoid, and the arytænoid on the arytænoid cartilages. Attached to the angle of union of the plates of the thyroid cartilage, and at the upper part of the larynx, is the epiglottis or valve which closes the upper aperture of its cavity, when it is laid down.

The *muscles* of the larynx, named from their attachments to the different cartilaginous portions or to the os hyoides, assist, with the ligaments, to connect the cartilages together, and the following is their number on each side: there is one in front, — the thyro-hyoid, — between the thyroid cartilage and os hyoides, and each of the remaining cartilages is connected to the others by one or more muscles; thus, the cricoid is attached, in front, to the thyroid, by the crico-thyroid, behind, to the arytænoid, by the crico-arytænoideus posticus, and, on the side, to the same cartilage, by the crico-arytænoideus lateralis; the thyroid is united to the arytænoid cartilage, by the thyro-arytænoid muscle, situated in the interior of the space included in the alæ of the thyroid cartilage, and to the cricoid, by the crico-thyroid muscle; the arytænoid is connected to the cricoid and thyroid cartilages by the crico- and thyro-arytænoid muscles before mentioned; and the arytænoid cartilages are united together by the arytænoid muscle. Muscles.

The *thyro-hyoid muscle*, described with the sterno-thyroid of the neck, of which it is a continuation, is a flat, somewhat square muscle, attached, below, to the same oblique ridge on the ala of the thyroid cartilage as that to which the inferior constrictor is inserted; and, above, to the cornu of the os hyoides. It is covered by the sterno-hyoid muscle, and lies on the thyro-hyoid membrane, and superior laryngeal vessels. Thyro-hyoid Muscle. Origin. Insertion. Relations.

The *crico-thyroid muscle* is thick and triangular, it is situated between the cricoid and thyroid cartilages, and on the crico-thyroid membrane. It *arises*, below, from the front and side of the cricoid cartilage; and the fibres of the muscle ascend, diverging from each other, to be *inserted* into the lower border of the half of the thyroid cartilage, and into its small cornu. The muscle is covered by the sterno-thyroid, and by the thyroid body; and it conceals the crico-arytænoideus lateralis muscle; Crico-thyroid Muscle. Origin. Insertion. Relations.

between it and the opposite muscle, is the crico-thyroid membrane which is divided in laryngotomy.

Arytænoid Muscle.

The *arytænoid muscle*, single in the middle line, and short and thick, is placed in the hollow on the posterior surface of the arytænoid cartilages which it connects together. Two planes of fibres with different directions are found in this muscle; the

Oblique portion.

superficial — the *arytænoideus obliquus* — consists of two oblique fasciculi which are attached, by one extremity, to the apices of the arytænoid cartilages; and, by the other, to their bases; they cross each other in their centre like the legs of the letter X;

Transverse.

the deep fibres — the *arytænoideus transversus* — pass, transversely, across the interval between the cartilages, and are fixed

Relations.

to their outer borders. It is covered by the mucous membrane and some glands; and it lies on the arytænoid crtilages. There is sometimes another arytænoid muscle described, since a few fibres, situated in the arytæno-epiglottidean fold of mucous membrane on the side of the aperture of the larynx, are named the *arytæno-epiglottidean muscle.*

Posterior Crico-arytænoid Muscle.

The *crico-arytænoideus posticus muscle*, large, flat, and triangular, lies on the posterior part of the cricoid cartilage. The

Origin.

origin is from the depression on the posterior part of the cricoid, on the side of its vertical ridge; its fibres run upwards and outwards, and converge to be *inserted* into the projection on the

Insertion.

outer part of the base of the arytænoid cartilage. The mucous membrane of the pharynx conceals this muscle; and it covers

Relations.

a part of the cricoid cartilage on which it lies.

Dissection.

Open the larynx for the two remaining muscles under cover of the thyroid cartilage; separate the small cornu from its articulation with the cricoid cartilage, on the same side as that on which the muscles are dissected, and remove the square half of the thyroid of the same side, by dividing it near the centre. Clean away the cellular membrane from the muscular fibres exposed, the lower constituting the crico-arytænoideus lateralis, and the upper the thyro-arytænoid muscle: the latter is the most extensive, and reaches upwards to some distance. In removing the cellular membrane near the centre, and upper part of the thyroid cartilage, be careful not to destroy the laryngeal pouch which is prominent and distended.

Crico-arytænoideus lateralis Muscle.

The *crico-arytænoideus lateralis*, a small muscle placed beneath the thyroid cartilage, may be considered only a part of the thyro-arytænoid muscle. It *arises* from the upper border of

Origin.

the side of the cricoid cartilage; the fibres pass upwards and backwards to be *inserted* by a tendon, with the thyro-arytænoid,

Insertion.

into the projection on the outer side of the base of the arytænoid cartilage. The thyroid cartilage and crico-thyroid muscle

Relations.

conceal it, and it lies on the crico-thyroid membrane.

Thyro-arytænoid Muscle.

The *thyro-arytænoideus muscle*, now also dissected, extends backwards from the thyroid to the arytænoid cartilage; it is

thick below and in front, but thin and expanded above and behind. It *arises*, on each side, near the angle of union of the plates of the thyroid cartilage, and from about the inferior third of its depth; the fibres pass backwards, — the inferior, forming a thick bundle, to be *inserted* into the projection in front of the base of the arytænoid cartilage, and also into a slight depression external to this; and the superior, thinner, diverge to be inserted into the anterior and outer surface of the cartilage. Some of the fibres of this muscle are said to ascend to the epiglottis, with the appellation of *thyro-epiglottidean* muscle. The outer surface of the muscle is covered by the thyroid cartilage, and the inner rests on the chordæ vocales, ventricle of the larynx, and its pouch.

Origin. Insertion. Relations.

Divide the trachea and cricoid cartilage along the middle line, behind, without cutting the branch of the recurrent nerve which is given to the arytænoid muscle, and the communication of the superior and inferior laryngeal nerves at the back of the larynx: this is to be dissected afterwards, on the side left for the nerves.

Dissection.

The space in the interior of the larynx is bounded by the cricoid and thyroid cartilages, and that portion included between the wide alæ of the thyroid, is much diminished in size by the existence of the thyro-arytænoid muscle and ligaments, which leave only a narrow angular interval — the glottis — between them, for the passage of the air. Above the glottis, on each side, is a depression — the ventricle of the larynx — situated between the upper and the lower ligament or cord. In the part enclosed by the cricoid cartilage the cavity again enlarges, but its size is limited by this cartilaginous ring. The extent of the cavity of the larynx, below, is the lower border of the cricoid cartilage; and above, the aperture between the epiglottis and arytænoid cartilages, or the superior orifice of the larynx.

Interior of the Larynx.

The *superior orifice* of the larynx, seen by placing together the divided cricoid cartilage, is a triangularly-shaped aperture, with the base in front, and the apex behind, and the sides are sloped off obliquely downwards and backwards. The boundaries of this orifice are, in front, the epiglottis; behind, the arytænoid cartilages and their muscle; and, on each side, the arytæno-epiglottidean folds of mucous membrane, containing a few muscular fibres of the same name, and some ligamentous fibres continuous with the upper vocal cord: this aperture is closed by its valve or the epiglottis during deglutition.

Superior Orifice.

The *ventricle* of the larynx is the oval depression, on each side, between the vocal cords, the upper boundary being semilunar, and the lower, straight. The outer surface is covered by the fibres of the thyro-arytænoideus muscle, and in its anterior part is the aperture into the laryngeal pouch.

Ventricle.

Laryngeal Pouch. The *sacculus laryngis* or *laryngeal pouch* *, best seen by removing the thyro-arytænoid muscle of that side on which the thyroid cartilage has been cut through, is a small membranous *cul-de-sac* which projects, upwards, between the superior vocal cord and the side of the thyroid cartilage. It is conical or cylindrical in shape, about half an inch in depth, and reaches, now it is distended, to the upper border of the thyroid cartilage, or even above it; its cavity communicates with the front and upper part of the ventricle, by a narrow aperture provided with two folds of mucous membrane. The external surface of the pouch is studded with small glands, whose ducts perforate the fibrous and mucous coats to open on the inner surface; numerous nerves are distributed on its outer surface.

Inferior Arytæno-epiglottideus Muscle. The *arytæno-epiglottideus inferior muscle*, also described by Mr. Hilton, is exposed by raising the mucous membrane close above the upper chorda vocalis. "The muscle arises by a narrow and fibrous origin from the arytænoid cartilage just above the arytænoid attachment of the superior chorda vocalis: it passes forwards and a little upwards, and, becoming expanded, covers the superior half, or sometimes two superior thirds, of the pouch on its laryngeal surface; and is inserted by a broad attachment into the edge of the epiglottis."

The Glottis. The *glottis*, the narrowest part of the cavity, is the interval or *rima* between the inferior chorda vocalis of each side, and it is wider behind than before, because the cords are here separated by the interval between the arytænoid cartilages. The antero-posterior measurement, the longest, is, in the male, nearly one inch, and the transverse, behind, about a quarter of an inch; but in the female the measurements are less, particularly the antero-posterior, which is only about two thirds of an inch, because of the smaller development of the angle of union of the thyroid cartilage. Immediately below the glottis, the cavity of the larynx is enlarged in the cricoid cartilage.

Dissection. Remove the mucous membrane from the chordæ vocales which are visible through it, and let it be done on the same side as that on which the muscles are dissected; take away the crico-arytænoideus lateralis muscle, the thyro-arytænoid having been already divided.

Chordæ vocales. Inferior. The *chordæ vocales* or thyro-arytænoid ligaments, are two ligamentous cords on each side, extended from the angle of the thyroid to the arytænoid cartilage. The *inferior* one, the strongest, is a firm fibrous band, attached, in front, to the angle of union of the plates of the thyroid cartilage about the middle of its vertical depth, and behind, to the anterior projection situated at the base of the arytænoid; this ligament consists of

* Mention is made of this structure by Galen; it is described by Morgagni, in his *Adversaria Anatomica*, i. § 16.; and it is also described by Mr. Hilton, in vol. ii. of the *Guy's Hospital Reports*, p. 520.

antero-posterior fibres, and is continuous below with the crico-thyroid membrane, which becomes thin as it is prolonged back to the arytænoid cartilage. It is free on all the other surfaces, and internally looks towards the one of the opposite side, the interval between them being the glottis; externally, it is covered by the thyro-arytænoid muscle; and, above, it forms the lower boundary of the ventricle of the larynx. The *superior cord*, semilunar in shape, and much weaker, contains some fibrous membrane in its structure; it is fixed, in front, to the angle of the thyroid cartilage, above the inferior, and near to the attachment of the epiglottis, and it unites with the fibrous membrane which fixes this fibro-cartilaginous process to the thyroid; it is attached, behind, to the front of the arytænoid cartilage. This ligament is continued above into the fibrous tissue in the arytæno-epiglottidean fold of mucous membrane; and between it and the inferior is the ventricle of the larynx. Superior.

The *mucous membrane* of the larynx is continuous, by the upper orifice, with that of the pharynx, and, below, it is prolonged along the trachea, to the bronchi and cells of the lungs. The membrane covers the epiglottis at the upper part of the larynx, attaching it, in front, to the tongue by the glosso-epiglottidean folds, and, behind the epiglottis, it is connected, on each side, to the apex of the arytænoid cartilage, forming the arytæno-epiglottidean folds of mucous membrane, which bound the superior orifice of the larynx, and contain the arytæno-epiglottidean muscle, and some fibrous tissue between the epiglottis and the superior chorda vocalis; in this part it is very loose, and the submucous tissue becomes readily infiltrated. In the larynx it closely lines the cavity, sinks into the ventricle, and is prolonged into the laryngeal pouch through its small opening; over the vocal cords it is very thin and adherent, so that they are visible through it; it now passes into the space bounded by the cricoid cartilage, and descends along the trachea. The *glands* of the larynx are situated in the arytæno-epiglottidean folds of mucous membrane; and in the thickness of the superior vocal cord; and others, placed in the substance of the epiglottis, have their openings on the laryngeal surface of this structure. Mucous Membrane. Glands.

The nerves to the larynx are now to be traced on the undissected side, and, for this purpose, disarticulate with care the inferior angle of the thyroid from the cricoid cartilage, without cutting the inferior laryngeal nerve which enters at this spot; fasten back with hooks or pins the half of the thyroid cartilage, and separate the cricoid from it, as far as can well be done, by the same means. The superior and inferior laryngeal nerves can now be traced, by only removing the mucous and the cellular membrane, — the superior enters the larynx, either through an aperture in the ala of the thyroid cartilage, or through the mem- Dissection.

brane between the os hyoides and it; and the inferior runs over the side of the cricoid cartilage, giving off a superficial branch which ascends, beneath the mucous membrane, to join a branch from the superior laryngeal.

Superior Laryngeal Nerve.

The *superior laryngeal nerve*, a branch of the pneumo-gastric in the neck, whose course has been already seen, enters the larynx by perforating the thyro-hyoid membrane with the artery of the same name, and, in its interior, divides into a muscular branch for the arytænoid muscle, and numerous filaments for the mucous membrane. The *branch to the arytænoid muscle*, the most superficial, runs downwards and inwards to the posterior part of the muscle which it supplies, and joins, on the back of the larynx, with the superficial ascending branch of the inferior laryngeal or recurrent; this gives filaments to the mucous membrane and glands situated in this spot. The filaments to the mucous membrane are ascending and descending, — the *ascending*, the least numerous, and the smallest, turn upwards in the arytæno-epiglottidean fold of mucous membrane, and supply it and the epiglottis, as well as the cellular structure behind the os hyoides; some of the filaments can be followed to the front of the epiglottis, which they pierce, to be distributed on its laryngeal surface: and the most anterior of this ascending set are continued forwards, in the external glosso-epiglottidean fold of membrane, to the outer and posterior part of the tongue, and are distributed to its mucous membrane: these are cut through if the tongue has been divided close to the os hyoides. The *descending* set give also a filament to join on the side of the larynx, with an ascending filament from the inferior laryngeal; this is variable in size, and descends beneath the thyroid cartilage, and between this and the lower part of the thyro-arytænoid muscle. The other filaments of this set descend, inwards, in the arytæno-epiglottidean fold of mucous membrane, through the interlacement of the vessels supplying it, to be distributed to the mucous membrane of the inside of the larynx, and they reach as low as the inferior chorda vocalis: these branches, in their course, run over the inner side of the laryngeal pouch, forming on it a kind of network, and giving small filaments to it.

Branch to the Arytænoid Muscle.

Branches to the Mucous Membrane.

Ascending.

Descending.

Inferior Laryngeal Nerve.

External branch.

The *inferior laryngeal nerve*, after passing beneath the lower border of the inferior constrictor muscle, and before entering beneath the thyroid cartilage, divides into an external or superficial, and an internal or laryngeal branch; — the *external* ascends beneath the mucous membrane of the pharynx, and if not removed, with this, in exposing the muscles of the back of the larynx, will be seen to lie on the crico-arytænoideus posticus muscle, and to terminate at its upper border by joining with the arytænoid branch of the superior laryngeal nerve, and by supplying, sometimes, the arytænoid muscle: a sort of plexus is

formed at the point of junction of these two nerves. The *internal* or *laryngeal* branch enters beneath the thyroid cartilage, lying on the cricoid, and along the outer border of the crico-arytænoideus posticus muscle, and divides into branches to supply the arytænoideus, thyro-arytænoideus, crico-arytænoideus posticus, and lateralis muscles; the branches to the last muscle are given to it whilst the nerve is entering the larynx; the branch to the arytænoid ascends beneath the crico-arytænoideus posticus muscle, and between it and the cricoid cartilage; and the other branches come from the nerve beneath the thyroid cartilage. It is joined, beneath the thyroid cartilage, by one of the descending filaments of the superior laryngeal nerve. Thus, this nerve supplies all the muscles of the larynx, except the crico-thyroid, which receives its nerve from the external laryngeal branch of the superior laryngeal nerve, and the arytænoid muscle is supplied by both the superior and inferior laryngeal nerves; it joins with the superior laryngeal nerve in two places, first, at the back of the larynx, beneath the mucous membrane of the pharynx; and secondly, on the side of the larynx, beneath the ala of the thyroid cartilage. Internal or Laryngeal.

The *arteries* given to the larynx arise from the superior thyroid, a branch of the external carotid, and from the inferior thyroid, of the subclavian. The *laryngeal branch* of the superior thyroid enters the larynx, with the nerve, by perforating the thyro-hyoid membrane or the thyroid cartilage, and divides into a superior and an inferior branch; the superior ascends to the epiglottis, forming very numerous ramifications on it, and supplying it, as well as the arytæno-epiglottidean fold with vessels; the inferior runs beneath the thyroid cartilage, and supplies the mucous membrane, and the muscles in the interior of the larynx. The *laryngeal arteries* of the inferior thyroid are generally small branches which perforate the crico-thyroid membrane, and ramify in the mucous membrane, as well as supply the muscles of the larynx. Arteries. Laryngeal branch of Superior Thyroid. Of Inferior Thyroid.

The *veins* accompany the arteries, and join the trunks of the veins which run with the arteries of the same name. Veins.

If it be wished, the laryngeal pouch and the chordæ vocales may be examined again on the same side as the nerves, and then the cartilages are to have the muscles removed from them, that their anatomy may be seen. The os hyoides is also to be cleaned. Dissection.

The *os hyoides*, so named from its shape, is situated between the base of the tongue and the larynx; the convexity of the arch that it forms being directed forwards, and the concavity backwards. It has a body and two cornua, on each side. The *body* is flattened and elongated, convex in front, and presents a central vertical projection, and, on each side, a depression marking the attachment of muscles inserted into it; it is con- Os hyoides. Body.

cave behind, looks downwards and backwards, and is connected to the epiglottis by a band of membrane; the upper border is connected to the fibrous tissue which is continued into the tongue. The cornua are joined to the body by surfaces covered with cartilage; the *great cornu* reaches backwards as far as the posterior border of the thyroid cartilage, it is large at its junction with the body of the bone, and ends posteriorly in a tubercle; its surfaces are directed upwards and downwards. The *small cornu* or appendix is directed upwards and backwards, and is joined by the stylo-hyoid ligament, which is sometimes ossified.

Great Cornu.

Small.

Cartilages of the Larynx.

The cartilages of the larynx are four; two single ones, — the thyroid and cricoid, placed in the middle line; and a pair, — the arytænoid, situated one on each side of the central line, together with a fibro-cartilage — the epiglottis.

Thyroid Cartilage.

The *thyroid cartilage* receives its name from its resemblance to a shield; it is situated at the front and upper part of the larynx, the greater part of which it forms, and its increased width, above, gives to the larynx somewhat of a funnel-shape. It is convex in front, and presents, in the middle line, the projection of the *pomum Adami*, which is more marked in the male than female; the posterior surface, concave, gives attachment in front to the epiglottis, chordæ vocales, and thyro-arytænoid muscles, and within its concavity are received the arytænoid cartilages, with the posterior part of the cricoid. It consists of two square parts or halves united along the middle line: the posterior border of each, rounded and thick, ends above and below in the superior and the inferior cornu, the former, the longest, is joined to the os hyoides by the round ligament, and the latter, the thickest and shortest, is articulated to the cricoid cartilage; the upper border, rather convex, ends in the middle line in a depression, it is slightly hollowed out at the root of the superior cornu, and to it is attached the thyro-hyoid membrane; the lower border is rather concave, and joins in the middle line the projecting part or the pomum. The outer surface is marked by an oblique line which extends downwards and forwards, from a tubercle at the root of the superior cornu, to near the middle of the lower border; the portion in front of this is excavated and less strong than the part behind; to the line is attached, in front, the sterno-thyroid, and behind, the inferior constrictor of the pharynx. The inner surface of each lateral half is smooth, and covered by mucous membrane.

Pomum Adami.

Cricoid Cartilage.

The *cricoid cartilage*, the only one of the cartilages of the larynx that forms a ring or circle, is placed below the thyroid, and its depth behind is three or four times greater than before. The lower border, nearly straight, is united to the first ring of the trachea by a fibrous membrane; the upper border, very irregular, presents, in the middle line behind, a straight portion

which extends outwards to the surface for articulation with the arytænoid cartilages, but beyond that, it is very oblique from behind forwards; to it are attached, in front, the crico-thyroid membrane and muscle, and, on the side, the lateral crico-arytænoid muscle. The outer surface, convex, gives attachment, on the side, to the inferior constrictor; but the posterior part, which is flat and rather square, is marked by a median ridge, and on each side of it is the depression for the crico-arytænoideus posticus; the median elevation gives attachment to the commencement of the œsophagus. The inner surface is smooth, and covered by mucous membrane.

Arytænoid Cartilages.

The *arytænoid cartilages*, two in number, are situated at the posterior and upper part of the cricoid cartilage, one on each side of the middle line, articulating with the cricoid at the point where the oblique and straight portions of the upper border meet. Each cartilage is triangular in shape, and bent backwards, so as to present a posterior surface, concave, for the arytænoid muscle, and an anterior, convex and rough, to which is attached the superior vocal cord. The inner surface is flat, and covered by mucous membrane, and the outer gives attachment to some fibres of the thyro-arytænoid muscle. The base is slightly hollowed out to articulate with the cricoid, and has, in front, an elongated process, to which is connected the inferior vocal cord, and behind, and on the outer side, another projection for the attachment of the crico-arytænoideus lateralis and posticus muscles; the apex, pointed and directed backwards and inwards, is surmounted by a cartilaginous process, — the *corniculum* or capitulum of Santorini,—which is inclined to the middle line, and nearly meets the one of the opposite side.

Corniculum.

Cuneiform Cartilages.

Two small cartilaginous processes, named *cuneïform*, are sometimes found in the arytæno-epiglottidean folds of mucous membrane.

Epiglottis.

The *epiglottis*, a fibro-cartilaginous structure, resembling a leaf, is situated behind the tongue and epiglottis, and in front of the superior orifice of the larynx, which, like a valve, it assists to close. It is vertical in position, and kept so by its attachment to the tongue, by means of its ligaments or folds of the mucous membrane. The anterior surface, concave above, but convex below, is connected to the base of the tongue by the glosso-epiglottidean folds; the posterior surface, convex from above downwards, and concave from side to side, is free and smooth, and covered by the mucous membrane; and from its sides the arytæno-epiglottidean folds of mucous membrane pass backwards. If the membrane that covers the epiglottis be removed, the lower attachment can be seen; this part of the epiglottis is thin and narrow, and is connected to the angle of union of the plates of the thyroid cartilage, above the chordæ vocales, by the *thyro-epiglottidean* ligament; to the root of the tongue by a strong

median band, and by another ligamentous structure to the os hyoides. Between it and the os hyoides is a mass of yellowish fat, named the *epiglottidean gland*. The epiglottis is perforated by numerous small apertures, and it contains some small glands in its interior.

Ligaments of the Larynx.

The ligaments of the larynx unite together the thyroid, cricoid, and arytænoid cartilages, which enter into it, and each cartilage is connected to the other two: between some of the points of union are found capsular ligaments and synovial membranes, but others have only ligamentous bands or membrane intervening between them.

Thyro-hyoid Ligament.

The *thyro-hyoid ligament* is a thin loose membrane between the bones from which it receives its name, and is connected, below, to the upper border of the thyroid cartilage, and, above, to the upper border of the posterior surface of the os hyoides: it is thicker in the middle than at the sides, and ends behind, on each side, in a rounded cord, which connects the upper cornu of the thyroid cartilage to the rounded extremity of the os hyoides. This ligament is covered in front by the thyro-hyoid muscle, and is perforated by the superior laryngeal nerve and its artery; beneath, it is in contact with the cellular structure and mucous membrane of the larynx. A synovial membrane is placed between the upper border of the thyroid cartilage, and the under part of the os hyoides.

The cricoid and thyroid cartilages are connected, in the centre, by a fibrous band, — the crico-thyroid; and laterally, by a capsular ligament and synovial membrane between the small cornu of the thyroid, and the side of the cricoid.

Crico-thyroid Ligament.

The *crico-thyroid membrane* or ligament, is thick and strong in the middle line, presenting a triangular portion which is fixed, above, to the centre of the lower border of the thyroid, and, below, by its wider part or base to the upper border of the cricoid cartilage; the lateral parts of the ligament are much weaker, and are inserted, below, into the border of the cricoid, but each joins, above, the inferior chorda vocalis. Numerous small apertures exist in this membrane for small vessels; on it lies the small transverse arch of the inferior thyroid arteries, and it is covered by the crico-thyroid and crico-arytænoideus lateralis muscles; and in the interior of the larynx, it is lined by mucous membrane.

Crico-thyroid Articulation.

An *orbicular*, or capsular ligament, surrounds the articular surfaces between the small cornu of the thyroid and the side of the cricoid cartilage; and these are covered by a *synovial membrane*. This articulation allows of but little motion, and chiefly fixes together the two cartilages.

The Cricoid to the Trachea.

The lower border of the cricoid is joined to the first ring of the trachea by the same ligamentous band that connects the cartilages of this tube together.

The articular surfaces of the arytænoid and cricoid cartilages are united together by a *capsular* membrane which is strongest on the inner and outer sides, and the surfaces are lined by a loose *synovial membrane*. The capitula are united to the arytænoid by cartilage or ligament. Crico-arytænoid Articulation.

The ligaments uniting the arytænoid to the thyroid cartilage, or the *thyro-arytænoid*, are the chordæ vocales. whose attachments have been seen. Some few fibres pass from the arytænoid cartilage to the epiglottis. Thyro-arytænoid Ligaments.

Open the trachea by carrying an incision along the front, in order to see its structure. The extent of the tube is from opposite the fifth cervical to the third dorsal vertebra, or about four inches, and its size is greater in men than in women. The trachea consists of a fibrous tube in which are developed cartilaginous processes, forming parts of circles, and a greater portion of the fibrous tissue is found on their cutaneous than on their tracheal surface. The cartilages in the tube of the trachea are from sixteen to twenty in number, and each forms only the two thirds or three fourths of a circle, the space, behind, being filled up by muscular fibres; each segment of a circle is convex in front, and concave behind, but their depth differs, the first being the widest; or two below this may be joined together. The last cartilage, or the one at the bifurcation into the bronchi, is V shaped, and the legs of the V are curved, on each side, to form the first cartilage of the bronchus: by the strength of the cartilages, this tube always remains open for respiration. If the fibrous membrane be removed from the outside, in the interval between the ends of the cartilages, the transverse muscular fibres which occupy the space between their truncated extremities will be exposed; and on the inside of these are longitudinal bundles of a yellow elastic tissue, which occupies the portion of the tube made up by the muscular fibres. Some glands are situated between the fibrous and muscular layers, as well as in the fibrous structure between the cartilages. The mucous membrane lines the whole tube, is continuous, above, with the lining of the larynx, and, below, with that of the lungs and their cells. The *arteries* to the trachea are chiefly from the inferior thyroid; and the *nerves* from the sympathetic, and recurrent of the pneumo-gastric. The structure of the bronchi is seen in the thorax. Structure of the Trachea. Arteries Nerves.

CONTINUATION OF THE NECK.

Take the portion of spine which has been set aside after the separation of the pharynx, and continue with the anatomy of Dissection.

the deep muscles in front of the cervical vertebræ. To expose these it is only necessary to remove the fascia that covers them. The muscles are few in number and are easily distinguished; one covering the bodies of the vertebræ, nearest the middle line, and extending from the cervical to the dorsal region, is called the longus colli muscle; a muscle external to it, which reaches from the transverse processes of the lower cervical vertebræ to the head, — the rectus capitis anticus major; and the small muscle external to this last, and rather behind it, between the atlas and occipital bone, — the rectus capitis anticus minor. This last is generally cut through in dividing the basilar process of the occipital bone, for the dissection of the pharynx. The rectus capitis lateralis was dissected in the neck. These muscles are the same on both sides of the middle line.

Longus Colli Muscle.

The *longus colli muscle* is situated in front of the cervical, and of the upper dorsal vertebræ, which are nearly covered, on each side, by it; it is pointed and tendinous above, and fleshy below. The direction of the fibres of the upper and lower portions of this muscle are so different, that they have been described

Lower portion.

separately. The *lower* or *inner portion* consists of fleshy fasciculi whose direction is vertical; it is fixed, below, to the lateral part of the bodies of the three upper dorsal, and the four lower cervical vertebræ, and to the intervening fibro-cartilages; the fibres ascend to be inserted, by aponeurotic bands, into the

Upper portion.

bodies of the second and third cervical vertebræ. The *upper* or *external* is directed, from without inwards, towards the middle line, and is attached, inferiorly, to the fifth, fourth, and third cervical vertebræ; the fibres are directed upwards and inwards, and end in a pointed tendon which is inserted into the body of

Relations.

the atlas. This muscle is concealed by the pharynx and œsophagus, by the common carotid artery and internal jugular vein, with the accompanying pneumogastric and sympathetic nerves; and it lies on the vertebræ. Its inner border corresponds to the middle line of the spine, and to the muscle of the opposite side to which it is united above; and its outer, to the scalenus anticus muscle, but it is separated from this by the vertebral vessels; above this, it is in contact with the rectus capitis anticus major muscle.

Rectus Capitis anticus major Muscle.

The *rectus capitis anticus major muscle* is external to the preceding, and projects more in front than it; the largest end of the muscle is at the occipital bone, and is marked by a

Origin.

tendon on the pharyngeal or cutaneous surface. It *arises* below, by pointed and tendinous attachments, from the anterior tubercles of the transverse processes of the sixth, fifth, fourth, and third cervical vertebræ, — the same transverse processes into which the scalenus anticus muscle is inserted, and with which it is united at its origin; from this attachment the fibres

Insertion.

ascend, and form a thick muscle, which is *inserted* into the basilar

process of the occipital bone in front of the foramen magnum. The bundle, that arises from the third cervical vertebra, is inserted posterior to the rest, and separate from them. The anterior or pharyngeal surface is covered by the pharynx, internal carotid, jugular vein, eighth, ninth, and sympathetic nerves; it lies in front of the upper cervical vertebræ, and partly conceals the rectus capitis anticus minor muscle. Along the inner border is the longus colli muscle. Relations.

The *rectus capitis anticus minor muscle*, small and flat, situated external and posterior to the last, *arises* from the transverse process of the atlas, and partly from its anterior ring of bone; the fibres ascend to be *inserted* into the basilar process of the occipital bone in front of the foramen magnum, and between it and the insertion of the rectus capitis anticus major. The anterior surface is covered by the rectus major, and ganglion of the sympathetic nerve; and it lies on the ligament between the occipital bone and the atlas. The anterior branch of the first cervical or sub-occipital nerve appears between this muscle and the rectus capitis lateralis. Rectus Capitis anticus minor Muscle. Origin. Insertion. Relations.

To expose the inter-transversales muscles in the upper part of the cervical region, in which they are best seen, remove from the anterior tubercles of the transverse processes the rectus capitis anticus major; and from the posterior, the levator anguli scapulæ, transversalis colli, and trachelo-mastoid muscles, and part of the posterior scalenus. These small muscles are found on each side of the anterior branch of the nerve as it leaves the intervertebral foramen, and they are closely united to the fibres of the muscles to be removed. Dissection.

The *inter-transversales muscles*, so called from their position, occupy the intervals between the transverse processes; they are small elongated muscles, two for each space, except the first, in which there is only one, and that on a level with the anterior set, so that there are six anterior and five posterior muscles on each side. They are attached, above and below, to the anterior and posterior tubercles of the transverse processes. These muscles are separated from each other, in the spaces, by the anterior branch of the cervical nerve which escapes between them, and beneath the posterior one is the posterior branch of the same nerve passing backwards; they are closely united to the muscles which are connected to the tubercles of the transverse processes. The first is near to the vertebral artery in the first space, but it is separated from it by the anterior branch of the second cervical nerve which turns forwards from behind. Inter-transversales Muscles. Relations.

The relations of the cervical spinal nerves at their exit from the canal, by the intervertebral foramina, can be better examined now, than in any previous stage of the dissection. The nerves lie in the intervals between the transverse processes, and the Exit of the Spinal Nerves.

anterior and posterior branches diverge from them; the anterior, lying in a groove, appears in the interval between the processes, and between the inter-transversales muscles, to join in the cervical and in the brachial plexus; the posterior passes backwards beneath the posterior inter-transversalis muscle, and the other muscles attached to the posterior tubercles, and in a groove between the articulating processes, to enter the fibres of the semi-spinalis colli, or pass between this and the complexus, from which point its distribution has been followed; it gives some branches to the muscles which cover it. The first and second nerves are an exception to this distribution, since the ganglion of the first is on the upper surface of the arch of the atlas, and that of the second nerve on the arch of the axis, and, from each ganglion, the anterior branch runs forwards to the cervical plexus across the vertebral artery; the posterior branches of the two first cervical nerves enter the muscles, to which they are, in great part, distributed.

Vertebral Artery. The *vertebral artery* has separate relations in the neck, previously to entering into the chain of foramina in the transverse processes, and also after it has escaped from these and has entered the skull; it has been seen in these two parts, and now there only remains to examine it in the foramina: for this purpose, cut away with a bone forceps the anterior part of each transverse process, and the artery with its accompanying vein and plexus of nerves will be exposed. The artery enters, generally, the foramen in the transverse process of the sixth cervical vertebra, though the point of entering varies much; it then ascends, vertically, in the series of foramina situated in the processes of the cervical vertebræ, as high as to the upper border of the second, where it is directed outwards to reach the aperture in the transverse process of the atlas or first vertebra. When the artery has passed through this, it winds horizontally backwards and inwards, on the posterior arch of the atlas, and behind the articulating process of this bone, perforates the posterior ligament, and ascends, as before seen, by the side of the medulla oblongata, to join, with the opposite, in the basilar, at the lower border of the pons. In its course through the foramina the artery lies, below the axis, in front of the cervical nerves, but the anterior branch of the second nerve crosses it, superficially, in the interval between the first and second transverse processes; the vertebral vein and plexus of nerves are found with the artery in the canal.

Branches. The artery does not give off any named branches in this course, but numerous small arteries which enter the spinal canal, along the nerves, to supply these and the cord, and to anastomose with the other arteries of the canal. On the arch of the atlas it gives branches to the deep muscles, and some to anastomose with the occipital artery.

Vein. The *vertebral vein* commences in small veins from the muscles

of the back, and from the occipital veins, and enters the transverse process of the atlas, where it is sometimes joined by a vein from the posterior condyloid foramen. In the canal with the artery it is joined by veins from the interior of the spine as well as from the external parts; and, after it has left the foramina, it lies external to the artery, receives the vein corresponding to the cervicalis ascendens artery, and sometimes a branch from the vein with the profunda cervicis artery, and opens into the brachio-cephalic vein.

Vertebral Plexus.

The *vertebral plexus* comes from the inferior cervical ganglion. The nerves that form it ascend with the artery, encircling it, and join with the spinal nerves. In the dissection of the anterior branch of the first or sub-occipital, filaments were seen descending around the vertebral artery to join the plexus, and the second nerve is also joined by it when passing over the artery.

Dissection.

On the remaining part of the spine dissect the ligaments that connect one vertebra to the other. Disarticulate the seventh cervical vertebra from the first dorsal, and the occipital bone may be sawn through vertically, so as to leave only an osseous ring to bound the foramen magnum behind; remove the muscles, vessels, and cellular structure, from the vertebræ.

Ligaments of the Vertebræ.

The ligaments found in the cervical region are, as in the others, an inter-articular fibro-cartilage between the bodies of the vetebræ, and an anterior and a posterior common ligament; with ligamentous bands between the plates and spines of the vertebræ, and capsular ligaments and synovial membranes between the articulating processes: these vary in the different regions according to the peculiarities of the vertebræ in them. Proper ligaments are placed between the occipital bone and the atlas, and between the atlas and the axis, which may be examined after the common ligaments.

Inter-spinal Ligaments.

The spines of the vertebræ are connected together through the medium of a ligamentous band — the *inter-spinal ligament* — stretched from the base to the apex. This structure is thin in the cervical region, and is placed between the inter-spinales muscles. In the other regions, small ligamentous bands connect the tips of the spines together, and are named *supra-spinal* ligaments.

Supra-spinal. Dissection.

The intervals between the plates of the vertebræ are occupied by the ligamenta subflava, which thus complete, behind, the spinal canal. These ligaments are best dissected from within; and the portion of the spinal canal, left untouched in the dissection of the cord, is to be opened by sawing through the transverse processes at their junction to the bodies of the vertebræ, by which the plates and articulating processes of these bones will be removed in one piece. The posterior arches of the first and second vertebræ are not to be sawn through, and the arch of the third is to be separated from that of the second vertebra,

by disarticulating it. After cleaning these ligaments, examine them from the inner side.

Ligamenta subflava.

The *ligamenta subflava* receive their name from their colour, and are found between the laminæ of the vertebræ, from the second to the sacrum, but not between the first and second. Their size depends upon the intervals between the plates of the vertebræ, and they are larger in the neck than in the back, but in this region they are smaller than in the loins: they consist of a yellow elastic tissue, the fibres of which are vertical. In each space there are two portions of this ligament, one for the right, and one for the left lamina; they approach each other, in the middle line, at the spinous process, and reach, externally, to the articulation between the articulating processes; each portion is fixed to the under surface of the lamina above, and to the upper border of the one below: separate one or two laminæ by cutting through the ligament, and its thickness and attachments will be better seen. The surface of these ligaments towards the canal, is in contact with the dura mater, and only separated by cellular membrane; the other surface is partly concealed by the laminæ, and by the multifidus spinæ muscle.

Union of the Articulating Processes.

The articulating processes of the vertebræ are surrounded by a *capsular ligament* of a few scattered fibres, which is thicker on the outer than the inner side. The articulating surfaces are covered with cartilage, as may be seen by separating them, and are surrounded by a *synovial membrane.*

Anterior Common Ligament.

The *anterior common ligament,* placed in front of the spinal column, extends from the axis to the sacrum, and is narrower in the cervical than the other regions, in consequence of the small size of the bodies of the vertebræ. It is attached to the axis by a pointed process which is united to the tendon of the longus colli, and, opposite the centre of the body of each vertebra, it is rather wider than opposite the intervertebral substance. The vertical fibres that constitute this ligament consist of two or more layers, the superficial passing over the bodies of three or four vertebræ, but the deeper extend only from one vertebra to the other; the fibres are for the most part united to the borders of the bodies, and to the intervertebral substance. In the neck it is in contact with the longus colli and the œsophagus; and it rests on the vertebræ, and on some small arteries that lie beneath it.

Posterior Common Ligament.

The *posterior common ligament,* situated in the spinal canal, is extended along the posterior part of the bodies of the vertebræ, in the same manner as the anterior in front; it commences, above, at the occipital bone, joining at this part a ligamentous structure — the occipito-axoid ligament, — and it reaches to the sacrum; its width, unlike the anterior, is greater opposite the intervertebral substance than opposite the bodies of the vertebræ. In the neck and back it is altogether larger

than in the lumbar region; and the anatomy of its upper part will be seen when the arches of the atlas and axis are removed. The fibres form one or two layers which have the same arrangement in their attachment to vertebræ, as in the anterior common ligament. One surface of the ligament is in contact with the dura mater, and the other lies on the vertebræ, and on some vessels entering their structure.

Intervertebral Substance.

The *intervertebral substance* or *fibro-cartilage* is a cartilaginous plate or disk, between the bodies of the vertebræ which determine its shape. In the neck they are not found between the first and second, but they exist between all the rest: they are thicker before, than behind, in the neck, which gives the convexity forwards of the portion of the spinal column formed by the cervical vertebræ, and the same is the case in the lumbar region. Each disk is thinner in the neck and back than in the loins; it is attached, above and below, to the bodies of the vertebræ, and, in front and behind, to the common ligaments of the bodies. It consists of distinct laminæ at the circumference, the fibres of one crossing those of the next, but this is best seen in the lumbar region, in which the cartilages are largest and thickest. Separate the body of the last cervical vertebra from the one above it, and the difference in the texture of the centre, which is a soft, spongy tissue, filled with a viscid substance, instead of being fibrous and laminar as the exterior, is very manifest. If two other bodies be sawn across, vertically, the pulpy substance of the centre projects in the incision.

External Ligaments of the Atlas and Axis.

The two first vertebræ are united together by ligaments connecting their arches and articular processes; as well as by some special, but accessory ligaments in the interior of the canal, and which cannot be seen without opening the canal.

Posterior Atlo-axoid Ligament.

The arch of the atlas is united to that of the axis by an anterior and a posterior atlo-axoid ligament. The *posterior* is a thin, loose, membranous-looking structure, attached, above, to the posterior arch of the atlas, and, below, to the upper border of the arch of the axis: some vertical fibres of a yellowish colour, resembling the ligamenta subflava, form a deep layer for this membrane. The rectus major crosses the ligament, and the second cervical nerve perforates it.

Anterior Atlo-axoid.

The *anterior ligament* connects the anterior arches in the same manner as the posterior unites the arches behind: the middle part of this ligament is the strongest.

External Ligaments of the Atlas and Occipital Bone.

The first vertebra, the atlas, is connected to the occipital bone by means of condyles and articulating surfaces; and farther, by an anterior and posterior ligament: the latter set, only, can now be seen.

Posterior

The ligaments, which connect the arch of the atlas to the occipital bone, are named *occipito-atloidean*. The *posterior liga-*

Occipito-atloidean. *ment* is fixed to the posterior part of the circumference of the foramen magnum, and to the posterior arch of the atlas; it is very thin, and in relation with the dura mater which is connected to the aperture of the spinal canal. The sub-occipital or first cervical nerve, and the vertebral artery, perforate it on each side of the middle line. The *anterior ligament* is placed between the anterior margin of the foramen magnum, and the anterior arch of the atlas. It has a central portion which is thick and firm, and is fixed above to the basilar process of the occipital bone, and below to the anterior tubercle of the atlas; and the other part, wider, reaches from the articulating condyles of the one side, to those of the other. The recti capitis antici minores muscles are in contact with this ligament.

Anterior Occipito-atloidean.

Dissection. The remaining ligaments connecting these bones are situated in the interior of the spinal canal, which will be required to be opened to see them. The occipital bone articulates with the atlas, by its condyles, with the axis or second vertebra through the medium of intervening ligaments; and the second and first vertebræ are connected also by a transverse ligament. To expose these, cut through the arches of the atlas and axis internal to the articulating surfaces, so as to leave untouched these processes; remove also the whole of the posterior part of the circumference of the foramen magnum; detach the tube of the dura mater from the interior of the canal, and remove it, and the posterior common ligament, ascending to the occipital bone, is brought into view.

Internal Ligaments of the Occipital Bone and Axis. The occipital bone is connected to the axis or second vertebra by strong ligamentous bands, although these bones are not in contact; they are three in number, a central, and two lateral or check ligaments.

Occipito-axoidean Ligament. The *occipito-axoidean ligament* is a thick fibrous band, not very visible till the continuation, upwards, of the fibres of the posterior ligament is removed. It is then seen to be attached, above, to the grooved or cranial surface of the basilar process of the occipital bone, in front of the foramen magnum, and between the condyles; it descends, vertically, in the spinal canal, over the odontoid process, to be attached to the body of the axis, and to join the posterior common ligament at this part; some of the lateral fibres are continued on to the body of the third vertebra. If the superficial portion of the ligament be divided between the projection of the odontoid process and the foramen magnum, a deeper but shorter process of it is seen to be fixed to the upper part of a transverse ligamentous band which binds down the odontoid process, and maintains it applied to the atlas. A synovial membrane is sometimes placed between the anterior part of this transverse ligament and the descending or superficial fibres which go to be inserted into the body of the axis. Cut entirely through both portions of this ligament, and

the odontoid or check ligaments, between the same bones, are exposed.

The *odontoid* or *check ligaments* are two strong, round, fibrous processes, about half an inch long, attached, below, to the apex and sides of the odontoid process, they then ascend, with a direction outwards, to be inserted, on each side, into a depression on the inner surface of the condyle of the occipital bone. A transverse band is sometimes found to connect them below the occipital bone, and to be joined by some fibres from the tip of the odontoid process. These ligaments are covered by the occipito-axoidean band, and lie against the anterior ligament between the atlas and axis. Odontoid or Check Ligaments.

The two first vertebræ are united together by articular surfaces, and by the odontoid process of the second, which is covered with cartilage, and retained in its position against the arch of the atlas, by a transverse band. Internal Ligaments of the two first Vertebræ.

The *transverse ligament* is a flat cartilaginous band, of a yellow colour, stretched horizontally behind the odontoid process which it keeps fixed against the anterior arch of the atlas; it is attached, on each side, to the depression on the inner surface of the articulating process of the atlas, and this is better seen by cutting away, on one side, a part of this process, till its insertion into it is reached. The upper border projects in the middle line above the odontoid process, and receives the fibres of the deep portion of the occipito-axoidean ligament; the lower is free, and closely binds the narrow part or neck of the odontoid process. The surface of the ligament, which looks towards the dura mater, is crossed by the superficial fibres of the occipito-axoidean ligament, but a synovial membrane intervenes between them. Cut across both this ligament, and the check ligaments, and partly disarticulate the odontoid process, which is now seen to be covered by cartilage on both the anterior and posterior surfaces, for its articulation with the arch of the atlas, and the transverse ligament. Two *synovial membranes* facilitate the rotatory movements of this process of bone, — the one being placed between it and the arch of the atlas, and the other between it and the transverse ligament which binds it down. Transverse Ligament. Synovial Membranes.

The *capsular ligament* which surrounds, on each side, the articular surfaces of the two first vertebræ, is fixed to their margins above and below, and is stronger in front than behind. Cut open the articulation, to see the form of the articular surfaces covered with cartilage; they are almost horizontal, those of the axis being directed upwards and outwards, and those of the atlas downwards and inwards. The *synovial membrane* of each articulation is very loose, projects beyond the articular surfaces, comes into contact, on the inner side, with the odontoid process and transverse ligament, and is sometimes continuous with the synovial membrane between these. The vertebral artery Union of the Articular Processes. Capsular. Synovial Membrane.

lies on the outer side of each articulation. Disarticulate, entirely, the odontoid process, and the attachments of the transverse ligament are more fully exposed.

Internal Ligaments of the Occipital Bone and Atlas. Capsular.

The only remaining articulation is that between the condyles of the occipital bone, and the articular surfaces of the atlas. This articulation is surrounded by a *capsular ligament* of a few scattered fibres, strongest externally and in front, which is attached around the articular surfaces, both above and below. Open the articulation, the condyles of the occipital bone look downwards and outwards, and the articular surfaces of the atlas, upwards and inwards. The *synovial membrane* is much the loosest on the outer side, and projects on to the occipital bone.

Synovial Membrane.

Sterno-clavicular Articulation.

Examine next, on the piece that has been laid aside, the ligaments that connect the clavicle to the sternum; remove the cellular membrane that surrounds them; and should they have become dry, immerse them for a short time in water. The sternal end of the clavicle articulates with a depression on the side of the upper piece of the sternum, and is kept in place by ligaments which surround it; it is received on a fibro-cartilage which enlarges the articular surface.

Anterior Ligament.

The *anterior ligament* consists of diverging fibres, attached by a narrow process to the head of the clavicle; from this it is continued over the articulation to the front of the sternum. The cutaneous surface is covered by the sterno-mastoid, and the other is united to the inter-articular fibro-cartilage.

Posterior.

The *posterior ligament*, less strongly marked than the anterior, is a flat band behind the joint, attached to the posterior part of the head of the clavicle, and to the sternum; it is covered by the sterno-hyoid muscle, and adheres to the fibro-cartilage.

Inter-clavicular.

The *inter-clavicular ligament* extends between the heads of the clavicles, above the upper part of the sternum; the fibres of this ligament do not cross in direct lines, but they dip into the hollow between the two clavicles, and are connected to the sternum. The anterior surface is in contact with the integuments, and the posterior with the sterno-thyroid muscles.

Costo-clavicular Ligament.

The *costo-clavicular ligament*, although not connected to the sternum, still serves to maintain the clavicle in position, by its attachment to this bone. It is a short, but very strong ligament, consisting of oblique fibres which are attached, below, to the inner and upper part of the cartilage of the first rib, and, above, to the inner part of the lower surface of the clavicle, near its sternal end. The anterior surface is in contact with the subclavius muscle, and the posterior with the subclavian vein. Sometimes the clavicle touches the rib, and there is a distinct articular surface, and synovial membrane.

Inter-articular Fibro-cartilage.

The *inter-articular fibro-cartilage* will be seen by cutting through the ligaments before described, since this will allow the clavicle to be raised. It is a flat cartilaginous plate, almost circular in

form, but thicker at the circumference than in the centre, in which there is sometimes an aperture. Above and behind, it is united to the head of the clavicle, which is imbedded in the cartilage, and, below, it is connected to the cartilage of the first rib; it is joined, by its circumference, to the ligamentous structure in front of the articulation, and behind it.

Two *synovial membranes* are found in this articulation; one on the upper surface of the fibro-cartilage, between it and the clavicle, and the other, below, between it and the first rib. Synovial Membranes.

DISSECTION OF THE EAR.

The ear, the organ for the perception of sounds, consists, in man, of an external trumpet-shaped cartilage, for the concentration of sounds, attached to the outer surface of the temporal bone, and of two distinct cavities situated in the centre of its petrous portion; one of these—the tympanum or middle ear — is connected to the external cartilage by the meatus externus; and the other — the labyrinth or internal ear — communicates with the middle by an aperture in its outer wall, into which is fixed the last bone of the osseous chain which reaches across the tympanum. The different parts accessory to the function of the sense of hearing will be dissected with the cavities, together with the nerves and vessels.

To obtain a knowledge of the anatomy of the two internal cavities of the ear, requires the dissection to be undertaken, both on the dry and on the recent temporal bone, in order that the osseous boundaries may be seen in the one, and the soft parts in the other. Since both temporal bones have been unavoidably destroyed in the previous dissection of the head and neck, it will be necessary to procure two fresh ones from another source; and that, which will be used for the dissection of the nerves, should be steeped in acid till it is quite softened.* If a minute examination of the internal ear be wished, it will be necessary to soften both temporal bones in the acid. Previously to commencing the dissection on the recent temporal bone, expose the cavities in a dry one, which will greatly facilitate the understanding these minute parts. Open the cavity of the tympanum by cutting through the thin osseous plate that forms the roof, and is situated in the angle of union of the squamous and of the upper surface of the pyramidal or petrous portion of the temporal bone: cut into the meatus auditorius through the Dissection.

* The proportion of this is about half an ounce of hydro-chloric acid to half a pint of water, and it should be changed occasionally till the bone is softened.

bony plate behind the Glasserian fissure, and if these have been made sufficiently large, the tympanum is exposed. The vestibule will be seen by cutting deeply into the posterior surface of the petrous substance of the temporal, between the meatus auditorius internus and the aqueduct of the vestibule. The three semicircular canals, that open into the vestibule, are behind the cavity, and must be separated from the surrounding bone by means of a file or small saw. The position of the superior vertical is marked by a projection, on the upper surface of the petrous portion, about half an inch behind the meatus auditorius internus; the inferior or posterior vertical will be found, behind the other, on the posterior surface, and rather behind the aqueduct of the vestibule; and the horizontal lies behind and between the other two, and deeper than they. The cochlea is in front of the vestibule, its position is transverse, between the meatus auditorius and the inner wall of the tympanum; and to obtain a view of it, the petrous substance, above it, is to be filed or cut away, down to the level of the meatus. In the recent temporal bone, the dissection necessary to expose the meatus externus and cavity of the tympanum is to be first made; but, as the boundaries of the space will be more destroyed, than in the former method on the dry one, both preparations must be employed, at the same time, in the examination of its anatomy. For this purpose, remove the greater part of the squamous portion of the temporal bone by a cut of the saw, directed through the root of the zygoma, and a little in front of the Glasserian fissure; the upper surface of the petrous portion is now seen, and on it the vidian nerve entering the hiatus Fallopii. Take away the osseous plate external to the line of the nerve, and the cavity of the tympanum is perceived, as in the other preparation, with its chain of bones across it; rather below the vidian, and to the outer side of it, is the tensor tympani muscle, contained in a bony canal, which is to be laid open; and close to this, but below it, another small canal for the Eustachian tube. In opening the tube, back to the tympanum, the small portion of bone that was left by the saw, in front, of the Glasserian fissure, will be taken away; but this is to be done carefully, so as not to remove the laxator tympani muscle which passes through the fissure; of course the chorda tympani is destroyed, but the nerves are scarcely referred to in this dissection for the osseous and muscular parts. The meatus is now to be laid open, either with the saw or with a bone forceps, without, however, injuring the membrana tympani which closes the lower or internal part.

Meatus auditorius externus.

The *meatus auditorius externus*, or canal that extends from the concha of the external ear to the tympanum, is partly osseous and partly cartilaginous and membranous; its length is about one inch and a quarter, and its direction is obliquely downwards

and forwards, but it is somewhat curved, the convexity looking upwards. The extremities of the canal are wider than the centre, and the lower wall is about two lines longer than the upper, because of the direction in which it is sloped at the inner extremity; the outer extremity opens into the concha of the external ear, and the inner is closed by the membrana tympani.

Cartilaginous part.

The *cartilaginous part* of the meatus, about half an inch long, is formed, below and in front, by a triangular cartilaginous plate which is a continuation of the cartilage of the external ear, bent upon itself, and then reflected upwards to be attached to the rough bony margin of the meatus; above and behind, or in the interval between the auricle of the external ear and the reflected part which is attached to the margin of the meatus, the tube consists of a dense fibrous membrane which contains some ceruminous glands.

Osseous part.

The *osseous part* of the canal, best seen on the dry bone, is about three quarters of an inch in length, and, like the meatus, of which it forms the greater part, is constricted in the centre; the extremities are the widest portions, and the outer one is rough, especially below, for the attachment of the cartilage. In consequence of the direction in which the ends are sloped, the anterior boundary of this part of the canal extends beyond the posterior, at the inner orifice, but the posterior projects, farthest, at the outer aperture. The auditory passage is lined by a prolongation of the integument, which is also continued over the membrana tympani by a very fine pellicle; some hairs are connected to the cuticle, and in the cellular tissue connecting the skin to the walls of the passage are some small glands — *glandulæ ceruminosæ* — which secrete the wax or cerumen of the ear, and whose ducts open on the surface; the greater number of these ducts lie about the centre of the meatus.

Glandulæ ceruminosæ.

Arteries.

The *arteries* to the canal are branches from either the external carotid, the temporal, or the internal maxillary artery; and the *nerves* are chiefly from the junction of the auriculo-temporal branch of the fifth with the portio dura; they enter the auditory passage between the cartilage and the bone, and are distributed to the canal. The auricular branch of the pneumo-gastric also supplies it.

Nerves.

Membrana Tympani.

The *membrana tympani* is a transparent membranous septum between the meatus auditorius and cavity of the tympanum, it is rather oval in form, and is attached, by its circumference, to a groove in a ring of bone at the inner extremity of the meatus; it is not suspended vertically between this canal and the tympanum, but obliquely, its outer surface looking downwards and outwards, and forming a much more acute angle with the lower than with the upper wall of the meatus. Towards the auditory canal it presents a concave surface, but it is convex to the tympanum, and retains this position by reason of its union with the handle of the malleus, which is connected to the

upper half of the membrane, and reaches rather below the centre. In the fœtus it is united to the osseous tympanic ring that supports it, and is separate, but is afterwards joined to the rest of the bone. The membrane consists of three different layers or structures; an external layer, epidermic, continuous with the lining of the meatus; an internal, mucous, which is a part of the membrane that lines the cavity of the tympanum, and is prolonged into its interior from the pharynx; and the third or central structure is the proper membrane, which consists of two layers; — an external, thin one, whose fibres radiate from the centre, where they are attached to the handle of the malleus, to the circumference of the membrane, and were described as muscular by Sir Everard Home[1]; and of an inner layer, thicker than the outer, but not so distinctly fibrous, which is united with the external in a circular band, near the circumference of the membrane.

Tympanum. The *tympanum* or middle ear is a circular space, situated in the base of the petrous portion of the temporal bone, behind the glenoid fossa and Eustachian tube, and in front of the mastoid cells, with which it communicates by an aperture, as well as with the pharynx, in front, by means of the Eustachian tube; a chain of small bones crosses the cavity, to convey the undulations of sound to the labyrinth that is internal to it. The shape of the tympanum is circular, or like a segment of a common drum, the outer and inner boundaries being nearly flat, and the antero-posterior measurement, nearly as long again as the one from without inwards, is about half an inch: the cavity presents an outer boundary, an inner boundary, and a circumference to be examined; the *outer boundary* of the space is the membrana tympani, and the ring of bone that projects from the surface of the meatus to receive the attachment of this structure; close to the union of the membrane with its groove, and in the projecting portion of bone, opposite the foramen rotundum of the inner wall, is the small aperture for the chorda tympani to enter the cavity. Above the membrana tympani, and rather in front of it, is the Glasserian or *glenoid fissure*, which receives the short process of the malleus, and allows the laxator tympani to pass through it; the chorda tympani nerve leaves the cavity by an aperture a little internal to the fissure. The *inner boundary* or wall, of greater extent than the external, is also more complicated; it presents in its centre, in the dry bone, a large projection, — the *promontory*, the front of which corresponds to the apex of the cochlea, and its surface is grooved by two or three canals that diverge from a common aperture, below, by which Jacobson's nerve enters the cavity to divide into branches that occupy the grooves. Above the promontory is an aperture — the *fenestra ovalis* — that leads into the labyrinth; but in the recent subject this is closed by the base of the stapes that

Outer Boundary.

Glasserian Fissure.

Inner Boundary.

Promontory.

Fenestra ovalis.

is received into it; this aperture resembles the half segment of a circle, the convexity looking upwards, and it is bounded above by a prominent osseous canal, — the aqueduct of Fallopius: its margins are directed to the cavity of the vestibule. Below the fenestra ovalis, and behind the promontory, is another large aperture, — the *foramen rotundum*, — separated, above, from the fenestra ovalis, only by a thin, narrow process of bone, prolonged backwards from the promontory; this opening resembles very much, in shape, the fenestra ovalis, but its base is almost vertical, instead of horizontal, and a spicula of bone — the lower part of the lamina spiralis — that crosses it, and is concealed rather within the margins, divides the aperture into two parts, — the upper one opening into the vestibule, and the lower into the scala tympani of the cochlea. In the recent state, the foramen is closed by a proper membrane — the *secondary membrane of the tympanum* — which is covered internally by the lining membrane of the vestibule, externally by the mucous membrane of the tympanum, and the aperture is thus closed by a structure that resembles the membrana tympani in having three layers; it is attached also to a groove, as the membrana tympani. At the front of the inner wall, and rather above the promontory, is a projecting thin spicula of bone, — the *processus cochleariformis*, — which is hollowed out above, is about half an inch in length, and is prolonged backwards, separating the canal for the tensor tympani muscle, from the canal for the Eustachian tube. The *circumference* of the cavity is circular, and projects below, and this part, situated over the jugular fossa, is marked by numerous small apertures; above, it is formed by the plate of bone that constitutes the roof of the tympanum; behind and above, it presents a large aperture into the *mastoid cells*, by which the cavity of the tympanum opens into the cellular structure of the mastoid process, and into which is received the short process of the incus. Below this aperture, and rather nearer the inner wall, is the conical projection of the *pyramid*, placed close below the canal of bone of the aqueduct of Fallopius, and perforated by an aperture in the apex for the passage of the stapedius muscle; the apex of this body is on a level with the posterior prolonged part of the promontory, and the canal of the interior is continued downwards and backwards, anterior to the aqueduct of Fallopius, and opens in front of it on the under surface of the bone: the two canals communicate together.* In the anterior part of the circumference are two canals; the upper one is the *canal for the tensor tympani muscle*, and is separated from the lower by the processus cochleariformis; the lower canal is the osseous portion of the

Foramen rotundum, and its Secondary Membrane. Processus Cochleariformis. Circumference. Mastoid Cells. Pyramid. Tensor Tympani Canal.

* The course of this canal of the pyramid has been shown by M. Huguier, Prosecteur de la Faculté, *Anatomie Descriptive*, Cruveilhier, tom. iii. p. 501.

Eustachian Tube.

Eustachian tube which opens into the pharynx, and by it the air in the interior of the tympanum communicates with the atmosphere: this is best seen on the preparation, in which it has been laid open. This tube, about an inch and a half long, is directed downwards and inwards, and is partly osseous, and

Osseous portion.

partly cartilaginous and membranous. Its *osseous portion* commences in the anterior part of the tympanum, runs forwards and downwards in the angle of union of the squamous and petrous portions of the temporal bone, and ends in the cartilaginous portion by a dilated extremity: the centre of this osseous part is narrowest; its length is about half an inch, and it is separated from the canal for the tensor tympani, only by the processus cochleariformis; it is situated to the outer side of the carotid canal, and internal to the glenoid fissure, or between the

Cartilaginous.

two. The *cartilaginous* part of the tube, about an inch long, is wider than the osseous, and is connected, above, to a hollow, seen at the base of the skull, between the outer surface of the petrous portion of the temporal bone, the internal surface of the spinous process of the sphenoid, and the posterior angle of this bone: the relations and anatomy of this part are seen with the pharynx. The interior of the tube is lined by mucous membrane that is continued into it from the pharynx, but this becomes thinner as it ascends, loses the character of the pharyngeal mucous membrane, and finally assumes that of the lining of the tympanum.

Relative Anatomy of the Chain of Bones of the Tympanum.

The chain of bones, that crosses the tympanum, is formed by the articulation of one bone to the other by capsular and synovial membranes, by which they are, individually, free to move, and to communicate to the labyrinth the successive vibrations of the membrane of the tympanum. The most external of these is called malleus, from its resemblance to a hammer; the next is the incus, which resembles an anvil; and the third is named the stapes, since it is very like a stirrup. The relative position of these must be examined, as also the muscles connected to them, before they are removed from their natural position, to see each bone. The *malleus*, situated vertically in the cavity, presents above a rounded head, with an articular surface directed backwards and inwards, to unite with a similar concave surface of the incus, a capsular and synovial membrane being found in the articulation; from the constricted neck of the bone, below the head, diverge two long processes, one vertically, — the handle, — to be connected by its whole length to the membrane of the tympanum, and the other — the long process — passes outwards and forwards to the Glasserian fissure in which it is placed. The tensor tympani, or internal muscle of the malleus, crosses the front of the tympanum, to be connected to the handle of the malleus; another structure — the laxator tympani, or great external muscle of the malleus — is united to

the long process in the Glasserian fissure; and a third muscle — the small external muscle of the malleus — descends, from the margin of bone above the membrana tympani, to the handle of the malleus below the short process; the chorda tympani nerve crosses the inner surface of the handle. The *incus*, situated also vertically, has, above, a thickened part, — the body, — which is free in the cavity of the tympanum, is excavated above, covered with cartilage, and articulated to the malleus; from the lower part diverge two processes; the shorter, but thicker, is directed backwards to the aperture in the mastoid cells, into which it is received, and is connected to the outer wall of the tympanum by a ligament which arises from a depression in this, and is united to the extremity of the process; the other process, the long one, descends like the handle of the malleus into the cavity, but is free except at the extremity by which it is articulated to the stapes: this process is parallel to the handle of the malleus but is nearer the inner wall of the tympanum, and is placed rather more posteriorly than it. On the surface of the long process, in contact with the stapes, is an orbicular portion of bone, — the lenticular process, — which is covered with cartilage, and articulates, by means of a synovial membrane and capsular fibres, with the head of the stapes. The *stapes* is placed, horizontally, one side of the stirrup looking forwards and the other backwards, and the base closes the fenestra rotunda, into the margin of which it is closely fixed by means of a ligament attached to the edges of the base of the stirrup; connected to the head of the stapes, behind, is the stapedius muscle which issues from the pyramid; the outer extremity of the head of the bone is articulated to the process of the incus. A fold of the lining membrane of the cavity closes the aperture in the stirrup.

The *internal muscle of the malleus* or *tensor tympani* * is the largest, and most distinct muscle connected with the chain of bones; it is long and slender in form, and is situated above the Eustachian tube, in the canal of bone which is separated from the tube by the processus cochleariformis. The muscle *arises*, in front, from the inner side of the cartilaginous portion of the Eustachian tube, and from the surface of the canal in which it lies; the fibres pass backwards to a tendon which, at the posterior part of the processus cochleariformis, bends downwards over its thin excavated extremity, as over a pulley, and is then directed backwards and outwards to be *inserted* into the handle of the malleus, rather below its short process, and on the oppo-

Internal Muscle of the Malleus.

Origin.

Insertion.

* The muscles usually described in the best treatises of anatomy are noticed here, and the muscular structure, even, of some of these is doubtful; but Tod, in his treatise on *The Anatomy and Physiology of the Organ of Hearing*, gives many more. This work may be referred to, if it be wished to study more carefully this subject.

Relations. site side of the bone. It is contained in a canal between the Eustachian tube and the hiatus Fallopii, and a branch of nerve from the otic ganglion lies in the same canal, and is distributed to the muscle.

Great External Muscle of the Malleus. The *great external muscle of the malleus* or *laxator tympani*, whose muscular nature is very doubtful, has therefore been named, by some, only a ligament of the long process of the malleus; it is connected externally to the spinous process of the sphenoid bone, it then passes through an aperture in the Glasserian fissure, and is attached to the extremity of the long process of the malleus.

Small External Muscle of the Malleus. The *small external muscle of the malleus*, sometimes described also as a ligament, is placed within the cavity of the tympanum; it is a roundish cord, attached above the membrane of the tympanum to the ring of bone that contains this structure, and then descends to be fixed to the handle of the malleus below the short process that projects, outwardly, from the base or upper part of this portion of the bone.

Stapedius Muscle. Origin. The *stapedius muscle* is also considered, by some, to be a ligament, and it is lodged in the canal in the interior of the pyramid. It *arises* from the circumference of its bony tube; the fibres end in a tendon which leaves the canal, and is directed forwards to be *inserted* into the posterior part of the neck of the stapes. The tendon of this muscle is very strong for its size, and assists in retaining the stapes applied to the fenestra rotunda.

Insertion. Relations.

Dissection. Remove the chain of bones from the cavity of the tympanum, taking the incus away first, and in dislodging the stapes from its aperture, do not pinch it too much with the forceps, or it will be crushed. Examine now the individual processes of the bones.

The Malleus. The *malleus*, the most external bone, resembles a hammer, and is divided into head, neck, and handle, with a long and a short process. The *head*, free in the cavity of the tympanum, is oval in shape, and smooth, except at the inner and posterior part, where a depression is found to articulate with the incus.

Head. Neck. Handle. The *neck* is the narrow constricted part that intervenes between the head and processes, it is slightly twisted. The *handle* or manubrium forms an obtuse angle with the body of the bone, and diminishes in size from above downwards; it is flattened from before backwards, presents an external and an internal ridge, — the membrane of the tympanum being connected to the former; the tip of the handle is also flattened, but in a direction opposite to the greater part of the process. On the outer side of the upper part of the handle, at its junction with the neck of the bone, is a short round projection, — the *short process* (*processus brevis*) which reaches to the membrane of the tympanum, and slightly carries it outwards. The *long process*

Short process.

(*processus gracilis* or *spinosus*) is connected to the anterior part of the neck of the bone, to a slight depression in front of its twisted portion, or from the same surface of the bone as that to which the smooth convex head looks. The process is long and slender, but is flattened at the extremity, it is generally not ossified, and is lodged in the Glasserian fissure; to it is united the structure which is named the great external muscle of the malleus. Long process.

The *incus* is also divided into body and processes; the *body*, larger than that of the malleus, is hollowed out, above, for its articulation with the malleus, and is surrounded by a slight groove to which the capsular ligament is inserted. The bone ends below in two processes; — the posterior or *short process*, conical in shape, and flattened, passes horizontally backwards to be received into the aperture of the mastoid cells; the vertical or *long process*, smaller than the other and round, decreases in size from above downwards; at the extremity it is curved inwards, and the tip ends in a rounded, convex eminence — the *lenticular* — which articulates with the stapes: this articular extremity is occasionally described as a separate bone, with the name of *os orbiculare*. The Incus. Body. Short process. Long process.

The *stapes*, when deprived of the membrane that covers it, is seen to be like a stirrup; and it has a base, two crura, and a head, to be examined. The *base*, a very thin plate of bone, is convex above, and almost flat below, to correspond to the shape of the margins of the fenestra ovalis; that surface that looks to the vestibule is rather convex, but the other is excavated. The *crura* extend from the base to the head, and the anterior is less curved than the posterior; both are grooved on the surfaces that look to the aperture of the stirrup, and this groove is continuous below with the one in the base. The *head* is marked by a superficial depression that receives the prominence of the lenticular process of the incus. The Stapes. Base. Crura. Head.

The cavity of the tympanum is lined by a thin membrane, of the character of a fibro-mucous structure, which projects into the mastoid cells that it lines, and is continued over the chain of bones. It is continuous, below, with the mucous membrane of the pharynx, and secretes, ordinarily, in the tympanum, only sufficient mucus to lubricate the surfaces. Mucous Membrane of the Tympanum.

The *nerves of the tympanum* are, the chorda tympani, and the nerve of Jacobson; and the dissection of these is to be made in a fresh temporal bone softened in diluted hydro-chloric acid; and another, with the ear prepared, is to be made use of at the same time. Nerves of the Tympanum.

It is impossible to dissect the nerve of Jacobson unless on a recent temporal bone softened in acid, and in taking it from a body for this purpose, the part of the occipital bone that bounds behind the foramen lacerum, as well as that which contains the Dissection.

ninth nerve, should be removed with the temporal, in order to have the relations of these nerves, and the first branches of the eighth pair. The chorda tympani has been already dissected, but this may be again repeated by merely cutting away the roof of the tympanum; and its point of origin from the portio dura must be seen after Jacobson's. The nerve of Jacobson will be best found — supposing the foramen lacerum to be entire, and the eighth nerve, that passes through it, in a perfect state — by opening the foramen behind, and taking away the portion of the occipital bone that bounds it in this direction; the glosso-pharyngeal nerve can then be followed through the aperture, the ganglion of Andersh will be seen in the foramen, and the nerve of Jacobson, below this, passing upwards to enter the aperture in the osseous ridge between the carotid canal and foramen lacerum. In following the pneumo-gastric through the foramen, its ganglion will be seen, together with the filaments of union between it and the spinal accessory; and the small nerve — the auricular of Arnold — from the pneumo-gastric, that crosses the jugular fossa to join the portio dura in the aqueduct of Fallopius, is very apparent. When the nerve of Jacobson and the auricular nerve are found, turn round the temporal bone, place the knife on the outer side of the Eustachian tube, but close to it, and carry it directly backwards and outwards through the vaginal and styloid processes, to remove the whole outer wall of the tympanum, but without cutting into the aqueduct of Fallopius, or injuring the portio dura. Seek, again, Jacobson's nerve as it is entering the canal by the foramen in the process of bone before mentioned, and, removing any osseous portion that conceals the nerve, follow it upwards, with great care, into the internal wall of the tympanum, over the promontory; one branch of it turns downwards to the carotid canal, and two run upwards, — one to join the large petrosal nerve, and the other to form the small petrosal. If the glosso-pharyngeal nerve is not left at its passage from the skull, it will be necessary to remove the outer wall of the tympanum, and to seek the nerve below, where it is entering its canal.

Jacobson's Nerve.

Jacobson's nerve, or *nervus tympanicus*, arises from the glosso-pharyngeal nerve, below the petrous ganglion; it then runs upwards and forwards, to enter the canal appropriated to it in a projection of bone between the foramen lacerum jugulare and the carotid canal; by this it is conducted to the lower part of the internal wall of the tympanum, and, on the promontory of this cavity, it divides into three or more branches, which lie, at first, in grooves on the surface of the prominence, before entering their canals or foramina. One of these small filaments passes downwards and forwards, through a short canal, to join the carotid plexus; and two ascend, — one to join the great petrosal or vidian nerve in the hiatus Fallopii; and the other, the *small*

Branch to the Carotid Plexus.

To the Vidian.

petrosal nerve that connects the nerve of Jacobson with the otic ganglion, passes in front of the fenestra ovalis, enters a canal — the *tympanic* of Arnold — which passes beneath the canal of bone for the internal muscle of the malleus, and then runs forwards between the hiatus Fallopii and it, to open on the upper surface of the petrous portion of the temporal bone external to the vidian or great petrosal nerve; the nerve then runs forwards on the petrous portion of the temporal bone, and leaves the skull to join the otic ganglion. Besides these branches, Arnold describes one to the Eustachian tube, one to the fenestra ovalis, and another to the foramen rotundum.

Small Petrosal Nerv.

The *arteries of the tympanum* can be dissected only in a well injected temporal bone. The tympanum is supplied with vessels from the *stylo-mastoid artery*, — a branch of the posterior auricular, which gives twigs to the mastoid cells, stapedius muscle, and tympanum; and one remarkable branch, the *superior tympanic*, to the membrane of the tympanum, on which it anastomoses with the *inferior tympanic*, — a branch of the internal maxillary, which enters by the Glasserian fissure; they form an arterial circle around the circumference of the membrane from which branches converge to the middle line. The cavity receives other small arteries from the *vidian*, — a branch of the middle meningeal, which enters the hiatus, and anastomoses with the stylo-mastoid branch. Other branches come to the cavity along the Eustachian tube, which receives arteries from many sources, viz. from the ascending pharyngeal, from the inferior palatine of the facial, as well as from the middle and small meningeal arteries. The branches of arteries are accompanied by veins.

Arteries of the Tympanum.

Stylo-mastoid

Superior Tympanic.

Inferior Tympanic.

Vidian.

The *auricular branch* of the pneumo-gastric nerve, that was crossing the jugular fossa, can now be followed into the bone; and the portio dura in the lower part of the aqueduct of Fallopius may be dissected by cutting away the bone from the posterior surface. This nerve is given off from the pneumo-gastric below its ganglion in the canal, it crosses the front of the jugular fossa, enters a small canal in its posterior part, near the stylo-mastoid foramen, and, running through part of the bone, enters the aqueduct of Fallopius, to join the portio dura nerve. Arnold describes this nerve as giving downwards a second filament to join the posterior auricular nerve of the facial, and a third outwards to the meatus auditorius externus and auricle.

Auricular Nerve of the Pneumogastric.

The osseous parts of the labyrinth, viz. the vestibule, semicircular canals, and cochlea, are to be exposed after the examination of the cavity of the tympanum and its contents; but to dissect the membranes, and their contained fluids that lie in the centre of its dense osseous structure, requires very great care, and that the bone should be softened in acid. These parts have been made out in the dry bone, if the previous instructions

Dissection.

have been followed; and the vestibule may be now seen in the temporal bone used for the tympanum, by making a vertical cut with a saw, into the substance of its petrous portion, close in front of the prominence of the superior vertical semicircular canal on the upper border; and this should extend into the osseous structure to a level with the fenestra ovalis already exposed by opening the tympanum. This vertical cut may be met by a horizontal one carried back to it from the tip of the bone, and on a level with the upper wall of the meatus auditorius internus: the cavity of the vestibule appears at the posterior part of the incision, and the semicircular canals, which lie behind it, may be followed in the bone by cutting it away with a file or bone forceps. The cochlea will easily be found by removing, afterwards, with the same instruments, a portion of the bone which intervenes between the meatus and the promontory of the tympanum: direct the successive cuts rather obliquely downwards and outwards.

Laby-rinth. The *labyrinth** or *internal ear* is the most fundamental part of the organ of hearing, and it consists of a central space — the vestibule; of accessory semicircular canals which open into this cavity, and are placed behind it; and of a structure—the cochlea —resembling a part of a snail's shell, which is placed in front of the vestibule. These different parts of the labyrinth are called the osseous labyrinth, since one or two membranous bags, filled with fluid, on which the nerves are expanded, are contained within the vestibule and semicircular canals, and are named the membranous labyrinth. There is also a fluid — the liquor Cotunnii — contained in the osseous labyrinth, and in it the membranous labyrinth floats.

Vesti-bule. The *vestibule* is an irregularly-shaped space in the centre of the petrous portion of the temporal bone, in front of the semicircular canals, behind the cochlea and meatus auditorius internus, and internal to the tympanum. The smallest measurement of the space is from the inner to the outer wall, and it is slightly prolonged in three directions, — upwards, downwards and forwards, and downwards and backwards. The *outer wall*, or boundary of the space, is the partition between it and the tympanum, and in it is the fenestra ovalis, whose margins are turned in to the cavity, and into it the stapes is received; below this, in the dry bone, is another small aperture, or the upper portion of the foramen rotundum, which also leads into the tympanum. The *inner wall* is marked by a slight depression —

Outer Wall.

Inner Wall.

* My limits will not permit a very full detail of the anatomy of many parts of the ear; but ample information may be obtained in the elaborate treatise of Breschet, *Recherches Anatomiques et Physiologiques sur l'Organe de l'Ouïe et sur l'Audition, dans l'Homme et les Animaux Vertébrés.* Paris, 1836. As well as in the complete article, "Organ of Hearing," by T. Wharton Jones, in the *Cyclopædia of Anatomy and Physiology.*

the *fossa sulciformis*, and in it is the aperture of the small *aquæductus vestibuli*, which commences near the common opening of the superior and inferior vertical semicircular canals, and then passes through the bone to open on the posterior surface of the petrous portion, behind the meatus internus, and beneath a small plate of bone. The *anterior boundary*, which is contiguous to the meatus and the turns of the cochlea, is perforated, internally, by numerous small apertures for arteries and the filaments of the auditory nerve, which enter the cavity, — the spot being named *macula cribrosa*, and external to this is the aperture of the *scala vestibuli* of the cochlea, which opens into the anterior prolongation of the vestibule. At the under and anterior part of the cavity, internal to the aperture of the cochlea, is a hemispherical depression, — *fovea hemispherica*. At the *posterior part* of the space are the apertures of the three semicircular canals, five only in number, since the two vertical join at one extremity, and open by one orifice. In the *upper wall*, at a point opposite to the fovea hemispherica, is another slight oval depression, — *fovea hemi-elliptica* — but this has been removed in opening the cavity.

Fossa sulciformis. Aqueduct of the Vestibule. Anterior boundary. Macula cribrosa. Fovea hemispherica Posterior boundary. Upper Wall. Fovea hemi-elliptica.

The *semicircular canals* are three somewhat semicircular osseous tubes which are placed behind the vestibule, and are contained in the substance of the petrous portion near its base: they are named from their position; — one is the *superior vertical*, which crosses the bone, and is prominent, on the surface, in its upper border; another is the *inferior* or *posterior vertical*, which diverges backwards from the former towards the posterior surface of the bone, and is placed behind the aqueduct of the vestibule; and the third, the *horizontal* one, is placed transversely across the space left by the divergence of the other two, and is considerably below the level of the superior vertical canal. Each of these canals forms about three fourths of a segment of a circle, and the concavity of each is directed towards the vestibule; it is a hollow tube with its centre narrower than the extremities, and, when cut across, its cavity is of an oval form. There are only five apertures opening into the vestibule from these canals, since the superior and inferior vertical unite together at one end; but three of these five apertures are dilated into an *ampulla* or *ampullary sinus*, there being one for each semicircular canal, and the following is their position in the cavity: — the ampulla of the superior vertical canal is at its outer or free extremity, which opens into the upper part of the vestibule above the fenestra ovalis; the ampulla of the horizontal one is also at its outer termination, near that of the superior vertical, and above the fenestra ovalis; whilst that of the inferior or posterior vertical canal is at the opposite side of the cavity, and at the aperture of its inferior or free extremity, the upper end being joined with the superior vertical canal.

Semicircular Canals. Superior Vertical. Inferior Vertical. Horizontal. Apertures and Ampullæ.

Cochlea. The *cochlea*, named from its resemblance to a snail's shell, is placed transversely between the vestibule, behind, and the carotid canal, in front, — the base of it being directed to the meatus auditorius internus, and the apex to the front of the promontory on the inner wall of the tympanum. This body consists of a central pillar — the modiolus — that passes from the base to the apex of the cochlea, and around this is coiled a tube which is divided by a partition, in its whole length, except at the extremity, into two separate compartments which have received the names of scala tympani and scala vestibuli; the partition between them is the lamina spiralis. The *tube of the cochlea* or the *canalis spiralis cochleæ* is about one inch and a half long, is coiled up so as to describe two turns and a half, and is divided by a partition into two parts or scalæ; it is about a line wide at the base of the cochlea, but gradually diminishes to half that size at the apex, and ends in an arch — the *cupola;* the first turn or coil is much larger than the other, and the second, and the remaining half turn lie within the circle that it describes. The *central pillar* or *modiolus* of the cochlea is the portion of bone included within the coils that the tube of the cochlea makes, and its size will vary according to whether the portion included in the first, second, or in the part of the third be examined; thus, within the first coil it is thick, in the next it is diminished in size, and the half turn, at the apex, is formed by only the one side of the tube of the cochlea which turns sharply round. This disposition of the modiolus will be understood by cutting through the shell of a snail, when, if the last half turn be viewed from the coil next below it, it is seen to be convex and funnel-shaped, but if the other side of a shell be now opened, the same half turn will present a single sharp border; this is the arrangement that the tube presents in the cochlea, and the convex part of the last half turn, which looks to the second coil, and is seen by opening the cochlea from below, is named the *infundibulum;* the free margin of the modiolus will be perceived by opening it from above, and on this the lamina spiralis ends. The outer surface is marked by a double spiral groove, and by many apertures, and through the centre of the modiolus runs one large canal — the *central tube* of the modiolus; and other smaller foramina, seen in the base of the cochlea, which occupies the lower part of the meatus auditorius internus, are also for branches of nerves and vessels which ascend to be distributed on the lamina spiralis. The *lamina spiralis* is a thin process of bone which extends only half way across the spiral tube of the cochlea in the dry bone, but, in the recent, the remaining part is supplied by the lining membrane of the cochlea, and the tube is thus divided into two distinct portions or scalæ of the cochlea; one, the *scala tympani*, opens into the tympanum through the foramen rotundum, and the other, the

Tube of the Cochlea.

Cupola.

Modiolus.

Infundibulum.

Central Tube.

Lamina spiralis.

Scala Tympani.

scala vestibuli, into the vestibule near the fenestra ovalis. The spiral lamina commences, below, at the base of the cochlea by a process of bone interposed between the apertures of the two scalæ, and opposite to the foramen rotundum, it then ascends, diminishing in size, by turns round the modiolus, to its upper part, and ends in a curved sharp point — the *hamulus* — which is connected to the free margin of the last half turn of the tube of the cochlea; but between it and the margin of this turn is an aperture — the *helicotrema** — by which one scala communicates with the other. This lamina consists of two plates of bone, between which are numerous grooves, continuous with those of the modiolus, in which the nerves run; at the attachment to the modiolus, the laminæ are separated from each other by a widened part — the *spiral canal* of the modiolus, and, at the free margin which projects into the tube of the cochlea, they are united together.

Scala Vestibuli. Hamulus. Helicotrema. Spiral Canal.

The *aqueduct of the cochlea* is a small canal, about a quarter of an inch long, that commences in the lower part of the scala tympani near its point of termination at the foramen rotundum; it is then directed downwards and inwards, through the substance of the bone, to open on the inferior surface of the petrous portion, in front of the jugular fossa, and in the bottom of a depression which lodges the petrous ganglion.

Aqueduct of the Cochlea.

The labyrinth is lined by a proper membrane, in which is contained the fluid of Cotunnius, and immersed in this is the membranous labyrinth to be afterwards seen: these, and their nerves and vessels can be exposed only in the fœtus, or in a bone softened with acid.

The *lining membrane of the labyrinth* is a serous or fibro-serous membrane, which is closely united to the walls of the osseous labyrinth, and extends backwards from the vestibule to the semicircular canals; it enters the cochlea, and gives two distinct tubes to line the two scalæ. The membrane contains a fluid — the *liquor Cotunnii* or *perilymph* — which occupies the parts of the vestibule, and semicircular canals not filled by the membranous labyrinth which is immersed in it; and it enters also the scalæ of the cochlea. It has been supposed by Breschet to be, originally, a prolongation of the dura mater which is then surrounded by bone, the only remnant of connection between the two being by means of the aqueducts which are lined by a thin membrane.† When the membrane of the vestibule is followed into the cochlea, it is seen to send two prolongations into the scalæ, which are separated, near the modiolus, by the presence of the lamina spiralis, but, external to this, they are applied to each other, and complete the partition between the two scalæ by means of a membranous septum which extends

Lining Membrane of the Labyrinth. Perilymph.

* (Ἕλιξ, twisted, τρῆμα, aperture). Breschet, *Recherches Anatomiques*, &c.

† *Recherches Anatomiques et Physiologiques*, p. 84.

from the margin of the lamina spiralis to the side of the tube; so that the partition between the scalæ, in the recent temporal bone, consists of an osseous portion — the lamina spiralis, and of a membranous part formed by the union of the sides of the two tubes that line the scalæ. In the recent cochlea the scalæ differ in length and size, for the scala tympani rather projects beyond the scala vestibuli, below, and is slightly larger than it; but, in the upper part of the cochlea, the scala tympani ends, at the helicotrema, by joining the scala vestibuli which then continues upwards into the cupola. The scalæ are filled with the perilymph which enters them from the cavity of the vestibule, and the fluid of one scala is continuous with that of the other by the helicotrema.

Membranous Labyrinth. The *membranous labyrinth*, the part more immediately concerned in the production of sensations by the impressions of sound, consists of membranous sacs which are situated within the vestibule and semicircular canals, and contain a fluid in their interior; and on the inner surface of these the branches of the auditory nerve are expanded. The sacs are, the saccule, and the common sinus which has prolongations from it to the semicircular canals.

Common Sinus. The *common sinus* is a small sac situated at the posterior part of the vestibule, and the shape of it, in some measure, resembles the cavity, though it does not exactly fill it, since the perilymph intervenes between it and the walls. The prolongations that pass from it to the semicircular canals are smaller than the osseous tubes, and are surrounded by the fluid of the perilymph; they are dilated into ampullary portions — *membranous ampullæ* — in the three ampullæ of the semicircular tubes. The *saccule* is a small transparent sac contained in the hemispherical depression of the vestibule, and situated in front of the common sinus, with which it is doubtful whether it communicates. The membranous labyrinth consists of a transparent membranous layer, within which is a nervous expansion, and external to this a vascular layer. In the interior of the common sinus, in its tubular prolongations, and in the saccule, is a clear and transparent fluid — the *endolymph* or *vitreous humour* of the ear; and in it is found a calcareous substance, which Breschet proposes to call otoconia*; there is generally one mass for the common sinus and one for the saccule; and the nervous filaments join these parts where the masses occur.

Membranous Tubes and Ampullæ. Saccule. Endolymph.

Dissection. The portio mollis nerve, which supplies the cochlea, semicircular canals, and vestibule, may be followed into these parts by cutting away the bone, so as to lay open the meatus internus and the labyrinth. This is to be done on the portion of bone on which the nerves of the tympanum were dissected.

* From *οὖς*, the ear, and *κόνις*, powder. See Breschet, op. cit. p. 72.

The *portio mollis,* or auditory nerve, enters the meatus auditorius internus with the portio dura, and the two are united by one or two filaments in the bottom of the meatus; the nerves then separate, the portio dura enters the aqueduct of Fallopius, and the portio mollis divides into an anterior branch for the cochlea, and a posterior, for the membranous labyrinth. The *anterior* branch divides, at the base of the cochlea, into many nerves which enter the numerous foramina in the base of the modiolus, the trunk entering the central aperture in this process. The filaments from the nerve pass outwards at right angles, those to the lower part of the lamina spiralis being the most external, and those to the upper portion, filaments from the inner branches and central continuation of the nerve. They all pass through the apertures in the modiolus, enter between the layers of the lamina spiralis, and terminate, at its free border, between the layers of the membranous portion of the partition between the scalæ of the cochlea. The *posterior branch* for the membranous labyrinth divides into three nerves; — the upper one, the largest, lies in the depression in the meatus auditorius, close behind the aqueduct of Fallopius for the portio dura, and divides into branches which enter the vestibule by the foramina in this part, and are distributed by three fasciculi; one, to the common sinus of the membranous labyrinth, and the other two, to the membranous ampullæ of the superior vertical and the horizontal semicircular canals; the middle nerve, still smaller, enters the vestibule by the foramina in the posterior part of the meatus, and are distributed to the saccule; and the lower nerve, the smallest, passes through a perforated spot near the ampulla of the inferior vertical semicircular canal, and is distributed to the membranous ampulla of this canal. The filaments of the nerves to the common sinus and saccule expand in a fan-like form on the outer surface of the membrane, and then perforate it to end in a nervous layer on the inner surface; but, on the membranous ampullæ, the nerve, as shown by Steifensands *, is at first forked, and embraces about a third of the circumference of the dilatation; it then enters a sulcus which projects transversely into the ampulla so as to divide it into two parts, perforates the coat, and ends in an expansion on the inner surface of the membranous tube near the ampulla.

Nerves. Portio mollis. Anterior branch. Posterior branch.

The arteries to the internal ear require to be carefully injected before they can be seen; they are, chiefly, from the branch to the meatus internus, and sometimes there is a small artery from the stylo-mastoid, of the posterior auricular, to the horizontal semicircular canal. The *artery to the meatus internus* divides into a branch to the cochlea, and one to the vestibule. The *branch to the cochlea* gives off small arteries that enter the aper-

Arteries. Artery of the Meatus. Branch to the Cochlea.

* See *Cyclopædia of Anatomy and Physiology*, article "Organ of Hearing."

tures in the base of the cochlea, and a larger one is found in the central aperture of the modiolus: small branches pass from these by the openings of the modiolus, to the lamina spiralis, on which they anastomose, forming an arch, from which parallel branches run outwards to unite in a second anastomotic arch at the extremity of the lamina, and from these, the small capillary branches are given to the membrane of the scalæ. The *branch to the vestibule* divides to supply the osseous and membranous labyrinths, and the small arteries form a plexus on the membranous ampullæ, from which branches run along the tubes and canals.

Branch to the Vestibule.

A small *vein* accompanies the artery, and receives the blood from the same parts that the artery supplies: it opens into the superior petrosal sinus.

Vein of the Meatus.

TABLE OF THE ARTERIES OF THE HEAD AND NECK.

- Arch of the aorta *gives off to the neck,*
  - 1. Brachio-cephalic
    - 1. Common carotid
      - 1. External carotid
        - 1. Superior thyroid
          - Hyoid branch
          - laryngeal
          - thyroid
          - muscular.
        - 2. lingual
          - Hyoid branch
          - dorsalis linguæ
          - sublingual
          - ranine.
        - 3. facial
          - Inferior palatine branch
          - tonsillitic
          - glandular
          - submental
          - inferior labial
          - inferior coronary
          - superior coronary
          - masseteric
          - lateral nasal
          - angular.
        - 4. muscular
        - 5. occipital
          - Meningeal branch
          - cervical.
        - 6. posterior auricular
          - Stylo-mastoid branch
          - auricular
          - mastoid.
        - 7. ascending pharyngeal
          - Pharyngeal branches
          - meningeal.
        - 8. temporal
          - Transverse facial
          - anterior temporal
          - posterior temporal
          - middle temporal
          - auricular
          - parotid
          - articular.
        - 9. internal maxillary
          - Inferior dental
          - middle meningeal
          - deep temporal
          - masseteric
          - buccal
          - pterygoid
          - superior dental
          - infra-orbital
          - spheno-palatine
          - superior palatine
          - vidian
          - pterygo-palatine.
        - 10. parotid.
      - 2. internal carotid
        - 1. Arteriæ receptaculi
        - 2. ophthalmic
          - Lachrymal
          - supra-orbital
          - centralis retinæ
          - ciliary
          - muscular
          - ethmoidal
          - palpebral
          - frontal
          - nasal.
        - 3. anterior cerebral
        - 4. anterior communicating
        - 5. middle cerebral
        - 6. posterior communicating
        - 7. choroid.
    - 2. subclavian
      - 1. Vertebral
        - Anterior spinal
        - posterior spinal
        - inferior cerebellar
        - posterior meningeal
        - anterior inferior cerebellar
        - superior cerebellar
        - posterior cerebral.
      - 2. internal mammary
        - Anterior intercostal
        - mediastinal
        - comes nervi phrenici
        - musculo-phrenic
        - abdominal.
      - 3. thyroid axis
        - Inferior thyroid
        - cervicalis ascendens
        - transversalis humeri
          - Supra-acromial
          - supra-spinal
          - infra-spinal.
        - transversalis colli
          - Superficial cervical
          - posterior scapular.
      - 4. deep cervical
      - 5. superior intercostal.
  - 2. left common carotid
  - 3. left subclavian

} The branches of these two vessels are the same as in the table above.

TABLE OF THE VEINS OF THE HEAD AND NECK.

- The superior vena cava *is joined by the following veins from the head and neck* -
  - Brachio-cephalic of both sides*
    - Internal jugular -
      - 1. Lateral sinus -
        - Superior longitudinal sinus
        - inferior longitudinal sinus
        - straight sinus
        - occipital sinuses
        - ophthalmic vein
        - superior petrosal
        - inferior petrosal.
      - 2. ascending pharyngeal -
        - Meningeal branches
        - pharyngeal.
      - 3. lingual -
        - Superficial dorsal
        - lingual
        - ranine.
      - 4. facial -
        - Frontal or angular
        - inferior palpebral
        - dorsal and lateral nasal veins
        - alveolar -
          - Alveolar branches
          - infra-orbital
          - superior palatine
          - spheno-palatine
          - vidian.
        - coronary superior and inferior
        - buccal
        - masseteric
        - submental
        - inferior palatine
        - tonsillitic
        - glandular.
      - 5. occipital -
        - Mastoid vein
        - cervical.
      - 6. superior thyroid -
        - Thyroid
        - laryngeal.
      - 7. middle thyroid.
    - subclavian -
      - 1. External jugular -
        - 1. Internal maxillary
          - Middle meningeal
          - inferior dental
          - deep temporal
          - pterygoid
          - masseteric
          - parotid
          - anterior auricular
          - transverse facial.
        - 2. temporal -
          - Anterior
          - posterior
          - middle or deep.
        - 3. posterior auricular
          - Auricular
          - stylo-mastoid.
        - 4. branch to the internal jugular
        - 5. transversalis humeri
        - 6. transversalis colli.
      - 2. anterior jugular
      - 3. superior intercostal of the right side.

* The brachio-cephalic receives the -

1. Vertebral -
   - Intra-spinal
   - ascending cervical
   - branches from the deep cervical.
2. deep cervical
3. internal mammary of the left and often right side
4. inferior thyroid
5. superior intercostal of the left side (*sometimes*).

TABLE OF THE CRANIAL NERVES OF THE HEAD AND NECK.

1. First nerve or olfactory - Filaments to the nose.
2. Second nerve or optic - To the retina of the eye.
3. Third nerve or motor oculi - To the muscles of the orbit.
4. Fourth nerve or trochleator - To the superior oblique in the orbit.
5. Fifth nerve or trifacial
   - Ophthalmic
     - Lachrymal - Lachrymal, palpebral, communicating.
     - frontal - Supra-orbital, supra-trochlear.
     - nasal - To lenticular ganglion, ciliary nerves, nasal, infra-trochlear.
   - superior maxillary
     - Orbital branch - Malar, temporal.
     - branches with Meckel's ganglion, posterior dental, anterior dental, infra-orbital.
   - inferior maxillary
     - Superior division - Deep temporal, masseteric, buccal, pterygoid.
     - inferior division
       - Auriculo-temporal - Temporal, auricular.
       - gustatory - Branches to mucous membrane, to sub-maxillary ganglion, to hypoglossal, to the tongue.
       - inferior dental - Mylo-hyoid, mental, incisor.
6. Sixth nerve or abducens - To the external rectus muscle of the orbit.
7. Seventh nerve
   - Portio dura*
     - Cervico-facial - Temporal, malar, infra-orbital.
     - temporo-facial - Buccal, supra-maxillary, infra-maxillary.
   - portio mollis
     - to join the portio dura
     - the nerve to the cochlea
     - The nerve to the vestibule - To the common sinus, and ampullæ of the semicircular canals, to the saccule, to the ampulla of the inferior semicircular canal.

---

* Before these divisions, the portio dura gives off - Chorda tympani, posterior auricular, digastric branch, stylo-hyoid branch.

- 8. Eighth nerve
  - Glosso-pharyngeal
    - Jacobson's nerve
    - nerve to the portio dura
    - to the pneumo-gastric
    - to digastric and styloid muscles
    - to carotid artery
    - to the pharynx
    - tonsillitic branches
    - lingual.
  - pneumo-gastric
    - To the spinal accessory
    - auricular nerve
    - nerve to the hypoglossal
    - to the sympathetic
    - to the spinal accessory
    - to the glosso-pharyngeal
    - pharyngeal nerve
    - superior laryngeal
      - External laryngeal
      - to arytænoid muscle
      - ascending } to the mucous
      - descending } membrane.
      - nerve to join the inferior laryngeal.
    - cardiac nerves
    - inferior laryngeal
      - Cardiac
      - œsophageal and tracheal
      - to inferior constrictor and muscles of the larynx
      - to join superior laryngeal.
  - spinal accessory
    - To the pneumo-gastric
    - to the cervical plexus
    - to sterno-mastoid and trapezius.
- 9. Ninth nerve or hypoglossal
  - To the pneumo-gastric nerve
  - to the sympathetic
  - to the loop of the atlas
  - descendens noni nerve
  - thyro-hyoid nerve
  - branches to the gustatory nerve
  - to the hyo-glossus, and stylo-glossus muscles, and to the tongue.

TABLE OF THE SPINAL AND SYMPATHETIC NERVES OF THE HEAD AND NECK.

- The cervical spinal nerves divide into
  - Anterior branches
    - The CERVICAL PLEXUS, formed by the anterior branches of the four first cervical nerves, gives off
      - Superficial ascending
        - Small occipital nerve
        - great auricular
        - superficial cervical.
      - superficial descending
        - Supra-acromial branches
        - supra-clavicular
        - supra-sternal.
      - deep internal
        - Phrenic
        - nerves to the descendens noni
        - to the pneumo-gastric
        - to the hypoglossal
        - to the sympathetic and rectus major muscle.
      - deep external
        - To join the spinal accessory
        - to the sterno-mastoid
        - to the trapezius
        - to the levator anguli scapulæ.
    - The BRACHIAL PLEXUS, formed by the anterior branches of the four last cervical and first dorsal, gives off
      - Branches above the clavicle
        - The rhomboid nerve
        - nerve to the phrenic
        - supra-scapular nerve
        - subclavian branch
        - posterior thoracic or respiratory
        - to the scaleni muscles.
      - branches below
        - Are dissected with the upper extremity.
  - posterior branches
    - Are generally distributed to the muscles, and give off cutaneous nerves; but the three or four first unite in the POSTERIOR CERVICAL PLEXUS.

The ganglionic or sympathetic nerves consist of

1. Superior cervical ganglion -
   - Ascending branches to unite in the -
     - Carotid plexus, which gives off -
       - Branch to Jacobson's nerve
       - to the vidian
       - to the sixth cranial nerve
     - cavernous ganglion, which gives off -
       - to the third cranial nerve
       - to the fifth and lenticular ganglion
       - to the carotid artery and branches, and these form the ganglion Ribes.
   - descending branches - To the middle ganglion.
   - external branches - To the spinal nerves.
   - internal branches -
     - Pharyngeal
     - superficial cardiac nerve.
     - Nervi molles
   - anterior branches - branches to join the pneumo-gastric and hypoglossal nerves.

2. Middle cervical ganglion -
   - External branches - To the spinal nerves.
   - internal -
     - Middle cardiac nerve
     - to join the external laryngeal.
   - inferior - To the inferior ganglion.

3. Inferior cervical ganglion -
   - Ascending branches - To upper ganglion.
   - descending - To first thoracic ganglion.
   - anterior - Branches to the subclavian.
   - external -
     - To the spinal nerves
     - to form vertebral plexus.
   - internal - Inferior cardiac nerve.

4. Meckel's ganglion -
   - Internal branches - Spheno-palatine
     - naso-palatine.
   - ascending - To join the superior maxillary nerve
   - descending - Anterior / middle / posterior - palatine.
   - posterior - Vidian - Carotid branch
     - large petrosal nerve.

5. Ophthalmic or lenticular ganglion -
   - Posterior branches - To nasal of the fifth nerve
     - to the third nerve.
   - anterior - Ciliary nerves.

6. Sub-maxillary ganglion -
   - Superior branches - To the gustatory nerve.
   - inferior - To the gland.
   - anterior - To the mucous membrane of the mouth.

7. Otic ganglion -
   - Superior branches - Small petrosal, to Jacobson's nerve
     - nerve to the tensor tympani.
   - external - To the fifth and sympathetic nerves.
   - anterior - To the tensor palati muscle.

TABLE OF THE ACTIONS OF THE MUSCLES OF THE HEAD AND NECK.*

THE HEAD IS MOVED

forwards by the	*backwards by*	*to either side by the*
Platysma myoides	Part of the trapezius	Platysma myoides
Sterno-mastoideus	Splenius capitis	Sterno-mastoideus
Rectus anticus major	Complexus	Part of the trapezius
Rectus anticus minor.	Trachelo-mastoideus	Splenius capitis
	Rectus posticus major	Splenius colli
assisted (when the lower jaw is fixed) by the	Rectus posticus minor	Trachelo-mastoideus
Mylo-hyoideus	Obliquus capitis superior.	Complexus.
Genio-hyoideus		
Digastrici.		

THE NECK IS MOVED

forwards by the	*backwards by*	*laterally by the*
Platysma myoides	Part of the trapezius	Various combinations of those muscles which separately move it forwards and backwards; assisted by the
Sterno-cleido-mastoideus	Rhomboideus minor	Scaleni
Digastricus	Serratus posticus superior	Inter-transversales
Mylo-hyoideus	Splenius capitis	Recti laterales.
Genio-hyoideus	Splenius colli	
Genio-hyo-glossus	Complexus	
Omo-hyoidei	Trachelo-mastoideus	
Sterno-hyoidei	Transversales colli	
Thyro-hyoidei	Inter-spinales colli	
Rectus anticus minor	Semi-spinales colli	
Longus colli.	Rectus posticus major	
	Rectus posticus minor	
	Obliquus capitis superior	
	Obliquus capitis inferior	
	Scaleni postici	
	Levator scapulæ.	

* The portion of this table including the motions of the head and neck is copied from Quain's Anatomy.

THE APERTURE OF THE MOUTH IS

closed by the
Orbicularis oris
and contraction of the
Buccinatores
Depressores labii superioris
Elevatores labii inferioris.

opened by
The relaxation of the orbicularis and buccinatores
Elevatores labii superioris
Elevatores labii superioris alæque nasi
Depressores labii inferioris.

enlarged by the
Levator anguli oris
Depressor anguli oris
Zygomatici
Buccinatores.

THE LOWER JAW IS MOVED

upwards by the
Masseterici
Temporales
Pterygoidei interni.

downwards by the
Digastrici
Mylo-hyoidei
Genio-hyoidei
Genio-hyo-glossi.

laterally by the
Pterygoidei externi
Pterygoidei interni.

THE BALL OF THE EYE IS MOVED

upwards by the
Rectus superior.

downwards by the
Rectus inferior.

inwards by the
Rectus internus.

outwards by the
Rectus externus.

circularly by the
Obliquus superior, *which rolls the ball downwards and inwards, and by the* Obliquus inferior, *downwards and outwards.*

THE GLOTTIS OF THE LARYNX IS

enlarged at the base by
Crico-arytænoidei postici
Crico-arytænoidei laterales.

contracted at the base by
Arytænoideus.

shortened from before by
Thyro-arytænoidei
Crico-arytænoidei laterales

elongated from before by
Crico-thyroidei.

THE SOFT PALATE IS MOVED

upwards by the
Levatores palati.

downwards by the
Palato-glossi
Palato-pharyngei
and contraction of the
Constrictors.

and made tense by the
Tensores palati.

THE LARYNX AND OS HYOIDES ARE MOVED

upwards by the
Digastrici
Stylo-hyoidei
Stylo-glossi
Stylo-pharyngei
Mylo-hyoidei
Genio-hyoidei
Hyo-glossi
Genio-hyo-glossi
Linguales, *when the tongue is fixed.*

downwards by the
Omo-hyoidei
Sterno-hyoidei
Sterno-thyroidei
Thyro-hyoidei.

THE SCALP IS MOVED

forwards by the
Anterior belly of occipito-frontalis
Pyramidales nasi.

backwards by the
Posterior belly of occipito-frontalis.

THE EYELIDS ARE

closed by the
Orbicularis palpebrarum
Corrugator supercilii.

opened by the
Levator palpebræ superioris
Relaxation of the orbicularis.

The tensor tarsi compresses the lachrymal canals.

THE PHARYNX

is diminished by
The *contraction of the* constrictors.

enlarged by
The *retaxation of the* constrictors
Stylo-pharyngei.

THE TONGUE IS

protruded by the
Genio-hyo-glossi, which make it concave along the middle.

retracted by the
Genio-hyo-glossi
Stylo-glossi
Linguales, *when the os hyoides is fixed.*

THE EAR IS MOVED

forwards by the
Attollens aurem
Attrahens aurem.

backwards by the
Retrahens aurem.

THE APERTURE OF THE NOSE IS

dilated by
Levator labii superioris alæque nasi.

diminished by
Compressor nasi
Depressor labii superioris alæque nasi.

THE MEMBRANA TYMPANI IS

rendered tense by the
Tensor tympani.

relaxed by the
Large external muscle of the malleus
Small external muscle of the malleus.

The stapedius muscle fixes the stapes.

DISSECTION OF THE UPPER EXTREMITY.

The surface of the thorax, as well as the exterior of the upper extremity, have numerous superficial depressions and prominences of bone and muscle, required to be recognised with certainty and facility by the surgeon, which should be examined before the dissection is begun. On the front of the chest is the mamma, which is very large in many females, so as to overlap the lower border of the pectoral muscle, and encroach on the axillary space. The anterior fold of the armpit is formed by the pectoral muscle, which is separated from the deltoid, parallel to its outer border, by a slight linear depression, and in this is the coracoid process of the scapula, close below the clavicle, and to the inner side of the articulation of the humerus. Another depression extends from the sternal extremity of the clavicle, in the line of separation between the two portions of this muscle, and it is placed over the course of the axillary artery. Between the arm and chest is the hollow of the axilla, which contains the axillary vessels and nerves, and is bounded, before, by the pectoral muscle forming the anterior fold, and behind, by the latissimus dorsi, and teres muscles, which are inclosed in the integuments of the posterior fold. Its size as well as depth will vary according to the development of the anterior and posterior folds, but the hollow of the space may be altered by the position of the arm to the trunk; thus, when the arm is rotated outwards and removed to nearly a right angle, the depth is greatest; and it is diminished in proportion as the arm is carried upwards, since the head of the humerus then descends into the space, and the folds are overstretched. On the side of the arm this space is divided into two by the slight prominence of the coraco-brachialis muscle, — the posterior portion, the largest, contains the axillary vessels and nerves, close to the border of the muscle. If the fingers be introduced into the axilla, and the arm rotated and moved about in different directions, the head of the humerus will be felt. The skin of the axilla is of a dark colour, and provided with hairs. The shoulder is prominent, in consequence of the projection of an arch, formed, internally, by the clavicle that reaches from the chest, and, externally, by the acromion process which commences in a narrow eminence on the back of the scapula. The convexity below this is occasioned by the head of the humerus covered by the deltoid muscle. Along the front of the arm, and somewhat on the inner side, is the prominence of the biceps muscle, and on each side of it a groove — the internal, most marked, points out the position of the brachial vessels:

these subside, below, in a depression in front of the elbow. Semiflex the elbow joint, and the prominences of the external or epicondyle on the outer side, and of the internal condyle or epitrochlea on the inner, will be rendered evident: the latter eminence is the most marked. At the back of the articulation is the prominent olecranon, situated rather nearer the inside than the outside of the arm, and best perceived when the arm is flexed. Below the epicondyle is the prominence of the head of the radius, separated from the lower extremity of the humerus by a slight interval; the position of this portion of bone is recognised by rotating the radius, the fingers being, at the same time, placed over it. In the front of the forearm the depression on the radial side points out the position of the radial artery, and a similar one on the ulnar side, the course of the ulnar artery. The bones of the forearm are sufficiently near the surface to be traced from one extremity to the other; each ends below in a styloid process, or a projection on the side of the wrist joint for the attachment of the lateral ligaments; the outer, or that from the radius, projects lower than the inner. The line of union of the lower end of the radius with the first row of carpal bones, to form the wrist joint, is behind the styloid process, and distant, in the centre of the arm, about an inch from the transverse grooves of the wrist. When the thumb is placed almost at right angles to the hand, a line drawn from it, across the palm, nearly marks the position of the superficial palmar arch of arteries. Two transverse lines cross the palm of the hand, and when the fingers are extended, the metatarso-phalangeal articulations are about a quarter of an inch in front of the anterior one. The transverse lines on the fingers serve to direct to the articulations between the phalanges, the ungual phalanx and the next being united about one line in front of the corresponding mark; and the second and third, about a line in front of the last of the transverse lines over this articulation.

Dissection. The thorax being raised to a convenient height by a block beneath it, let the arm hang over the side of the table, and place it, slightly rotated outwards, in the position of nearly a right angle to the trunk. To begin the dissection, divide the integuments* along the lower border of the pectoral muscle, from the xiphoid cartilage of the sternum to the anterior part of the humerus, carrying the scalpel around the projection of the mammary gland in the female; make a second incision along the middle line from the xiphoid cartilage to the sternal extremity of the clavicle, continue it along this bone to its centre, and then along the depression extending down thence between the pectoral and deltoid muscles, until it nearly joins the one

* All incisions through the skin are not to extend deeper than this, if it be wished to dissect the cutaneous nerves and vessels.

already made along the lower border of the pectoral; in dividing the skin over the clavicle, be careful of the cutaneous nerves that descend over it. Raise the skin from the surface marked out by these lines, without injuring the thin platysma muscle near the clavicle; reflect next, by means of a vertical incision from the sternum to the posterior fold of the axilla, the portion of integument, covering the side of the chest and the axillary space, to a level with its posterior boundary, and seek the cutaneous nerves in the superficial fascia; some of these, from the cervical plexus, pass over the clavicle; some appear at the side of the sternum, from each intercostal space; and the others, also from the intercostal nerves, are found along the side of the chest, about one inch beneath the anterior fold of the axilla or the lower border of the pectoral muscle, and they send filaments forwards, over this border, to the front of the muscle, as well as backwards to the integuments of the posterior part of the scapula and arm.

Fascia of the Axilla.

Beneath the cellular membrane, which is not very abundant, is a deeper fascia that closely invests the muscles, and, in the interval between the anterior and posterior folds of the axilla, is continued across this space. The fascia of this part is of considerable strength in some subjects, and closes the axillary space on this side; it is fixed to the anterior and posterior folds, by dividing to enclose the muscles; externally it is continuous with the deep fascia of the arm, and it becomes thin on the side of the chest; some cutaneous nerves and vessels perforate it. If an incision be made into it, and the finger introduced through the aperture, the dissector will perceive the loose cellular structure which occupies, for the most part, the axilla. This fascia may be removed from the border of the pectoral muscle, to dissect, more readily, the cutaneous nerves of the intercostals.

Cutaneous Nerves of the Cervical Plexus.

Sternal.

Clavicular.

The *cutaneous nerves* of the cervical plexus, distributed to the integuments over the pectoral muscle, pass over the clavicle at different parts of this bone,—the descending cutaneous branches of the plexus, from which they are offsets, having divided above the clavicle. The most internal nerves, named *sternal*, consisting of one or two small branches, cross the clavicle near its sternal extremity, and are distributed to the integuments over the upper and inner part of the pectoral muscle; they do not extend far below the clavicle. The *clavicular*, three or four in number, and larger than the preceding, cross the centre of the clavicle, one large branch lying on the prominence of this bone, and another passing over it near the interval between the pectoral and the deltoid muscle; some of these can be followed, after supplying the integuments below the clavicle, almost to the lower border of the muscle, and to the mamma. Near the lower part of the anterior fold of the axilla, some of their filaments are directed

upwards and inwards, towards the sternum, to join the cutaneous filaments of the intercostal nerves.

Cutaneous of the Intercostal.

The intercostal nerves, or anterior branches of the dorsal, in their course from the spine to the middle line, give off the middle intercostal cutaneous branches, seen along the side of the chest, and terminate at the sternum in small cutaneous nerves — the anterior intercostal cutaneous. The *anterior intercostal cutaneous* nerves are branches which perforate the pectoral muscle, and each is distributed by a small internal filament to the front of the sternum; and by a long, slender, external filament, which is directed outwards and downwards, over the surface of the muscle, for two thirds of its breadth, and either joins the branches of the cervical plexus, or is distributed to the integuments and mamma. The first intercostal cutaneous is only a small single filament; the external branches of the second and third, join the nerves of the cervical plexus, and those of the fourth, fifth, and sixth, supply the mamma; the seventh is distributed, as the others, to the integuments: these are accompanied by small cutaneous arteries and veins, which are derived from the intercostal vessels, and have the same distribution as the nerves. The *middle intercostal cutaneous* nerves, also branches of the intercostal, leave the trunk of the nerve about midway between the spine and sternum, and their points of emergence, along the side of the chest, form a semilunar line, which rises from the third space to about the sixth, and then gradually descends to the eleventh. The number of branches, now dissected, are usually six or seven, the first intercostal not giving one, and they become cutaneous by passing from beneath the digitations of the serratus muscle: each nerve then divides into an anterior and a posterior branch; the anterior turns over the border of the pectoral muscle, and is distributed to the integuments over it, or to the mamma. The anterior branches of the third, fourth, and fifth intercostal are the largest, and supply the mamma; but the second and third cutaneous nerves are not now seen, since they are in the axillary space, and will be dissected with it. The posterior branches are directed backwards, along the side of the chest, to supply the integument of the arm, and that over the scapula and latissimus dorsi; the branches of the two upper, distributed to the arm, are larger than the others, and are called intercosto-humeral nerves: these lie in the axillary space.

Anterior Intercostal Cutaneous.

Middle Intercostal Cutaneous.

Dissection.

Remove the fascia or aponeurosis of the axilla, without cutting the intercosto-humeral nerves which come from the middle intercostal cutaneous to supply the arm; some filaments of these nerves perforate the fascia, together with one or two small branches of arteries. Clean away the cellular membrane from the axillary space, to expose the vessels and nerves contained in it; this is a difficult task for the young dissector to accomplish, since it is so interwoven with small vessels, nerves,

and lymphatic glands. The dissection may be commenced on the side of the chest, where no vessels are found, but, in the part next the humerus, the large axillary vessels and nerves are to be avoided; along the posterior wall is a small artery, the subscapular with some accompanying nerves, and under cover of the anterior fold is found another branch — the long thoracic. Some of the glands should be left with the small vessels and ducts, that are connected to them. Dissect off the fascia from the posterior boundary, and follow forwards the latissimus and teres muscles to their insertion into the humerus, by making an incision, of about two inches in length, from the lower border of the pectoral muscle, and along the inner side of the arm.

The *axillary space*, now exposed, is seen to be a somewhat conical interval between the arm and chest, the base of the cone being below, and closed by the fascia, and the apex above, between the first rib on the inner side, the superior costa of the scapula externally, and the clavicle and subclavius muscle in front; the base of the cone is wide next the chest, but narrow and pointed at the arm. The anterior boundary is formed by the portions of the pectoral muscles, which intervene between their outer and inner attachments, the pectoralis major extending over the whole front of the space, and reaching as high as the clavicle, but the minor, a narrow muscle, assists to form only its central part; near the thorax, the pectoralis minor projects below the major; beneath the lower border of this, the anterior fold, is the long thoracic artery, continued to the side of the chest, and it is accompanied by its vein. The posterior boundary or fold is formed, below, by the portions of the latissimus dorsi and teres major muscles, which are free in their extent between the thorax and arm, and above this, by the subscapular muscle; the teres is placed behind the latissimus near the chest, but, at its attachment to the humerus, it projects lower than the latissimus, and comes into contact with the axillary vessels. The lower border of this fold is much anterior to the upper portion formed by the subscapularis, since the latissimus projects forwards to the humerus; and, near this bone, the posterior boundary extends one inch and a half below the line of the anterior.* Lying on this fold, near the humerus, are the axillary vessels, and the brachial plexus of nerves, and extending along it, in the direction of the chest, but internal to the edge of the latissimus, and on the subscapularis muscle, is the subscapular artery, with its vein and nerve; and winding round the lower border of the subscapularis is the dorsalis scapulæ artery. Near the humeral end of this same border, and underneath the axil- Axilla.

* The serratus magnus is often enumerated as one of the muscles of the posterior wall, but in the ordinary state of the arm during dissection, or in an operation, the scapula lies against the chest, and thus excludes this muscle from the cavity.

lary vessels are the posterior circumflex artery and nerve, and external to this is the branch of nerve to the teres major muscle; the intercosto-humeral nerves cross this border in their course to the arm. The internal boundary, the most extensive, is the side of the thorax as low as the fourth rib, with the corresponding intercostal muscles, and digitations of the serratus, which lie, posteriorly, on the ribs; on this wall, near its junction with the posterior, is a long nerve — the posterior thoracic or external respiratory of Bell — distributed to the serratus, and, above this, are some small branches of arteries from the superior thoracic; near the union of this with the anterior fold, the intercosto-humeral nerves will be seen perforating the intercostal muscles, and, generally, a branch of an artery from the subscapular ramifies over the lower intercostal spaces. On the outer side this space has very small dimensions, in consequence of the anterior and posterior folds converging, to be fixed into the humerus; the humerus, covered by the biceps and coraco-brachialis muscles, bound the axilla in this part; the axillary vessels and branches of the brachial plexus of nerves are found to occupy this side of the space.

Axillary Artery in the third part of its extent.

The *axillary artery*, a continuation of the subclavian, and named from passing through the axillary space, extends, in the present position of the arm, obliquely downwards and outwards from the lower border of the first rib, to the lower border of the teres muscle; but, as the artery has distinct relations, as will be afterwards seen, according as it is above, below, or beneath the small pectoral muscle, it is described in three different portions. The portion of the axillary below the small pectoral muscle is now exposed, it is about three inches in length, and is almost concealed by nerves and veins: it has in front of it the lower border of the pectoralis major, which forms the fold of the axilla, and below this, to its termination, it is covered only by the fascia of the arm and the integuments; it lies on the subscapularis muscle, the tendon of the latissimus, and on the tendon of the teres. On the outer side of it is placed the coraco-brachialis muscle, on the inner, the axillary vein, and it is surrounded with branches of the brachial plexus of nerves. In the upper part of this extent, the artery is concealed from view by the axillary vein which lies to its thoracic side, but, below this, in consequence of the course of the artery being outwards, and that of the vein rather inwards, it becomes superficial, and the vein lies more to its sternal and posterior part; near the lower border of the subscapularis muscle, it is crossed by a large vein from the outer side, to join the axillary. To its outer side is situated the median nerve; to the inner, separating the vein from the artery, are the ulnar and internal cutaneous nerves, with the nerve of Wrisberg which passes behind the vein to its inner side. Behind the vessel are the musculo-spiral, and the

circumflex nerve, the latter leaving the artery and the axilla at the lower border of the subscapularis muscle. Sometimes the external cutaneous, another branch of the brachial plexus, is found with the median, to the outer side of the artery, but this usually leaves the vessel at the lower border of the small pectoral muscle. This portion of the axillary artery gives off the long thoracic branch along the anterior fold of the axilla; the subscapular along the posterior; anterior and posterior circumflex, below the preceding, in front of the neck of the humerus and behind it; and a muscular branch to the coracobrachialis: one or more small arteries are frequently distributed to the side of the chest.

Axillary Vein.

The *axillary vein*, resulting from the union of the veins of the arm, has the same extent as the artery, a part only of it being now dissected; it has the same relations to muscles before and behind, and lies to the sternal side and over this vessel, but separated from close contact with it, by the interposition of the nerves; it receives the basilic of the arm, and branches corresponding to those of the artery, and, at the lower border of the subscapularis, is joined by a large branch from the outer side. As the vein is placed to the inner side of the artery, it lies on the different branches of arteries and nerves which pass inwards.

Middle Intercostal Cutaneous of the second Nerve.

The two upper *middle intercostal cutaneous nerves*, which could not be seen before, since they occupied the axilla, are larger than the others, and are derived from the second and third intercostal nerves. The branch supplied by the second, the largest, perforates the muscle in the intercostal space, above the attachment of the first digitation of the serratus, and it soon gives one branch, inwards, to join with the nerve of Wrisberg from the brachial plexus, another forwards to join with a similar one from the nerve next below, to form a branch which is distributed to the integuments of the upper and anterior part of the arm; whilst the trunk of the nerve divides into two or more branches, the *intercosto-humeral*, which cross the posterior fold of the axilla and are distributed to the integuments of the inner and posterior part of the arm. The size of the branch supplied to the nerve of Wrisberg varies much; it is sometimes so large as to appear to constitute the nerve, which is then joined by a small filament from the plexus. The *cutaneous branch* from the third intercostal nerve escapes from the third intercostal space, appears below the second digitation of the serratus magnus muscle, and divides into an anterior and a posterior branch; the anterior has been seen in the dissection of the cutaneous nerves to turn over the border of the pectoralis, to perforate the fascia, and supply the integuments and mamma; the posterior, the larger, gives off numerous branches, which radiate and pass inwards to supply the axillary space, one uniting with the cu-

Intercosto-humeral.

Intercostal Cutaneous of the Third.

taneous from the second intercostal, to give rise to a small cutaneous nerve for the arm; the remainder of these have the same direction as the intercosto-humeral, and cross the axillary border to supply the upper and posterior part of the arm and shoulder. The *lymphatic glands* of the axillary space, variable in size and number, are reddish-looking bodies, situated in the lower part of the space, nearer the chest than the arm, and in contact with the anterior and posterior folds of the axilla. These glands receive, below, the ducts of the lymphatics of the arm, and emit, from their upper parts, the efferent ducts which unite together, at the upper part of the axilla, to form the right thoracic duct, of about one inch in length; this opens into the point of union of the right subclavian, and the axillary vein. When this trunk does not exist, the ducts open, separately, into the veins. The branches of arteries, supplied to these glands, are from the artery of the armpit, or arteria thoracica alaria.

Lymphatic Glands.

Mamma. The *mammary gland* is to be examined after the cavity of the axilla, and before the dissection of the pectoralis major. Its office is the secretion of milk; it is situated on the lateral part of the thorax, opposite the interval between the third and the seventh rib, and it often projects into the axilla; it varies much in size in different females, in consequence of the great quantity of adipose tissue contained in the intervals of the glandular structure. In the female, these organs have a very inferior degree of development until the age of puberty, and in the male they remain atrophied. It consists of a hard, firm, conical body, thicker in the centre than at the circumference, which is covered by the skin, and rests, by its base which is flat, upon the pectoralis muscle, but separated by a layer of cellular membrane; from the centre of the gland rises a conical eminence, named the *nipple*, of a reddish or brownish colour, which has, in its centre, one or more depressions into which the lactiferous tubes open; the skin of the nipple is studded with sebaceous follicles, whose secretion lubricates the surface. Around the nipple is the areola, which is pink in females who have not suckled, but afterwards of a brownish colour. The gland is formed by numerous glandular masses, separated from each other by intervals, and by processes of a strong enveloping fibrous tissue, and each has its separate excretory tube: the intervals between these masses are filled by adipose tissue. The structure of the glandular masses consists of small granules of a reddish-white colour, connected together in lobules, and these are collected into masses, and in the granules the excretory or lactiferous tubes commence by small radicles, which unite together to form larger canals, and these, again, to give rise to the lactiferous tubes which pass inwards to the centre, and, beneath the nipple, are dilated into sacs, about fifteen in number; the tubes then become contracted in size, and pass through the

Structure.

nipple to open on its surface. The arteries, that this structure receives, come from the long thoracic, and internal mammary, besides branches which are supplied from other arteries of the axillary, through the pectoral muscle; also from the intercostal arteries with the cutaneous nerves: — the veins accompany the arteries. The nerves are from the anterior and middle intercostal cutaneous branches. Vessels. Nerves.

Clean the surface of the pectoral muscle by removing the mammary gland and the layer of cellular membrane which covers it; and as the direction of the fibres of the muscle is from the thorax to the arm, dissect in their course, and begin at the lower border. Dissection.

The *pectoralis major muscle* is triangular in shape, the base at the sternum, the apex at the humerus, and it bounds, in front, the axilla. It *arises,* internally, by aponeurotic fibres, from the anterior surface of the sternal half of the clavicle; by fleshy and tendinous portions, from the cartilages of the true ribs, except the last, and from the osseous portion of the sixth; by aponeurotic fibres, from the aponeurosis of the external oblique of the abdomen; and it is united to the muscle of the opposite side, in front of the sternum, by a fibrous prolongation. From these points of origin, the fibres take different directions in their course to the humerus; thus the superior, from the clavicle, rather the shortest, pass obliquely downwards, overlapping the middle fibres which are almost transverse; and the inferior, the longest, are directed upwards and outwards, behind the superior and middle, so that the fibres, which were highest at the inner attachment, become inferior at the outer, and those, that were lowest, become superior at the humerus; they all end in a tendon which is *inserted* into the outer edge of the bicipital groove of the humerus, and sends off an expansion to the fascia of the arm. This tendon will be seen after the muscle is divided. Pectoralis major Muscle. Origin. Insertion.

On the cutaneous surface are the skin and superficial fascia, in which ramify the cutaneous vessels and nerves; the attachment to the clavicle is separated from the thoracic portion by a cellular interval, marked by a depression on the surface, and is covered by the platysma; the mamma lies on the muscle near the lower border, and the anterior cutaneous nerves perforate it near the sternum. The upper border, the shortest, lies in the groove which is seen, on the surface, to descend from the middle of the clavicle, and it is parallel to the deltoid muscle, but separated by the cephalic vein, and a small artery — the arteria thoracica humeraria; the lower, the longest, forms the inferior border of the fold of the axilla, its lowest fibres being twisted behind the upper, and, near the thorax, the pectoralis minor projects below it. The sternal part, thin and aponeurotic, is attached to its fellow of the opposite side, across the sternum, by an aponeurotic fibrous Relations.

expansion, and lower down to the aponeurosis covering the rectus muscle.

Dissection. Place the arm by the side, and divide the clavicular attachment of the pectoral without cutting the branches of nerve and artery which enter it; draw down the upper border of the sternal portion of the muscle; remove carefully much cellular membrane, and dissect the branches of the anterior thoracic nerve into its substance, also the branches of the acromial thoracic artery: these perforate the strong costo-coracoid membrane, near the clavicle, and above the upper border of the small pectoral muscle. Cut through the remaining portion of the pectoral without injuring many of its vessels or nerves, since their anatomy will be resumed after the muscles. Throw up and down the halves of the muscle.

Parts that the Pectoralis covers. The parts that the pectoral muscle covers, are, by the middle of its posterior surface, the small pectoral muscle, with the branches of vessels and nerves which lie between the two; between the small pectoral and the clavicle it forms the upper part of the anterior boundary of the axilla, and covers the subclavius muscle, the costo-coracoid membrane which separates it from the vessels beneath; and it will lie on the parts that perforate the costo-coracoid membrane, viz. the cephalic vein, the acromial thoracic artery and vein, and the anterior thoracic nerve, together with the superior thoracic artery, which ramifies on the upper part of the chest. This part of the muscle conceals the first and second intercostal spaces and muscles, with the nerve perforating the second, and the arteries ramifying on them. Below the small pectoral, it enters into the anterior boundary of the axilla, as it did above this muscle; it lies, here, on the vessels, nerves, and glands of the axillary space, and on the coracobrachialis and biceps muscles; on the side of the chest, below the muscle, it covers the cartilages and bony parts of the ribs, the intercostal muscles, serratus magnus, and the upper parts of the rectus and obliquus abdominis muscles, connected to the thorax. The tendon of insertion of the muscle into the outer border of the bicipital groove of the humerus, joins this bone about one inch and a half below its head, and it is divided into an anterior and a posterior aponeurotic portion, united, below, at the attachment to the humerus, but separate above, so as to receive the handle of the scalpel between them; the fibres from the clavicle, and some from the upper sternal attachment, join the anterior tendon, whilst the inferior, join the posterior portion, which is wider than the anterior, and ascends as high as it; at the attachment to the bone, it is united to the tendon of insertion of the deltoid. The tendon sends, upwards, an aponeurotic expansion, over the bicipital groove, to the great tuberosity of the humerus, backwards, another to line the groove and join that from the

Tendon of the Pectoralis.

tendon of the latissimus, and downwards, one to the fascia of the arm.

Pectoralis minor Muscle.

The *pectoralis minor muscle* is next to be dissected out without removing the vessels and nerves on its surface. Its shape resembles that of the pectoralis major, and it is extended, like it, from the thorax to the arm, across the centre only of the axillary space, the portion of the anterior wall, above and below it, consisting of only the pectoralis major.

Origin.

The *origin* is, by aponeurotic fibres, from the third, fourth, and fifth ribs, external to their cartilages; the fibres run, upwards and outwards, to join a tendon which is *inserted* into the upper surface of the coracoid process, as far forwards as the summit, and unites with the coraco-brachialis, and short head of the biceps, which arise from the tip of this process.

Insertion.

Relations.

The upper border of the muscle forms the lower limit of the space between it and the clavicle, in which are contained the upper part of the axillary artery, with the accompanying vein, and the brachial plexus of nerves, with their branches; the lower border, more oblique and longer than the upper, projects from beneath the pectoralis major near the chest, and the long thoracic artery runs parallel to it, on the side of the thorax; the tendon of insertion is continued further on this border than on the upper. The anterior or cutaneous surface is covered by the pectoralis major, and by branches of the anterior thoracic nerve, and acromial thoracic vessels, and one or two branches of nerves perforate the muscle; the posterior surface lies on the ribs and the intercostal muscles between them, as well as on the serratus magnus muscle; it conceals the middle part of the axillary vessels, the brachial plexus of nerves, and a plexus of small nerves, which supplies it and the pectoralis major.

Costo-coracoid Membrane.

The *costo-coracoid membrane* or *ligament* is best exposed by scraping it with the handle of the knife; and by removing the cellular structure on the outer side of the vessels and nerves, it can be followed down around these parts, and its attachment to the coracoid process can be seen. This structure is named from its attachments, internally, to the first rib, and, externally, to the coracoid process of the scapula. It varies much in thickness in different subjects, and between its points of attachment it has a membranous appearance, covers in the subclavius muscle, and is attached to the clavicle; but, below this muscle, it consists of a narrow, firm band, over the axillary vessels, with an apparently defined arched border, which is found to be continued downwards behind the pectoral muscle, closely investing the nerves and vessels, on which it is lost about the head of the humerus, but on the inner side it joins the vein much sooner: thus the fascia envelopes the vessels and nerves in a sheath, similar to that for the vessels of the lower extremity when they leave the abdomen. This membrane is perforated by the cephalic vein, and one or two other small veins from the trunk of the axillary,

by the acromial thoracic artery, and anterior thoracic nerve. Make a transverse incision above the lower border of the subclavius, turn up this muscle, and the layer of fascia beneath it, from the cervical region, is seen to join this structure, and so to incase the subclavius muscle. Take away this membrane to expose the axillary vessels, and the brachial plexus of nerves above the pectoralis minor.

Upper part of the Axillary Artery;

The *upper portion of the axillary artery*, above the small pectoral muscle, lies in the space between the upper border of this muscle and the clavicle, being covered by the costo-coracoid membrane and pectoralis major, and crossed by the cephalic vein and anterior thoracic nerve; commencing at the lower border of the first rib, the vessel rests on the first intercostal space and on the second rib, but it soon leaves the thorax, crosses the apex of the axilla to reach the subscapularis muscle, and it is unsupported by muscular structure; the posterior thoracic nerve or external respiratory crosses behind it. To its inner side, and somewhat nearer the surface than it, is the axillary vein; and to the outer is the brachial plexus of nerves, separated by a cellular interval, and the plexus consists, in this part, of two large trunks which lie side by side. The superior thoracic and acromial thoracic arteries arise from this portion of the artery.

and of the Vein.

The *axillary vein* in relation with this part of the artery lies internal and close to it, has the same relations to muscles, and receives the cephalic and acromial thoracic veins.

Middle part of the Axillary Artery;

The *middle part of the axillary artery*, enveloped by the brachial plexus of nerves, is beneath the pectoralis minor muscle, which limits this artificial division of it into three parts; and superficial to the pectoralis minor is the pectoralis major; so that this is the only portion of the artery covered by both pectoral muscles; at the lower border of the pectoralis minor it is crossed by the inner root of the median nerve. To the inner side is placed one of the large nervous cords which were contiguous to the outer side of the upper portion of the artery, since it has passed inwards behind the vessel; to the outer, is found the external of the two trunks, described in speaking of the brachial plexus, as in relation with the artery above the pectoralis minor. Behind the artery is the subscapularis muscle, separated from the vessel by a large nerve, formed by branches from the cords on the outer and inner sides of the artery; so that the vessel is surrounded by nerves in this part of its course. The alar thoracic branch is given from this portion of the artery to the axillary glands.

and of the Vein.

The *axillary vein* is still to the thoracic side of the artery, separated from it by the nerves, and it is crossed by the small nerves which go to the thorax.

Branches of the Artery.

The *branches* of the axillary artery supply the thorax and parts about the shoulder, those to the thorax have the distinctive term, thoracic, applied to them, and those to the shoulder

are the subscapular and circumflex: the thoracic branches are four,— suprema, acromialis, longa, and alaris.

Arteria thoracica suprema, the first branch that leaves the artery, arises above the pectoralis minor muscle, and opposite the first intercostal space, it runs inwards, beneath the vein, to the side of the thorax, and, ramifying over the two first intercostal spaces, anastomoses with branches of the intercostal arteries. This artery is sometimes small, or there may be two.* Superior Thoracic.

The *acromial thoracic artery* is a short trunk from the front of the axillary artery, above the pectoralis minor muscle, it perforates the costo-coracoid membrane, and, appearing in the interval between the pectoralis major and deltoid muscles, divides into ascending and descending branches. The *ascending*, the smallest, are a few arteries which run to supply the subclavius, and pass beneath the deltoid to enter it and anastomose with the posterior circumflex; one of these branches,— the *inferior acromial*, longer than the rest, perforates the deltoid, near the acromion, ascends on this process, and anastomoses with the supra-acromial artery, and with branches from the transversalis colli artery. The *descending* branches consist of an external set, which cross beneath the cephalic vein to the interval between the pectoral and deltoid, enter the substance of these muscles, and give off a long slender branch—the *thoracica humeraria*—to accompany the cephalic vein; a middle set, the most numerous, which pass between the two pectoral muscles, accompanied by the greater number of the branches of the anterior thoracic nerve, to supply the muscles; and of an internal set which are distributed to the side of the chest and the serratus muscle, and inosculate with branches from the internal mammary, and the intercostal. Acromial Thoracic. Ascending branches. Inferior Acromial. Descending branches. Thoracica humeraria.

Arteria thoracica alaris varies much in its origin; it is either a separate trunk from the axillary, behind the pectoralis minor, or it consists of branches from the subscapular or long thoracic arteries. The branches of this artery are distributed to the glands in the axillary space. Alar Thoracic.

The *long thoracic artery* or external mammary is a branch of considerable size, it runs downwards and inwards, along the lower border of the pectoralis minor muscle, to the side of the chest, and is then prolonged on the serratus magnus muscle to about the sixth intercostal space; it gives branches to each intercostal space that it crosses over, to join the corresponding intercostal arteries; it supplies the pectoral and serratus muscles, and, in the female, sends one or more large branches to the mamma. Long Thoracic.

The *subscapular artery*, the largest of the branches of the axillary, next to the acromial thoracic, arises opposite the lower Subscapular.

* One of the pectoral branches of the acromial thoracic artery, which runs between the pectoral muscles, is often described as this artery.

border of the subscapularis muscle, continues along this border for about two inches, and then divides into an anterior and a

Posterior or Dorsal branch.

posterior branch of nearly equal size: — the *posterior* or *arteria dorsalis scapulæ* turns round the lower border of the subscapular muscle to the back of the scapula, and it will be dissected with

Anterior.

the muscles of that part; the *anterior*, in direction the continuation of the artery, runs along the subscapularis muscle, internal to the latissimus dorsi, to near the lower angle of the scapula, and it terminates by distributing branches, externally to the latissimus, and internally to the serratus magnus; the arteries to this last muscle may be followed to near its lower part. Some of the external branches supply the teres major muscle, and descend to the inferior angle of the scapula, to anastomose with the arteries of this part. The subscapular nerve, or that for the teres and latissimus muscles, accompanies the artery, and crosses it to reach the muscles; the subscapular vein lies below the artery, and joins the axillary vein at the lower border of the subscapularis. This artery is generally the most constant in its position, and often, in cases of varieties in the origin of the other branches, gives them off by a common trunk. The subscapular sends a small branch across the base of the axillary space, to the side of the chest, as an accessory to the long thoracic.

The circumflex arteries leave the axillary in the region of the arm, wind round the neck of the humerus, one before and the other behind, but are not now dissected.

Veins.

These arteries are accompanied by veins which open into the

Cephalic Vein.

axillary vein; and near the clavicle is the *cephalic vein*, which ascends, from the outer side of the arm, in the interval between the pectoral and deltoid muscles, passes forwards and inwards beneath the great pectoral muscle, to join also the axillary, and it perforates the costo-coracoid membrane close to the subclavius muscle; it crosses the brachial plexus of nerves, and the axillary artery in the upper part, also branches of the acromial thoracic artery.

Dissection.

In order to dissect out and follow the branches of the brachial plexus, the axillary vein and its branches are to be removed, and the axillary artery cut across and drawn to the thoracic side; the pectoralis minor may be partly cut through, if necessary, but care must be taken of the nerves on it. Should the lower part of the neck be exposed, a much more accurate knowledge of the plexus will be obtained by the dissectors of both the head and neck, and the upper extremity.

Brachial Plexus.

The *brachial plexus*, formed by the anterior branches of the four last cervical nerves and the first dorsal, extends from the sides of the bodies of the lower cervical vertebræ to the coracoid process in the axilla; the relations therefore of that part of the plexus above the clavicle, as well as the branches given from it,

will differ much from the portion below this bone, and its description must be referred to in the dissection of the head and neck. The relations of the plexus below the clavicle are the following: — it is covered by the great pectoral muscle and costo-coracoid membrane, and below this, by both pectoral muscles; and it lies on the first digitation of the serratus, and on the subscapularis muscle. Above the small pectoral it is placed to the acromial side of the artery, separated by a cellular interval from it, beneath the muscle it surrounds the artery, and below the pectoral, are the following terminal branches from it to the upper extremity; — two, the external cutaneous and median, being to the outer side of the artery; the ulnar, internal cutaneous, and nerve of Wrisberg, to the inner side of this vessel; and the musculo-spiral and circumflex, behind it. Below the clavicle, in the axillary space, the brachial plexus consists of two large cords only, instead of three as above the clavicle, and these lie side by side; the one nearest the artery is formed by the eighth cervical and first dorsal nerves, and the other, by the fifth, sixth, and seventh cervical nerves. Beneath the small pectoral muscle, the inner cord passes beneath the artery to its inner side, and where this same cord separates from the other, a branch is given from each; these unite to form a third nervous cord, situated behind the artery, so that, beneath the pectoral muscle, the artery has a nervous cord on the outer side, on the inner, and behind it, and from these three terminal cords are given all the branches below the clavicle; thus, from the outer cord, arise, one of the anterior thoracic (the posterior thoracic being formed high in the neck from the fifth and sixth cervical nerves), the external cutaneous, and outer head of the median nerve; from the inner, the second anterior thoracic nerve, the internal cutaneous, ulnar, and inner head of the median, with, occasionally, the nerve of Wrisberg; and from the posterior cord, the two subscapular nerves, sometimes the nerve of Wrisberg, branches to the latissimus and teres muscles, with the large terminal branches of the musculo-spiral and circumflex nerves. The two primary cords are sometimes connected by a small branch, and the formation of the third may take place as high as the clavicle, instead of behind the axillary artery in its middle part, so that three nervous cords appear close below the clavicle, and on the outer side of the artery.

Anterior Thoracic Nerves.

The *anterior thoracic nerves* are two in number, one lying in front of the axillary artery, and coming from the outer cord, the other, beneath the vessel, from the inner cord. The *superficial* of the two, larger than the other, sends down a small filament beneath the pectoralis minor, and on the inner side of the artery, to join with the deep branch; it then perforates, as was seen, the costo-coracoid membrane above the acromial thoracic branch, runs downwards and inwards over the axillary

Superficial branch.

vein and artery, and divides into filaments which enter, with the branches of the acromial thoracic artery, between the two pectoral muscles, and, about the centre of the pectoralis minor, are directed horizontally inwards and outwards, and supply the pectoralis major. One small branch from it runs parallel to the clavicle, and is distributed to the anterior surface of the sternum, and another supplies the clavicular portion of the great pectoral muscle. Cut across the pectoralis minor muscle, near the centre, to see the deep branch of the anterior thoracic nerves, which forms a kind of plexus beneath it; remove also the cellular membrane from these small nerves. The *deep branch* of the anterior thoracic nerves comes from the inner cord, turns upwards between the axillary artery and vein, and joins with the filament sent to it from the superficial branch; from the point of union of the two results an inverted arch or kind of plexus, and from the convexity of this many filaments are distributed to the under surface of the pectoralis minor. Some of the filaments perforate the pectoralis minor to supply the major, and others pass above the border of the pectoralis minor to the pectoralis major muscle.

Dissection.

Deep branch.

External Cutaneous, and Median.

The *external cutaneous* leaves the cord at the lower border of the pectoralis minor muscle, and perforates the coraco-brachialis muscle which separates it from the axillary artery. The *median* continues in contact with the artery to the lower border of the teres muscle, and is joined by its internal root which crosses the artery about the lower border of the pectoralis minor.

Nerve of Wrisberg.

The *nerve of Wrisberg*, or *small internal cutaneous**, arises either from the internal cord, in common with the ulnar nerve, or from the upper part of the posterior cord. The nerve lies by the side of the ulnar and internal cutaneous, crosses beneath the axillary vein opposite the lower border of the subscapularis muscle, and joins with the filament from the middle intercostal cutaneous of the second intercostal nerve; it then runs downwards, internal to the vein, and beneath the fascia of the arm, and it will be followed in this part. The communicating branch from the intercostal cutaneous may join higher up, or it may be the larger filament of origin. The nerve may occasionally perforate the vein.

Internal Cutaneous and Ulnar.

The *internal cutaneous* and *ulnar* spring from the inner cord, descend internal to the artery, continuing with it to its termi-

* This nerve, first noticed by Wrisberg as the "cutaneus minor internus vel cubitalis," is described by Klint, "de Nervis Brachii," in the *Scriptores Neurologici* (Ludwig.), tom. iii. cap. v. It is here said to arise by a trunk common to it and the ulnar, median, musculo-cutaneous, and internal cutaneous, but no mention is made of its union with the middle cutaneous of the intercostal; but Cruveilhier, who describes this nerve as the "accessoire du brachial cutané interne," speaks of its junction with the branch from the intercostal. See *Anatomie Descriptive*, tom. iv. p. 799.

nation at the lower border of the teres, but the internal cutaneous then passes to the cutaneous surface of the vessel, and lies on it.

The *subscapular nerves* are two in number;—the superior, given off high up from the posterior cord, is a small nerve which descends, behind the artery, to the upper part of the axillary surface of the subscapularis muscle; the inferior, larger in size, and arising lower from the cord, is distributed to the middle of the subscapularis; this last is irregular in its origin. Subscapular Nerves.

The *nerve to the latissimus dorsi muscle* arises a little above the border of the subscapularis, runs downwards and inwards along the posterior boundary of the axilla, placed at first above the subscapular artery, but crossing beneath it to reach the border of the latissimus dorsi, internal to which it runs; it then enters the substance of the latissimus, and may be traced in it to a considerable distance. Nerve to the Latissimus.

The *nerve to the teres major* is either a branch from the preceding, or a separate one from the cord below it, it descends over the border of the subscapularis, nearer the humerus than the nerve to the latissimus, and is distributed to the teres. Nerve to the Teres.

The *circumflex nerve* continues behind the artery, only to the lower border of the subscapularis, since it passes to the back of the arm; but the *musculo-spiral* accompanies the vessel to its termination at the teres tendon. The Circumflex and Musculo-spiral Nerves.

The *nerve to the serratus magnus*, or the posterior thoracic, or external respiratory of Bell, is seen, in the dissection of the neck, to be formed by branches of the fifth and sixth cervical nerves, before they enter the plexus; it then descends, behind the brachial plexus and vessels, to the serratus magnus muscle on the side of the chest, to which it is distributed by filaments that may be traced to near its lower part. At the upper part of the muscle filaments are sent backwards to supply it. Nerve to the Serratus Muscle.

The *subclavius muscle* is a thin roundish muscle, placed beneath the clavicle. It *arises* internally, from the cartilage of the first rib, by a round tendon which is continued along the inferior surface of the muscle, and this origin is anterior to the costo-clavicular ligament; the fibres run upwards and outwards to be *inserted* into the groove on the under surface of the clavicle, and they extend as far outwards as the coraco-clavicular ligament. The anterior surface is covered by the costo-coracoid membrane, and the posterior corresponds to the layer of cervical fascia which descends, from the neck, beneath the muscle. The upper border is fixed to the clavicle, and the lower overhangs the axillary vessels, and the brachial plexus of nerves. Subclavius Muscle. Origin. Insertion. Relations.

The *latissimus dorsi muscle* is now seen in that part which, by extending from the side of the chest or inferior angle of the scapula to the humerus, forms the lower border of the posterior fold of the axilla. The fibres of the muscle are directed Humeral portion of the Latissimus.

forwards and outwards, and cross each other in their course to the tendon of insertion, so that the inferior fibres or those from the ribs ascend to the upper border of the tendon, whilst the most superior fibres or those from the spines of the dorsal vertebræ descend to the lower border, and the intervening fibres are inserted between these two, into the tendon, which is about three inches long, and is *inserted*, after dipping into the bicipital groove, into the outer side of this depression, and sends off some aponeurotic fibres to join with those from the pectoralis in the groove. The insertion of this tendon ascends nearly to the attachment of the subscapularis to the small tuberosity of the humerus, and higher than the tendon of the pectoralis major. A synovial bursa separates it from the tendon of the teres major, close to which it lies, and to which it is united by aponeurotic fibres. In consequence of the crossing of the fibres to reach the borders of the tendon, they form a groove or hollow which receives the lower border of the scapula, and the teres muscle, and it is thus that the latissimus shuts out the teres from the axillary space, and from contact with the axillary artery, except at the insertion into the humerus, at which part the teres extends below it. This portion of the latissimus assists to form the posterior boundary of the axilla, and is in contact with the axillary artery, and nerves of the brachial plexus.

Insertion.

Dissection. Saw through the clavicle rather external to its centre*, divide the subclavius muscle, and the fascia descending beneath it is seen; cut across the brachial plexus, as well as the axillary artery, below the clavicle, if this has not been done previously, and throw them to the outer side; separate the scapula from the side of the chest, and the serratus muscle is seen lying between the base of this bone and the thorax; remove the cellular membrane from it.

Serratus magnus Muscle. The *serratus magnus* is a large square muscle, attaching the upper extremity to the trunk, and it is situated on the side of the thorax, from which it arises by nine or ten pointed digitations attached to as many of the upper ribs. In consequence of the fibres taking different directions, and forming muscular portions of a different thickness, three separate divisions of the muscle are described; an upper, to the superior angle of the scapula, a lower to the inferior angle, and a middle, between these two, to the base of the bone. The *upper* arises by one large process attached to both the first and second ribs, and to an aponeurotic arch between them, over the intercostal muscle; the fibres are directed upwards and backwards, to be inserted into the rough portion of bone on the inner surface of the supe-

Upper portion.

* If the posterior triangle of the neck has not been dissected, this bone should be left entire, since to divide it would destroy the relative anatomy of the neck; and when the serratus has been once or twice exposed after this method, a better dissection of the back will be obtained if it is not divided.

rior angle of the scapula. The *middle portion* arises from the oblique lines on the outer surface of the second, third, and fourth ribs by large and thin digitations, from which the fibres run horizontally backwards and outwards, forming a thin muscle, to be inserted into the base of the scapula between the superior and inferior angles. The *lower part* of the muscle, the largest and strongest, arises by narrow processes from the outer surface and upper border of the fifth, sixth, seventh, eighth, and ninth ribs; these digitate with corresponding portions of the external oblique of the abdomen; the fleshy fibres ascend, and converge to the inferior angle of the scapula, into the inner surface of which they are inserted. This muscle is applied upon the ribs and intercostal muscles, the part below the pectoral being subcutaneous, but the part above is beneath these muscles. In the ordinary position of the arm, the subscapularis muscle and scapula are applied against it, and the axillary artery and brachial plexus of nerves lie on the upper origin from the ribs. Along the side of the chest, the middle cutaneous nerves of the intercostal pass from beneath its digitations.

Middle portion. Lower portion. Relations.

Detach the digitations of the serratus from the ribs, to see the intercostal muscles between the points of emergence of the cutaneous nerves and the sternum: a fascia prolongs forwards the external intercostal muscle to the sternum. When the external intercostal has been seen, cut it through, for the internal, and for the intercostal nerve and artery.

Dissection.

The *intercostal muscles*, situated in the intervals between the ribs, consist of an external and internal layer whose fibres cross, those of the external being directed downwards and forwards, and those of the internal downwards and backwards; the outer layer of muscular fibres does not extend farther forwards than the osseous part of the ribs, and the inner, beginning at the sternum, ceases behind at the angles.

Intercostal Muscles.

The *external intercostal* muscle consists of fibres which pass obliquely downwards and forwards, from the outer edge of the lower border of the rib above, to that of the upper border of the rib beneath, into which they are inserted; the attachment to the ribs is tendinous and fleshy, and small tendons extend between the ribs. Posteriorly, the fibres are continuous in direction with the levatores costarum, and they cease, in front, behind the cartilages of the ribs, but a thin aponeurosis continues forwards this layer to the sternum; the internal intercostal is seen anterior to this muscle. This portion of the muscle is covered by the serratus and pectoral muscles. The muscles, in the lower spaces, are continuous, in front, with the fibres of the external oblique of the abdomen.

External. Origin. Insertion. Relations.

The *internal intercostal* has the same structure as the external, and its fibres, which are inclined obliquely downwards and backwards, cross those of the external like the legs of the letter

Internal.

Attachments. X; its attachments are to the inner border of the rib above and below each intercostal space. It begins at the sternum, where its fibres are seen in front of the external, and ceases, behind, at the angles of the ribs. These muscles are covered by the external layer, and where this is deficient in front, by the aponeurosis prolonged from it to the sternum; they are concealed by the pectoral, rectus, and external oblique muscles, and the intercostal nerve and artery lie on each; in the lower intercostal spaces, corresponding to the false ribs, the fibres are continuous with those of the internal oblique muscle of the abdomen. Cut through one or more of these muscles, they are thinner than the external, and lie on the pleura, and, near the sternum, on the internal mammary artery, and triangularis sterni muscle. The relations of these muscles behind, both externally and internally, are seen in the dissection of the back, and the thorax.

Relations.

Inter. costal Nerve. Each *intercostal nerve*, the anterior branch of a dorsal spinal nerve, accompanied by the intercostal vessels, runs forwards to the middle line of the body, in the interval between the ribs, and between the two layers of intercostal muscles; and, about the centre of the intercostal space it gives off, to the surface, the middle intercostal cutaneous branch. The nerve then enters between the fibres of the internal muscular layer, runs along the lower border of the rib above, to near its cartilage; it now perforates the internal intercostal muscle, comes into contact with the pleura, crosses the internal mammary vessels, and, in some of the spaces, the triangularis sterni muscle, and near the sternum perforates again the fibres of the muscle, and is distributed to the integuments. In its course it supplies the intercostal muscles, and, soon after the nerve has appeared on the inner surface of the thorax, it gives off branches to the rib beneath, these are accompanied by the anterior branches of the internal mammary artery. The first intercostal nerve is very small; in the lower spaces, the nerves follow the curved direction of the ribs, and the fifth, sixth, and seventh become cutaneous beneath the cartilages of the corresponding ribs, where they change their direction to ascend to the sternum. The sixth and seventh pass on the inner surface of the cartilaginous process which unites the sixth to the seventh, and the seventh to the eighth rib.

Intercostal Artery. The *anterior part of the intercostal artery* is now also dissected; these arteries are branches of the thoracic aorta, they lie, as the nerves, between the intercostal muscles in each space, nearer the rib above than that below, and, anterior to the centre of the space, each divides into two branches; the upper one continues the direction of the artery below the rib, and the lower descends to the upper border of the other rib; they anastomose with branches sent, externally, from the internal mammary artery. The intercostal muscles receive their branches from the artery, and it is accompanied by the intercostal vein.

Expose the internal mammary artery by cutting through the cartilages of the true ribs, except the first and last, near the sternum, and to see it remove a sufficient portion of each; the cartilage of the seventh rib should be left attached to the sternum, to support the diaphragm. The triangularis sterni muscle is dissected at the same time, but it is only partially seen; for, to obtain a good view of it, the whole of the front of the thorax, including the sternum and ribs attached to it, should be removed in a single piece, and the muscle dissected from the inner side. Dissection.

The *internal mammary artery*, a branch from the subclavian, enters the thorax behind the cartilage of the first rib, and extends along the side of the sternum, beneath the cartilages of the ribs, and half an inch external to the articulation of these with the sternum, as far as to the interval between the sixth and seventh, in which spot it divides into an internal or abdominal, and an external or musculo-phrenic branch. In this part of its course, it is covered by the cartilages of the ribs, and by the internal intercostal muscles, and is crossed by the branches of the intercostal nerves; it lies on the pleura, and below this, on the triangularis sterni muscle which separates it from the pleura. The artery is placed external to the mediastinal space, and is accompanied by two veins, and by a chain of lymphatic glands. On the left side it is destroyed by injecting the body. Internal Mammary Artery.

This artery gives many branches to the anterior mediastinum; these are called *mediastinal*, and are distributed to the remains of the thymus gland, to the cellular membrane, and to the triangularis sterni muscle and pericardium. Branches. Mediastinal.

The *anterior intercostal arteries* supply the front of the intercostal spaces; they are two for each space, and arise either separately, or by a common trunk which soon divides into two; these run outwards between the pleura and internal intercostal muscle, one being placed on the border of each rib, and they terminate by anastomosing with the intercostals from the aorta. Anterior Intercostal.

The *perforating arteries* arise from the front of the mammary, and are one or two for each space; they perforate the intercostal muscle, then the pectoralis, supplying it with branches, and are lost in the integuments, as was seen in the dissection of the cutaneous nerves: the lower of these branches in the female are larger than the others, and supply the mammary gland. Another branch perforates the intercostal muscle, and ramifies on the cartilages of the ribs. Perforating.

The *abdominal branch* passes beneath the cartilage of the seventh rib, enters the sheath of the rectus, and will be seen with this muscle; it sends a branch to the front of the xiphoid cartilage, to anastomose with one from the opposite side. The *musculo-phrenic* runs outwards, beneath the cartilages of the seventh and eighth ribs, to enter the wall of the abdomen, Abdominal. Musculo-phrenic.

by perforating the diaphragm opposite the cartilage of the eighth or the ninth rib: these branches will be seen in the dissection of the abdomen. The musculo-phrenic supplies the anterior intercostal arteries to some of the lower spaces.

Mammary Veins. Two *veins* accompany the internal mammary artery, and open, by one trunk, into the brachio-cephalic vein on the left side, and into the vena cava, on the right.

Triangularis Sterni Muscle. The *triangularis sterni muscle*, not well seen unless the anterior parts of the ribs and the sternum are removed together, is a thin radiating muscle, fibrous, internally and externally, at its attachments.

Origin. It *arises*, internally, from the side of the xiphoid cartilage and sternum; the fibres pass outwards and upwards, the upper ones being most oblique, to be *inserted* by tendinous processes into the cartilages of all the true ribs except the first, and, in the intervals between the ribs, to the aponeurosis on the inner surface of the internal intercostal muscle.

Insertion.

Relations. The muscle lies on the pleura, and, on the left side, in the space of the anterior mediastinum; it is covered by the cartilages of the ribs and intercostal muscles, by the internal mammary artery and veins, and the intercostal nerves. The lower fibres are continuous with those of the transversalis abdominis muscle.

Dissection. The dissection of the interior of the thorax follows the examination of its walls, and the anatomy of the remainder of the arm will be resumed when the dissections of the thorax and back are completed.

DISSECTION OF THE THORAX.

Dissection. To open the cavity of the thorax, saw through the sternum opposite the interval between the two first ribs, and, again, between the attachments of the cartilages of the fifth and sixth ribs to this bone. The cartilages of the ribs that are connected to the sternum have been divided, on the right side, in the dissection of the internal mammary, and partially so, on the left, in the injection of the subject; but if any remain, cut through them, except through those of the first and seventh ribs; the latter is to be left entire for the support of the diaphragm, which belongs to the dissectors of the abdomen. Raise the sternum from below upwards, and the space, situated in the anterior portion of the mediastinum, will be seen behind it. Detach the pleura or lining membrane of the thorax from the ribs, and take away the greater part of the true ribs, except the first and last, by sawing through them as far back as can be conveniently done. It may be necessary, in some subjects, to divide the seventh rib, and to remove a part of it, but this should be done

external to its cartilage. Divide the pleura, on each side, in its whole extent, and the cavity of the thorax is exposed.

Boundaries of the Thorax.

The *thorax*, a partly osseous and cartilaginous, and partly muscular case, contains the lungs, — the organs of respiration, with the air tube and vessels which supply them; the heart, the chief agent in the circulation, together with the great vessels connected to it; the nerves and vessels for the supply of its contents; and the œsophagus, pneumo-gastric nerves, the thoracic duct, and phrenic nerves and vessels, that pass through it from the neck to the abdomen. Its form is that of a hollow cone, it is placed above the abdomen, and between the upper extremities, to which it gives attachments; and the interior, which is now larger than the space occupied by the contained organs, is filled during life by the expanding lungs. The apex of the cone, situated, above, at the root of the neck, is wider in the transverse than in the antero-posterior direction, is oblique from above downwards, and from behind forwards; and it is bounded, in front, by the sternum and clavicles, behind, by the first dorsal vertebra, and on each side by the first rib. Through it pass, in the middle line, the trachea and œsophagus, with the sterno-hyoid and thyroid muscles in front, and the muscles, on the spine, behind them; and on each side of these are the large vessels that pass from the arch of the aorta to supply either the head and neck, or the upper extremities; the large veins that correspond to these; the nerves passing from the region of the neck to the thorax; with the thoracic duct, and upper part of each bag of the pleura, and the lungs: all of these will be more specially examined afterwards. The base, also wider in the transverse direction, is sloped off very obliquely, but in the opposite direction to the apex, or from above downwards, but from before backwards; and it is bounded, in front, by the extremity of the sternum and the xiphoid cartilage, behind, by the last dorsal and first lumbar vertebræ, and, on each side, by the irregular line of the ribs below the seventh. A muscular and moveable partition — the diaphragm — by its position across the base, separates the cavity of the thorax from that of the abdomen; and through this partition the aorta, for the supply of the lower extremities, passes, as well as the œsophagus with its accompanying nerves, and the thoracic duct. The anterior boundary, of about half the extent of the posterior, consists of the sternum and the cartilages of the ribs connected to it; and the posterior is formed by the spinal column, and, on each side, by the ribs and intercostal muscles. From the examination now made of the thorax, it will be seen that this is a hollow cone, with the lower third of the anterior part removed, and that, from the moveable state of its lateral boundaries, its interior must vary much in the conditions of inspiration and expiration; but the greatest changes in the capacity of the space are occasioned by the position of the

diaphragm, since its limits in forced respiration can scarcely be fixed; and it may be further diminished by the protrusion of this partition into the thorax, by the enlargement of any of the organs in the abdomen. In the natural state, the convexity of the diaphragm is greater on the right than on the left side, and the right half of the thorax is consequently shorter than the left; its height of ascent on the right side is to the interval between the fourth and the fifth rib, and on the left, to that between the fifth and sixth.

The Pleuræ.

The *pleuræ* are two serous membranes or sacs which line the wall of the thorax, and are reflected around and over the organs contained in its cavity, — one sac being placed on each side of the spinal column. Each pleura is a conical-shaped bag, in the interior of which fluid collects; and the cavity of one pleura is distinct from that of the opposite, though the membranes approach each other in front of the heart, as well as behind it, and form a mediastinum or partition between the two sides of the chest. The apex of each is above the first rib, between the scaleni muscles, and the right is higher than the left; the base is in contact with the diaphragm. The bag of the right side is shorter and wider than that of the left, which is narrowed by the inclination of the heart to that side; and each is reflected over the projecting lung, which is external to it. The outer surface is rough, and connected by cellular membrane to the thorax and lung, but the inner is smooth and secretes the serum; that portion of the membrane in contact with the ribs is called *pleura costalis*, whilst that covering the lung is thin and transparent, and is named *pleura pulmonalis*. The continuity of the membrane, on each side, over the lung and along the wall of the cavity, may be proved by tracing it from a given point to the same point again. Thus, if the right pleura be followed, it will be found to pass, from the posterior part of the sternum, vertically downwards and backwards to the side of the pericardium, forming one layer of the portion of the mediastinum or partition in front of the heart; it is then continued along the side of the pericardium to the anterior part of the root of the lung, is reflected over this organ so as to connect together its different lobules, and arrives at the under or posterior surface of the root; it is then directed backwards to the bodies of the vertebræ, forming one of the layers of the portion of the partition or mediastinum behind the heart, and is finally reflected upwards and forwards along the inner surface of the ribs, and so reaches the sternum or point of departure. Above the lung the lining membrane passes backwards by the side of the great vessels in the middle line, reaches the vertebræ, and is then reflected upwards along the ribs; below the root of the lung it forms a fold, called the *ligamentum latum pulmonis*, which is connected externally to the lung, and internally to the portion of the membrane in the

Ligamentum latum

mediastinum. The position of the heart, contained in its pericardium, along the middle line of the chest, and the great vessels that are connected to it, prevent the contact of the pleuræ of opposite sides along the centre of the thorax; but in front of this organ they approach each other, forming the anterior part of a partition or the anterior mediastinum, and, as they pass from the lungs and pericardium to the spine, they form the remaining portion of the partition behind the heart, or the posterior mediastinum. The *anterior mediastinum* extends from the back of the sternum to the pericardium; it is formed by a layer from the pleura of each side, as this is reflected from the sternum to the pericardium, and it encloses, between its layers, a space which is wider above and below than in the centre, and is also inclined, below, a little to the left side. The boundaries of this space are, in front, the sternum; behind, the pericardium; and on each side, the pleura; the upper part contains the origins of the sterno-hyoid and thyroid muscles, with the remains of the thymus gland and the vessels supplying it; and the lower is filled with cellular structure, and the triangularis sterni muscle of the left side is found in it. The *posterior mediastinum*, situated between the spine and the roots of the lungs, is formed, like the anterior, by a layer from each pleura, but they are separated farther from each other, and enclose a larger space, and more important parts. Draw forwards the right lung, and remove, on this side, the layer of pleura that is continued backwards from its root to the spine, in order that the space may be seen. On each side it is bounded by the pleura, in front by the pericardium, and behind by the spine; and it contains the thoracic portion of the descending aorta, which lies to the left side, and on the spine; the vena azygos, to the right, also on the spine; and between these, but close against the side of the aorta, is the thoracic duct. The œsophagus, situated in this space, lies, above, behind the trachea, it then escapes from beneath the left division of this tube and the arch of the aorta, and lies to the right side of this vessel; but as it descends to the diaphragm it gradually inclines in front of the aorta, and when it is about to perforate the diaphragm, opposite the tenth dorsal vertebra, is situated on the left of it; the pneumo-gastric nerve of each side accompanies this tube, the left being in front, and the right behind it. The trachea is contained in the upper part of the space, and lies in front of the œsophagus, but behind the aortic arch, and about the third dorsal vertebra, it divides into two branches that leave the space to enter the lungs. In the lower part of the space will be found the splanchnic nerves which are branches of the sympathetic, some lymphatic glands, and cellular membrane.

Pulmonis.

Anterior Mediastinum.

Posterior Mediastinum.

Remove the portion of the mediastinum in front of the heart, divide the internal mammary artery, if it has not been done;

Dissection.

take away the remains of the thymus gland, and the cellular membrane between the layers of the anterior mediastinum, as well as from the surface of the pericardium, but leave untouched, for the present, the arch of the aorta, and the small nerves that cross it. The root of the lung is to have the cellular membrane scraped away from it, with the handle of the knife, and care must be taken of the phrenic nerve and artery in front, and of the pneumo-gastric behind it.

Form and Relations of the Lungs.

The *lungs*, the organs of respiration, two in number, are contained in the cavity of the thorax, one on each side of the spine, and outside the cavity of the bag of the pleura which is reflected over it; during inspiration, in the healthy state of these organs, the chest is completely filled by them, so that the space, now seen, between the pleura parietalis and pleura pulmonalis is destroyed, and the two surfaces of the membrane are brought into contact. Each lung is of a conical form; but the right is wider and shorter than the left, consequent upon the position of the liver below, and the direction of the heart to the left side; it is divided into three lobes, the left having but two. Its base, which is directed downwards, is concave, and receives the convexity of the diaphragm, but it is most concave on the right side, from the presence of the liver; it is sloped off obliquely downwards and backwards, so that it projects much lower by its posterior, than by its anterior border. The apex projects above the level of the first rib, usually higher on the right than on the left side, and is beneath the anterior scalenus muscle and subclavian artery. The posterior border, thick, round, and vertical, is received into the hollow of the ribs near the vertebræ, is longer than the anterior, because of the obliquity of the base, and projects below, between the ribs and the diaphragm. The anterior border, thin, irregular, and oblique from above downwards, extends forwards over the pericardium, particularly on the left side, on which it is excavated for the heart; in the right lung are two fissures in this border, marking the division into three lobes, but, in the left, there is but one between its two lobes. The outer surface, convex, is received into the hollow of the ribs, and presents, in its centre, the fissure that separates the lung into lobes. The inner surface looks to the mediastinum, and is hollowed out, in front, for the convexity of the heart, but more on the left than on the right side; and to the posterior part of this surface is connected the root of the lung.

Divisions.

Each lung is divided into lobes by the fissure of the lung, which commences near the apex, and descends obliquely forwards to end, in the anterior border, near the base; this fissure divides the lung, on both sides, into an upper, small lobe, and a lower, large one; but, on the right side, a second small fissure is directed downwards and backwards from the anterior margin, to end in the great fissure; it cuts off a small triangular piece from the upper lobe, and gives three lobes to

the right lung. The root of the lung consists of the air tube, and the different vessels and nerves that pass to or from the lung, collected together and covered by the pleura; it is situated on the inner surface of this organ, about midway between the base and apex, and one third of the breadth of this surface from the posterior border. In front of the root, on the right side, is the superior or descending cava, and the phrenic nerve, part of the right auricle of the heart, and the anterior pulmonic plexus; behind, is the posterior pulmonic plexus; above, is the azygos vein which arches round it from behind to open into the superior cava; and below, is the ligamentum latum or fold of the pleura. On the left side, the phrenic nerve and anterior pulmonary plexus are in front; the posterior pulmonary plexus and descending aorta behind; the arch of the aorta above, and the fold of the pleura below, as on the right side. In the root are the vessels for the function, and for the nutrition of the lung, and if the pleura be carefully removed from it, without destroying the small anterior plexus, or the posterior one, it is found to be composed of a division of the air tube or the bronchus which becomes cellular in its ramifications in the lungs, and supplies these organs with air; of a branch of the pulmonary artery, to carry the impure blood to the lung, to be renewed; and of pulmonary veins to convey the blood to the heart, when it is purified: these vessels are for the function of the organ; and, connected with the nutrition, are the bronchial arteries and veins, the pulmonic plexuses of nerves and lymphatics. The following is the relative position of these parts in the root:—the bronchus, with its accompanying nerves and bronchial vessels, is the most posterior on both sides, the pulmonary veins the most anterior or superficial on both sides, and the pulmonary artery is situated between the other two; but the position of these from above downwards is different, and their relations to each other, in this direction, are, on the right side, bronchus, artery, and vein, though, on the left side, the artery and bronchus have changed places, and the relation is, consequently, artery, bronchus, and vein: this change in the relative position of the two sides, depends upon the left bronchus having to descend below the level of the left pulmonary artery, in order to pass through the arch of the aorta. The colour of the lung varies with the age of the individual; it is grey with some few black spots in the adult, much studded with black spots or lines in old age, and in the fœtus it is of a reddish brown; but the colour may be much altered, particularly at the posterior part, in consequence of the accumulation of blood from the position of the body on the back. To the touch, the lung is soft, light, and yielding, and when in a healthy state and contains air, it crepitates under pressure, since the air is forced through the delicate cells that contain it. The specific gravity of these organs is less than that of any other part of the body, and when

Root of the Lung.

Relations of the Vessels of the Root.

Colour.

Consistence.

Specific Gravity.

a portion is placed in water it floats on the surface, by reason of the air confined in the cells; but the lung of a fœtus that has not respired, and that of an adult, rendered impervious to air by disease, readily sink in this fluid. The structure of the lung will be examined subsequently to its removal.

Dissection. Remove with care the cellular membrane from the arch of the aorta, and from the large vessels connected to the heart, and seek some very small nerves — the cardiac — which are contained in it, and enter the chest through the upper aperture. On the arch of the aorta are two large nerves, — the phrenic and pneumo-gastric of the left side; the former, the more superficial of the two, descends in front of the root of the lung, and the pneumo-gastric behind it. Between these, and superficial to the arch, is the left superior cardiac nerve that descends to the superficial cardiac ganglion placed in the concavity of the arch, and it should be followed through the fibres of the pericardium to this plexus. Two other small nerves — the cardiac of the pneumo-gastric — enter the upper part of the chest, and each lies internal to the brachio-cephalic vein of the same side, but posterior to it; the right descends along the brachio-cephalic artery, and ascending part of the arch of the aorta, to the heart; and the left crosses the arch, internal to the superior cardiac of the left side, to join the superficial cardiac plexus, and supply the heart. Along the right side of the brachio-cephalic artery is the superficial cardiac nerve of the right side, which turns behind this vessel to join the deep cardiac plexus, and sends some filaments forwards, on the arch, to join with the right cardiac branch of the pneumo-gastric. The nerves to the heart, from the plexus, are followed with difficulty through the fibrous pericardium, because of their softness: the plexuses on the surface of the heart, with the coronary vessels, will be dissected when the pericardium is opened.*

Cardiac Nerves of the Pneumo-gastric. The *cardiac nerves of the pneumo-gastric*, one on each side, arise from the trunks of the nerves in the lower part of the neck, and enter the thorax through its upper aperture, lying internal to the brachio-cephalic vein of the same side.

Right Nerve. The *nerve of the right side* enters the chest in the angle of union of the subclavian and carotid arteries, but superficial to the subclavian, and descends along the brachio-cephalic artery, but beneath the left brachio-cephalic vein, to the ascending part of the arch of the aorta; the nerve then divides into many small filaments that are continued to the heart in close contact with the coats of the aorta, and some of these join the superficial cardiac ganglion, as well as the superficial cardiac nerve, of the right side, from the sympathetic. It sends back a branch round

* If the subject should be very fat, it is almost impossible to dissect the small cardiac nerves.

the brachio-cephalic artery, to enter the deep cardiac plexus beneath the arch. The filaments of distribution of this nerve, though minute, are very numerous, and cover the ascending part of the aorta with their ramifications: they are destroyed more or less by injecting the subject. The *nerve of the left side* enters the thorax by its upper aperture, and appears beneath the left brachio-cephalic vein near its commencement, it then descends in front of the left carotid artery, crosses the arch, nearer the middle line than the superficial cardiac nerve of this side, and in its concavity joins, chiefly, the superficial cardiac ganglion around the ductus arteriosus. Left Nerve.

The *cardiac nerves* of the sympathetic are derived from the ganglia of the part of the nerve in the neck, and are three on each side, — a superior or superficial, a middle, and an inferior; they are larger than those from the pneumo-gastric, enter the thorax through its upper aperture, and unite in either the superficial or the deep cardiac plexus, from which branches proceed to supply the heart. It is only the superficial nerve of each side that is now seen, and the left joins, more especially, the superficial cardiac plexus; but the remaining, which join the deep plexus, will be dissected, with this, behind the arch of the aorta. Cardiac Nerves of the Sympathetic.

The *superficial cardiac nerve*, of the right side, enters the thorax in front of the subclavian artery, descends along the brachio-cephalic artery, and, at the arch of the aorta, divides into branches; some of these turn in front of the arch, supply filaments to it, and some join with the cardiac nerve of the pneumo-gastric, whilst others may be followed to the heart; but the trunk of the nerve turns beneath the arch, and ends in the deep cardiac plexus. Right Superficial Cardiac.

The *superficial cardiac nerve*, of the left side, lies between the left carotid and subclavian arteries as it enters the chest, is internal to the pneumo-gastric, and behind the brachio-cephalic vein; it then passes downwards between these two vessels, and, near the arch, gives backwards a deep branch to join either the middle or inferior cardiac of this side. The nerve then crosses the arch between the position of the phrenic and pneumo-gastric, perforates the pericardium, and ends in the superficial cardiac ganglion in the concavity of the arch, joining with the cardiac branch of the left pneumo-gastric. Left Superficial Cardiac Nerve.

The *cardiac plexus* in the thorax, like the solar plexus in the abdomen, is the centre of union of the branches of the sympathetic nerve, from which filaments are distributed to supply the viscera of the cavity; this centre, like the analogous plexus in the abdomen, is joined by nerves from a portion of the sympathetic system external to the cavity, and it is also placed in front of the spinal column, — the trunk or gangliated portion of this nerve lying by the sides of the vertebræ. The cardiac nerves unite together superficial to the great vessels, and beneath them: the union in front of the pulmonary artery is the Cardiac Plexuses

superficial cardiac ganglion or plexus, and that beneath, the deep plexus.

Superficial Ganglion or Plexus.

The *superficial cardiac ganglion* or plexus is situated in the concavity of the arch of the aorta, between it and the ductus arteriosus, or continuation, in the fœtus, of the pulmonary artery to the arch of the aorta. It presents a ganglion in this spot, is joined by the superficial cardiac nerve of the left side, and occasionally by some filaments from the superior nerve of the right; by the cardiac nerve of the left pneumo-gastric, and by a large nerve that comes forwards to it, from the deep plexus, round the ductus arteriosus. The branches of this plexus descend on the pulmonary artery and aorta to the heart, and join the coronary plexus of nerves that accompanies the right coronary artery; they unite, in their descent, with branches that come forwards, from the deep plexus, around the trunk and left branch of the pulmonary artery to form the coronary plexus. Some filaments spread laterally to the root of the left lung, and enter the anterior pulmonary plexus. These nerves are much destroyed in the injection of the body.

Pericardium.

The *pericardium* is a fibro-serous membrane which contains the heart, it is situated in the middle line of the thorax between the pleuræ, but it is directed more to the left, than to the right side. It is conical in form, the base below, on the aponeurotic portion of the diaphragm, and the apex, above and to the right side, is continued on the large vessels that leave the heart, or join it. On each side, the pericardium is covered by the pleura, is in contact with the lung, and is crossed by the phrenic nerve and its artery; but on the left side the lung projects more over it than on the right, and the nerve is bent, from a straight direction, around the projecting bag. The anterior part corresponds to the space in the anterior mediastinum, to the thymus gland, and to the sternum; and, on the left of the middle line, to the cartilages of the fourth, fifth, sixth, and seventh ribs. Its posterior surface forms the anterior boundary of the space between the layers of the posterior mediastinum, and is in contact with the parts contained within it. The outer or *fibrous layer* of the pericardium is very thin, consists of fibres that cross in different directions, and is closely united to the central tendinous structure of the diaphragm; the fibres are prolonged on the vessels that enter it above, and these are strongest on the aorta. The different vessels that pass to the heart perforate this layer of the membrane, but not the serous lining which is reflected around them; so that there is one aperture for the aorta; two for the branches of the pulmonary artery, and, in the fœtus, one for the ductus arteriosus; four for the pulmonary veins, one for the superior, and one for the inferior cava: this last vessel does not receive a sheath from the fibres, as the others, since it perforates the tendinous structure of the

Form and Relations.

Fibrous Layer.

diaphragm, and opens directly into the auricle. Lay open the pericardium for the serous lining which gives the smooth shining appearance to the inner surface of the fibrous layer, and to the surface of the heart over which it is reflected. The *serous layer* resembles the arachnoid membrane in the skull, and is so closely united to the fibrous, that its existence as a separate membrane is perceptible, only at its reflection from the aorta and pulmonary artery to the heart. If this layer be traced, it will be found to have a visceral portion reflected over the heart and a parietal, on the fibrous coat of the pericardium: thus, after lining the inner surface of the fibrous layer, it is reflected downwards on the great vessels of the base of the heart, viz. on the aorta, pulmonary artery, and superior or descending cava, but it envelopes in one sheath or fold the aorta and pulmonary artery, so that their contiguous surfaces are uncovered by serous membrane. On each side, the membrane is also reflected to the heart by the pulmonary veins; it then passes on the front of the heart to the apex, turns over it, covers the posterior part, extending upwards in a *cul-de-sac* between the entrance of the pulmonary veins into the left auricle, and it is finally reflected to the fibrous layer, and is continuous with the rest of the membrane. The inner surface of the pericardium is lubricated by a thin serous fluid which, in disease, collects in considerable quantity. The vessels to the pericardium are from the internal mammary, bronchial, and œsophageal arteries, and from the phrenic branches of the aorta.

Serous Layer.

Vessels.

The *heart*, the chief agent in the propulsion of the blood, is a hollow muscular organ divided into four compartments by septa. It is situated between the pleuræ, is enveloped in the pericardium, and is maintained in its position by the pericardium which incases it, and by the great vessels which are connected to it; but its position may be slightly altered by the state of the body, since the heart is lower in the erect, than in the recumbent posture, or it may be protruded more from its natural relations by the enlargement of any surrounding part. The form of the heart is conical, the base being directed upwards and to the right side, and the apex downwards and to the left; and its size is, normally, about as large as the closed hand of the individual, provided this be not disproportioned. The anterior surface, formed by the ventricles, is somewhat convex, and is divided by a longitudinal depression, near the left side, into two unequal portions:—that to the right, larger than the other, corresponds to the right ventricle, and the part to the left of it, is formed by the left ventricle; the groove is situated over the partition between these or the septum ventriculorum, and lodges a branch of the left coronary artery, with its vein and nerves. The right ventricle occupies nearly the whole anterior surface, is prolonged upwards to the left side, and ends

Heart.

Situation.

Form.

Surfaces.

in a funnel-shaped portion, — the infundibulum, from which the pulmonary artery springs. The posterior surface is flat, and on it are seen not only the ventricles, but also the auricles above them, and a vertical depression, corresponding to the septum, extends from the base to the apex, and divides it into a right and a left portion; this line of separation is not usually in the centre between the ventricles, but is situated nearer the right than the left side, so that the left ventricle forms the greater portion of this surface. Between the auricles and the ventricles is a horizontal groove, placed transversely across this surface, and it contains the coronary vessels, which send downwards some branches towards the apex, in the groove between the ventricles. The right border is thin, and is formed by the right ventricle; the left is thick, convex, and consists of the fibres of the left ventricle. Into the apex the tip of the left ventricle alone enters, and it touches the thorax in the interval between the fifth and sixth ribs. To the base of the heart or of the ventricles are connected the large pulmonary artery and aorta.

Divisions. The heart consists of two portions — the auricles — situated at its base, and seen by raising this organ, and of two ventricles which form the greater part of its bulk, and extend to the apex. Each auricle receives blood from the veins that open into it, and transmits the same into the ventricle of that side; and this is then passed, from the right ventricle to the lungs, by means of the pulmonary artery, and from the left, to the general system, through the aorta. A septum or partition divides the right from the left auricle, as well as the right from the left ventricle, so that there are two single hearts, one on each side, consisting of an auricle and ventricle, and having its own veins, by which the blood is brought to it, and its artery, by which this is carried away; the right side of the heart receives impure or dark blood from the system, and distributes it to the lungs through the pulmonary artery, but the left is supplied by pure or red blood from the lungs, and sends it over the system by the aorta. The

Auricles. auricles, so named from the resemblance that the auriculæ, or processes that project forwards from them, have to dogs' ears, are placed at the base of the heart, almost altogether behind the right ventricle and the two large arteries that arise from the heart, so that only the auriculæ are at first seen on the sides of the vessels. They are two in number, a right and left, have walls much thinner than those of the ventricles, and are separated from the ventricles, below, by a horizontal groove, which is interrupted, in front, by the projection upwards of the right ventricle and pulmonary artery; behind, they are separated from each other by a vertical groove, but, before, the aorta and pulmonary artery lie in the interval between them. The right auricle, the larger of the two, is placed nearer the front of the

heart than the left; it lies on the right pulmonary veins, and receives, above, the superior cava, below, the inferior cava, and behind, the coronary vein; its auricula projects forwards to the right of the pulmonary artery. The left auricle, lying deeper than the right, in the concavity of the arch of the aorta, receives four pulmonary veins, two from the left side at its extreme left, and two from the right, at its other side; the aricula of this cavity, smaller than the right, appears on the left side of the aorta. The ventricles constitute the greater part of the heart, forming entirely the anterior surface, the borders, and the greater part of the posterior surface; they are much stronger, thicker, and more muscular than the auricles, below which they are placed; and there is a right and a left cavity, as in the auricles, separated from each other by a partition, whose position is indicated by the grooves in front and behind; and the sulcus, on the surface, between them and the auricles, marks the separation between each auricle and ventricle. Ventricles.

Before the heart is opened for the dissection of its cavities, trace the coronary vessels, and the coronary plexuses of nerves, in the grooves on the surface of this organ, and in the cellular membrane that surrounds them when the serous covering is removed: the nerves are very small and not easy to follow, and if the arteries are injected they will be more readily dissected. Dissection.

The *coronary arteries*, the first branches of the aorta, are two in number, and arise from this vessel close above the semilunar valves; they are called, from their position, right and left coronary. Coronary Arteries.

The *right coronary artery*, larger than the left, comes forwards, from the aorta, between the right auricle and the pulmonary artery, it then descends obliquely to the right side, in the horizontal groove between the right auricle and ventricle, turns to the back of the heart, and, opposite the vertical sulcus on its posterior surface, divides into two branches:—one continues the direction of the artery in the circular groove between the left auricle and ventricle, to join an anastomosing branch from the left coronary; the other runs vertically to the apex of the heart, in the sulcus separating the ventricles, to anastomose also with other branches of the left coronary artery. As the artery lies in the groove between the cavities of the right side it gives, upwards, branches to supply the auricle, downwards, others to the ventricle, and one of these, very large, runs on the anterior surface of the ventricle, towards its right border. Right.

The *left coronary artery* is directed downwards, and to the left side, behind the pulmonary artery, and appears between this vessel and the left auricle; it continues its direction to the left, and divides, opposite the sulcus on the front of the heart between the ventricles, into two branches, like the right artery: the descending branch runs, in the groove on the anterior surface between the ventricles, to the apex, to anastomose with the Left.

descending branch of the right; and the circular branch or the continuation of the artery winds to the back of the heart, in the sulcus between the divisions of the left side, and anastomoses with the similar branch from the right coronary. This artery sends down muscular branches to supply the left ventricle, and gives others to the left auricle.

Coronary Vein. There is but one *coronary vein* to the two arteries; its radicles commence at the terminations of the branches of the arteries, and unite together, forming a large tube, which lies in the sulcus separating the auricles from the ventricles, and opens into the back of the right auricle, to the left of the aperture of the inferior cava.

Coronary Plexuses. The *coronary plexuses* of nerves are two, an anterior and a posterior. The *anterior* is formed by descending branches from Anterior. the superficial cardiac ganglion, which join the nerves that come forwards, from the deep plexus, between the pulmonary artery and the aorta. The plexus of nerves at first accompanies the right coronary artery, giving filaments to the right auricle, but the filaments afterwards leave it to be distributed to the substance of the ventricle. The *posterior plexus*, derived altogether Posterior. from the deep cardiac plexus, is found with the left coronary artery; it sends branches with it along the groove in front of the heart, and some round to the back, with the other branch of the artery; these are supplied to the left ventricle and auricle.

Dissection. The examination of the cavities of the heart may be made in the course which the blood follows in traversing them, viz. right auricle, right ventricle, left auricle, and left ventricle.* Open the right auricle by a vertical incision from the entrance of the superior cava to near the inferior, and about half an inch from its free margin; carry another into the auricula, remove the coagulated blood, and raise up the flaps during the examination of the cavity.

Right Auricle. The *cavity of the right auricle*, which serves for the reception of the blood from the system, is of a somewhat conical shape, compressed before and behind, the base of the cone being upwards and to the right side, forming a projection between the two cavæ, and the apex downwards and to the left, at its junction with the right ventricle. The anterior part or wall is thin, and is occupied by the auricula, and the posterior forms the septum auricularum, for this cavity lies rather in front of the left auricle; its interior presents many apertures, but the surface is not very irregular. In the base of the cone are the openings of the two venæ cavæ which return the blood to the auricle, and in the apex is the aperture from the right auricle into the

* This is to be done whilst the heart is in its position in the thorax; for the removal of it destroys the anatomy of the auricles, and the nerves and vessels to be afterwards dissected.

right ventricle, and through it the blood passes from the cavity; between the inferior cava and the opening into the ventricle, and in the lower part of the auricle, is the small aperture of the coronary vein, which is guarded by a thin fold of the lining membrane — the *valve of Thebesius* — which prevents the regurgitation of the blood from the cavity. The orifice of the superior cava is directed downwards and forwards into the front of the auricle, and is not provided with any membranous valve; but the aperture of the inferior cava, situated in the lowest part of the auricle, and near the septum, is directed inwards and backwards, and its orifice is marked by the thin remnant of the *Eustachian valve* — a structure that is large in the fœtus, and serves the purpose of directing the current of blood, brought by the cava, through the auricular septum into the left auricle. This valve is situated in front of the inferior cava, one surface looking forwards, the other backwards, its lower margin, convex, is fixed to the front of the vein, and the upper, which is free, looks to the cavity; by its left extremity, it is connected to the annulus or rim that surrounds the depression of the fossa ovalis on the posterior wall, and by its right, it joins the auricle on the other side of the vein; the free margin of this valve is often reticulated. Between the two cavæ the cavity is dilated, and the wall is sometimes slightly thicker in this spot, giving rise to an elevation in the interior, or the *tuberculum Loweri*. The aperture of communication between the auricle and ventricle will be seen, in examining the right ventricle, to be also provided with valves to prevent regurgitation. In the anterior boundary or wall is the *pouch of the auricula*, and near it, and in its interior, are the *musculi pectinati* or muscular fibres of the auricle, which cross each other, project into the cavity, and occasion the irregular surface of this part. The posterior or left boundary, or the septum auricularum, is marked by the depression of the *fossa ovalis*, or the remains of an aperture — the *foramen ovale* — by which the right and left auricles communicated before birth; this depression is situated nearer the inferior than the superior cava, and is continuous below with the cavity of this vein; in the adult, the opening is closed by a thin septum which is often perforated by one or more apertures in its upper part. An elevated ring of muscular fibre — the *annulus of Vieussens* — surrounds the fossa, except below; it is most prominent above and to the inner side, and is joined, below, by the left extremity of the Eustachian valve. On this part of the auricle, between the fossa ovalis and the opening of the superior cava, are many small apertures which are supposed to be the orifices of small veins, and are named *foramina Thebesii*. In the adult, the blood, received into this cavity by the veins, is passed into the right ventricle by the aperture into it, or the right auriculo-ventricular opening, but, in the fœtus, there are two

Aperture of the Coronary Vein.

Valve of Thebesius.

Aperture of the Superior Cava; and of the Inferior.

Eustachian Valve.

Tuberculum Loweri.

Auricula and Musculi pectinati.

Fossa ovalis.

Annulus.

Foramina Thebesii.

distinct currents crossing in the auricle:—one, of pure blood, from the inferior cava, which is directed, by means of the channel formed, at this period, by the hollowing out of the septum and the extent upwards of the Eustachian valve, into the left auricle by the foramen ovale; the other current of impure blood is brought by the superior cava from the head and neck, and upper extremities, descends in front of the descending one, and enters the right ventricle by the right auriculo-ventricular aperture.

Dissection. Take hold of the right ventricle, and make an incision along both its anterior and posterior surface, near the septum between it and the other ventricle, but do not extend them through the partition between it and the auricle of the same side; raise the V-shaped flap that is formed, and elevate the apex of the heart so as to look into the cavity from below.

Right Ventricle. The *cavity of the right ventricle* is of a conical or triangular form. The apex below reaches to the right border of the heart, but does not extend to the apex which belongs to the left ventricle and fibres of the septum; the base, situated above and looking towards the right, is sloped off obliquely downwards, and to this side, and is perforated by two apertures, the one to the right is the right auriculo-ventricular, and the one to the left, situated much higher, is the mouth of the pulmonary artery. The anterior and right wall of the ventricle is thin, and forms the greater portion of the anterior surface of the heart, and the posterior and left, or the septum ventriculorum, is thick, and separates this cavity from the left ventricle. The inner surface is very irregular, in consequence of the projections of the muscular fibres or *carneæ columnæ*, which cross each other in different directions, and leave intervals between the elevations; the greatest number of these prominences are found on the anterior wall and lower part of the septum, but near the aperture of the pulmonary artery the surface of the cavity is smooth. There are three kinds of the carneæ columnæ found in the ventricles; one set is prominent in the cavity, without being separate from the wall, these are therefore attached in their whole length, and are seen for the most part on the septum; the second set, smaller than these, form flat bands which are free in the centre, and are attached to the wall of the cavity, chiefly to the anterior, by the two extremities; and the third set, much the largest, united to the wall of the ventricle by one extremity only, project into the cavity, forming almost separate muscles, and end in a rounded or bifid extremity, to which are attached the chordæ tendineæ of the valves of the auricular opening; these are sometimes called the *muscles of the heart*. The *right auriculo-ventricular opening* is situated in the base of the ventricle, to the right of that for the artery, or next the circumference of the heart; it is larger than the orifice of the artery, and is oval in figure; the line of separation between the auricle and ventricle is marked by a white fibrous band which surrounds it, and determines its form;

Carneæ Columnæ.

Right Auriculo-ventricular Opening.

guarding the aperture, to prevent the reflux of the blood into the right auricle, is a membranous valve which projects into the cavity of the ventricle, is serrated or divided into points at its lower margin, and to these are attached small tendinous cords—the *chordæ tendineæ*—to unite it to the carneæ columnæ or muscles of the ventricle. It is constituted by a fibrous structure, derived from the circumference of the opening, which is covered by the thin lining membrane of the heart; and from the division of its lower margin into three points or portions, it is named *tricuspid*, but these divisions do not extend its whole depth. The anterior portion of the valve corresponds to the anterior wall of the ventricle, and is fixed, by its tendinous cords, to the carneæ columnæ situated on this part; the posterior, very short, joins by its tendinous processes, the septum of the ventricles on which it is placed; and the left portion, the largest and most moveable, is situated between the apertures of the auricle and the artery; its borders look forwards and backwards, the anterior being connected to one of the carneæ columnæ on the front or moveable part of the ventricle, and the posterior to the upper part of the septum: the tendinous cords of attachment are united to its borders. When this valve is raised by the blood, it closes the aperture during the contraction of the ventricle, and opposes the regurgitation into the auricle; whilst the chordæ tendineæ arrest the protrusion of the valve, by the blood, into the same cavity. The *aperture of the pulmonary artery* will be seen by extending the anterior incision into it; it is situated to the left of the auriculo-ventricular opening, and much higher than it, close to the septum of the ventricles, and in front of the orifice of the aorta, and it is separated from the muscular substance of the heart by a fibrous band which surrounds it; it is also provided with three small *semilunar* or *sigmoid valves*, which are attached, by one margin that is convex, to the circumference of the aperture, and by the other, which is free, they are directed to the centre of the artery. Each valve is convex downwards to the ventricle and concave to the artery, and is applied to the coat of this vessel so as to resemble, in form, a swallow's nest; each is thin and transparent, contains some fibrous membrane in its interior, and is covered by the lining membrane of the arteries; in the centre of the free border is a thickening and slight projection,— the *corpus arantii*,— better seen in the aorta. Whilst the blood is passing from the ventricle to the lungs, the valves are placed against the sides of the artery, but when the elasticity of the vessel acts on the blood, they are thrown down, touch each other in the centre of the artery, and stop the course of the blood towards the ventricle.

Chordæ tendineæ.

Tricuspid Valve.

Opening of the Pulmonary artery.

Semilunar Valves.

Corpus arantii.

The *pulmonary artery*, a short thick trunk, conveys the blood from the right side of the heart to the lungs; it commences in the right ventricle and extends upwards and to the left side for

Pulmonary Artery.

about one inch and a half, enclosed in the pericardium, and when it has passed beyond the aorta it gives a branch to the right lung—the right pulmonary artery; and the trunk then divides into the left pulmonary, to supply the left lung, and the ductus arteriosus, which is now an obliterated cord, and connects this vessel to the arch of the aorta. The trunk of the artery is connected to the heart, externally, by the pericardium, internally, by the lining membrane of the vessel and heart, and between these by the middle coat of the artery, which presents, below, three convex portions, to which are attached fibrous processes from the fibrous zone that surrounds the opening into the vessel; in its course it is contained in the pericardium, it lies on the aorta, and on each side of it is the coronary artery and auricula. This vessel conveys dark or impure blood to the lungs, and is the only exception, in the body, to the general law of arteries containing red or pure blood. In the fœtus the ductus arteriosus, which is now an obliterated tube, is the continuation of the pulmonary artery, is larger than either of the branches to the lungs, and joins the concavity of the arch of the aorta, rather beyond the origin of the left subclavian artery from its convexity. Its use at that period is to convey the blood of the pulmonary artery into the aorta, below the origin of the vessels for the head and neck and upper extremities, in order that it may pass to the placenta by the hypogastric arteries, because the lungs, which are not readily permeated by blood, do not perform for the fœtus the process of purification; but, after birth, when the function of the lungs is established, the current of the blood is directed into its new channel by the pulmonary arteries, the ductus arteriosus is gradually obliterated, and the only remains of it in the adult is a fibrous cord.

Right branch. The *right branch* of the pulmonary artery, longer than the other, crosses through the arch of the aorta, and divides, at the lung, into its branches of distribution;

Left. the *left branch*, very short, runs almost transversely outwards to the lung, in front of the aorta and left bronchus, and in this organ divides into branches. The special anatomy of these vessels is seen with the root of the lung.

Dissection. To expose the cavity of the left auricle, raise the apex of the heart, make a transverse incision into it from the veins of one side to those of the other, and another forwards into the auricula.

Left Auricle. The *cavity of the left auricle* is smaller than the right, its walls are thicker, and it performs, for the left side of the heart, the same office that the right does for the other, since it receives the blood by the pulmonary veins, and passes it into the ventricle; but the blood instead of being dark-coloured is of a florid hue. Its shape is irregularly conical, the base, or wider part to the spine, receives the openings of the pulmonary veins, two on each side, and the apex, directed downwards and forwards to

the ventricle, presents the left auriculo-ventricular aperture; the last orifice, only, has valves. On the anterior wall is the *pouch* of the *auricula*, and the aperture to it is narrower than on the right side; in the interior of the auricula, as well as around its circumference, are the *musculi pectinati*, but they are not so well marked as in the right auricle. In the septum between this auricle and the right is a superficial fossa, — the *remains* of the *foramen ovale*, — but it is considerably above the depression in the right auricle, since the foramen of communication is an oblique canal in the septum, instead of a mere aperture; and through it, in the fœtus, the pure blood was transmitted from the right to the left side of the heart: this is obliterated after birth.

Auricula.

Musculi pectinati.

Remains of the Foramen ovale.

The left ventricle may be opened by an incision, near the septum, along its anterior as well as its posterior surface, by which a V-shaped flap will be formed similar to that of the right side: raise the heart to see its interior.

Dissection.

The *cavity of the left ventricle* is also conical, the apex is below and forms the apex of the heart, and the base, above, is sloped slightly downwards from right to left, or in a direction the opposite to that of the other side; and in it are the openings of the aorta and left auricle. The walls are much thicker than in the right ventricle, the inner surface is less irregular, and it is smooth near the opening of the aorta. There are three sets of the *carneæ columnæ;* but those which are free by one extremity in the ventricle, and receive the *chordæ tendineæ*, but attached by the other to the wall, constituting the muscles of the heart, are larger in this ventricle than in the right, and are only three in number. The *left auriculo-ventricular opening*, smaller than the right one, and longest in the transverse direction, is situated to the left of the orifice of the aorta, but so close to it, that only a thin fibrous band, which gives attachment to the valve, is placed between them; it is also provided with a membranous valve which projects into the cavity of the ventricle, is attached in the same manner to a fibrous ring surrounding the aperture, but it differs from the right in being stronger, and of greater length, in having firmer and more numerous chordæ tendineæ, and in being divided into two instead of three portions; and from its supposed resemblance to a mitre, it has been named *mitral valve*. The margins of its portions are directed forwards and backwards, and the *chordæ tendineæ* are connected to them; and the valve is attached in front, by the tendinous cords, to only one columna carnea, but, behind, to two. The right division of the valve, or that placed between the openings of the aorta and the auricle, is larger and looser than the other, and, at its attachment above, is connected to the adherent border of one of the sigmoid valves of the aorta, which alone intervenes between the two apertures in the base; the use and action of

Left Ventricle.

Carneæ Columnæ.

Left Auriculo-ventricular Opening.

Mitral Valve.

Chordæ tendineæ.

Opening of the Aorta.

this valve are altogether similar to the right or tricuspid. The *opening of the aorta*, to the right of the auriculo-ventricular, and higher than it, lies close to the septum, whilst the auricular aperture is nearer the circumference of the heart. It may be seen by slitting up the side of the vessel without dividing the pulmonary artery; it is larger than the pulmonary artery, is situated close beneath it, and is also connected to the ventricle by the same means. In the interior are three *semilunar* or *sigmoid valves*, larger and stronger than in the pulmonary artery, but they have the same structure, attachments, and functions: the *corpus arantii* is better marked in these valves; on the outer side of each, the aorta is dilated into a small pouch which is called the *sinus of Valsalva*. Above the free margins of two of the valves are the *apertures* of the *coronary arteries*, and these are situated so high that, when the valves are thrown back against the wall of the artery by the blood passing into it, they are not closed by the membranous folds.

Semi-lunar Valves.

Corpus arantii.

Sinus of Valsalva.

Apertures of the Coronary Arteries.

Position of the Apertures of the Heart.

The openings into each ventricle have been now seen to be two, one from its corresponding auricle, and one into its artery; the aperture of the artery is close to the septum, and higher than the auricular opening which is situated near the outer part of the heart; so that the different apertures would have this relation to each other, from the right side of the heart to the left: right auriculo-ventricular opening, pulmonary artery, aorta, and left auriculo-ventricular aperture; but, as, in the natural position, the auricles are posterior to the ventricles, their apertures must be behind those of the arteries which issue from the centre and fore parts of the ventricles. The orifices of the arteries are separated only by the partition between the ventricles, since, originally, they constituted but one tube which has been subsequently divided into two by the septum; the opening of the pulmonary artery is in front of the aorta.

If the dissector should wish to study the fibres, which are destroyed in this heart, let him procure the heart of an ox or a sheep.

Arch of the Aorta.

The *aorta*, or great artery by which the blood is conveyed from the heart to the different parts of the body, forms an arch in the first part of its course, from which the vessels for the head and neck are given off, and this portion of it is to be now examined. The aorta commences at the right side of the left ventricle, beneath the pulmonary artery, and opposite the junction of the cartilage of the fourth rib of the left side to the sternum; the artery then ascends, to the right, behind the sternum, as high as the upper border of the cartilage of the second rib of this side; it now turns almost horizontally backwards, and to the left, to reach the left side of the body of the second dorsal vertebra, and finally descends, vertically, to the left side of the body of the third dorsal vertebra, forming thus the

arch of the aorta. The *first* or *ascending portion* of the arch, which reaches as high as the second rib, is contained nearly altogether in the pericardium, and is covered, at first, by the pulmonary artery, but as these vessels diverge to different sides, the aorta is soon uncovered; above this, the artery lies behind the sternum, and, near its termination, the brachio-cephalic vein of the left side crosses it. On the right side is situated the descending cava, on the left the pulmonary artery, and behind it is placed the right division of this vessel. This portion of the arch is oftentimes dilated, when it is named the great sinus of the aorta: it gives off the two coronary arteries. The *second* or *transverse* part passes behind the sternum to the body of the second dorsal vertebra, and is crossed by the phrenic and pneumo-gastric nerves, and the superficial cardiac of the left side; it lies on the trachea, above its bifurcation, as well as on the œsophagus, thoracic duct, and recurrent nerve of the left pneumo-gastric. From the upper border arise the three large vessels for the supply of the head and neck; the brachio-cephalic, the largest, to the right, the left subclavian to the left, and between them the left carotid: to the concavity of this portion, near its termination, the ductus arteriosus is attached. The *third* or *descending* part, which terminates the arch at the lower border of the body of the third dorsal vertebra, is very short, it lies between the vertebra and pleura, and is in contact with the œsophagus and thoracic duct, on its right side. In the concavity which the arch forms, are contained the left auricle of the heart, and root of the left lung, and deeper than this, as seen in the posterior mediastinum, the œsophagus and thoracic duct, with a mass of conglobate bronchial glands; and, passing through the arch, are the recurrent nerve, the right branch of the pulmonary artery to the right lung, and behind this the left division of the trachea. The branches that usually arise from the arch of the aorta are the two coronary, and the three arteries from the transverse part; but the number of its branches may vary in consequence of the left vertebral artery arising from it between the left carotid and left subclavian; or the right subclavian may arise, as a separate trunk, from the left side of the arch, in which case it will have to cross the spine, either before or behind the œsophagus, to reach the right side of the neck. The two coronary arteries have been dissected.

First part.

Second part.

Third part.

Branches.

The *brachio-cephalic* artery, the most anterior, and largest of the branches from the transverse part of the arch, is a thick trunk, about one inch and a half in length, which ascends to the right side, and divides, opposite the right sterno-clavicular articulation, into right carotid and right subclavian arteries. In this extent it is covered by the first piece of the sternum, and origins of the sterno-hyoid and sterno-thyroid muscles, and by the left brachio-cephalic vein which crosses it, below, to join the right

Brachio-cephalic Artery.

brachio-cephalic in the superior cava. The artery at first lies on the trachea, but as it ascends it lies to the right side of that tube, and is placed over the longus colli muscle, though separated from it by a cellular interval; on the right side, is the right brachio-cephalic vein and phrenic nerve, and on the left the trachea; and the cardiac nerves of the right side descend in relation with this artery. The point in the neck to which the vessel reaches, before dividing, is very variable in different individuals; no collateral artery arises from the brachio-cephalic, as a constant occurrence, but there is oftentimes found a small branch—the *middle thyroid artery*—for the thyroid body. Its terminal branches are seen in the dissection of the neck.

Middle Thyroid.

Left Carotid in the Thorax.

The *left carotid artery*, arising from the arch of the aorta, whilst the right comes from the brachio-cephalic trunk opposite the sterno-clavicular articulation, is longer than that of the right side by the portion which intervenes between the arch and sterno-clavicular articulation, and it has different relations up to this point, but afterwards both have the same in the neck. The artery ascends, obliquely, to the left sterno-clavicular articulation, being crossed by the left brachio-cephalic vein, and situated behind the sterno-hyoid and thyroid muscles, the first piece of the sternum, and the remains of the thymus gland; it lies on the trachea, but as it ascends it passes to its left side, and is placed over the œsophagus which bends to the left side of the neck, and over the thoracic duct and vertebral artery. To the outer side is the pneumo-gastric nerve which lies between it and the left subclavian, with one or more cardiac nerves; and to the inner, the trachea which projects more, near the sternum.

Left Subclavian in the Thorax.

The *left subclavian artery* arises from the arch of the aorta opposite the second dorsal vertebra, but the right springs from the brachio-cephalic, opposite the sterno-clavicular articulation, and it must therefore differ from the right subclavian in its course to the first rib, in length, direction, and relations. This part of the vessel extends from the arch, to the margin of the first rib, ascends almost vertically from the chest, being closely enveloped by the left lamina of the pleura, which enters into the mediastinum, and separates it from the lung; but it is too deep in the chest to have any relation to the sternum and the muscles which arise from this bone, and it is posterior to the left brachio-cephalic vein. The artery lies on the trachea and recurrent nerve, then on the œsophagus which projects to the left of the trachea, on the thoracic duct which crosses beneath it, and is placed, higher in the neck, between the carotid and subclavian arteries, and above this it is situated over the body of the first dorsal vertebra, but at some distance from it, and rests on the last cervical ganglion of the sympathetic; to the inner side is the trachea, and the œsophagus and thoracic duct, above where they are crossed by the vessel, together with the pneumo-gastric and cardiac

nerves, and the left carotid artery, which are parallel but more anterior than it; and to its outer side is the pleura and the lung.

The *brachio-cephalic veins* are two in number, a right and a left, and each is formed behind the sternal extremity of the clavicle, by the union of the subclavian and internal jugular veins. The *right vein*, about one inch and a half long, descends, vertically, on the right side of the brachio-cephalic artery, as low as to the arch of the aorta, and ends by joining the left in the superior or descending cava. It is in contact with the pleura, and is crossed, near the upper aperture of the chest, by the internal mammary artery which passes forwards to the side of the sternum; along its outer side is the phrenic nerve, and beneath it are the pneumo-gastric and cardiac nerves. This trunk receives the vertebral and deep cervical veins, and sometimes the internal mammary, and inferior thyroid of this side. The *left vein* is much longer than the right, and is directed obliquely downwards and inwards to its junction with it. It crosses behind the thymus gland, the sternum, and the muscles attached to it; and is crossed by the internal mammary of this side; it lies upon the three large arteries that ascend to the head, as well as on the pneumo-gastric, phrenic, and cardiac nerves, that appear beneath its lower border. This vein is joined by the vertebral, deep cervical, inferior thyroid, and the internal mammary of this side; in addition to this, by some phrenic, thymic, and pericardiac veins, from the space containing the pericardium and heart, and sometimes by the superior intercostal, which receives the left bronchial, and crosses the arch of the aorta to open into it.

Brachio-cephalic Vein. Right. Branches. Left. Branches.

The *superior* or *descending cava*, resulting from the union of the two brachio-cephalic trunks, is the vein by which the blood is returned from the upper parts of the body to the heart. It commences at the highest point of the arch of the aorta, or opposite the cartilage of the second rib of the right side, then descends slightly backwards, perforates the pericardium, and opens into the upper part of the right auricle. As the vein is contained, with the other large vessels, in the space between the layers of the pleura forming the mediastinum, it is in contact externally with the pleura which separates it from the lung, and with the phrenic nerve that lies along it, internally with the ascending aorta; in front of it are the remains of the thymus gland, and the wall of the thorax; and, behind, is the right branch of the pulmonary artery. It is joined by the azygos vein when about to perforate the pericardium, and, often, at its commencement, by the right inferior thyroid and internal mammary veins, as well as by some small mediastinal branches.

Superior Cava. Branches.

The *phrenic nerve*, one of the large nerves crossing the arch of the aorta, is one of the deep branches of the cervical plexus, and extends to the diaphragm: it has been called internal

Phrenic Nerves.

Right. respiratory nerve. The *right phrenic* enters the upper aperture of the thorax behind the subclavian vein, and in front of the internal mammary artery which it crosses; it then descends on the right side of the right brachio-cephalic vein and superior cava to the pericardium, along which it continues to the dia-
Left. phragm, anterior to the root of the lung. The *left nerve* has the same relation to the subclavian vein, and internal mammary artery, as it enters the chest; it descends on the outer side of the left carotid artery, and over the left pneumo-gastric, to the arch of the aorta, crosses the arch to the right of the superficial cardiac nerve and the pneumo-gastric, and passes over the trunk of the pulmonary artery to reach the pericardium and the diaphragm; but it is remarkable in turning round the heart which is directed to this side, and thus this nerve is longer than the right; each is accompanied by the phrenic artery, a branch of the internal mammary. This nerve does not give off its branches till it approaches the diaphragm, though it is often joined, in the upper part of the thorax, by a small branch from the fifth and sixth nerves of the brachial plexus; near the diaphragm it divides into its final branches of distribution: some of these run, for a short distance, between the pleura and the diaphragm before perforating the muscle, but they all finally pass through it, supply the muscle, and join on the under surface with filaments of the sympathetic.

Internal Mammary Artery. The portion of the internal mammary artery that lies by the side of the sternum was dissected from the outside, but the part of the artery that intervenes between its entrance through the upper aperture and the sternum, which was not then examined, is now exposed. The *internal mammary*, at its entrance into the thorax, is behind the first rib, and external to the brachio-cephalic vein, but as it runs obliquely inwards, round the upper aperture, to reach the sternum, it lies along this bone, and crosses, on the right side, the phrenic nerve and brachio-cephalic vein, and on the left, the brachio-cephalic vein of this side, the phrenic and pneumo-gastric nerves, and the left carotid artery: the artery now changes its direction, runs vertically downwards by the side of the sternum, and so reaches the wall of the abdomen.

Comes Nervi phrenici branch. The chief branch from this portion of the artery is the *comes nervi phrenici*, which arises from its upper part, and descends with the phrenic nerve, between the pleura and pericardium, to be distributed to the diaphragm. This artery is rarely injected down to the diaphragm.

Dissection. The pneumo-gastric nerve, on the right side, is seen passing over the side of the trachea to reach the posterior part of the root of the lung, and to expose the plexus it forms here, as well as some filaments to the front of the root, remove the pleura and cellular membrane; and seek some small fila-

ments of the sympathetic, that come from the ganglia by the side of the spine to the plexus; its further course on the œsophagus, in the space of the posterior mediastinum, will be brought into view by removing the pleura of the right side, when this lung is raised from its position by the side of the spine. After the left has crossed the aorta, it gives more filaments to the anterior pulmonary plexus, forms its posterior in the same manner, and can be followed on the œsophagus by raising the left lung, and taking away the pleura and pericardium that conceal it.

Pneumo-gastric Nerve.

The *pneumo-gastric nerve*, one of the three portions of the eighth cranial nerve, passes through the thorax in its course from the neck to the abdomen, and, like the phrenic, it differs in its course and relations on the two sides. The *right nerve* enters the thorax between the subclavian vein and artery, passes obliquely downwards and backwards over the side of the trachea, but posterior to the brachio-cephalic vein and phrenic nerve, to reach the interval between the trachea and œsophagus; the nerve then descends behind the root of the lung, expands and forms, by division into bundles of fibres, the posterior pulmonary plexus. From the lower part of the plexus two large branches issue; they run along the right side of the œsophagus, unite to form the continuation of the nerve, which descends behind the œsophagus, sending branches around this tube to unite with those of the left in the plexus gulæ, and passes with it, through the diaphragm, to be distributed to the posterior surface of the stomach. In its course through the thorax, the right is more posterior than the left. The *left nerve* enters the thorax behind the left brachio-cephalic vein, internal to the phrenic nerve, and close to the outer side of the carotid artery, descends over the trachea, in the interval between the left carotid and left subclavian arteries, and crosses behind the phrenic nerve; it now runs obliquely downwards and backwards over the origin of the left subclavian from the arch, and over the arch itself, enters beneath the root of the lung, and forms by dividing and spreading out the left posterior pulmonic plexus, which is larger than the right: one or two large branches leave the lower part of the plexus, and unite in the trunk of the left nerve, which is continued, on the front of the œsophagus, to the anterior part of the stomach.

Right.

Left.

Branches. Recurrent of the Right.

The first branch from the pneumo-gastric in the thorax, is the *recurrent* or *inferior laryngeal nerve*, which, on the right side, arises as soon as the trunk has entered the cavity, winds round the subclavian artery, and ascends in the neck, to be placed between the trachea and œsophagus, and this relation it maintains till it reaches the lyrynx: its distribution and relations are dissected in the neck. This branch on the left side arises opposite the lower border of the arch of the aorta, turns round the arch

Recurrent of the Left.

to its posterior surface, by crossing over the ductus arteriosus, and ascends on the trachea beneath the left subclavian artery, then between this tube and the œsophagus to the larynx, as on the right side. The nerve is connected, on both sides, by filaments, to the cardiac nerves of the sympathetic, the connection with the right being opposite the upper aperture of the thorax, and with the left behind the arch of the aorta; but the communication of the left nerve with the sympathetic is the most marked, since numerous large branches from it join the deep cardiac plexus: this will be seen with the dissection of the plexus.

Cardiac branches. The *cardiac branches* of the pneumo-gastric nerve of the right side pass in front of the trachea, and join with the cardiac nerves from the sympathetic, and some filaments are distributed to the œsophagus and back of the trachea, between which it is placed; these branches, on the left side, come from the recurrent nerve which has the same position as the trunk on the right. The

Anterior Pulmonary branches and Plexus. *anterior pulmonary branches*, the next in order from above downwards, arise rather above the root of the lung, and on the left side are more numerous, and larger than on the right; they descend to the anterior surface of the root, and join with branches of the sympathetic from the cardiac plexus, which pass horizontally outwards on the pulmonary artery, to form the *anterior pulmonary plexus*, from which branches are given off to the substance of the lung along the great vessels. The *posterior*

Posterior Pulmonary branches and Plexus. *pulmonary branches*, larger and more numerous than the anterior, arise from the *posterior pulmonary plexus*, which is situated behind the bronchus in the root of the lung, and is formed by the enlargement of the pneumo-gastric, which subdivides into numerous fibres, these are united into meshes, and accompany the bronchus into the substance of the lung. The plexus of the left side is larger than that of the right, and each is joined by some filaments which come forwards from the gangliated cord of the sympathetic, along the side of the spine. At the lower part of the plexus, some of its divisions unite to give rise to the trunk of the pneumo-gastric which descends to the stomach. The

Œsophageal and Plexus gulæ. *œsophageal branches*, the last from the pneumo-gastric in the thorax, arise from each trunk as it lies on the œsophagus, and pass backwards around this tube which they encircle, the branches of opposite sides joining on it; this plexiform arrangement is named *plexus gulæ*, and extends nearly to the diaphragm.

Dissection. The deep cardiac plexus is situated beneath the arch of the aorta, and consists of a right and a left portion in which the cardiac nerves of the sympathetic unite. To see the right portion and the nerves joining it, cut carefully across the arch of the aorta, above where it escapes from the pulmonary artery, if this should not have been done in the examination of its valves, and draw the arch well over to the left side; divide the cava

above the entrance of the azygos vein, and throw it down; this portion of the plexus in which the cardiac nerves of the right side end, is now exposed by the removal of cellular membrane, and the branches from it are to be traced downwards to the heart along the pulmonary artery, as well as outwards on the right branch of this vessel. For the dissection of the left portion of the plexus, and the recurrent and cardiac nerves of this side, that are connected to it, divide the arch, to the left of the junction of the ductus arteriosus with it, raise it upwards with the vessels arising from it, and, should it be necessary, divide the ductus arteriosus and left pneumo-gastric nerve; remove the cellular membrane, and some lymphatic glands which lie in front of the trachea, some of these may be indurated and enlarged, and situated in the midst of the nerves. Follow downwards to the heart, along the pulmonary artery, the nerves from this portion of the plexus, as well as some outwards, on the left branch of this vessel, to the pulmonary plexus.

Right middle Cardiac Nerve.

The superficial cardiac nerve, both on the right and left side, has been dissected, and the middle and inferior, of each side, are now exposed. The *middle cardiac nerve*, the largest of those of the right side, enters the chest in front of the recurrent nerve, but beneath the subclavian artery; it runs downwards and inwards in front of the trachea, is joined by branches from the recurrent or pneumo-gastric, and passes behind the arch of the aorta to end in the right or upper portion of the cardiac plexus. It is joined by filaments from the superior and inferior cardiac nerves.

Right inferior Cardiac Nerve.

The *inferior cardiac nerve*, of the right side, is placed beneath the subclavian artery in the upper aperture of the chest, and is united to either the recurrent or the pneumo-gastric nerve; it then descends on the trachea and behind the arch to the same part of the plexus. It generally unites with the middle cardiac nerve of this side.

Left middle Cardiac.

The *middle cardiac nerve*, of the left side, lies between the carotid and subclavian in entering the thorax, it continues in front of the trachea, but behind the arch to join the left portion of the plexus and the recurrent nerve: this is often absent.

Left inferior Cardiac.

The *left inferior cardiac*, variable in size, sometimes joins the middle, but, at others, runs as a separate branch to the plexus beneath the arch; it is usually joined, above the arch, by a branch from the superficial cardiac.

Deep Cardiac Plexus.

The *deep cardiac plexus*, or the portion of the sympathetic centre for the supply of the viscera in the cavity of the thorax, is situated between the trachea and arch of the aorta; it receives the cardiac nerves of each side, from the cervical ganglia, except the left superficial, and it consists of two plexiform bodies, a superior or right, and an inferior or left, and from these the branches descend to supply the heart, with its great vessels, and

Superior portion. the lungs. The *superior* or *right portion* is situated on the trachea, beneath the brachio-cephalic artery and arch of the aorta, and above the right division of the pulmonary artery; it results from the union, in a plexus, of the three cardiac nerves of this side, with branches from the pneumo-gastric, and with some filaments from the cardiac branch of the right pneumo-gastric, sent backwards round the brachio-cephalic artery: this has been named the great or deep cardiac plexus, and oftentimes there is a union by means of a ganglion. From its lower part the nerves descend to the heart, and the greater number, united into one or two large branches, pass in front of the trachea, but behind the arch, to the trunk of the pulmonary artery along which they descend to near the heart, and then divide into numerous filaments which encircle this tube; — some run between it and the aorta to its front, and join with the nerves from the superficial cardiac ganglion, which lie in front of this vessel, and others descend to the heart, and form the anterior coronary plexus around the right coronary artery; the other filaments turn behind the pulmonary artery, or between it and the aorta, come into contact with the left coronary artery, and accompany it, to form, with filaments from the left portion of the cardiac plexus, the posterior coronary plexus. Other filaments from it descend to the right of these, or external to them, meet with the right branch of the pulmonary artery, and continue along it to the lung, assisting to form the anterior

Inferior. pulmonary plexus. The *inferior* or *left portion* of the plexus, much lower than the other, is placed behind the transverse part of the arch, close to the junction of the ductus arteriosus with it, above the left division of the pulmonary artery, and rather on the left of the trachea: it is formed by the union of the left recurrent with the middle and inferior cardiac nerves of this side, or only with the inferior, when the middle is absent. The branches descend beneath and around the left division of the pulmonary artery, to the trunk of this vessel which they encircle, and also on the aorta to the heart; they join with filaments from the superficial cardiac ganglion, and from the upper portion of the plexus, and enter, more especially, into the posterior coronary plexus, with the left coronary artery; a considerable branch comes forwards round the ductus arteriosus to join the superficial cardiac ganglion, and others pass, to the left, along the pulmonary artery, to join the pulmonary plexus.

Anatomy of the Vessels in the Root of the Lung. The relative position of the constituents of the root of the lung was examined with the general form of the organ, and it now remains to study their anatomy before they enter into its structure.

Right Pulmonary Artery. The pulmonary artery divides into a branch for each lung; the *right*, longer, but smaller than the left, passes behind the ascending part of the arch of the aorta, and the vena cava, and

lies on the bronchus of this side, but above the level of the right auricle of the heart; at the lung, it divides into three primary branches for its lobes, these enter the substance of the organ, and subdivide into arteries that accompany the bronchus. The *left branch*, shorter than the right, is directed in front of the descending aorta and left bronchus, to the root of the lung, and divides into two branches for its two lobes. The right and left branches of the pulmonary artery, diverging from each other, enclose, with the divisions of the bronchi, a lozenge-shaped space, in which are contained some bronchial glands. Left.

The *pulmonary veins* commence in the lungs at the termination of the arteries, and appear as large branches issuing from the different lobes to unite, on each side, into two large trunks which run inwards to open into the sides of the left auricle. The *right veins* are the longest, they are below the pulmonary artery, and lie beneath the ascending part of the arch of the aorta, and the right auricle of the heart; the *left veins* cross in front of the descending aorta, and, like those of the right side, are placed below the other parts in the root of the lung. Pulmonary Veins. Right. Left.

The *bronchial arteries*, for the supply of the structure of the lungs, arise from the front of the descending or thoracic aorta, but they are very variable in number as well as place of origin, and are designated by the names of superior and inferior: — the *superior*, usually two, arise either separately, or by a common trunk from the front of the aorta, opposite the third or the fourth dorsal vertebra, and one, directed to each side, adheres to the posterior surface of the bronchial tube on which it ramifies, and passes into the interior of the lung; the *inferior*, two or more in number, arise lower down than the preceding, and are distributed, like them, on the bronchus of each lung: these small arteries give branches to the œsophagus, bronchial glands, and pericardium. The superior bronchial of the right side may arise from the superior intercostal artery. Bronchial Arteries. Superior. Inferior.

The *bronchial veins* accompany the arteries, and the branches unite into one for each side; the right opens into the azygos vein, and the left into the superior intercostal vein. Veins.

The *lymphatics* of the lung join the lymphatic glands that surround the bronchus in the root, and the lymphatic vessels from these enter the glands in front of the trachea, or along the œsophagus; and so they open into the thoracic duct, in its course through the thorax. Lymphatics.

Take away the pulmonary artery and veins in order that the bronchus may be seen, and if the divided arch be turned to one side, and the cellular membrane and glands removed, the thoracic part of the trachea may be examined. Dissection.

The *trachea* is a fibro-cartilaginous tube, situated partly in the neck and partly in the thorax; it is joined above to the larynx, Form and relations

of the Trachea. and ends below, in the lungs, by means of the bronchi; its extent is from the fifth cervical to the third dorsal vertebra, and at this spot the division into the bronchi takes place. Its anterior part is convex and firm, by reason of strong cartilaginous bands situated in a fibrous structure, but the posterior surface is flat and muscular, the cartilages being deficient: this same general structure is found in the bronchi, and even in their primary divisions in the lung. In the thorax, the trachea lies in the space in the posterior mediastinum, between the layers of pleura; it is covered, above, by the first piece of the sternum, and sterno-thyroid muscles, and below by the left brachio-cephalic vein, by the brachio-cephalic and left carotid arteries, which are soon placed on the sides of it, and by the arch of the aorta and cardiac plexus of nerves; and it lies upon the œsophagus which projects to its left, above the arch of the aorta. On the right side are the pleura, pneumo-gastric nerve, and brachio-cephalic artery; and, on the left, the left carotid artery, and pneumo-gastric nerve with its recurrent branch, together with some of the cardiac nerves.

Of the Bronchi. The *bronchi* or divisions of the trachea, which extend to the lungs, are two in number, one for each side, and each is again divided, near the lung, into as many primary branches as there are lobes. The bronchus on both sides is posterior to the other vessels in the root, is surrounded by the bronchial vessels and glands, and by the pulmonary nerves; but the *right*, larger than the left, is shorter than it, and passes almost horizontally outwards above the right pulmonary artery; the vena azygos arches over its upper part.

Right.

Left. The *left bronchus* is nearly double the length of the right, passes obliquely downwards through the arch of the aorta, and, in its extent to the lung, lies on the œsophagus, thoracic duct, and descending aorta, and below the level of the left pulmonary artery.

Dissection. Remove the lung from the body, on both sides, by cutting through its root; take away the remains of the heart and pericardium, by dividing the inferior vena cava, and, in detaching the pericardium from the diaphragm, and from the parts in the posterior mediastinum, the dissector should endeavour to disturb, but little, the contents of the space. Examine first the structure of the lung, by tracing the divisions of the bronchi, and the vessels and nerves of the root into its interior.

Structure of the Lung. When the branches of the bronchus are followed into the lung, they are found to divide, in a binary order, into others, and these again into much smaller tubes which, in their turn, subdivide and terminate in minute air cells, that occupy the greater part of the structure of the lung, are united together by cellular membrane to form lobules, and by the pleura into larger masses or lobes. Each lobule is the aggregate of the ultimate cells of termination of a bronchial tube, and the cells are attached to

the central trunk by their minute branches, like the fruit of a bunch of grapes by pedicles to the stalk; but each lobule is separated from the surrounding ones by cellular membrane, and each vesicular cell communicates with those of the same lobule, only by means of the common central tube which conveys the atmospheric air into their interior. The existence of small distinct cells and lobules is marked on the exterior of the lung, when it is distended, by the presence of cellular bands of partition; and if air be blown into a large bronchial tube, it will distend only the lobules connected with its divisions, and the cells in which these end. In the root of the lung the *bronchus* forms a hollow tube, convex in front, but flat behind, and muscular; it consists of a strong fibrous membrane, containing in its substance cartilaginous portions which form segments of circles, reaching two thirds or more round the tube, decrease in size and strength in proportion to their distance from the trachea, and are covered by a thicker layer of the membrane on the outer than on the inner surface. The interval between the ends of the cartilaginous portions is occupied by transverse muscular fibres; and internal to these is an elastic tissue, which is disposed in longitudinal bands, and is closely united to the mucous membrane of the tube. Some glands are situated between the muscular and mucous layers, as well as in the fibrous membrane that connects the cartilaginous processes. In the substance of the lung, the cartilaginous portions in the divisions of the bronchi are thinner, and entirely surround the smaller tubes which are circular; but they are afterwards found only in separate fragments, and these disappear at the last bifurcations of the air tube, so that only the fibrous membrane is continued to the cells. The muscular and elastic tissues, which are situated only in the posterior part of the trachea and bronchi, expand in their small divisions in the lung, so as to give them an entire lining, but the existence of these structures has not been ascertained in the small cells. The mucous membrane of the trachea and bronchi lines all the divisions in the lung, and is continued into the cells.* The branches of the *pulmonary artery* and vein closely accompany the divisions of the air tube; the artery divides, like the bronchus, into smaller branches as it passes deeper into the lung, and one branch enters into each lobule, divides into numerous ramifications, which spread out on the exterior of the cells, and form with the radicles of the veins a vascular network: these vessels convey the deteriorated blood to the lungs to be renewed. The *veins* commence by minute ramifications on the walls of the cells, and the branches derived from one lobule unite into larger trunks with those from

Bronchus.

Pulmonary Artery.

Veins.

* The structure of the trachea is described in the dissection of the neck, p. 269., which may be turned to.

the other different lobules and lobes, and end in the pulmonary veins of each lung, which return the blood to the heart when it is purified. The *bronchial artery* runs with the bronchus, ramifies on it for the supply of the substance of the lung, and joins the *bronchial vein*. The large *nerves* from the posterior pulmonary plexus accompany the bronchi, appear in the angles of division of these tubes, and extend to the last branches, to which they are distributed.

Bronchial Artery.

Nerves.

Dissection.

Continue the dissection with the parts in front of the spine; seek the small thoracic duct close above the diaphragm, and against the right side of the aorta, by raising the pleura from this vessel, the duct is usually seen, without farther dissection, to lie in the loose cellular membrane, or, by scraping with the handle of the knife, it will be apparent; inject this tube as near the diaphragm as can be done.* Clean away now the cellular membrane from the parts contained in the space of the posterior mediastinum, and trace up the thoracic duct behind the arch of the aorta to the upper aperture of the thorax. On the front of the vertebral column are seen, the vena azygos on the right side, the aorta on the left, the thoracic duct between them, though nearest to the aorta; together with the œsophagus, which lies against the vertebræ above the arch of the aorta, but below this spot is to the left of the aorta, and superficial to the other vessels. The trachea and its bifurcation lie in front of the spine, down to the arch of the aorta. Raise the pleura from the sides of the bodies of the vertebræ, to dissect the trunk of the sympathetic nerve, which forms a gangliated cord along each side of the spinal column; and remove it from the inner surface of the ribs, for the inner layer of the intercostal muscles, and the intercostal vessels and nerves. In some of the spaces, the vessels and nerves may be followed by dividing the internal intercostal muscle.

Large Azygos Vein.

The *azygos vein*, named sometimes large azygos, receives the greater number of the intercostal veins of both the right and the left side of the chest; it commences in the cavity of the abdomen in one of the lumbar veins, and often joins with the inferior cava, or sometimes with the renal vein. It enters the thorax by passing through the aortic opening of the diaphragm, with the thoracic duct, ascends in front of the bodies of the dorsal vertebræ, in the space between the layers of the posterior mediastinum, but to the right of the thoracic duct and other parts in front of the spine; and it lies on the right intercostal arteries that separate it from the bodies of the vertebræ. Opposite the third

* A tallow injection is very convenient for this purpose, as it runs readily without any heating of the part, and it may be coloured with either yellow or blue. When the duct is filled, cease to force the fluid, which will then only distend the veins of the head and neck, and interfere with the dissection.

intercostal space the vein leaves the spine, arches forwards over the bronchus in the root of the right lung, and opens into the descending or superior cava as this vessel perforates the pericardium. It is joined in its course by the intercostal veins of the eight inferior spaces of the right side, by the small azygos and superior intercostal veins of the left side, which cross behind the aorta, by some œsophageal and mediastinal veins, and, at the root of the lung, by the right bronchial vein. It is also joined, sometimes, by the superior intercostal vein of the right side. This vein is not provided with valves, so that the intra-vertebral veins may be injected from it.

Small Azygos Vein.

The *small azygos vein* receives the veins of the four or five lower intercostal spaces of the left side; it is very variable in its size and origin, ascends along the left side of the spine, and crosses behind the œsophagus and thoracic duct, at an uncertain height, to open into the azygos major vein. It receives oftentimes, before crossing the spine, the superior intercostal vein of the left side.

Superior Intercostal Vein.

The intercostal veins of the spaces above the extent of the azygos veins unite, on each side, into a *superior intercostal vein*, which opens, on the right, either into the right subclavian or the large azygos vein; and on the left, the vein descends along the side of the bodies of the vertebræ, is joined by the left bronchial vein, and either ends in the large azygos vein, or comes forwards to join the left brachio-cephalic vein.

Thoracic Duct.

The *thoracic duct* commences in the abdomen opposite the second lumbar vertebra in a dilated pouch,— the receptaculum chyli, — behind the aorta or to its right side, enters the thorax through the aortic aperture in the diaphragm, and ascends in the space of the posterior mediastinum as high as to the fourth dorsal vertebra, being placed close to the right side of the aorta, on the right intercostal arteries; it next crosses beneath the arch of the aorta, and, connected to the left side of the œsophagus, continues beneath the trunk of the left subclavian artery, having, above this, the same relation to the œsophagus, and being situated to the inner side of the subclavian, but behind the carotid; it then leaves the cavity of the thorax, ascends in the neck as high as the seventh or sixth cervical vertebra, and arches outwards in front of the scalenus muscle, to join the left subclavian vein, rather external to its junction with the left jugular. It is not uncommon to see the thoracic duct divided in its course into two branches which unite again; it is often divided at its junction with the subclavian vein. Sometimes, it is found on the left side of the spine and aorta, and other varieties in the course of the trunk are not unusual. This duct receives the lymphatics of the lower extremities, those of the abdomen, of the viscera and walls of the left half of the thorax, and of the left upper extremity, and left side of the head and neck. The

lymphatics of the right side of the thorax, of the right upper extremity, and right half of the head and neck, join the *right thoracic duct* which opens into the right subclavian vein.

Right Duct.

Some *lymphatic glands*, connected with the lymphatics that open into the duct, are found in the cavity of the thorax, along the course of the internal mammary, along the side of the spine and trachea, and with the bronchi in the lungs; others are placed between the layers of intercostal muscles. Into these different glands the lymphatics of the wall of the cavity or of the viscera open, before they join the thoracic duct.

Lymphatic Glands.

The *œsophagus*, in its extent between the pharynx and stomach, occupies part of the cervical region, and the thorax. It is a hollow muscular tube, which enters the thorax in front of the vertebral column, but behind the trachea, and rather to its left side, is then directed obliquely downwards and inwards to the middle line, and crosses beneath the arch of the aorta opposite the fourth dorsal vertebra; it now descends through the space of the posterior mediastinum, superficial to the other parts contained in it, and on the right of the aorta, but in the lower part of the thorax, it crosses to the left of this vessel in order to pass through its aperture in the diaphragm. The œsophagus is covered, down to the arch of the aorta, by the trachea, beneath which it lies as it enters the thorax, but it is inclined a little to the left of this, and is crossed by the left subclavian artery; it lies upon the longus colli muscle and vertebral column, and to its left side is the thoracic duct and left recurrent nerve. The remaining portion of the tube passes beneath the aorta, left bronchus, and the heart and pericardium which cover it to the diaphragm; it is placed at first upon the spine, but as it descends, it comes forwards, and is separated from this by cellular membrane, by the right intercostal arteries, by the thoracic duct which, near the diaphragm, is to the right of the œsophagus, but crosses beneath and appears, above, to the left of it; and, close to the diaphragm, it is situated on the descending aorta. On the left side is the aorta, but, on the right, only the pleura, forming the right layer of the posterior mediastinum. It is accompanied by the two pneumo-gastric nerves, the right being in front and the left behind it in the lower part of the mediastinum, and these form, by their branching, the plexus gulæ around it. Some lymphatic glands surround the tube. Its coats are two, a muscular and a mucous; and if a portion be removed and distended with air, they may be readily dissected. The muscular coat consists of two layers of muscular fibres; the external, with parallel longitudinal fibres, forms an entire covering for the tube, and is continuous below with the longitudinal fibres of the stomach; the internal, composed of circular fibres which surround the œsophagus, is in contact with the mucous membrane, but not closely united to it. When this portion is cut

Œsophagus.

Structure.

Muscular Coat.

Mucous.

open, the mucous membrane is seen to be very thick, and separated from the muscular by cellular structure; it is marked by longitudinal folds, and is covered by the epithelium, which is separable by acids, or by maceration; some small glands are situated, at intervals, beneath it. The *arteries* for its supply come from the aorta, from the bronchial, and from the right intercostal arteries; and, below, from the coronary of the stomach. The *veins* open, below, into the coronary, and, above, into the azygos vein.

Arteries.

Veins.

The *thoracic aorta*, or portion of this vessel situated in the cavity of the thorax, extends from the lower border of the left side of the body of the third dorsal vertebra, where the arch ceased, to the opening in the diaphragm opposite the last dorsal vertebra, through which it passes to reach the abdomen. It is situated, above, on the left side of the bodies of the vertebræ, but, below, in front of the spinal column, it is contained in the space of the posterior mediastinum, and projects towards the left half of the thorax. The aorta is covered by the root of the left lung, by the pericardium, and, near the diaphragm, by the œsophagus; it is in contact, on the left, with the pleura, and on the right, with the thoracic duct and œsophagus; it lies on the vertebral column, and on the small azygos vein. The branches from this part of the aorta are bronchial, already seen, œsophageal, mediastinal, and intercostal.

Thoracic Aorta.

Branches.

The *œsophageal arteries* arise at different points of the aorta, descend on the œsophagus, and divide into ascending and descending branches: the upper anastomose with the bronchial arteries, and with some branches supplied to the commencement of the tube from the inferior thyroid; and the lower with the coronary artery of the stomach. They perforate the muscular coat, and ramify in it and the mucous lining of the œsophagus. The small *mediastinal arteries* supply the cellular membrane and glands in the posterior mediastinum.

Œsophageal.

Mediastinal.

The *aortic intercostal arteries*, so named to distinguish them from the superior intercostal of the subclavian, are usually eight or nine in number on each side, but generally one or two more to the right, than to the left half of the thorax; they arise from the posterior part of the aorta, pass outwards, the upper ones obliquely, and the lower transversely, to reach the intercostal spaces, and in this interval each divides into an anterior and a posterior branch. From the position of the aorta on the left of the spinal column, the right intercostal arteries which arise very near the left, and sometimes by a common trunk, are longer than those for the left side, and pass beneath the thoracic duct, œsophagus, and vena azygos, to reach their intercostal spaces; and the arteries of both sides are covered, on the sides of the vertebræ, by the pleura and trunk of the sympathetic nerve. Each supplies small branches to the body of the vertebra over which

Intercostal.

it passes, and at the head of the rib a small branch is given upwards and downwards, to anastomose with the artery above and below; by which means a chain of anastomosis is maintained between the arteries along the side of the trunk. The *anterior branch*, the continuation of the artery, and larger than the posterior, extends obliquely outwards in the intercostal space, lying beneath the pleura and the fascia prolonged backwards from the inner layer of the intercostal muscles, and on the external intercostal, and it reaches the lower border of the rib above, near its angle; it now continues forwards between the two layers of the muscles, and about the anterior third of the space divides, as seen in the dissection of the wall of the thorax, into two branches; an inferior, that descends to the rib beneath, and is distributed on its outer surface, and another branch which continues to the sternum to join with the internal mammary. These arteries supply the intercostal muscles and spaces; some small perforating branches pass through the external intercostal, and are distributed to the muscles on the front and sides of the thorax, anastomosing with the thoracic arteries of the axillary, and they give likewise cutaneous branches to the integuments. Below the sixth intercostal space the arteries anastomose, in front, with the internal mammary, epigastric, lumbar, and circumflex ilii arteries in the wall of the abdomen. Each of these arteries is accompanied by the anterior branch of a dorsal nerve, and by an intercostal vein, — the vein being situated highest, the nerve lowest, and the artery in the interval between them; but, in the upper spaces, the nerve lies at first above the artery, and crosses it near the intervertebral foramen to be placed below the vessel. The *posterior branch* passes backwards between the transverse processes, and between the ascending costo-transverse ligament and the vertebra, and gives off, opposite the intervertebral foramen, a spinal branch which enters the canal, and supplies the vertebræ, and the membranes and substance of the cord. The artery now continues its course, appears in the back, internal to the longissimus dorsi, with the posterior branch of each dorsal nerve, as seen in the dissection of this part, and supplies the muscles: the lowest of these branches anastomose with the lumbar, and the upper, with the deep cervical, and the posterior scapular arteries, thus completing the arterial anastomosis, behind, along the side of the thorax.

Anterior branch.

Intercostal Vein.

The *intercostal vein* commences, in front, by two branches which correspond to those of the artery, runs backwards to the vertebræ with the artery but superior to it, and is joined, at the head of the rib, by a vein from the interior of the spinal canal, as well as from the back of the trunk; it then receives some small veins from the bodies of the vertebræ, and opens into either the azygos, or the superior intercostal vein.

Superior

The *superior intercostal artery*, of each side, arises from the

subclavian, descends over the two or three first intercostal spaces, near the heads of the ribs, and supplies an external branch to each of these superior spaces, usually one more on the right than on the left side, and it terminates by anastomosing with an ascending branch from the upper aortic intercostal. Each intercostal branch from it divides, at the head of the rib, into a posterior branch to supply the spinal canal and posterior muscles, and into an anterior, which runs between the layers of the intercostal muscles, and is distributed as the other intercostal. Inter-costal Artery.

The *internal intercostal muscle*, partly seen in front, in the dissection of the intercostal spaces, is attached to the inner margin of the ribs between which it lies; and the fibres, consisting of fleshy and tendinous bundles, are directed downwards and backwards so as to cross those of the external layer. The muscle does not extend farther towards the spine than the angles of the ribs, in the upper spaces, but, in the lower, it reaches nearly to the heads of these bones; prolonging backwards this layer of muscles, is a fascia which reaches to the vertebræ. The inner surface is in contact with the pleura, and the outer with the external layer of intercostal muscles, but separated from it by the intercostal vessels and nerve. Between the posterior border of the muscle and the spine, after the removal of the fascia, the external intercostal muscle appears. Internal Inter-costal Muscle.

The *anterior branches of the dorsal* nerves, instead of uniting into plexuses like the same nerves in the cervical, lumbar, and sacral regions, run forwards to the middle line of the body, supplying the intercostal spaces, and below the sternum, the abdominal wall. Each leaves the posterior branch in the intervertebral foramen, runs outwards in front of the ascending costo-transverse ligament which separates it from the posterior division, and lies between the pleura and external muscle of the space along with the intercostal vessels; the nerve then enters between both layers of the intercostal muscles, and runs forwards either between the muscles, or in the fibres of the inner, to about midway between the sternum and spine, and divides into a middle intercostal cutaneous nerve for the integuments of the thorax and arm, and a filament which continues forwards to the sternum before it becomes cutaneous: these branches have been dissected in the wall of the thorax. As the nerve lies between the layers of muscles, it supplies them with filaments, and is placed below the intercostal artery; and opposite the head of each rib, it is joined by one or two filaments from the ganglion of the sympathetic. Below the sixth intercostal nerve, the anterior branches that reach to the middle line quit the intercostal spaces at their anterior part, and extend forwards in the abdominal wall to the centre of the body. There are some exceptions to this general distribution of the intercostal nerves; thus the Anterior branches of the Dorsal Nerves.

Of the First. first ascends in front of the neck of the first rib, and leaves the thorax by the upper aperture, to join the last cervical, in the brachial plexus; and the branch which supplies the muscles, and runs forwards in the first intercostal space to the middle line, is given off soon after the nerve has left the intervertebral foramen, is directed forwards along the inner surface of the first rib which it crosses, perforates the inner layer of muscles opposite the cartilage of the rib, and becomes cutaneous by the side of the sternum, to be distributed as the rest: no middle intercostal cutaneous branch is supplied by this nerve. Of the Second. The second nerve, lying in the second intercostal space, ascends to the first by crossing the second rib, it then descends again over the second rib, near its middle, to the second space, and divides into its large middle cutaneous, and the branch which continues forwards to the sternum; this nerve, like the first, gives, soon after its exit, Of the Third. a branch to supply the muscles in the intercostal space. The third intercostal enters, oftentimes, between the layers, by perforating the internal intercostal muscle. Posterior branch. The *posterior branch* of each dorsal nerve passes back between the ascending costo-transverse ligament and the spine, and is seen in the dissection of the back.

Sympathetic Nerve. The *sympathetic nerve* in the thorax consists, as before seen, of a central plexus, — the cardiac, placed in front of the spine, in which the cardiac nerves from the cervical ganglia end; and of a gangliated cord, situated on each side of it over the heads of the ribs, which is continued into the neck by the upper aperture of the thorax, and into the abdomen beneath the ligamentum arcuatum internum of the diaphragm; it is covered only by the pleura, and lies over the intercostal vessels. The ganglia on this thoracic portion of the sympathetic are usually twelve in number, one being placed over the head of each rib, but the number may vary in consequence of the union of the two upper, or because of the disappearance of some of the intermediate ones; the two last ganglia leave the line of the heads of the ribs, and are situated obliquely along the side of the bodies of the vertebræ. Each ganglion is connected, externally, by two filaments with each spinal nerve, and, internally, branches are given off from it to supply the parts in the posterior mediastinum, and to unite to form the splanchnic nerves: thus, the internal branches from the six upper are unconnected to the splanchnic nerves, but supply the aorta, the longus colli muscle, and some filaments to the pulmonary plexus; but the internal branches of the six lower ganglia, larger than those of the upper, give rise, by their union, to the splanchnic nerves. Great Splanchnic Nerve. The *great splanchnic*, connected by branches to the ganglia as low as the tenth, is a large white nerve, placed on the front of the bodies of the vertebræ, which descends to the diaphragm, perforates its crus to reach the

abdominal cavity, and ends in the semilunar ganglion. The lower nerve, the *small splanchnic*, much less in size than the other, receives branches only from the two last ganglia; it descends to the diaphragm a little external in position to the other, and perforates the crus either on the outer side of the great nerve or through the same aperture, to join with the renal plexus and the semilunar ganglion of the abdomen. This nerve is sometimes divided into two portions which run separately to their distribution.

Small Splanchnic Nerve.

The upper surface of the diaphragm, which forms the partition between the thorax and abdomen, is convex on each side, where it corresponds to the concave base of the lung, but is rather flat in the centre which is in contact with the pericardium. The convexity of the right side is greater than that of the left, in consequence of the presence of the liver, and ascends to the interval between the fourth and the fifth rib; but on the left it reaches only to the intercostal space between the fifth and sixth ribs. The centre of the muscle is tendinous, but the part in contact with the wall of the thorax is fleshy; passing through the diaphragm are the aorta, with the thoracic duct and vena azygos, the œsophagus with the pneumo-gastric nerves, and the vena cava. The phrenic nerves and vessels expand on the upper surface, external to the position of the pericardium.

Upper Surface of the Diaphragm

The relative position of the parts passing through the upper aperture of the thorax can be better seen now, than before the dissection of the cavity. In the middle line is the trachea, lying in front of the œsophagus, the origins of the sterno-hyoid and sterno-thyroid muscles, and the remains of the thymus gland being in front of these tubes, and the longus colli muscle behind them; between the trachea and œsophagus is the recurrent nerve of the left side. On each side, the bag of the pleura, and the apex of the lung, project into the neck, the different vessels and nerves being between them and the trachea and œsophagus; thus nearest the surface on each side, is the brachio-cephalic vein, the phrenic, and the pneumo-gastric nerve with its cardiac branch; on the right side, next in order from before backwards, are the brachio-cephalic artery, and cardiac nerves, and on the left, the left carotid artery, thoracic duct, and left subclavian artery and cardiac nerves; and behind these, on each side, are the sympathetic, anterior branch of the first dorsal nerve to join the brachial plexus, and the superior intercostal branch of the subclavian.

Parts passing through the upper aperture of the Thorax.

In the common order of proceeding the body is now turned over on the face for the dissection of the back, to which the dissector must refer; and after this region is examined, if the thorax is a separate part from the arm, take three or four of the vertebræ, with about four inches of the ribs attached, in order

Dissection.

to see the ligaments connecting the ribs to the vertebræ, and these bones to each other.* Remove all the muscle from the vertebral grooves behind, if the spinal canal remains unopened, as well as from the intercostal spaces, to dissect the ligaments of the ribs.

Union of the Rib and bodies of the Vertebræ.

In the articulation of the head of the rib with the bodies of the vertebræ, its convexity is received into a hollow formed by the depressions on the sides of the bodies of two contiguous vertebræ, and is maintained in position by the following ligaments between the two, viz. costo-vertebral and inter-articular, with two synovial sacs.

Costo-vertebral Ligament.

The *costo-vertebral ligament*, composed of radiating fibres, connects the head of the rib to the two vertebræ between which it is placed; it is named *stellate* from its form, and consists of an upper portion, the largest, which is attached to the lower border of the body of the vertebra above; a lower, to the upper part of the one below; and a central part which is fixed to the inter-vertebral substance.

Inter-articular.

The *inter-articular ligament*, very short and thin, passes from the prominence which separates the two articular surfaces on the head of the rib, to the interosseous substance between the vertebræ: to see this the stellate ligament must be cut through; it is not present in the articulation of the first, eleventh, or twelfth rib.

Synovial Membranes.

Two *synovial sacs* are found in this articulation,—one on each side of the inter-articular ligament; but, as in the articulation of the first rib, and in that of the eleventh and twelfth, there is no inter-articular ligament, the head of the bone being received into a single cavity, so there is but one synovial membrane to each articulation.

The Neck and Transverse Processes.

The neck and tubercle of the rib are united to the transverse processes of the dorsal vertebræ by three costo-transverse ligaments, and by an intervening synovial membrane.

Anterior Costo-transverse.

The *anterior* or ascending *costo-transverse ligament* passes from the upper border of the neck of the rib, to the lower border of the transverse process above that to which the other two ligaments are attached; its outer border is continuous with the aponeurosis between the layers of the intercostal muscles, and is often divided into two portions. In front of it are the intercostal nerve, vein, and artery, and between it and the body of the vertebra are the posterior branches of the same vessels and nerve. To the first rib there is no anterior costo-transverse ligament.

Posterior Costo-transverse.

The *posterior costo-transverse ligament* is a thin band of fibres between the apex of the transverse process and the rough part of the tubercle of the rib.

* If the thorax and extremity should be considered one part, finish the extremity before the following ligaments.

The *middle costo-transverse ligament*, situated transversely between the neck of the rib and the transverse process in front of which it is placed, is best seen by sawing horizontally through both the neck and the transverse process, and then taking away the upper part. The ligamentous fibres are mixed with a reddish cellular membrane, and are situated at the lower part of the neck. Middle Costo-transverse.

A *synovial membrane* is placed between the apex of each transverse process and the tubercle of the rib, except between the eleventh and the twelfth and the two last ribs. Synovial Membrane.

The articulation of the cartilages of the ribs to the sternum and to the osseous parts of the ribs, can be seen on the portion of sternum removed, and on the ribs that remain connected to its lower part. Union of the Cartilages of the Ribs.

The costal cartilages are united, externally, by periosteum only, to the osseous parts of the ribs, which are hollowed to receive them; and, internally, the cartilages of the true ribs are articulated to the sternum by an anterior and posterior ligament, and synovial membrane. Those of the false, are united to each other by anterior and posterior bands of fibres, and the surfaces in contact are covered with a synovial membrane, but the cartilages of the two last ribs are separate; the synovial membranes may be absent in one or more of the articulations between the cartilages, and then only the ligaments will be found uniting them. The cartilage of the first rib is sometimes united inseparably to the sternum; that of the second rib articulates in the angle of union of the first and second pieces of the sternum, and is provided occasionally with an inter-articular ligament fixed to its projecting part, and with two synovial membranes instead of one. The cartilages of the two last true ribs are also united to each other in a manner similar to that joining the cartilages of the false ribs. To the Ribs. To the Sternum. To each other.

In the articulation of the vertebræ to each other, the broad flat surfaces of the bodies are maintained in contact, and united by a strong anterior and posterior ligament, an intervening elastic fibro-cartilage being placed between them; other ligaments connect the processes of one vertebra to the same parts of another; thus ligaments join together the plates of the vertebræ, the articular processes, and the spines. The portion of spine employed for the ligaments of the ribs may be used for those of the vertebræ, and the spinal canal having been opened, either now, or before, for the dissection of the cord, and the medulla and its membranes removed, the ligaments of the bodies will be seen in front of the vertebræ and behind them; the ligamenta subflava between the plates or arches of the vertebræ, and the supra- and inter-spinous ligaments can be dissected on the portion of spine removed in opening the canal. Articulation of the Vertebræ.

The *ligamenta subflava*, so named from their colour, consist Union of

the Processes. Ligamenta subflava.

of a strong, yellowish ligamentous and elastic structure, situated between the arches or plates of the vertebræ, to connect them together, and close the spinal canal behind. These ligaments, best seen by looking at their inner surface, are of a somewhat square shape, and two are placed in the interval between the arches of two contiguous vertebræ; each is attached below to the upper border, but above to the inner surface of the half arch; an interval in the middle line separates the ligament of one half of the arch from that of the other side, and its outer border is in contact with the junction of the articulating processes; their spinal surface is contiguous to the dura mater, and they are covered externally by the arches of the vertebræ.

Supra-spinous Ligament.

The spinous processes are united together by supra- and inter-spinous ligaments. The *supra-spinous* consists of longitudinal bundles of ligamentous fibres connecting together the apices of the spinous processes. It is thin in the back to what it is in the loins, and it does not exist in the cervical region; some of its fibres are superficial, and are continued over three or more spinous processes, and others are deep and pass from spine to spine. It is closely united to the tendons of the muscles attached to the spines. The *inter-spinous ligaments*, situated deeper than the preceding, occupy the intervals between the spinous processes, and extend from root to apex; each is attached above to the under surface of the spine, and below to its upper border. The size of these depends upon the intervals between the spinous processes; thus, in the back, they are much smaller than in the loins. The sides of the ligament, in each space, are in contact with the multifidus spinæ muscles, one margin is united with the supra-spinous ligament, and the other extends downwards to the interval between the ligamenta subflava.

Inter-spinous.

Union of the Articular Processes. Capsule. Synovial Membrane.

The articular processes are covered with cartilage, and a *synovial membrane* is interposed between them; and enveloping the whole, is a *capsular ligament* of some irregularly scattered fibres, which are stronger externally than internally. This articulation is partly covered on the inner surface by the ligamenta subflava, and on the outer by the muscles; its size and extent will vary in the several regions, according to the difference in the articulating processes of the vertebræ.

Ligaments of the Bodies.

The bodies of the vertebræ are united together by an anterior and posterior common ligament, and by an intervertebral fibro-cartilage.

Posterior Common Ligament.

The *posterior common ligament*, situated on the posterior surface of the bodies of the vertebræ, and in the vertebral canal, reaches from the axis to the sacrum; it is wider opposite each intervertebral fibro-cartilage than opposite the bodies of the vertebræ: which gives a sinuous appearance to its margins, particularly in the lumbar region. The ligament is stronger and wider in the back, than in either the neck or loins, and the fibres

which enter into it are, superficial, extending over three or four bodies, and deep, between those of two vertebræ; the thickness of it in the back is greater than in the other regions. The surface which looks to the spinal canal is in contact with the dura mater, and the other lies against the intervertebral cartilages, to which it is closely joined, and the bodies of the vertebræ, from which it is separated, in their centre, by the small vessels that perforate them. Along each side of the ligament is the longitudinal vein of the vertebral canal.

Anterior Common Ligament.

The *anterior common ligament* extends in front of the vertebræ from the axis to the sacrum, is whiter, and presents more marked fibres than the posterior; it is rather wider opposite the bodies of the vertebræ than opposite the intervertebral substance, and its breadth is greater in the dorsal than in the cervical region, but less than in the lumbar. The fibres, as in the posterior, consist of two planes, — a superficial, which passes over the bodies of three, four, or five vertebræ, and a deep, from that of one vertebra to another; the fibres come from the intervertebral fibro-cartilages, rather than from the bodies of the vertebræ, are attached to the margins more than to the centre of the body, and form a band, thicker in the middle than at the borders, which is perforated by small vessels to the vertebræ. This ligament is covered in the dorsal region by the aorta, thoracic duct, and vena azygos, and it lies on the intervertebral substance and bodies of the vertebræ.

Intervertebral Fibro-cartilage.

The *intervertebral fibro-cartilages*, seen when the anterior and posterior common ligaments are removed, form a series of discs of a cartilaginous structure, situated between the bodies of the vertebræ, which they serve to connect together, the highest being found between the second and the third cervical vertebra, and the lowest between the last lumbar and the sacrum. The thickness of these bodies is less in the back and neck than in the loins, their shape depends upon that of the vertebræ, and their depth, at the front and back, varies in the different regions; thus, in the cervical and lumbar region, where the spine is convex forwards, the anterior part of each cartilage is thickest; but in the dorsal, in which it is concave in front, the anterior border is thinner than the posterior. Separate one vertebra from the cartilage, to obtain a horizontal view of it, and saw, vertically, one or two others, to see its elasticity. Each intervertebral cartilage is united firmly, above and below, to the bodies of the vertebræ between which it is placed, and is thicker in the middle, where it is pulpy, than at the circumference. A number of cartilaginous plates enter into its structure, and these are more compact, and closer together at the circumference than in the centre, at which part they are separated by a soft spongy substance, permeated by a viscid fluid which projects from its situation when a vertical section is made. The

fibres of each cartilaginous plate pass obliquely from one vertebra to the other, so that those of one plate or layer cross those of the other, like the legs of the letter X: this disposition of the fibres in the layers is best seen between the lumbar vertebræ, since this structure is large, and the layers are easily separated from each other. The intervertebral substance is united, in front and behind, to the anterior and posterior common ligaments; laterally, it is joined by the ligaments of the articulation of the head of the rib, and it reaches to the intervertebral foramen.

DISSECTION OF THE SHOULDER AND SCAPULAR REGION.

Dissection. After the dissection of the muscles of the back, detach the upper extremity from the trunk by cutting through the serratus magnus muscle, and place the limb on the table with the subscapularis uppermost; tie together the axillary artery and brachial plexus, and fasten them to the coracoid process; separate from each other the muscles inserted into the base and superior costa of the scapula, and clean them.

Muscles to the Superior Costa of the Scapula. Into the *superior costa* is fixed the omo-hyoid muscle, which is about half an inch wide, is attached to the superior costa behind the ligament converting the notch in this part of the bone into a foramen, and sometimes to the ligament: the direction of the muscle is upwards and inwards to the clavicle, to which it may, occasionally, be found connected. Into *the base* are inserted the levator anguli scapulæ, between the superior angle and spine of this bone; the rhomboideus minor to the smooth surface opposite the spine; and the rhomboideus major between the spine and inferior angle, but it is not fixed directly to the bone in all this extent, but only inferiorly, the other fibres ending in an aponeurotic arch which is connected, above, near the spine of the scapula; between this arch and the bone is a thin fibrous membrane perforated by vessels. Internal to these is the large serratus, attached to the scapula by three distinct parts, corresponding to the separate portions of the muscle; — the upper one, thick and fleshy, is fixed to the rough surface of the bone internal to the superior angle, the lower, larger and more muscular, to the impression on the inner side of the inferior angle, and the middle portion, very thin, and almost membranous in some subjects, is attached to the base of the bone between the angles, forming a septum between the levator anguli and rhomboidei on the one side, and the subscapularis on the other. The serratus, by its position, conceals the

To the Base.

greater part of the subscapularis. The posterior scapular artery is now seen to supply these muscles.

Separate the serratus from the subscapularis, take away the cellular membrane, and the subscapularis muscle is seen to be covered by a fascia attached to the bone around its margins. Remove this, and the muscle is exposed. Dissection.

The *subscapularis muscle* is triangular in shape, covers the ventral surface of the scapula, and extends beneath the axillary vessels and nerves to the head of the humerus; along the inferior costa, the muscle projects beyond the bone so as to come into contact with the latissimus, but on the other sides it does not reach to the margins. It *arises* from all the concave portion of the venter or costal surface of the scapula, and is connected to the ridges on the bone by tendinous processes amongst the muscular fibres; from this origin the fibres, collected into separate bundles, ascend, the inferior being oblique, and the superior almost horizontal, to the surface of a tendon placed at first in the interior of the muscular fibres, but which, escaped from these, is *inserted* into the small tuberosity of the humerus, and some of the inferior fleshy fibres are continued to the neck of the bone below this process. To see this insertion, throw down the axillary artery and nerves, and detach the subscapularis from the fossa, noticing at the same time the tendinous processes of origin; follow back the tendon of insertion into the muscle, into which it extends for some distance; it will be seen to be inseparably united to the anterior and inferior part of the capsule of the shoulder joint, to extend farthest along the upper border of the muscle, and to have, between it and the root of the coracoid process, either a bursa which communicates with the joint, or a prolongation of the synovial membrane of the articulation. The muscle is covered in the greater part of its extent by the serratus magnus which lies against it, separated, however, by cellular membrane, by the fascia covering the subscapularis, and near its insertion into the humerus it is crossed by the axillary vessels and brachial plexus of nerves, and by the muscles which arise from the coracoid process; entering this surface near the vessels are numerous small arteries and the subscapular nerves already seen. It lies on the venter of the scapula, crosses the neck of the bone and articulation of the shoulder joint, and conceals an arterial anastomosis on this surface of the bone. In relation with the upper border is the omo-hyoid muscle, and anterior to this are the supra-scapular nerve and artery; the inferior border is in contact with the latissimus, conceals the long head of the triceps, and is separated from the teres major by a process of fascia; along this border run the subscapular artery, vein, and nerves for the teres and latissimus; the base of the muscle is close to the insertion of the serratus magnus, which separates it from the rhomboideus major.

Subscapularis Muscle. Origin. Insertion. Relations.

A considerable artery, the *infra-scapular branch*, is given off Infra-scapular branch.

from the dorsal artery of the subscapular, to ramify in the subscapular fossa. It arises opposite the inferior costa of the scapula, runs upwards beneath the subscapularis, and anastomoses with branches of arteries which come from the axillary and perforate the muscle; some of the branches radiate downwards, and some across the centre of the bone, to join with those turning over the costæ of the scapula: this artery supplies the articulation of the shoulder and the bone.

Dissection. Turn now to the dorsum of the scapula, but before dissecting the muscles, seek the cutaneous nerves distributed over the deltoid muscle. Place the arm over a block high enough to allow it, when the scapula is fixed on one side, to hang on the other, so as to render tense the muscular fibres. Remove the skin by beginning at the anterior border of the deltoid already exposed, and raise it from before backwards. The integument has been removed from the greater part of the dorsum of the scapula by the dissection of the trapezius.

Cutaneous Nerves. The cutaneous nerves are the supra-acromial branches of the cervical plexus, cutaneous branches of the circumflex nerve, which appear below the posterior border of the deltoid, also some filaments of the same nerve, which perforate the muscle: these ramify in the integuments over the deltoid.

Dissection. Take the fascia from the deltoid, to expose it; this may be begun at the anterior border; in removing it, the dissector will find that it dips between the fibres of the muscle, dividing it into large fasciculi which resemble those of the gluteus maximus, and from the coarseness of these some difficulty will be experienced in cleaning them. At the posterior border of the muscle the fascia is continued over the infra-spinatus muscle. Of course the muscle will be dissected in the direction of its fibres, viz. from above downwards.

Deltoid Muscle. The *deltoid* is a large triangular-shaped muscle, the base above, at the clavicle and scapula, and the apex below, at the

Origin. humerus. It *arises* from the whole of the inferior border of the spine of the scapula, from the anterior border of the acromion process, and from the external half or third of the clavicle; the fibres, as in all triangular muscles, take different directions, the anterior, the shortest, pass downwards and backwards; the middle descend vertically; and the posterior, the longest, are directed downwards and forwards, to form a thick pointed portion, which

Insertion. is *inserted*, by a tendon, into the impression on the middle of the outer surface of the humerus, between the fleshy processes of

Relations. the brachialis anticus muscle. The cutaneous surface is convex forwards by the position of the head of the humerus beneath, and forms the projection of the shoulder; it is fasciculated on the surface by processes of fasciæ which dip between the fibres, and the number of these varies; sometimes the muscle appears to be divided into three portions, corresponding to the attach-

ments to the clavicle, acromion, and scapula, and, at others, into more. The platysma covers the upper part of the muscle, and the fascia and cutaneous nerves the lower. The anterior border is parallel to the pectoralis major, separated from it by the cephalic vein and thoracica humeraria artery; the posterior rests on the infra-spinatus muscle and overhangs the triceps muscle. The base is attached to the clavicle and scapula, and corresponds to the line of insertion of the trapezius to the upper border of these bones; the apex is attached to the humerus, and a digitation of the brachialis anticus lies on each side of it. Divide the deltoid near its upper attachment, and throw down, as much as the vessels and nerves on the under surface will permit, the lower part of the muscle to see its insertion; dissect at the same time the circumflex artery and nerve beneath the muscle. A bursa will be seen beneath it. The insertion is fleshy on the outer aspect, but tendinous beneath, and the under surface of the muscle is also aponeurotic above this; the attachment to the bone consists of a central tendon which is the strongest, receives the middle or vertical fibres, and projects lowest on the bone; of an anterior portion, extending upwards from it along the bone, which receives the clavicular fibres of the muscle, and joins the insertion of the pectoralis major; and of a posterior thinner portion which, in like manner, is united to the fibres from the spine of the scapula. The muscle conceals posteriorly, below the spine of the scapula, the infra-spinatus and teres minor muscles; the head, and upper part of the humerus, with the tendons of the teres minor, infra- and supra-spinatus muscles inserted into the great tuberosity of this bone: between these and it a large bursa is placed. Below the head of the bone are the circumflex arteries and nerve, and the upper part of the biceps muscle; in front of the humerus, the coracoid process and muscles attached to it, and near the clavicle, the inferior acromial artery.

Insertion of the Tendon.

Relations to the posterior surface.

Follow back the circumflex vessels and nerve round the neck of the humerus, taking away the cellular membrane which fills up an interval behind the bone, and in front of the long head of the triceps; in this fat is a branch from the nerve to the teres minor muscle placed along the inferior costa of the scapula.

Dissection.

The *posterior circumflex artery* is a branch from the axillary opposite the lower border of the subscapularis muscle, it leaves the artery and axilla by passing round the neck of the humerus, through a space bounded in front by this bone, behind by the long head of the triceps, and above and below by the teres muscles; the artery is accompanied by the circumflex nerve placed above it, and by a vein; having passed through this space, it enters beneath the deltoid muscle and divides into numerous branches;—some of these ascend on the capsule, and head of the bone supplying them, one of the branches passes in front of the tendon of the teres minor, and one behind, this last also

Posterior circumflex Artery.

supplies the teres minor, or the branch to it may be given off when the trunk is turning round the humerus; others encircle the neck of the bone to anastomose with the anterior circumflex; but the greater number of branches descend, and are distributed to the under surface of the deltoid, and join with branches to this muscle from the acromial thoracic artery: this artery supplies also the long head of the triceps muscle. The inferior acromial branch is now seen.

Circumflex Nerve. The *circumflex nerve*, a branch from the posterior cord of the brachial plexus, and lying at first behind the axillary artery, soon leaves the axilla by passing round the lower border of the subscapularis, and close to the articulation of the shoulder; it then runs with the artery, but placed nearer the head of the humerus, through the interval between this bone and the triceps muscle, and, beneath the deltoid, divides into numerous branches which enter the under surface of the muscle to supply its substance; some of these perforate the deltoid and enter the integuments. As the nerve passes by the subscapularis it gives a branch to the teres minor, which enters the lower border of this muscle and supplies it; and near the posterior border of the deltoid, the *cutaneous branch of the shoulder*, which perforates the fascia, and is distributed, as seen, to the integuments over the deltoid.

Branch to the Teres minor.

Cutaneous branch.

Anterior circumflex Artery. The *anterior circumflex artery*, much smaller than the posterior, arises from the outer side of the axillary artery below the head of the humerus, and rather below the origin of the posterior circumflex; it passes horizontally outwards in front of the neck of the bone, above the tendons of the latissimus and teres muscles, and beneath the coraco-brachialis, short head of the biceps, and external cutaneous nerve, to the bicipital groove of the humerus; at this part the artery divides into an ascending branch, which runs in the groove, supplies the head of the bone and the articulation; and a transverse, which is directed outwards to anastomose with the posterior circumflex, and acromial thoracic arteries.

Infra-spinatus Muscle. The *infra-spinatus muscle* will be seen by removing the aponeurosis which covers it, and is attached to the margins of the scapula and spine of this bone, sending a process between this muscle and the teres minor, and is continued forwards to its insertion. The muscle is triangular in shape, occupies the infra-spinal fossa, and extends from it to the head of the humerus. It

Origin. *arises* from the greater part of the infra-spinal fossa by fleshy and tendinous processes, except near the neck of the bone, where it is separated by the infra-spinal vessels and nerve, and by some cellular membrane; from the lower surface of the spine, from the fascia covering it, and from the process of fascia between it and the teres minor. The fibres run outwards, and the lower ones obliquely upwards, to the tendon which, concealed by those fibres that arise from the spine, passes over the capsule of the

Insertion articulation of the shoulder, and is *inserted* into the middle of the

three depressions on the great tuberosity of the humerus, being connected by a tendinous expansion with the tendons of the supra-spinatus and teres minor. The cutaneous surface is rough when the fascia is removed, because the fibres attached to it are divided; the part of the muscle near the spine of the scapula is covered by the deltoid, and that near the inferior angle by the latissimus, but the portion between them is subcutaneous. The upper border is in contact with the spine of the scapula, and deltoid muscle attached to it; the lower has parallel to it the teres minor, from which it is often separated by a process of fascia, and the teres major comes into contact with it at the inferior angle of the scapula; the posterior border corresponds to the insertion of the rhomboideus major. The muscle lies on the scapula, on the infra-spinal branches of the supra-scapular vessels and nerve, and on the humero-scapular articulation. Relations.

The *teres minor muscle* is a long narrow slip placed near the inferior costa of the scapula, and below the infra-spinatus, to which its origin is, frequently, inseparably united; if the fascia covering it is not removed, let it be done. It *arises* from a smooth surface on the dorsum of the scapula, between the inferior costa and the fossa infra-spinata, and also from the processes of fasciæ which incase it; the fibres run upwards to the tendon of *insertion* which is attached to the inferior of the three depressions on the great tuberosity of the humerus, and some are continued forwards to the bone below this process. The superficial surface is covered by the deltoid, and is partly subcutaneous; and the deep lies on the scapula, long head of the triceps, and articulation of the shoulder joint. The upper border is in contact with the infra-spinatus; and the lower with the teres major, near the inferior angle of the scapula; but as these muscles diverge to their insertions, they have not this relation in front; this border lies on the long head of the triceps, and underneath it turns the dorsal branch of the subscapular: a branch of this artery lies between the teres muscles. Teres minor Muscle. Origin. Insertion. Relations.

The *teres major muscle* is extended from the inferior angle of the scapula to the humerus, and it will be necessary to turn to the front of the arm to see part of its anatomy. Its *origin* is from the rough surface on the dorsum of the scapula a little above the inferior angle, and for some distance along the inferior costa, from the fascia covering the subscapularis muscle; the fibres are directed forwards to the humerus to join the tendon of *insertion* which, about two inches wide, is fixed to the posterior and inner border of the bicipital groove of the humerus. The tendon appears sooner on the anterior than the posterior surface of the muscle, is intimately united to the lower border of the tendon of the latissimus, but not so closely near the bicipital groove, since a bursa intervenes between them; it extends as high as that of the latissimus, and nearly Teres major Muscle. Origin. Insertion.

as far below, as that tendon is wide, and an expansion is sent off from the tendons to the fascia of the arm. In front, the latissimus dorsi, axillary vessels and nerves, and coraco-brachialis and biceps muscles lie on it; and, behind, it is covered, at the inferior angle of the scapula, by the latissimus dorsi, but as this becomes inferior to the teres, this surface is then subcutaneous. When the teres has passed below the inferior costa of the scapula, it is placed in front of the long head of the triceps, and assists to form the posterior boundary of the axilla. The upper border is parallel to the subscapularis, but separated by an intermuscular septum, and by the circumflex artery and dorsal branch of the subscapular; it lies close to the teres minor, as far as the tendon of the triceps, the process of fascia and descending branch only of the dorsal artery intervening. The lower border is in contact with the latissimus, and is received into a hollow formed by the crossing of its fibres, as was seen in the examination of this part of the muscle; but near the humerus, in consequence of the greater extent of its tendon and the ascending of that of the latissimus, the teres projects below it. Between the teres and the lower border of the scapula, with its subscapularis and teres minor muscles, is a triangular space, limited in front by the shaft of the humerus, and it is divided into two by the long head of the triceps which crosses about its centre; the *posterior division*, triangular, is bounded above by the lower border of the scapula and its muscle, below by the teres major, and in front by the long head of the triceps, and through it passes the dorsal branch of the susbcapular artery; the *anterior*, larger in size, because of the greater divergence of the teres from the border of the scapula, is somewhat square-shaped, the teres major being below, the scapula and subscapularis muscle above, the shaft of the humerus in front, and the long head of the triceps behind: the posterior circumflex artery and nerve, which are distributed to the deltoid, pass through it from the front to the back of the arm.

Relations.

Spaces at the lower border of the Scapula.

Before dissecting the supra-spinatus, which would come next in order, the ligaments connecting the clavicle and scapula should be studied, since the acromion requires to be sawn through to expose this muscle.

Dissection.

The clavicle is united to the coracoid process of the scapula by means of a ligamentous band between them, and to the acromion by an articulation, and synovial membrane.

Union of the Clavicle and Scapula.

The *coraco-clavicular ligament*, easily seen by removing some cellular membrane which surrounds it, is a firm ligamentous process connecting the bones. In consequence of parts of this ligament having different directions, two distinct names have been given to these, although they are united posteriorly. The posterior portion, called *conoid*, is triangular in shape, the apex, below, joins the posterior part of the coracoid process, and the base, above, is attached to the tubercle on the under surface

Coraco-clavicular Ligaments.

Conoid portion.

of the clavicle; the anterior, the *trapezoid*, rather square-shaped, is larger than the conoid, and is placed external to it; it is fixed, below, to the inner border of the coracoid process, and, above, to the line extending from the tuberosity on the under surface of the clavicle towards the outer extremity of the bone; the posterior part of this ligament is united to the conoid, but the anterior is separated from it by cellular membrane. Trapezoid.

The acromio-clavicular articulation is formed by the articular surfaces of the clavicle and acromion, retained in contact by ligaments, with a synovial membrane between them; and to see it, the cellular membrane, and fibres of the trapezius and deltoid must be removed. Acromio-clavicular Ligaments.

The *capsular membrane* of this articulation consists of scattered fibres which surround the ends of the bone, and are thicker above and below; which has occasioned separate superior and inferior ligaments to be described to the articulation. Capsular.

The *inter-articular cartilage* is sometimes found between the bones at their upper part only, and the articular surfaces, and the sides of the cartilage are covered by one *synovial membrane*. To see these parts the clavicle may be sawn through external to the coraco-clavicular ligament, and a longitudinal section made through the articulation of it and the acromion. Inter-articular. Synovial Membrane.

The proper ligaments of the scapula are ligamentous bands passing from one part to another of the same bone. Ligaments of the Scapula.

The *coraco-acromial*, or *anterior proper ligament* of the scapula, is a triangular ligamentous band between the acromion and coracoid process. It is attached, externally, by its apex, to the point of the acromion process in front of the articulation to the clavicle, and, internally, by its base which is separated into two portions, to the outer border of the coracoid process of the scapula, the anterior portion, almost transverse, being fixed to its apex, and the posterior, stronger, more oblique, and longer, to its base: the part of the ligament between these two is membranous. The upper surface is covered by the deltoid, the lower forms with the acromion an arch over the supra-spinatus muscle, and articulation of the humerus. Coraco-acromial.

The *posterior proper ligament* of the scapula is a short, strong band of fibres, extended across a notch in the superior costa of this bone, converting it into a foramen; it is fixed in front to the base of the coracoid process, and behind to the superior costa, and through the foramen formed by it passes the supra-scapular nerve, but above it, the artery of the same name. The omo-hyoid muscle arises from it. Posterior Ligament.

Saw through the acromion, so as to remove it with the outer extremity of the clavicle, and the supra-spinatus will be seen after the removal from its surface of a strong fascia which covers it in, as in the case of the infra-spinatus, and is attached to the margins of the fossa. Dissection.

Supra-spinatus Muscle. Origin. Insertion. Relations.

The *supra-spinatus muscle*, also triangular in its shape, is situated in the supra-spinal fossa. Its *origin* is from the surface of the bone in the fossa, as well as from the fascia which covers it; the fibres converge as they pass forwards and outwards to the tendon, which passes over the articulation, to be *inserted* into the upper of the three impressions on the great tuberosity of the humerus; an expansion is sent from the tendon to join with that of the infra-spinatus. The cutaneous surface is covered by the trapezius, and beneath it by the fascia; the muscle lies on the bone in the supra-spinal fossa, and on the artery and nerve which run under it, on the humero-scapular articulation, and on the head of the humerus. The upper border is parallel to the superior costa of the scapula, and in contact with the omo-hyoid muscle, and supra-scapular artery and nerve; the lower rests on the spine of the scapula; the base, towards the base of the scapula, corresponds to the insertion of the levator anguli scapulæ.

Dissection.

Separate the supra-spinatus from the supra-spinal fossa by detaching it at the base, and the infra-spinatus from the inferior depression; and dissect the supra-scapular artery and nerve, which enter beneath the upper border of the supra-spinatus, and the dorsal branch of the subscapular, beneath the infra-spinatus muscle.

Supra-scapular Artery. Supra-spinal branch. Infra-spinal.

The *supra-scapular artery* is one of the branches into which the transversalis humeri divides near the superior costa of the scapula; it enters into the supra-spinal fossa beneath the supra-spinatus muscle, by passing usually above the ligament which converts the notch in this part into an aperture, the nerve being below it. Beneath the supra-spinatus muscle, it gives off the *supra-spinal artery*, which sends outwards and inwards branches to the muscle, and to the articulation, and some enter the bone; the trunk then passes beneath the acromion into the infra-spinal fossa, and terminates in the *infra-spinal artery*, which gives branches downwards to the muscle, and to the inferior angle of the scapula, outwards on the bone to supply it, and to join the posterior scapular; and inwards, some to anastomose freely with the dorsal artery of the subscapular. One or two branches of the supra-scapular ascend by the side of the spine to perforate the attachments of the muscles to this part, and to ramify on the acromion process with the superior and inferior acromial.

Dorsal branch of the Subscapular Artery.

The *dorsal branch of the subscapular* arises from this artery soon after it has passed the head of the humerus; it runs along the posterior wall of the axilla, passing backwards from the subscapular, and lying on the subscapularis and tendon of the long head of the triceps, to reach the posterior of the two spaces at the inferior border of the scapula; the branch then turns through this space, close to the inferior costa which is grooved for it, enters the infra-spinal fossa beneath the teres minor and infra-spinatus muscles, and terminates by supplying the muscles

and fossa, and by anastomosing with the infra-spinal branch of the supra-scapular artery. When it turns round the bone, it gives off a long descending branch, which continues along the inferior costa, between the teres minor and major, to the insertion of the latter; at this point it turns to the dorsum of the scapula, and anastomoses with the other arteries on this surface, and with the posterior scapular. These arteries are accompanied by veins which have the same relations.

Supra-scapular Nerve.

The *supra-scapular nerve*, a branch of the brachial plexus, is dissected to this part in the neck; when it reaches the superior costa of the scapula, it enters the supra-spinal fossa by passing through the notch; the nerve is then directed downwards and outwards beneath the acromion, and a fibrous band which binds it down in this part, to reach the infra-spinal fossa, in which it divides into many filaments that radiate to supply the upper and lower parts of the muscle. In the supra-spinal fossa it gives off, moreover, two filaments, one near its entrance, and the other near its exit from it: these correspond to the supra-spinal branches of the artery, and those below the acromion to the infra-spinal branch of the same vessel.

DISSECTION OF THE ARM.

Dissection.

The dissection of the shoulder being completed, continue with that of the arm: — place the extremity on the table with the front uppermost; make an incision along the centre of the prominence of the biceps, and continue it to about two inches below the bend of the elbow; at its termination, make a transverse one to allow the skin to be raised in two flaps, and remove it from both the front and back of the arm, to dissect the cutaneous veins, nerves, and fascia; a bursa is found between the olecranon and skin. The cutaneous nerves on the outer side of the arm are, from the circumflex, which have been seen on the deltoid, from the musculo-spiral or radial, about the centre of the arm, and from the external cutaneous, in the outer bicipital groove, immediately above the elbow; on the inner side and in front, as in the thigh, the nerves are much more numerous; thus, beginning above, are found the small cutaneous branch of the internal cutaneous, and the cutaneous from the nerve of Wrisberg*; the internal cutaneous perforating the fascia by two branches, over the artery in the middle of the arm; and, nearer the posterior part, to which they are distributed, the cutaneous branch of the musculo-spiral, and the

* There is sometimes a small branch from the two upper intercostal-cutaneous to the integuments over the coraco-brachialis muscle.

long descending branch of the nerve of Wrisberg, about the lower third; and posterior to these and distributed behind are the branches of the intercosto-humeral. The veins are most numerous in front of the bend of the elbow, and the basilic and cephalic ascend from them along the inner and outer sides of the biceps muscle.

Superficial Fascia.

The *superficial fascia* of the arm is thicker in front of the elbow than in the other parts, and contains between its layers the superficial veins and lymphatics, as in the groin. The superficial layer contains the fat, and varies most in thickness.

Veins in front of the Elbow.

In front of the bend of the elbow the cutaneous veins of the forearm, seen issuing from beneath the integument, unite in the two veins of the arm; they are frequently very irregular, but in the normal arrangement they have the following disposition:—a small vein, the radial, lies on the outer side, and is a continuation of the veins of this part of the forearm; some larger ones the anterior ulnar, unite, in front of the inner condyle, to form the ulnar vein, which is then joined by the posterior ulnar from behind; and in the centre is the large median vein. The median, usually the largest of the three, divides, rather below the bend of the elbow, into an internal branch which joins the ulnar, to give rise to the basilic vein of the arm, the communicating branch being named the median basilic; and into an external, which unites, in like manner, with the radial, to form the cephalic vein, and the communicating branch between these is the median cephalic. The point of division of the median is joined by a branch from the deep vein, which perforates the fascia of the forearm. The median basilic and cephalic veins should be studied with care by the dissector, since venesection is practised in them; and the relation of the median basilic to the brachial artery which it crosses, as well as to its varieties, is very important.

Median Basilic.

The *median basilic vein* passes upwards and inwards over the brachial artery, to reach the inner border of the biceps, and to unite with the ulnar in the basilic vein. Its direction is more horizontal than that of the median cephalic, but this varies according to the situation of the median vein; for when this is nearer the inner side of the arm, the median basilic will be more vertical in its direction, and *vice versâ;* in this vertical position the vein will cross the artery more obliquely, and lie along its side for a greater distance. It is covered by the superficial fascia and skin, and is crossed by some small branches of the internal cutaneous nerve; it lies on the aponeurosis of the arm, in the interval between the muscles arising from the inner condyle, and the inner border of the biceps, and crosses the brachial artery, separated from it by a strong aponeurotic layer sent from the tendon of the biceps towards the inner condyle, to join the fascia of the arm, and which is strongest rather below the bend

of the elbow: behind the vein are three or more large branches of the internal cutaneous nerve, which cross it. This vein is more prominent and fixed than the median cephalic, in consequence of its firm support behind, is generally the larger trunk, and is selected for venesection. In cases of high origin of the radial or ulnar arteries from the brachial trunk, it is to this vein, with reference to the operation of venesection, that they have an important relation; for the irregular branch may pass beneath the fascia and vein, as the brachial, increasing the number of vessels behind it, and the chances of injury; or it may be superficial to the aponeurosis of the arm in close contact with the vein, for which, in fat subjects, it is not impossible that it may be mistaken. The *median cephalic*, the other division of the median, runs more vertically upwards and outwards than the median basilic, to reach the outer border of the biceps; it is external to the artery, and loosely supported behind, in consequence of being surrounded by cellular membrane, and lying in the deep groove between the biceps and outer mass of muscles of the forearm; it is covered only by the superficial fascia and skin, and lies on the aponeurosis of the arm, and external cutaneous nerve which perforates the fascia in the outer bicipital depression a little above the vein. This vein is sometimes larger than the median basilic, but, from its position between the muscles, it is difficult to compress or open it.

Median Cephalic.

The *basilic vein*, commencing above the inner condyle, but lower down than the cephalic, by the union of the median basilic and the ulnar, ascends along the inner bicipital depression of the arm, and perforates the aponeurosis about its centre, to join a deep vein, or it continues up to the axillary vein, with which it unites. In its course it is situated over the brachial artery, separated only by the aponeurosis, and is accompanied by the branches of the internal cutaneous nerve which lies to the outer side. The posterior ulnar veins sometimes open below into it instead of joining the ulnar, and it receives cutaneous veins in the arm.

Basilic Vein.

The *cephalic*, formed a little above the elbow by the median cephalic and radial veins, ascends along the outer part of the arm, superficial to the fascia, in the outer bicipital depression, and in the interval between the pectoral and deltoid muscles; and it terminates by perforating, below the clavicle, the aponeurosis of the arm and costo-coracoid membrane, to join the axillary vein. It has no relation to vessel or nerve in its upper part, but in the lower the external cutaneous nerve is behind it.

Cephalic.

The *superficial lymphatics*, placed above the fascia of the arm, require to be injected with mercury to dissect them, and the glands are not found lower than the bend of the elbow; the vessels ascend along the basilic, to join the axillary vein. In the upper part of the course of the cephalic, a lymphatic vessel

Lymphatics.

accompanies the vein, receives the lymphatics from the outer part of the arm, and opens into the axillary glands.

Cutaneous Nerves on the outer side.

The *external cutaneous nerves* of *the musculo-spiral*, the highest of the cutaneous nerves on the outer side of the arm, except those from the circumflex, are two or three in number, and perforate the fascia about the centre of the arm; the smaller branches supply the integuments of the outer and posterior part, but one large descending branch, distributed to the forearm, runs along the outer side of the arm external to the cephalic vein, passes by the elbow joint, and will be afterwards followed as far as the wrist.

External Cutaneous of the Musculo-spiral.

External Cutaneous.

The *external cutaneous nerve*, or branch to the integuments from the musculo-cutaneous of the brachial plexus, perforates the fascia in the outer bicipital depression rather above the elbow joint, descends beneath the median cephalic vein, and soon divides into branches for the forearm.

On the inner side and front

Internal Cutaneous.

The *internal cutaneous nerve* perforates the fascia of the arm about its centre by two branches; the external, the largest, descends beneath the median basilic vein, and divides into many branches for the integuments of the forearm, which pass in front of the elbow joint; the internal also descends beneath the vein, but to the ulnar side of the other, and, below the elbow joint, it winds to the back and inner part of the forearm in which it terminates, extending as low as the wrist. As these nerves pass by the vein they send filaments over it; and they supply the integuments. Near the axilla, the internal cutaneous gives off a small branch which perforates the fascia, and is distributed to the integuments of the inner and upper part of the arm: sometimes, this extends to near the elbow.

Internal Cutaneous of the Musculo-spiral.

The *internal cutaneous of the musculo-spiral* perforates the fascia about the middle of the arm, divides into branches which turn to its posterior part, and may be followed to the olecranon.

Nerve of Wrisberg.

The *nerve of Wrisberg*, in its course down the arm beneath the aponeurosis, gives a small cutaneous branch, which perforates the fascia above the preceding one, and is distributed in the integuments to about the middle of the arm; but the nerve itself becomes cutaneous about the lower third, and divides into numerous filaments which supply the inner and posterior regions of the lower part of the arm, and descend to the olecranon: they join, in front, with the internal cutaneous, and, behind, with the cutaneous nerve of the musculo-spiral.

Intercosto-humeral.

The *intercosto-humeral nerves*, branches of the two first cutaneous nerves of the intercostals, are three or more in number, which cross the tendons of the latissimus and teres, perforate the fascia of the axilla, and are distributed to the integuments covering the inner and posterior part of the upper region of the arm, above the cutaneous of the musculo-spiral: some of the branches descend below its middle.

The *aponeurosis of the arm* will be seen, when the cellular membrane is removed from it, to form a sheath for the muscles both on the front and back of the arm, and to send processes between them. Its fibres are for the most part transverse, though some are scattered and vertical, and they form a white shining structure, which varies in thickness in different parts; thus it is thicker in the depression on each side of the biceps, than over the centre of this muscle; in front of the elbow it is much strengthened by the aponeurotic expansion sent off from the tendon of the biceps to the inner condyle and fascia of the arm, and this is placed between the median basilic vein and brachial artery. Below, the fascia is continued over the depression in front of the elbow to the forearm; and, on each side, it is fixed to the line of the humerus which leads to the outer, and inner condyle of the bone, giving rise to the intermuscular septa which intervene between the muscles on the front and back of the arm; above, it receives some fibres from the tendons of the pectoralis, latissimus, and teres, and is continuous with that of the axilla. On the back of the arm the fascia is stronger than it was over the biceps, it is continued above to the infra-spinatus and deltoid muscles, and is fixed to the spine of the scapula, and below it is prolonged to the arm, and connected to the points of bone of the elbow joint.

Aponeurosis or Fascia of the Arm.

Replace the skin on the back of the arm until the front is dissected; make an incision through the fascia over the prominence of the biceps, and continue it, below, as far as to the division of the integuments; raise the fascia from the anterior surface, extending it on the outer side to the external intermuscular septum, but on the inner rather farther back than this process, so as to expose part of the triceps. In removing the cellular membrane from the muscles, vessels, and nerves, or in examining the anatomy of the muscles, be careful not to displace the natural relations of the trunk of the brachial artery. The prominent muscle in the centre of the arm is the biceps, the coraco-brachialis lying to its inner side half way down the arm, and the brachialis anticus is beneath it; to its inner side is the brachial artery with the terminal nerves of the plexus, and to the outer side below, and in front of the external intermuscular septum, are the origins of some of the muscles of the forearm.

Dissection.

The *biceps muscle* is situated in the centre of the arm, and forms the prominence observable through the skin; it is long and taper, and wider in the middle than at either extremity. The upper part of the muscle consists of two heads or portions; — the internal, the shorter, *arises* in common with the coraco-brachialis muscle, but external to it and separated by an aponeurotic partition, from the apex of the coracoid process of the scapula; the external, consisting of a long roundish tendon, arises within the capsule of the shoulder joint from the upper part

Biceps Muscle.

Origin.

of the glenoid cavity of the scapula, and appears between the tuberosities of the head of the humerus, in a depression, in which it is confined by an expansion from the capsule and pectoralis muscle, — the synovial membrane of the articulation being reflected around it. From these tendons of origin the fibres commence, and descend, forming two fleshy bundles which touch each other about the middle of the arm, and unite in the belly of the muscle, which is flattened from before backwards, terminates rather above the elbow joint in a long roundish tendon, that commences higher on the outer than inner side of the biceps, sends from its inner side, as it is passing in front of the elbow joint, a strong fibrous expansion between the median basilic vein and brachial artery, to join the inner condyle and fascia of the arm, and then sinks into the hollow at the bend of the elbow, between the supinator longus and pronator teres, to be *inserted* behind the tubercle of the radius. The muscle is covered in the lower three-fourths of its extent by the skin and fascia, but above this by the great pectoral and deltoid muscles; at the bend of the elbow the tendon passes deeply into the hollow, lying to the outer side of the brachial artery and median nerve, and is crossed by the radial artery. To the inner side lies the coraco-brachialis muscle to about the middle of the arm, and below this, are the brachial vessels and median nerve: this border is the guide to the vessel which is rather overlapped by it in the lower half of the arm; the outer border, corresponding to the cutaneous depression on the outer side of the biceps, is in contact, above, with the pectoralis major, and below, with the muscles of the outer part of the forearm, arising above the outer condyle. The parts on which the muscle lies will be better seen when it is cut through in a subsequent part of the dissection; they are, below, the brachialis anticus muscle and musculo-cutaneous nerve, then, on the bone, above the brachialis, and it partly overlaps the coraco-brachialis; above this, it is contained in the axillary space with the vessels and nerves, the inner head being united to the coraco-brachialis; and it lies on the tendons of the latissimus and teres, on the anterior circumflex artery, and on the subscapularis muscle which separates it from the articulation of the shoulder, and head of the humerus. The relations of the long head to the articulation, and the insertion into the radius, will be afterwards dissected.

Insertion.

Relations.

Coraco-brachialis Muscle.

The *coraco-brachialis muscle*, so named from its attachments, is slender and roundish, and is situated with the upper part of the biceps in the axillary space. Its *origin* is fleshy from the tip of the coracoid process, in common with the short head of the biceps; the fibres are vertical, and descend, the internal being the longest, to be *inserted* by a tendon into the rough surface on the inner side of the humerus, about opposite to the insertion of the deltoid on the outer, but the height of this attachment to the bone varies. This muscle is contained in the axillary space,

Origin.

Insertion.

Relations.

and is therefore covered by the pectoralis major, the tendons of the latissimus and teres being behind it; part of it is subcutaneous and prominent in the axilla, when the arm is carried upwards, and is the guide to the axillary artery: the brachial artery and accompanying nerves lie on its insertion into the bone. It covers the subscapularis muscle, and tendons of the latissimus and teres, the anterior circumflex artery, and the humerus, into which it is inserted; perforating the muscle is the musculo-cutaneous nerve. The outer border is in contact with the short head of the biceps; and the internal has along it the artery with its accompanying veins and nerves, except inferiorly, where they lie on it.

Trunk of the Brachial Artery.

The *brachial artery* extends from the lower border of the tendon of the teres major muscle, where the axillary ceases, to the hollow of the bend of the elbow, or to the coronoid process, opposite which it divides into the radial and ulnar arteries. The vessel, with its accompanying veins and nerves, lies at first to the inner side of the humerus, then in front of it, and inferiorly extends below it into the forearm; its course is marked, externally, by the depression on the inner side of the biceps. From its different relations to muscles and nerves when in these several positions with reference to the bone, it is divided into three portions; — the upper extending to the middle of the arm, at which point the brachial crosses to the front of the coraco-brachialis; the middle from this to the bend of the elbow; and the third, very short, whilst the vessel lies in the hollow at the bend.

Upper part.

The *upper part*, about three inches in extent, closely surrounded with its nerves and veins, has the following relations: — external to it is the coraco-brachialis, and, at the lower part, the biceps; internally, the artery is subcutaneous, and may be felt pulsating during life. It is covered by the fascia and integument, the basilic vein lying over it, when this extends high up the arm, and the internal cutaneous nerve is in contact with its cutaneous surface, unless when this nerve perforates the fascia high up, and is then separated by the fascia; it lies over the long head of the triceps for about two inches, but separated from it by the musculo-spiral nerve and superior profunda artery, and below this it rests, for about one inch, on the inner head of the triceps extensor; it then winds in front of the coraco-brachialis, and enters into the relations of the middle part. To the outer side and in close contact with it, is the median nerve which separates it from the coraco-brachialis muscle, and, sometimes, the musculo-cutaneous is found in this position; to the inner, the ulnar nerve which continues this relation to the artery as far as the insertion of the coraco-brachialis, and lies close to it, separated only by the vein; superficial to it is the internal cutaneous, until it perforates the fascia; and behind it, for as far as it corresponds to the long head of the triceps, is the musculo-spiral nerve. It is

accompanied by the venæ comites, which unite across the artery,
Middle. and lie between it and the nerves. The *middle part* occupies the lower half of the arm, and is accompanied by only one nerve, since the ulnar leaves opposite the insertion of the coraco-brachialis. The brachial is superficial in this part as in the other, being covered only by the fascia and integument, except at the bend of the elbow, where it is crossed by the median basilic vein, and is covered by the fascia of the biceps, which passes to the inner side of the arm; the basilic vein lies over its course. To the outer side is the biceps muscle, which overlaps it more or less, according to its size; and it is placed on the brachialis anticus muscle. The *median nerve* closely accompanies it, passing either before or behind it to its inner side, in which position it lies at the bend of the elbow; but, in crossing superficially to the artery, the nerve lies obliquely on it in the greater part of the extent of this middle portion, for it commences to pass over it close to the insertion of the coraco-brachialis, and is placed to its inner side about two inches above the elbow joint. The veins
Lower. are the same as in the other part. In the *lower part*, the artery dips into the hollow, bounded, externally, by the supinator longus, and internally, by the pronator teres, and it divides opposite the coronoid process into radial and ulnar arteries. In the space with it are found the tendon of the biceps, and the median nerve, the tendon lying external, and the nerve internal to it; the artery and tendon have a direction to the radial side of the arm, and the nerve to the ulnar, which has caused them to be separated by an interval of half an inch. It is covered only by the fascia of the arm, and aponeurosis of the biceps, and lies on the brachialis anticus muscle. In the outer part of the space, and covered by the supinator longus, is the musculo-spiral nerve. This part of the artery is also accompanied by veins.

Previously to following the branches of the artery, examine the anatomy of the trunks of the nerves in relation with it.

Trunk of the Median Nerve. The *median nerve* commences in the brachial plexus by two roots or portions, one from the external, and one from the internal cord; the inner one crosses to the outer side of the axillary artery, to unite with the other to form the median nerve, which descends through the arm, lying close to the outer side of the brachial artery, as far as to the insertion of the coraco-brachialis, but the nerve then crosses it very obliquely, and is found to its inner side a little above the elbow*; it may pass superficially to it, or between it and the brachialis anticus, to reach the inner side of the artery. It now enters the hollow at the bend of the elbow, lying internal to the vessel, and is separated

* The median nerve sometimes leaves the artery at the middle of the arm, passes to the internal intermuscular septum, along which it descends to the bend of the elbow, and enters the space under cover of the pronator teres muscle.

at its termination by an interval of half an inch; it then continues to the forearm by passing between the two heads of the pronator teres muscle. This nerve supplies no branch until it approaches the muscles of the forearm, but it is often joined by a branch from the musculo-cutaneous below the coraco-brachialis muscle; and it is covered by the same parts as the artery, being deep in the axillary space, and superficial below this.

Trunk of the Ulnar Nerve.

The *ulnar nerve*, given off from the inner part of the plexus, lies internal and close to the axillary, and also to the brachial artery, as low as the insertion of the coraco-brachialis muscle; it then leaves the artery suddenly, passes to the inner side of the arm, perforates the internal intermuscular septum, and, placed behind this structure, descends, surrounded in a sheath of muscular fibres of the triceps, to the interval between the olecranon and inner condyle; and it leaves the arm by passing between the two heads or attachments of the flexor carpi ulnaris. It is accompanied by the inferior profunda vessels, and by a small nerve from the musculo-spiral, to the inner head of the triceps muscle. No branches are given off by this nerve until it enters the interval between the olecranon and inner condyle; whilst in the axilla, it is covered by the pectoral muscles, but below this it is in part superficial, and in part covered by the intermuscular septum and fibres of the triceps.

Trunk of the Internal Cutaneous.

The *internal cutaneous nerve*, another branch of the plexus, from the inner cord, of which it arises in common with the preceding, lies internal to the axillary artery, as far as to the tendon of the latissimus; but, below this, it is superficial to this vessel, and to the brachial, with which it continues to about the middle of the arm, where it divides into two branches, which separately pierce the fascia, and become cutaneous: these then descend to the elbow joint, internal to the position of the artery, and divide into branches for the forearm. This nerve occasionally divides higher up into its branches which perforate the fascia; it gives off a small branch to the integuments of the upper part of the arm: this was dissected with the cutaneous nerves.

Trunk of the Nerve of Wrisberg.

The *nerve of Wrisberg* has been seen to arise from the plexus either with the ulnar, or, very high up, from the posterior cord of the plexus with the musculo-spiral and circumflex: the relation of it to the vein and other nerves, is described with the brachial plexus. It crosses the border of the subscapularis, gives off, to the upper part of the arm, a small cutaneous filament which has been dissected with the nerves to the integument; it then continues beneath the fascia, along the inner side of the arm, and on the triceps muscle, perforates the fascia about the lower third, and is distributed, as seen, to the integuments of the region of the elbow, joining the internal cutaneous, and cutaneous branch of the musculo-spiral.

Branches of the Brachial Artery. The *brachial artery* gives externally and internally many branches, but the external for the supply of the muscles are not named; those from the inner and posterior part are the superior profunda with the musculo-spiral nerve, the inferior profunda with the ulnar, the anastomotica near the elbow, and the nutritious artery through the tendon of the coraco-brachialis.

Superior Profunda. The *superior profunda*, the largest branch, leaves the artery at the lower border of the tendon of the teres, and winds round the bone to the back of the arm, so that it will be dissected with the triceps muscle.

Inferior Profunda. The *inferior profunda* artery arises from the middle part of the brachial, or whilst this lies on the coraco-brachialis muscle; it passes downwards and inwards, perforates the internal intermuscular septum, diverges from the trunk of the brachial, and accompanies the ulnar nerve, beneath and internal to which it lies, to the interval between the olecranon and inner condyle, to anastomose with the anastomotic and posterior ulnar recurrent arteries. It gives branches in front of the intermuscular septum, which descend to inosculate with the anastomotic artery, and some behind it to supply the triceps muscle. It is not very uncommon for this branch to come from the superior profunda branch.

Anastomotic. The *anastomotic artery* is the last branch of the brachial; it arises about an inch above the elbow, passes almost transversely inwards over the brachialis anticus, perforates the internal intermuscular septum, and anastomoses with the inferior profunda and recurrent ulnar; it gives branches to the brachialis muscle, and sends some down beneath the pronator teres to join with the anterior ulnar recurrent artery in front of the articulation.

Nutritious Artery. The *nutritious artery of the humerus* comes from the brachial, whilst it lies on the coraco-brachialis muscle; it perforates the tendon of the muscle to enter an aperture in the humerus in this part, and is distributed to the cancellated structure of the bone. Previously to entering the bone it gives some small branches to the coraco-brachialis muscle.

Veins. The *brachial veins*, two in number, accompany the brachial artery, which they surround in a kind of venous plexus, by means of the branches of communication that connect them; the small veins that they receive correspond to the branches of the arteries.

Dissection. Cut through the tendon of the biceps muscle below, and turn upwards the belly of the muscle, remove any cellular membrane that may prevent the examination of the brachialis anticus muscle, or the musculo-cutaneous nerve and its branches.

Brachialis anticus Muscle. The *brachialis anticus* is a flat muscle, situated in front of the lower half of the humerus, and extending from the insertion of the deltoid to the upper part of the ulna. It *arises* from the

Origin. outer surface of the humerus, by two fleshy digitations which

embrace the insertion of the deltoid, the outer separating this muscle from the outer head of the triceps, and the inner being between the deltoid and coraco-brachialis; from the front of the humerus between the lines leading to the condyles, nearly down to the articulation; and from the internal intermuscular septum, and capsule of the elbow joint; from this extensive origin the fibres descend, the outer and inner being most oblique, and converge to the tendon, which extends highest on the outer side, sends off some fibres to the aponeurosis of the arm, and is then *inserted* into the ulna below the coronoid process of this bone. Inser-tion. This muscle lies between the humerus and the other parts examined, and it is therefore covered by the biceps, the brachial artery and median nerve, with the anastomotic branch of artery, as well as by the musculo-cutaneous nerve; and it lies on the humerus and articulation of the elbow. On the inner side it is Rela-tions. limited by the internal intermuscular septum, which it touches, and from which fibres arise; but on the outer, it is separated from this structure by the supinator longus, and extensor carpi radialis longior muscles, which arise from the line leading to the outer condyle, and are placed in front of the septum; the musculo-spiral nerve lies on the outer margin, between it and the supinator longus. The tendon of insertion, and its relation to the articulation, will be seen when the muscle is divided.

The *musculo* or *external cutaneous nerve* * has been seen to Muscu-lo-cuta-neous Nerve. arise from the outer cord of the brachial plexus, opposite the lower border of the pectoralis minor; it then passes downwards and outwards, over the insertion of the subscapularis into the head of the humerus, perforates the coraco-brachialis muscle, and descends obliquely between the biceps and brachialis anticus to the outer side of the tendon of the biceps, and near the elbow, becomes cutaneous, and is distributed to the integuments of the forearm. In passing by the elbow joint, it lies beneath the median basilic vein. This nerve may not perforate the coraco-brachialis, or it may be connected to the median by a large branch, after it has passed through the muscle. The branches that it sends off before it perforates the fascia of the arm are muscular; whilst in the centre of the coraco-brachialis, it sup- To Co-raco-brachi-alis. plies it with filaments, and, before it enters it, gives to the upper part of the muscle another branch which also supplies the short head of the biceps. It gives branches to the biceps, when under To Bi-ceps. cover of this muscle, and one long slender filament sometimes descends along the outer side of the artery to the articulation. The greater number of the branches are distributed to the sub- To Bra-chialis. stance of the brachialis anticus, to which they radiate from a common trunk.

In the dissection of the back of the arm, flex the forearm Dissec-tion.

* Or perforans Casserii nerve.

upon the arm, make an incision through the fascia to below the olecranon process, and raise it with the cellular membrane beneath, from the surface of the large triceps muscle which occupies this region.

The Triceps Muscle. The *triceps extensor cubiti muscle*, so called from its use, and division, above, into three heads, is larger below and in its centre, than at its upper attachment: the processes into which it is separated are called, from their position, middle, outer, and

Middle Head. inner heads. The *middle head*, the longest, arises from a ridge, about an inch long, on the inferior costa of the scapula, immediately behind the glenoid cavity, also from the lower angle of this cavity, like the biceps from the upper, and it is here connected to the capsule of the shoulder joint; this attachment is tendinous on both surfaces, but the tendon extends farthest on the side next the humerus. From this head the fibres pass vertically downwards, forming at first a thin flat belly situated between the two teres muscles; but it is soon increased in size, and turns upon itself, so that the anterior and inner surface becomes posterior, unites with the outer head about the middle of the arm, and with the inner, at the union of the middle and lower thirds, and ends below in a tendon on both its cutaneous and deep surfaces; and by the union of these there results a strong tendinous process, which is *inserted* into the upper and posterior part of the olecranon, a bursa intervening, and a fibrous prolongation is sent to the fascia of the arm. The deep tendon, concealed in the muscle, will be exposed by separating the middle head from the internal nearly down to the olecranon: it commences on the under surface of this part, above its centre, becomes wider and stronger below, receiving the muscular fibres from the inner and outer heads, and near the olecranon approaches the surface to join, on the cutaneous surface of the muscle, with the superficial tendon which occupies nearly its whole width, extends as high as the junction of the outer and middle portions, and further on the outer than the inner

Outer Head. side. The *outer head*, pointed above, is attached to the posterior surface of the humerus, below the insertion of the teres minor muscle; and to the outer part of this surface of the bone, behind the ridge leading to the outer condyle, as low down as the condyle; also to the external intermuscular septum. From this origin the fibres take different directions; the superior, vertical, descend to the superficial tendon, and meet the long head about the centre of the arm; the others decrease in obliquity from above downwards; and the inferior are transverse and continuous with the small anconeus muscle: they are chiefly inserted into the under surface of the deep tendon, but some join the outer margin of the superficial. Over the musculo-spiral nerve and profunda artery, which perforate this head, the fibres arise from

Inner Head a tendinous arch. The *inner head*, more fleshy than either of

the others, is shorter, and arises by a pointed and muscular portion from the humerus, below the insertion of the teres major; from the inner part of its posterior surface as low as the inner condyle, and from the internal intermuscular septum; the upper fibres run outwards and downwards, to join the deep tendon of the middle head, and the inferior, almost transverse, have the same attachment: some of these fibres go straight to the olecranon and capsule of the joint. The greater part of the triceps muscle is subcutaneous, the upper portion only being covered by the deltoid; and it lies on the humerus, musculo-spiral nerve, and profunda artery, and on the articulation of the elbow. The long head lies between the teres muscles, the major being in front of it and the minor behind; it divides the space below the inferior border of the scapula into two parts, and lower down, it is separated from the humerus by the musculo-spiral nerve and superior profunda artery. The outer head and border, the longest portion of the muscle, fixed to the bone, corresponds to the insertion of the deltoid, to the brachialis anticus, and muscles of the forearm arising from the line leading to the outer condyle, separated from these, nevertheless, by the intermuscular septum: the musculo-spiral nerve and profunda artery perforate this border. The inner head and border have along it the insertion of the coraco-brachialis, and the brachialis anticus, the intermuscular septum intervening also on this side; the ulnar nerve and inferior profunda artery are in contact with it as they run behind the septum, and are incased in a sheath of muscular fibre, and the superior profunda and musculo-spiral nerve separate this head from the outer.

Relations.

The *intermuscular septa* are two processes of fibrous membrane, continuous with the investing aponeurosis of the arm, and are fixed to the ridges which extend upwards from the condyles of the humerus: they divide, inferiorly, the muscles on the front from those on the back of the arm, and give origin, by their surfaces, to muscular fibres. The *internal*, the largest and strongest, and attached to the line continued to the inner condyle, extends as high as to the insertion of the coraco-brachialis muscle, from the tendon of which it receives some fibres; it is placed between the triceps behind, and brachialis anticus before, to both of which it gives attachment, and it is perforated near its upper part by the ulnar nerve and inferior profunda artery, and near its lower by the anastomotic artery. The *external*, thinner, connected to the line leading to the outer condyle, reaches to the insertion of the deltoid, from which it also receives some fibres, and the upper part of the septum arches over the outer portion of the brachialis anticus, to the deltoid; behind the septum is the outer head of the triceps, and in front of it the supinator longus, and extensor carpi radialis longior muscles,

Intermuscular Septa.

Internal.

External.

which separate the brachialis anticus from it. The musculo-spiral nerve and superior profunda artery perforate it.

Dissection. To follow the superior profunda artery and its accompanying nerve through the substance of the triceps, the long head may be cut across below the level at which they wind round the bone, and to trace the branches down to the anconeus, cut through the centre of the muscle in the line of union of the outer with the middle head. The branches given off by the nerve and artery on the outer side of the humerus will be found, in front, between the brachialis anticus and supinator longus muscles.

Superior Profunda Artery. The *superior profunda artery*, already seen to be the first branch of the brachial, arises below the tendon of the teres major, descends behind the brachial for some way, so as to separate it from the long head of the triceps; then turns round the humerus from the inner to the outer side, in the groove in the bone, placed at first between the outer and inner heads; but it afterwards perforates the former, and the external intermuscular septum, and, in this position in the arm, divides into its terminal branches: one of these descends in front of the intermuscular septum with the nerve, and anastomoses with the radial recurrent artery between the brachialis anticus and supinator longus muscles; the others continue along and behind the septum, to inosculate with branches of the interosseous recurrent artery on the outer side of the elbow. It is accompanied by the musculo-spiral nerve; and, as it lies beneath the fibres of the outer head, is covered by a tendinous arch; it gives many branches in its course; thus, previously to turning behind the bone, it supplies large branches to the triceps, coraco-brachialis, and deltoid muscles; these anastomose with the other arteries supplied to the muscles. Between the triceps and the bone many muscular arteries are distributed to the triceps; amongst these are two long descending branches; the external of the two runs with a branch of the musculo-spiral nerve to the interval between the olecranon and outer condyle, and anastomoses in the anconeus muscle, with the recurrent interosseous which ascends beneath it; the internal continues to the olecranon and inner part of the arm, supplying the triceps, and communicates with the ulnar recurrent and inferior profunda arteries. The artery is accompanied by a vein, which has the same anatomy.

Musculo-spiral Nerve. The *musculo-spiral* or *radial nerve* arises with the circumflex, from the posterior cord of the brachial plexus, and behind the axillary artery. It descends over the subscapularis muscle, the tendons of the latissimus and teres, and lies in contact with the long head of the triceps, which it separates from the brachial artery; the nerve then winds with the superior profunda artery between the humerus and long head of the triceps, and next between this bone and the external head, to reach the outer

side of the arm; it now perforates the attachment of this head, the external intermuscular septum, and the supinator longus muscle, and, arrived at the anterior aspect of the arm, changes its direction, descending vertically over the brachialis anticus, and between it and the supinator longus, and extensor carpi radialis longior, to the external condyle of the humerus, on which it divides into the radial, and posterior interosseous nerves; — the radial runs with the radial artery, and the interosseous perforates the supinator brevis muscle to reach the back of the forearm. This nerve gives branches to the inner side of the arm whilst behind the brachial artery; to the back, when between the muscle and bone; and to the outer side, after it has perforated the outer head of the triceps.

Branches on the inner side.

On the inner side of the arm, the first branch is the *internal cutaneous* of the *musculo-spiral:* this is placed beneath the fascia of the arm, which it perforates about the middle, and it is distributed to the integuments of the posterior and lower part. The next branch is a long slender nerve to the inner head of the triceps, which descends, in close contact with the ulnar nerve, to the lower third of the arm, and is then distributed to this part of the muscle. Two or more branches are supplied to the long head of the triceps, in which they end. Whilst it is beneath the triceps, the branches for the most part supply this muscle; but one long nerve to the anconeus descends between the outer and middle heads, accompanied by an artery, to the interval between the olecranon and external condyle, and is distributed to the under surface of the anconeus; it gives branches to the outer head of the triceps in its course. When the nerve perforates the outer border of the triceps, it gives the cutaneous filaments to the arm, and one, larger than the rest, the *external cutaneous* of the musculo-spiral, descends to the outer and posterior part of the forearm as far as the wrist. Between the brachialis anticus and supinator longus it gives branches to these two muscles, as well as to the extensor carpi radialis longior, and it then divides into the radial and posterior interosseous nerves.

Internal Cutaneous.

To the inner and middle heads of the Triceps.

On the back of the arm to the Triceps and Anconeus.

On the outer side.

External Cutaneous.

Muscular.

Dissection.

The dissection of the arm down to the elbow is now completed, with the exception of the anatomy of the shoulder joint; but if the dissector should feel that his acquaintance with it is not very perfect, let him re-examine any part that may be necessary before proceeding farther in the dissection. To expose the articulation of the shoulder, it is necessary to detach from it the tendons of the subscapularis, supra- and infra-spinatus, and the teres minor, as far as can be done, those of the subscapularis and supra-spinatus are most closely united to it: remove the cellular membrane from the enveloping capsule. This articulation admits of more motion than any other in the body, and now the muscles are removed, it will be perceived how readily the

head of the bone leaves the glenoid cavity of the scapula, so that the close approximation of the articular surfaces does not depend upon the ligaments which remain entire, but upon the surrounding muscles.

Scapulo-humeral Articulation.

The surfaces of bone which enter into the articulation of the shoulder, are the hemispherical head of the humerus, and the glenoid fossa of the scapula; these are covered with cartilage, over which a synovial membrane is reflected, and are enveloped by a capsule; the cavity of the scapula is moreover deepened by an orbicular ligament.

Capsular Ligament.

The *capsular ligament* is a thin membranous structure, formed of cross fibres, which surrounds the articular ends of the bones. It is thicker above than elsewhere, because of the presence of some additional fibres, called the coraco-humeral ligament, together with some fibres from the tendons of the muscles surrounding it; below the coracoid process is an aperture through which the synovial membrane projects beneath the tendon of the subscapularis. The upper part or border is fixed around the neck of the scapula, and is connected below by fibres to the middle head of the triceps; the inferior, to the anatomical neck of the humerus, surrounding its hemispherical articular surface, and it is prolonged lower on the under than upper surface; its continuity is interrupted between the tuberosities of this bone by the tendon of the long head of the biceps, which enters within the capsular membrane, but the margins of the opening are removed by the expansion prolonged upwards to the capsule, on the tendon, from the pectoralis major muscle. The following muscles will be found to surround the capsular ligament: — above and externally, are the tendons of the supra-spinatus, infra-spinatus, and teres minor, which unite together to form a tendinous investment for it, and give it some fibres; internally and below, is the subscapularis, whose tendon is inseparably united to it; and inferiorly, the tendon of the middle head of the triceps is in contact with it: this part of the capsule is uncovered by muscle.

Coraco-humeral Ligament.

The thickened part of the capsule results from some fibres crossing, as a band, the upper and outer part of the articulation, and this is called the *coraco-humeral* or *accessory ligament*. It is attached to the coracoid process of the scapula, close to the posterior divergent part of the coraco-acromial or anterior common ligament of this bone, and is therefore connected to the capsule which ascends in that direction; it is directed outwards over the head of the bone, united to the capsule, and the fibres are fixed to the great tuberosity of the humerus with the tendons of the muscles inserted into it.

Tendon of the Biceps.

Open the articulation by cutting through the capsule near its attachment to the scapula, to see its connection to the bone, as well as the tendon of the biceps. This tendon, roundish in shape as it lies in the bicipital groove between the two tuberosities of

the head of the humerus, in which it is confined by a prolongation of fibrous membrane to the capsule, becomes flat as it leaves the groove; it then turns over the head of the bone, is attached to the upper angle of the glenoid cavity of the scapula, and is connected, on each side, with the glenoid ligament surrounding the fossa.* It is free and moveable within the capsule, and, by being arched over the head of the bone, serves as a ligament in assisting to retain it in its position. Although the tendon is within the capsule, it is still said to be external to the joint, because it does not perforate the lining synovial membrane, which is reflected around it, and sends a process on it into the bicipital groove.

Glenoid Ligament.

The *glenoid ligament* is a firm fibro-cartilaginous band about two lines deep, surrounding the articular fossa of the scapula: it is connected, above, to the processes sent off on each side from the tendon of the biceps, and below to the tendon of the middle head of the triceps. It consists of fibres which come from the edge of the fossa, and mix with the others. It serves to deepen the shallow articular fossa of the scapula.

Synovial Membrane.

The *synovial membrane* covers the articular surfaces of the bones as well as the inner side of the capsule; it is reflected around the tendon of the biceps so as to shut it out from its cavity, and is prolonged by a *cul-de-sac* into the bicipital groove, the sides of which it lines, after being reflected from the tendon. On the inner side of the articulation it passes through the aperture in the capsule, and either communicates with the bursa placed beneath the subscapularis, or, when this is absent, sends a prolongation beneath the muscle to supply the place of the bursa.

DISSECTION OF THE FOREARM.

Dissection.

In the dissection of the forearm, place the hand with the palm upwards; make an incision from the elbow to the wrist, and terminate it by a transverse one; the extremities of this are to be prolonged along the inner and outer borders of the hand to the clefts of the fingers, to allow the integument to be removed from its posterior surface; raise the skin from the front and back of the forearm, as well as from the back of the hand, and dissect out the cutaneous veins and nerves in the superficial fascia. Along the inner side of it, in front, are the ulnar veins, and internal cutaneous nerve, with a cutaneous branch of the ulnar; on the outer, the radial veins, and the cutaneous

* The tendon may, occasionally, be found fixed to the head of the humerus, as it lies in the bicipital groove.

nerves from the musculo-cutaneous and musculo-spiral, which extend behind; on the back of the hand, as on the foot, is a plexus of veins, with the cutaneous branches of the radial and ulnar nerves, to supply the dorsum of the hand and fingers. Small cutaneous bursæ are placed between the skin and knuckles.

Cutaneous Veins on the back of the Hand. On the dorsum of the hand is a venous arch, which receives by its convexity the digital veins, and sends off from its concavity branches to the arm; the outer termination is by a branch that lies in the first metacarpal space, and is called cephalic vein of the thumb; and the inner by another, called salvatella, which lies on the fifth space, and is continuous with the ulnar vein.

Of the Arm. Radial Vein. The *radial vein* commences on the outer side of the back of the hand, by the *cephalic of the thumb* or outer termination of the arch, ascends along the outer and posterior part of the forearm to about its middle, being joined by branches from the arch, and from the ulnar vein; it then turns forwards over the radius, ascends in front of the elbow, and joins above this with the median cephalic, to give rise to the cephalic vein: the external cutaneous nerve accompanies it. Sometimes there are two radial veins which unite into one below the bend of the elbow.

Ulnar. The *ulnar veins* are generally two, an anterior and a posterior; the *posterior*, the largest, commences below by the *vena salvatella*, and branches from the back of the hand, ascends along the inner and posterior part of the forearm, and near the elbow comes forwards to join the anterior, and the trunk, resulting from the junction of the two, unites with the median basilic to form the basilic vein; some of its branches may open into the basilic. The *anterior* commences near the wrist and lower part of the forearm, runs on its front to the elbow, receiving branches of communication from the posterior, and it ends by joining with it in front of the inner condyle. Branches of the internal cutaneous nerve run with these veins.

Median. The *median vein* commences in front, near the wrist, by some small veins from the thenar and hypothenar eminences of the palm of the hand, and it is joined by some branches from the deep ulnar and radial veins; it then ascends, increasing in size, along the centre of the forearm, and near the elbow divides into an external branch—the median cephalic—which joins with the radial in the cephalic vein of the arm, and an internal—the median basilic—which unites with the ulnar to form the basilic. A deep vein—the communicating—joins it at its point of division: a branch of the internal cutaneous nerve runs with it in the forearm.

Cutaneous Nerves. Internal Cutaneous. The *internal cutaneous nerve*, before seen at the bend of the elbow, to consist of an anterior and a posterior branch, can now be followed to its termination; the *anterior* divides into numerous filaments, which are distributed to the integuments of the inner

part of the forearm as low as the wrist, and communicate with a cutaneous filament of the ulnar, which perforates the fascia, generally, in the lower third of the forearm: one or more branches of this division accompany the median vein, and extend to the wrist. The *posterior* division winds backwards below the elbow, and distributes filaments to the posterior part: these extend to the wrist.

External Cutaneous of the Musculo-cutaneous.

The external cutaneous nerves are two, which have been dissected in the arm; the *anterior*, or *cutaneous* of the *musculo-cutaneous*, passes beneath the median cephalic vein, and divides into branches which supply the integuments of the forearm, and descend to the wrist, both internal and external to the radial vein; and some of the filaments may be followed to the integuments of the ball of the thumb. At the wrist, the internal branches join with the radial nerve, and one perforates the fascia, runs on the radial artery, surrounding it with branches which accompany it to the back of the wrist, and give filaments to both the front and back of this articulation. The branches external to the radial vein supply the outer and posterior parts of the forearm with cutaneous nerves. The *posterior* in position, or *cutaneous* of the *musculo-spiral*, lies along the outer and posterior part of the forearm, distributing filaments to the integument as far as the wrist.

Of the Musculo-spiral

Radial Nerve.

The *cutaneous branch*, or termination of the *radial nerve*, perforates the fascia, along the radial border of the forearm, in its lower third; it supplies filaments to its lower part and to the hand, and then descends to the inferior extremity of the radius, and divides into two branches; the *external*, the smaller, joins the external cutaneous branch of the musculo-cutaneous nerve, and continues to the radial border of the thumb, of which it is the cutaneous dorsal collateral branch, and in its course it gives filaments to the ball of the thumb; the *internal* divides on the back of the hand into many branches, one of these passes forwards to the ulnar side of the thumb; others to both sides of the index finger; and one, to the radial side of the middle finger, joins with a branch from the ulnar, to supply the opposed sides of this and the ulnar finger.

Cutaneous of the Ulnar Nerve.

The *cutaneous branch of the ulnar nerve*, for the back of the hand and fingers, appears by the styloid process of the ulna, and divides into branches; some of these ascend on the back of the hand, but the others, larger, descend to supply both sides of the little, and the ulnar side of the ring finger; and a small branch joins with one from the radial, to supply the opposed sides of the ring and middle fingers: this nerve sends a branch along the inner side of the hand to unite with the nerve supplied to the little finger from the palmar portion of the ulnar nerve. The cutaneous nerves to the dorsum of the fingers and thumb supply the integuments of the back of the fingers; they

extend to about their middle, join with a dorsal branch from the large nerves on their palmar surface, and are then continued forwards to the extremities: these can be followed by removing the integuments from one or two fingers.

Fascia of the Arm.

The *aponeurosis of the forearm* forms a white shining covering, which surrounds it, and through this are seen longitudinal white bands, marking the intervals between the muscles, into which processes are sent to separate them from each other. Its fibres cross obliquely, and constitute a membrane thicker below than above, and it receives some fibres near the condyles of the humerus from the tendons of the muscles beneath: on the inner side of the forearm, the fascia is attached to the margins of the ulna, and leaves a part of this bone subcutaneous. On the front it is thinner than behind, is continuous above with that of the arm, and receives some fibres from the biceps and brachialis anticus, and below, it ends in the anterior annular ligament; it is thin and smooth along the depression on the radial side of the forearm, corresponding to the position of the radial artery, and near the wrist the tendon of the palmaris longus projects through it, and has a sheath of the fascia prolonged on it; some cutaneous veins and nerves also perforate it on this surface. A horizontal process of the fascia separates the numerous muscles on the front of the arm, into a superficial, and deep set. The fascia is thicker behind than before, sends a horizontal process to divide the muscles into two layers, and is attached internally to the ulna. It is connected above to the olecranon, and receives some fibres from the tendon of the triceps; but behind the wrist it is thickened by some transverse bands, to form the posterior annular ligament, and is then continued over the back of the hand, on which it becomes very thin and cellular.

Dissection.

Replace the skin on the back of the forearm, divide the fascia in front, along the centre, to the wrist*, and take it away with the cutaneous nerves and veins, without injuring the radial artery, which lies, superficially, in nearly the whole length of the depression on the radial side of the arm,—the ulnar being situated deeply: remove the fascia on the inner side back to the ulna; it adheres closely in the upper part to the muscles beneath. When the fascia is removed, a large mass of muscles is seen, on the front of the forearm, to arise from the inner condyle; and on the outer side, another set, larger than the internal, which arises from the outer condyle, forms the prominence of the outer side of the forearm, and between the two is the radial artery. The inner bundle, the only ones to be examined in the dissection of the front, is thick and fleshy above, forming the projection on the inner and anterior part of the forearm; but

* The dissector is sometimes advised to commence the forearm with the back: this he may do by turning to its dissection.

the muscles, composing it, end below in tendons, which are inserted into the bones of the carpus, metacarpus, or phalanges: these have been divided, from their position, into superficial and deep, and, from their function, into pronators * and flexors. The superficial set, consisting of five muscles, has one pronator and four flexors, which have the following position: — the most external is the pronator, and the muscle next it, directed to the radial side of the forearm, the flexor of the radial side of the wrist, or the flexor carpi radialis; the most internal muscle, the flexor of the ulnar side of the wrist, or the flexor carpi ulnaris; and between them, and deeper than they, the superficial flexor of the fingers, or the flexor sublimis digitorum; and on this last is a long slender muscle, often absent,—the palmaris,—which is attached to the fascia of the hand. The deep layer, not now seen, and arising from the surfaces of the radius and ulna, has a deep pronator, and two flexors—one of the thumb, and the other the deep flexor of the fingers. In examining the relations of the muscles of the superficial layer, by partially separating them from each other, be careful not to destroy the relations of the radial artery; clean the surfaces of the muscles as well as the radial and ulnar arteries: the ulnar artery is superficial only in the lower half of the inner side of the forearm.

Pronator Teres Muscle.

The *pronator radii teres*, the most external of the muscles which arise from the inner condyle of the humerus, is extended from this point to about the middle of the radius: it is thick and roundish, and forms the inner boundary of the triangular space at the bend of the elbow.

Origin.

It *arises* by means of a tendon common to all the muscles of the superficial layer, from the inner condyle of the humerus, from the septum between it and the flexor carpi radialis to its inner side, from the fascia covering it, and by a slender tendinous portion from the anterior and inner surface of the coronoid process, which is interposed between the median nerve and ulnar artery, and is seen by separating the pronator from the flexor carpi radialis. The fibres run outwards, and converge to a flat tendon, which is *inserted* into a rough part in the middle of the outer surface of the radius, below the insertion of the supinator brevis, which surrounds the upper portion of this bone and external to the radial attachment of the flexor sublimis.

Insertion.

Its cutaneous surface is partly superficial, and covered only by the fascia, veins, and nerves; but near the radius it is crossed by the radial vessels and nerve, and is covered by the supinator longus of the posterior set of muscles; it lies on the brachialis anticus, on the ulnar artery, and on the

Relations.

* Pronation consists in rolling the radius over the ulna, so as to turn the palm of the hand backwards, and therefore these muscles must be attached by one extremity to this bone. When the words inner and outer are used with reference to the sides of the forearm, the palm of the hand is supposed to be upwards, and the hand consequently supine.

median nerve which enters the forearm between its two heads, and below this on the flexor sublimis digitorum, and radius. The outer or radial border corresponds to the radial artery, bounds the triangular space of the elbow, and, near the radius, is in relation with the supinator brevis muscle: the inner border is in contact with the flexor carpi radialis.

Flexor Carpi radialis Muscle.

The *flexor carpi radialis muscle,* next in position to the pronator, is fleshy above, but tendinous below; it is situated on the ulnar side of the forearm at its origin, but on the radial near the wrist, and disappears by passing beneath the annular ligament.

Origin.

It *arises* from the tendon common to it and the other muscles, from the fascia covering it, from the intermuscular septa between it and the muscles on each side, and from an aponeurotic layer on its posterior surface. The fibres descend, forming a belly, larger in the middle than at either end, and terminate in a tendon which extends for two thirds of the length of the muscle, is directed downwards and outwards to the radial side of the arm, enters beneath the annular ligament, and, passing through a groove in the trapezium, is finally *inserted* into the base of the metacarpal bone of the index finger: but this deep part will be dissected with the hand. The muscle is subcutaneous except at its insertion; and it rests on the ulnar artery and median nerve, before they enter between the heads of the flexor sublimis, then on this muscle, and, in the lower third of the forearm, on one of the deep layers of muscles — the flexor pollicis longus. The radial border is in contact, in its upper half, with the pronator teres, but below that it is parallel to the radial artery, and close to it, its tendon being taken as the guide to the vessel in the lower half of the forearm: the ulnar border touches at first the palmaris longus; but as these diverge to their insertions, it has, below, no muscle in relation with it, but about two inches above the wrist the median nerve lies along it.

Insertion.

Relations.

Palmaris longus Muscle.

The *palmaris longus,* internal to the last, is often absent; its fibres *arise* from the common tendon, and from aponeurotic septa on each side and behind it, and descend, giving rise to a flat thin muscle that soon ends in a long tendon, which is continued down the centre of the forearm, and over the annular ligament to the palmar fascia, into which it is inserted.* The muscle lies beneath the fascia, and on the flexor digitorum sublimis; the outer border touches the flexor carpi radialis, and the inner the flexor carpi ulnaris muscle.

Flexor Carpi ulnaris Muscle.

The *flexor carpi ulnaris,* the most internal of the muscles of the superficial layer, is bifid above, and continues fleshy along its inner border near to its inferior attachment: the tendon on the anterior surface is the guide to the ulnar artery in the lower half of the forearm. The muscle *arises* by the common tendon from the inner condyle of the humerus, from the inner side of the

Origin.

* In some subjects this muscle is fleshy down to the wrist.

olecranon, also from a tendinous arch between these points, beneath which passes the ulnar nerve and recurrent artery, and from the aponeurosis of the forearm, which is thickened and attached to the crest of the ulna, that separates the anterior and internal from the posterior surface of the bone. The upper fibres descend vertically; but the others, which extend to near the wrist, become less oblique as they approach this part, and are directed forwards to the tendon which occupies the anterior and inner surface of the muscle for about its lower half, and is *inserted* into the cutaneous surface of the pisiform bone of the carpus; some fibres are continued downwards from the insertion to the muscles of the little finger, which arise below, and some turn inwards over the ulnar artery and nerve, to join the anterior annular ligament. The cutaneous surface is close beneath the fascia, and the prominence of the tendon, the guide to the ulnar artery, is readily felt during life. The inner border is united to the fascia of origin, and beneath it pass the branches of the ulnar nerve and artery to the back of the hand: the outer is in contact, above, with the palmaris and flexor digitorum sublimis, but in the lower third, these muscles are separated by an interval in which appears the ulnar artery and nerve, which keep this relation to its insertion. To see the parts that the muscle covers, cut through the attachment to the inner condyle and turn it inwards: it lies on the flexor digitorum sublimis, and ulnar artery, which comes from beneath it, and more to the ulnar side of the arm, on the flexor digitorum profundus, and ulnar nerve; and these relations it keeps down to the wrist, except that the artery escapes rather from beneath it. The posterior ulnar recurrent artery ascends between its two heads to anastomose, as before seen, with the inferior profunda and anastomotic arteries of the brachial.

Insertion.

Relations.

The *radial artery* commences at the bifurcation of the brachial in the hollow at the bend of the elbow, extends along the outer side of the forearm to the end of the radius, turns from the front to the back below the extremity of this bone, and passes through the muscle in the first interosseous space, to terminate by branches in the palm of the hand. The part of the artery on the back of the wrist cannot be seen now; but the portion in the arm extends from opposite the coronoid process of the ulna to the styloid process of the radius; it is smaller than the ulnar, and more superficial than it, though in direction it appears the continuation of the brachial, and it lies, above, to the ulnar side of the radius, but, below, in front of it. A line from the centre of the hollow of the elbow to the styloid process of the radius indicates its course, and, to examine its relations, it may be divided into an upper and a lower portion. In the *upper half* of the forearm, the artery lies between the fleshy belly of the supinator longus on the outer side, and that of the pronator

Radial Artery.

Upper portion.

teres on the inner, and is covered only by the skin, superficial and deep fasciæ, except in muscular subjects, in which it is partly concealed by the supinator, which projects over it; it lies on the tendon of the biceps, on the supinator brevis, separated however by a considerable quantity of cellular structure and branches of the musculo-spiral nerve; and below this, on the pronator teres, near its insertion: two veins accompany this part of the artery, giving cross branches over it. The radial nerve is separated from its upper part by a considerable interval, and is underneath the supinator longus, but about one inch and a half above the insertion of the pronator teres it comes into contact with the vessel, though still placed to the outer or radial side. The *lower half* is more superficial than the upper, as it lies in front of the radius, and can be felt pulsating during life; it is covered only by the skin, superficial and deep fasciæ, and by branches of the external cutaneous nerve, some of whose filaments perforate the fascia, surround the artery, and accompany it to the dorsum of the hand; and behind the vessel are the thin radial origin of the flexor sublimis, the flexor pollicis longus of the deep layer, the pronator quadratus, from which it is separated by cellular membrane, and lastly, the extremity of the radius. To the outer side is the tendon of the supinator longus, and to the inner the tendon of the flexor carpi radialis. The venæ comites have the same relation to this part as to the upper, and the deep and superficial veins in general communicate. The radial nerve lies in contact with it above, but it soon leaves it to pass beneath the tendon of the supinator longus to become cutaneous; so that the nerve is in contact with the artery only in the middle third of the whole of its course in the forearm.

Lower.

Branches. The portion of the radial artery in the forearm gives off muscular unnamed branches; and three named ones, the recurrent, superficialis volæ, and anterior carpal artery.

Radial Recurrent. The *recurrent radial artery*, oftentimes a large branch, leaves the trunk, close below its commencement, and very frequently it comes from the brachial artery. It passes downwards and outwards in front of the supinator brevis muscle, then turns upwards beneath the supinator longus and in front of the brachialis anticus, to anastomose with branches of the superior profunda artery; this artery lies amongst the branches of the musculo-spiral nerve, and from its convexity many branches are given to the muscles of the outer and posterior part of the arm, and they anastomose in these muscles with the posterior interosseous artery: many branches supply the supinator and brachialis muscles.

Superficialis Volæ. The *superficial artery* of the palm (superficialis volæ) varies much in size as well as in its place of origin; it usually arises from the radial as this is about to turn to the back of the hand, but it may arise at different heights; it is directed downwards over the mass of muscle connected with the thumb, and joins in

the palm of the hand with the ulnar, to complete the superficial arch of arteries. This branch may pass through some of the muscular fibres, or end in the muscles.

The *anterior carpal branch* leaves the radial opposite the lower border of the pronator quadratus, directs itself inwards below this muscle, and on the anterior surface of the radius, to anastomose with a corresponding branch from the ulnar, so as to form an arch which supplies the carpal bones: this will be seen after the dissection of the deep layer. Anterior Carpal.

Detach the flexor carpi radialis and palmaris longus from the common origin from the inner condyle, and throw them to one side. In doing this, the branches that they receive from the ulnar artery and median nerve must be cut across, but they are to be remembered. Leave for the present the pronator teres. Dissection.

The *flexor digitorum sublimis* or *perforatus* is a broad thick muscle, fleshy above, but divided below into four tendons which are continued beneath the annular ligament to the fingers. It *arises* in common with the other muscles of this layer from the inner condyle of the humerus; from the internal lateral ligament, and from the aponeurotic septa between it and the other muscles; from the inner part of the anterior surface of the coronoid process by aponeurotic fibres; and by a thin muscular portion which commences at the tubercle of the radius, is attached to the oblique line on its front to about two inches below the insertion of the pronator teres, and lies internal to the supinator brevis and pronator teres, but external to the attachment of the flexor pollicis beneath it. From these numerous origins the fibres descend, those from the upper vertically, and those from the radius obliquely inwards, to end in a fleshy belly that terminates about the lower third of the forearm in four tendons, which, placed at first side by side, are arranged, close above the wrist, into two layers connected by cellular membrane, those for the middle and ring finger being anterior, and those for the index and little finger posterior to the others; and this relation is maintained as they pass beneath the annular ligament of the wrist to reach the fingers. Of the two anterior tendons, the external, or that for the middle finger is the largest, receives the fibres which descend from the radial origin, and is accompanied by muscular fibres to near the wrist; and of the posterior two, the one for the index, is larger than that for the little finger. This muscle is covered by the other muscles of the superficial layer, and on the radial origin lie the radial vessels and nerve. The outer border is attached to the radius, and below this, where it is free, is seen the median nerve: the inner or ulnar is in contact with the flexor ulnaris, and ulnar vessels and nerve. To see the parts that this muscle lies on, detach with care the coronoid and condyloid attachments, without cutting, at the same time, the origin of the flexor pollicis, the recurrent branches of the ulnar

Superficial Flexor of the Fingers. Origin.

Relations.

artery, or the median nerve, and turn the muscle over to the radius. It lies on the flexor digitorum profundus and flexor pollicis muscles of the deep layer, also on the median nerve which passes with the ulnar artery between its coronoid and radial origins, and then lies close against its under surface to near the wrist; it covers also, in the upper part, a portion of the ulnar artery.

Ulnar Artery. The *ulnar artery*, the larger trunk resulting from the bifurcation of the brachial in front of the coronoid process, lies along the inner side of the forearm, in front of the ulna, as far as its lower extremity, and it then passes over the annular ligament, enters the palm of the hand, and terminates by forming the superficial arch of arteries to supply the fingers. Its relations in the upper and the lower half of the forearm are the following:—

Upper portion. In the *upper half*, the course of the artery is obliquely downwards and inwards from the coronoid process to reach the middle of the forearm; it forms an arch, the convexity of which is upwards and inwards, and it then becomes vertical to descend to the wrist. In this extent it lies deeply, above, between the superficial and the deep layer of muscles, but it becomes comparatively superficial about its termination. In front of it are the pronator teres and flexor sublimis muscles, and above these the flexor carpi radialis and palmaris longus, and at the middle of the forearm it comes into contact with the flexor carpi ulnaris, which overlaps and conceals it; it lies at first on the brachialis anticus, then crossing below the coronoid process, it is placed altogether on the flexor profundus. The veins accompanying the artery are the two venæ comites which surround it. The median nerve lies to its inner or ulnar side, on the brachialis anticus, for about one inch; but the nerve then crosses in front of the artery to the outer side, so as to lose this relation to it, and as it crosses it is separated from it by the attachment of the pronator teres to the coronoid process; the ulnar nerve is not in contact with this portion of the vessel, which it approaches, only, at its lower part, and whilst it is under cover of the flexor

Lower. carpi ulnaris. To see the artery *in the lower half* of the forearm, replace the flexor digitorum sublimis and flexor carpi ulnaris muscles. This portion extends from the termination of the upper half, at which part the artery appears on the inner side of the flexor sublimis, to the lower border of the annular ligament of the wrist; it is vertical in direction, and much more superficial than the upper. It is covered by the skin, superficial and deep fasciæ, by an aponeurosis extended from the aponeurosis of origin of the flexor carpi ulnaris to the flexor profundus, and it is slightly overlapped above, by the flexor carpi ulnaris: a branch of the ulnar nerve descends on it in the lower part; it lies on the flexor profundus and the annular ligament. To the outer side are the tendons of the flexor sublimis; and to the inner, the tendon of the flexor carpi

ulnaris, which rather conceals the upper part of the artery, and is the guide to it in the living subject; also the pisiform bone at its lower termination. On the annular ligament the artery turns slightly outwards, lies close to the pisiform bone, and is covered by some fibres from the tendon of the flexor carpi ulnaris to the ligament. Venæ comites accompany and surround it. The ulnar nerve, lying to the ulnar side, comes into contact with the artery in the middle of the forearm, and continues the same relation to this vessel through the lower half. On the ligament the nerve still accompanies it, but is placed internal, and rather posterior to it.

Branches. The branches of the ulnar in the forearm are muscular, which are unnamed; and the named are anterior and posterior recurrent, interosseous, which divides into anterior and posterior, the metacarpal, and anterior and posterior carpal. The flexor sublimis and flexor carpi ulnaris muscles must be again removed from their position to see their distribution.

Anterior Recurrent. The *anterior ulnar recurrent artery*, the first branch of the ulnar, when it is separate, but more commonly it is small, and arises in common with the posterior recurrent; its course is upwards in front of the brachialis anticus and elbow-joint, and beneath the pronator teres, to inosculate with the anastomotic artery in front of the articulation. The artery gives branches to the muscles which cover it.

Posterior Recurrent. The *posterior ulnar recurrent artery*, a much larger branch than the anterior, is directed inwards beneath the flexor sublimis muscle to the interval between the coronoid process and olecranon, passes beneath the flexor carpi ulnaris and between its origins, with the ulnar nerve, to anastomose with the inferior profunda and anastomotic arteries: it gives branches to the superficial layer of muscles, to the articulation, and ulnar nerve.

Interosseous. The *interosseous artery* is the next branch given off beneath the flexor sublimis muscle; it is a short thick trunk, about one inch long, which descends to the interval between the muscles of the deep layer, and divides into its anterior and posterior branches: these will be examined with the next layer.

Branch to the Median Nerve. Amongst the muscular branches that the artery gives off, is one long and constant *branch* *, which accompanies the *median nerve*, united closely to it, and in the lower part of the forearm is distributed to it and the flexor sublimis: oftentimes, this branch comes from the interosseous artery.

Metacarpal. The *metacarpal branch* leaves the artery above the lower extremity of the ulna, turns backwards with a branch of the nerve

* This artery is sometimes as large as either the ulnar or radial, and in certain varieties of these arteries passes beneath the annular ligament to the palm of the hand, to join the palmar arch of arteries.

beneath the tendon of the flexor ulnaris, descends along the ulnar border of the metacarpal bone of the little finger, and forms its dorsal branch.

Anterior Carpal. The *anterior carpal artery*, a very small branch, arises from the trunk at the lower border of the pronator quadratus muscle, passes beneath the flexor profundus, and unites on the radius with the anterior carpal from the radial artery: its branches are supplied to the bones and articulations of the carpus.

Posterior Carpal. The *posterior carpal artery* is very small, and arises below the styloid process either from the ulnar, or from the metacarpal branch as it runs over the side of the articulation; it passes transversely beneath the extensors to supply the carpus.

Ulnar Nerve. The *ulnar nerve* enters the forearm in the interval between the olecranon and inner condyle, by passing between the heads of the flexor carpi ulnaris; it then descends under cover of this muscle, and lying on the flexor profundus, to the annular ligament of the wrist, over which it passes with the ulnar artery into the palm of the hand. In the upper third of its extent, it lies much to the ulnar side of the artery, being deeply placed beneath the flexor ulnaris; but in the middle third it is close to the vessel lying on its inner side, and continues so till it enters the palm of the hand to divide into branches: on the annular ligament the nerve is rather posterior to it. Its relations to muscles are the same as those of the artery; for, like it, the nerve is superficial below, but deep above.

Branches. To the Elbow Joint. When the nerve lies in the interval between the olecranon and inner condyle and under cover of the flexor carpi ulnaris, it gives some small branches to the articulation in contact with it.

To Flexor Ulnaris and Profundus. In the forearm it supplies branches to the flexor carpi ulnaris, and, below, one to the flexor profundus on which it lies; the nerve to the last muscle is distributed to the two inner of its four divisions. About the middle of its extent, the nerve gives off a small branch, which descends beneath the fascia, and soon divides into a cutaneous and a deep filament: the

Cutaneous Nerve. *cutaneous* perforates the fascia at different heights, and varies much in size; it terminates by communicating with the internal cutaneous, unless it is large, when it supplies, in addition, the integuments; the deep descends on the front of the ulnar artery,

Dorsal branch of the Hand. and divides into small filaments which accompany it. The *cutaneous dorsal branch of the hand*, the distribution of which has been dissected, is the last branch of this nerve in the forearm; it arises two inches or more above the extremity of the ulna, lies on the flexor profundus on the inner side of the nerve, gradually inclining inwards so as to pass between the flexor ulnaris and ulna, a little above the styloid process of this bone; it then perforates the fascia, and supplies the integuments of the back of the hand as well as that of the two inner fingers.

Median Nerve. The *median nerve*, before seen to lie in the hollow of the bend

of the elbow, internal to the brachial and ulnar arteries, enters the forearm by passing between the two heads or origins of the pronator teres, and between the coronoid and radial attachments of the flexor sublimis; it now descends beneath the flexor sublimis, to which it is closely united, and on the flexor profundus, to about two inches of the annular ligament of the wrist, at which part it becomes superficial, lying between the tendons of the flexor sublimis and flexor carpi radialis; it then passes beneath the annular ligament, enters the palm of the hand, and divides into branches. In the hollow of the bend of the elbow it lies on the brachialis anticus, and is parallel to the ulnar artery for about one inch; but as the direction of the vessel is inward, and that of the nerve outward, they soon cross each other, being separated at this spot by the attachment of the pronator teres to the coronoid process, and then lose all relation to one another. In the forearm, the median is accompanied by the branch from the ulnar artery.

Branches.

This nerve is the chief source of the branches to the muscles of the forearm, and these, which are for the most part muscular, arise near the elbow, are distributed to the deep and superficial layers, and supply all the muscles which are placed on the front, except the flexor carpi ulnaris and part of the flexor profundus. Above the elbow, the median gives off a small branch, which descends on the brachialis anticus, supplies the teres, and sends filaments backwards around the ulnar artery to enter the articulation; whilst beneath the pronator teres, a muscular branch arises for the superficial layer, and is distributed to the pronator, palmaris, flexor carpi radialis, and flexor sublimis muscles: some of these have been divided in the dissection. Under cover of the flexor sublimis, it gives branches to the flexor pollicis, and to the outer half of the flexor profundus, the inner half of this muscle being supplied by the ulnar nerve; and one large nerve, the *anterior interosseous*, which runs with the interosseous artery, and will be dissected with it. When the median is superficial in the lower part of the arm, and to the outer side of the flexor sublimis, it gives a long *cutaneous branch* to the palm of the hand: this descends beneath the fascia, lying on the median nerve, and near the wrist divides into two branches which perforate the fascia; one, descending over the ligament, enters the palm of the hand in which it terminates, reaching to about its middle; the other is directed outwards to the integuments over the ball of the thumb.

To the Teres and Articulation.

To the Superficial Layer of Muscles.

To the Deep Layer.

Anterior Interosseous Branch.

Cutaneous of the Palm.

Radial Nerve.

The *radial nerve*, a branch of the musculo-spiral in front of the outer condyle of the humerus, runs to the outer side of the forearm, over the supinator brevis but beneath the supinator longus, to reach the radial artery about the middle of its extent; it then continues forwards, lying to its outer side, and under cover of the supinator longus to the lower third of the forearm,

passes backwards beneath the tendon of this muscle, perforates the fascia, and divides above the styloid process of the radius into two branches which supply the back of the hand, as well as of the thumb and two first fingers. This nerve is in contact with the radial artery only in the middle third of the forearm, gives no muscular branches in its course, and terminates in a cutaneous distribution to the back of the hand and fingers.

Muscles of the Deep Layer.

The muscles of the deep layer are only three in number: a deep flexor of the fingers, or flexor profundus, lying on the ulna; the long flexor of the thumb, or flexor pollicis, on the radius; and at the lower part of the bones, and beneath the other two muscles, is the pronator quadratus, or deep pronator. Between the flexor profundus and flexor pollicis are the interosseous vessels and nerve, and to examine them the pronator teres, flexor sublimis, and median nerve must be well drawn over to the radial side of the forearm, and, if in the way, they may be divided; and the cellular membrane must be removed from the surface of the muscles.

Flexor Profundus Muscle. Origin.

The *flexor digitorum profundus* or *perforans* is the largest and strongest of the muscles of the forearm, and occupies nearly all the anterior surface of the ulna. It *arises* from the upper three fourths of the anterior surface of the ulna, and by two fleshy digitations, one on each side of the coronoid process, which embrace the insertion of the brachialis anticus; from the same extent of the internal surface of the bone, extending upwards to the olecranon, and backwards to the line which separates this surface from the posterior; from the aponeurosis which, attached to the inner part of the ulna, gives origin to the flexor ulnaris, and from the inner half of the interosseous ligament. The fibres are for the most part vertical, but those that arise from the inner surface of the bone are directed outwards and obliquely downwards, and form a fleshy belly which ends in four tendinous processes, whose destination, after passing beneath the annular ligament and through the palm of the hand, is to the last phalanges of the fingers. In the arm, it is only the outer tendon, or that for the index finger, that is separate from the rest; for the others are so united by cross processes as to appear but one mass of tendinous structure, and the three tendons composing it become free and distinct only below the annular ligament.

Insertion.

Relations.

The cutaneous surface is covered by the muscles of the superficial layer arising from the inner condyle, by the median nerve, by the ulnar artery, nerve, and flexor carpi ulnaris; and the muscle lies on the ulna, interosseous ligament, and two inches above the extremity of the ulna, on the pronator quadratus, and anterior carpal arteries. The outer border is in close contact with the flexor pollicis, the anterior interosseous artery and nerve only intervening, and frequently, the artery runs in the fibres of the flexor profundus; the inner border is connected to

the ridge of the ulna, separating the inner from the posterior surface, and it corresponds, by this attachment, to the extensor ulnaris and anconeous muscles.

The *flexor pollicis longus muscle*, situated in front of the radius, *arises* from the anterior surface of this bone as low as the pronator quadratus, extending outwards to the oblique line for the flexor sublimis, and upwards to its tubercle; it also arises from the outer part of the interosseous ligament, and by a small muscular and tendinous slip from the coronoid process of the ulna: the fibres descend, some vertically and some obliquely, to a tendon on the cutaneous surface, which they join as low as to the pronator quadratus; the tendon then becomes free and round, passes over the pronator, but beneath the annular ligament, and crosses the palm of the hand to reach the last phalanx of the thumb, into which it is *inserted*. It is covered by the flexor sublimis, and below this muscle by the radial artery, and tendon of the flexor carpi radialis; and it rests on the radius, part of the interosseous membrane, and pronator quadratus muscle. The inner border is in contact with the flexor profundus, and interrosseous vessels and nerve; and the outer is fixed to the oblique line on the front of the radius, extending downwards and outwards from the tubercle, and is separated from the attachment of the supinator brevis and pronator teres, by the radial origin of the flexor sublimis.

Flexor Pollicis Muscle. Origin. Insertion. Relations.

The *pronator quadratus muscle*, seen by separating the flexor profundus and flexor pollicis muscles, is of a square figure, is placed in front of the lower ends of the radius and ulna, and is the last and deepest of the anterior muscles. The ulnar attachment, wider than the radial, is fixed to the inferior fourth of the anterior surface of the bone, and to the border separating the anterior from the inner surface; some of the fibres are connected also to an aponeurosis on the inner part of the muscle; the fibres pass almost transversely outwards to be *inserted* into the lower fourth of the anterior surface of the radius. The anterior surface is covered by the tendons of the flexor profundus digitorum, flexor pollicis, and flexor carpi radialis muscles, and by the radial artery; and the muscle is placed on the lower ends of the radius and ulna, on the interosseous membrane, and interosseous vessels and nerve.

Pronator Quadratus. Origin. Insertion. Relations.

The *interosseous artery* is a branch from the ulnar: it arises opposite the tubercle of the radius, and beneath the flexor sublimis, passes backwards to reach the interosseous membrane, and divides into an anterior and a posterior interosseous artery. The *posterior* is directed above its upper border to the back of the arm, and will be dissected with this. The *anterior interosseous* continues to descend on the anterior part of the membrane, between the flexor profundus and flexor pollicis muscles, but nearer the radius than the ulna, to the pronator quadratus,

Interosseous Artery. Anterior.

beneath the upper border of which it gives off a posterior branch that passes below the interosseous membrane to the back of the carpus, to anastomose with the posterior carpal arteries; whilst the continuation of the artery, seen when the pronator is divided, runs downwards beneath the muscle, which is supplied by it, to the front of the carpus, and joins the arch formed in front of the lower extremities of the radius and ulna by the anterior carpal branches of the radial and ulnar arteries: from the small arch resulting from the anastomosis of these vessels, numerous small branches descend to supply the articulations and the carpus.

Anterior Interosseous Nerve.

The *anterior interosseous nerve* is a considerable branch given off from the median in the upper part of the forearm: it passes with the interosseous artery, between the flexor profundus and flexor pollicis, lying on the radial side of the vessel, and, beneath the pronator quadratus, divides into many filaments which are distributed to the upper and lower parts of the under surface of the muscle.

DISSECTION OF THE PALM OF THE HAND.*

Dissection.

Make an incision along the centre of the palm of the hand, from the wrist to the clefts of the fingers, and at this part another transverse one: raise the skin from the palm, dissecting the cutaneous nerve of the median, which extends to near the centre of the hand; on the inner side, and crossing the upper part of the hypothenar eminence, is the palmaris brevis muscle inserted into the skin, and below this much cellular membrane, which occupies, moreover, the intervals between the fibres of the muscle. In the centre of the hand the fat is absent, and the skin is closely united to the palmar fascia beneath, and in cleaning the fascia, which is strong and shining, resembling that of the foot, be careful of the nerve and artery to the inner side of the little finger, and to the outer side of the index, since these are uncovered by it near the fingers. Remove the skin from the thumb and fingers, dissecting the digital nerves and arteries along their sides, and take away the cellular membrane from the sheath of the tendons situated in the centre, but do not remove a thin band of fascia which lies in the thin folds of skin, or in the webs between them.

Cutaneous of the Median to the Palm.

The *cutaneous palmar branch of the median* enters the hand by passing over the annular ligament, one division of it being distributed to the centre of the palm and reaching to about its

* The posterior part of the forearm may be completed before the hand, if the dissector should desire it.

middle, the other being supplied to the integuments of the thenar eminence.

The *palmaris brevis* muscle, not always present, consists of bundles of fibres separated by cellular intervals, and is about one inch in extent from above downwards. It is attached, externally, to the annular ligament and palmar aponeurosis, and the fibres pass transversely inwards to join the cutis on the inner border of the hand. The cutaneous surface is covered by the skin and cellular membrane; and it is situated over the muscles composing the hypothenar eminence, and over the ulnar artery and nerve. This muscle may now be detached and thrown inwards. Palmaris Brevis Muscle.

The *palmar fascia* consists of a strong central portion, and of two lateral, which cover over the mass of muscles belonging to the thumb and little finger, and become so thin as not to require a separate description. The central portion occupying the middle of the hand is pointed at the wrist and expanded near the fingers, so as to cover nearly the whole of the palm: the fibres that compose it are strong, white, and shining, but they become weaker in front; between them are small apertures, which allow cutaneous vessels and nerves to pass through to enter the integuments; and they are continuous on each side with the thin aponeurosis covering the thenar and hypothenar eminences. It is attached, behind, to the annular ligament of the wrist, where it is joined by the tendon of the palmaris longus, and near the heads of the metacarpal bones it divides into four processes, which, directed to the fingers, give off some superficial fibres to join the transverse ligamentous structure and the integument at the clefts of the fingers, as in the sole of the foot; and some which lie deeper than these, and are continuous with the sheaths of the tendons: at the point of divergence of these processes from one another are placed transverse fibres, forming arches, beneath which pass the digital branches of arteries and nerves, and the lumbricales muscles. To see each process joining the sheath of the tendons, remove its superficial fibres, cut through it over the head of the metacarpal bone, insert the knife beneath, and divide it longitudinally; it will be perceived to send down, on each side of the tendon, a lateral portion to join the transverse ligament of the heads of the metacarpal bones, and to be inserted for a short distance into the borders of the bone: these lateral portions of attachment assist to form the upper part of the sheath for the flexor tendons, also the lateral boundaries of the space between the metacarpal bones, which contains the nerve, artery, and the lumbricalis muscle, the limit to it, below, being the transverse ligament of the metacarpal bones. The fascia is immediately beneath the skin, separated only by cellular membrane and cutaneous vessels and nerves, and it covers the palmar arch of vessels, with the nerves and tendons of the hand. The *transverse ligament of the fingers* is similar to that Palmar Fascia.

Transverse Ligament of the Fingers.

of the toes, and consists of transverse fibres between the first phalanges of the four fingers; and beneath it pass the digital nerves and arteries. Its position is in the thin portion of skin between the fingers, and it serves to prevent the separation of the phalanges.

Sheaths of the Tendons.

Along the fingers, the tendons of the deep and superficial flexors are contained in a sheath, which, partly osseous and partly membranous, binds them to the phalanges, and extends from the head of the metacarpal bone to the distal extremity of the second phalanx; and if one of them be divided along a finger, its posterior boundary, receiving the tendons, is seen to be the two first phalanges, which are hollowed out in the centre but raised at the margins, to which the membranous or anterior part of the sheath is connected. Its upper part is formed by the process of the plantar fascia, which comes to the finger, and by the metacarpal bone, and it ends below on the last or ungual phalanx. The portion which is opposite the centre of the two phalanges is much thicker than that over the articulation between them, owing to the existence of two firm cartilaginous processes which are attached to the margins of these bones, and the process connected to the first or metacarpal phalanx is stronger and larger than the other: it is by means of this sheath that the metacarpal phalanx is flexed, since no tendon is inserted into it. Each sheath is lined by a synovial membrane which lubricates the tendons, extending upwards on them into the palm of the hand; and on its sides are the digital vessels and nerves.

Dissection.

Take away the palmar fascia, and the thinner portions of the sheath of the tendons along the fingers. The palmar arch of arteries, and the median and ulnar nerves lie beneath the fascia.

Superficial Palmar Arch.

The artery that forms the *superficial palmar arch* is the continuation of the ulnar, which, after passing the annular ligament, directs itself obliquely across the palm of the hand, from the ulnar side to the middle of the muscles of the thumb, to join the superficialis volæ, a branch of the radial, thus completing the superficial arch of the hand; it receives also near this part a small communicating artery from the arteria radialis indicis, a branch of the radial, which is given off opposite the head of the metacarpal bone of the index finger, and is superficial to the tendons. The arch, formed in this manner, has its convexity towards the fingers, and concavity to the annular ligament, and crosses the hollow of the palm, between the eminence of the muscles of the thumb and those of the little finger, about three quarters of an inch below the lower border of the annular ligament, or a line across the palm, when the thumb is placed at right angles to the hand, would be nearly over its direction: the median and ulnar nerves accompany it, and divide in the palm.

It is very superficial, being covered only by the skin, superficial and palmar fascia, and, near the ulnar border of the hand, by the palmaris brevis muscle; it lies on the muscles of the little finger, on the median and ulnar nerves, and the tendons of the flexor muscles continued from the arm. From the convexity of the arch the digital branches spring to supply the fingers, and from the concavity some small arteries pass upwards to the palm of the hand: the small profunda artery is given off as the ulnar enters the hand.

Digital Arteries.

The *digital arteries* from the convexity of the arch are four in number, and supply the three inner fingers, and the ulnar side of the index, the thumb and half the index being supplied by the radial artery; one passes to the inner side of the hand and to the little finger, the ulnar side of which it supplies; a second to the cleft between the little and ring fingers, and divides into two branches for the supply of their contiguous sides; a third to the interval between the ring and middle fingers, and divides in like manner; and a fourth to that of the index and middle fingers, and supplies the sides of these two. These branches in the hand cross over the tendons, and then continue in the intervals between them to the clefts, where they are joined by a deep communicating branch from the deep arch, with the exception of the one for the ulnar side of the little finger, and this receives its branch about the middle of the hand, between the muscles of the little finger and the long tendons. They are accompanied by the digital branches of nerves which are divided, like them, at the cleft between the fingers; sometimes the nerves are perforated near the heads of the metacarpal bones by the corresponding digital arteries. From the point of division, an artery extends along each side of the finger, accompanied by a branch of the nerve, which is superficial to it, as far as to the last or ungual phalanx, on which those of opposite sides converge to each other, and unite to form an arch, from the convexity of which numerous branches proceed to supply the papillæ of the extremity of the finger, as well as the surface beneath the nail: on the last phalanx the nerve may be perforated a second time by the artery. Small branches are given off from the digital arteries to supply the sheath of the tendons, and a transverse branch near the front of both the metacarpal, and the next phalanx; these run close to the bone and join with similar ones from the opposite side to form an arch, from which small arteries pass forwards to supply the phalangeal articulation in front of it.

Communicating Artery.

The *communicating* or *profunda artery* is a small branch of the ulnar, on the annular ligament; it runs downwards and backwards, with a branch of the ulnar nerve, between the abductor minimi digiti and flexor brevis, or, when this last is absent, between the abductor and adductor muscles, to join, deep in the

hand, with the branch of the radial, which forms the deep palmar arch of arteries.

Ulnar Nerve. The *ulnar nerve* divides on the annular ligament, and to the outer side of the pisiform bone, into a superficial and a deep palmar branch. The *deep* passes with the profunda artery into the palm, to accompany the deep arch of arteries, and will be seen with it; but the *superficial palmar branch*, which continues with the artery over the annular ligament, enters the centre of the hand, and supplies with digital nerves only the little, and the ulnar side of the ring finger, instead of three and a half as the ulnar artery; and the thumb and remaining two fingers and a half receive their nerves from the division of the median in the palm of the hand.

Deep branch.

Superficial palmar.

Digital Nerves. The *digital nerves* of the superficial branch of the ulnar are two: one for the ulnar border of the little finger runs downwards and inwards over its muscles, lying to the inner side of its digital artery, gives filaments to the integuments on the inner side of the hand, is joined by the dorsal cutaneous branch of the ulnar, and then continues along the ulnar border of the finger to its extremity. The other digital nerve, larger than the preceding, runs forward on the inner side of the superficial arch of the ulnar artery, crosses over the tendons of the little finger, to reach the interval between those of the ring and little fingers, and, lying in front of the fourth lumbricalis muscle, divides at the cleft between them into two branches which supply their opposed sides. Rather above the centre of the palm, this nerve sends an oblique branch to join with the digital nerve of the median, which supplies the ring and middle fingers. The anatomy of the branches along the sides of the fingers, is the same as that described in those from the median.

Median Nerve. The *median nerve*, larger than the ulnar, supplies digital branches to the thumb and two fingers and a half, as well as some nerves to the muscles of the thumb and hand. It enters the palm beneath the annular ligament, and at the lower border of this structure is superficial to the tendons of the flexor sublimis; it now becomes flattened and enlarged, and divides into an external and an internal branch of nearly equal size: from the outer are given off a branch to the muscles of the thumb, two digital nerves for its supply, and one for the radial side of the index finger; and from the internal, two large digital branches, which, by dividing at the front of the interosseous spaces, supply the opposed sides of the ring and middle, and of the middle and index fingers. In the hand, the nerve is covered by the superficial arch and palmar fascia, and it lies on the flexor tendons.

Digital Nerves in the Hand. The *digital nerves* of the median, five in number, have the following relations and distribution: the two for the thumb pass outwards, the external lying on the long flexor tendon at the

head of the metacarpal bone, continue forwards, one on each side of it, to the extremity, and are distributed as the other digital branches; the nerve supplying the ulnar side crosses over the adductor pollicis muscle, and gives a branch to it; and that for the opposite, sends backwards some cutaneous filaments, to join with the dorsal cutaneous branches of the radial. The third digital branch, or that for the radial side of the index finger, crosses the tendons to it, as well as the first lumbricalis muscle, to which it gives a filament, and is then distributed as the others. The fourth passes behind the superficial arch, lies in the interval between the tendons of the index and middle fingers on the second lumbricalis muscle, which it sometimes supplies, and divides at the cleft between them into two branches which are distributed to their opposed sides; and the fifth crosses the tendons of the middle finger, is situated over the third interosseous space, and, like the last, supplies the sides of the middle and ring fingers; it is joined by a communicating branch from the ulnar nerve. From the cleft between the fingers to the extremity of the last phalanx, the nerves lie along the sides of the sheaths of the tendons, with the digital branches of the arteries, internal and superficial to which they are placed. About the centre of the metacarpal phalanx, each nerve divides into a dorsal and palmar branch; the *dorsal* turns backwards, unites with the small nerve from the cutaneous branches on the back, to form a nerve which extends to the integuments of the last phalanx; but the *palmar*, the continuation of the nerve, extends to the last phalanx, on the palmar surface of which it gives off a branch for the papillæ of the ball of the finger, and another, which turns beneath the nail to be distributed. The nerve does not join with that on the opposite side of the finger, as the artery, but it sends backwards and forwards filaments to supply the front and sides.

On the Fingers.

Dorsal branch.

Palmar.

The *branch to the muscles of the thumb* turns backward from the outer division of the median nerve, supplies the superficial or outer portion of the short flexor, and then sinks between the abductor and opponens pollicis muscles, to which it distributes branches, and it ends in these.

To the Muscles of the Thumb.

Cut through the palmar arch below the communicating artery, also the superficialis volæ, and throw the arch down to the fingers, with the ulnar nerve which is to be divided at the annular ligament: make an incision through the annular ligament in its centre, without injuring the muscles which arise from it, and turn the halves to each side, to follow the flexor tendons to their termination.

Dissection.

The *tendons of the flexor sublimis*, in passing behind the annular ligament, occupy about its inner half, are superficial to those of the profundus; and, instead of being arranged two and two, as in the forearm, are all four nearly on the same plane, the

Tendons of the Flexor Sublimis.

two inner being slightly bent around the unciform bone: the median nerve lies on the same level when they enter beneath the ligament, but when about to pass from beneath it the nerve inclines in front of them. The four tendons now cross the palm of the hand, diverging from each other towards the fingers; they lie beneath the superficial arch and the nerves, and in front of those of the flexor profundus, separated more or less by the lumbricales muscles, except that for the index finger, which is placed in front of the tendon of the profundus, only at the head of the metacarpal bone; they now enter the sheaths of the fingers, those of the flexor sublimis being superficial, and slightly hollowed behind for the tendons of the profundus. Opposite the middle of the metacarpal phalanx, the tendon of the sublimis presents a slit for that of the profundus, which passes to the last phalanx; and its divisions, after being connected to the bone by fibrous bands, bend backwards, and unite together by cross portions beneath the tendon of the profundus, so as to form a grooved partition between it and the articulation, and this divides, a second time, into two processes which are fixed to the margins of the second phalanx about its centre. The tendons of this muscle are separated behind the annular ligament from those of the profundus, and from the median nerve, by folds of a large synovial membrane: cut through the flexor sublimis and median nerve above the wrist, divide the branches of the nerve to the thumb, and throw these forwards to the fingers.

Tendons of the Flexor Profundus.

The *tendons of the flexor profundus* are three in number behind the annular ligament: the one for the index finger is separate from the others up to its commencement, but it is only at the lower border of the ligament that the internal divides into two; they lie on the same level as the tendon of the flexor pollicis, separated from it by an interval, and are beneath those of the sublimis; the inner tendon is also slightly bent. They then diverge across the palm of the hand to the heads of the metacarpal bones, enter the sheaths of the fingers with the tendons of the sublimis but beneath them, perforate these opposite the centre of the metacarpal phalanges, become superficial over the articulation of these with the next, and proceed to the ungual phalanges, into which they are inserted by a flat expansion. After each tendon has passed through the sublimis, it is marked by a longitudinal groove, and a process passes backwards from it through the united portion of the tendon of the sublimis, to be fixed to the extremity of the first or metacarpal phalanx. In the sheath of the fingers they are surrounded by a synovial membrane, and in the hand the lumbricales muscles are attached to them.

Relations.

The tendons of the flexor sublimis and profundus muscles are covered by the annular ligament, by the palmar fascia and palmar arch, by the median and ulnar nerves, and on the fingers they are enveloped in a fibrous sheath; they

lie on the carpal bones, on the interossei muscles, and adductor muscle of the thumb, and on the fingers, correspond to the phalanges. Behind the ligament they are enveloped by a synovial membrane which is large and loose, projects above and below its borders, lines its posterior surface, and envelopes the tendons and nerve in its folds; at the lower border it is divided into processes which extend on them. A separate synovial membrane exists for the tendon of the flexor pollicis.

Tendon of the Flexor Pollicis.

The *tendon of the flexor pollicis*, in passing beneath the annular ligament, lies close to the carpal bones, external to the tendons of the profundus, and behind the median nerve; it then turns outwards to the thumb, between the two heads of the flexor brevis pollicis, and sesamoid bones, enters a sheath, which is not so distinct as those of the fingers, and is inserted by an expansion into its ungual phalanx. Behind the ligament it is surrounded by a separate synovial membrane, which is continued into its sheath.

Lumbricales Muscles.

The *lumbricales muscles* are four small, slender, fleshy portions, attached by one end to the radial border of the tendons of the flexor profundus, soon after they have passed beneath the annular ligament; and by the other, which is tendinous, to the expansion on the dorsum of the metacarpal phalanges; their size diminishes from the radial, to the ulnar margin of the hand.

First.

The *first*, or most external, the largest, is united to the radial border of the outer tendon of the flexor profundus, and slightly to its front; the fibres end in a tendon which passes on the radial side of the metacarpo-phalangeal articulation to the metacarpal phalanx of the first finger, to join the tendinous expansion on the dorsum.

Second.

The *second* is connected to the radial side of the second tendon, and its tendon of insertion passes on the outer side of the corresponding articulation of the middle finger.

Third.

The *third* is attached to the two tendons between which it lies, and its tendon is sometimes divided into two processes for the sides of the two fingers between which it is placed.

Fourth.

The *fourth* is also connected at its origin to the two last tendons of the profundus, and is inserted into the radial side of the little finger in the same manner as the others.

Relations.

These muscles are covered by the tendons of the flexor sublimis, the two outer lie on the adductor pollicis, and the two inner on the interossei; and in the intervals between the heads of the metacarpal bones they are situated in canals, as before seen, formed by processes of the palmar fascia and the transverse ligament of the metacarpal bones. The two first are supplied by the digital branches of the median nerve, and the two others by the deep branch of the ulnar.

Dissection.

Cut through the flexor profundus above the wrist; raise the lower portion, and throw it down to the fingers with the lumbri-

cales, taking care of the nerves to these muscles. The muscles of the thumb are more distinctly seen after the removal of the tendons, and the interossei and part of the deep palmar arch are now exposed. A careful dissection is required to separate the small muscles of the thumb and little finger.

Muscles of the Thumb. The muscles of the thumb, forming the thenar eminence in the palm, consist of an abductor, adductor, flexor brevis, and opponens pollicis muscle: the separation between these is not very distinct, and in many subjects some of them are inseparably united.

Abductor Pollicis Muscle. Origin. The *abductor pollicis*, the most external and superficial of the muscles of the thumb, is thin, and *arises* from the anterior and outer part of the annular ligament, from the os scaphoides, and sometimes from the tendon of the extensor ossis metacarpi pollicis: the fibres are directed outwards and downwards to the base of the first phalanx of the thumb, into which the muscle is

Insertion. *inserted* by a short flat tendon, and some fibres are continued to the tendon on the dorsum of the phalanx. The cutaneous surface is crossed by the superficialis volæ artery, and is close beneath the skin, very little cellular membrane being found in this part;

Relations. and the muscle lies on the opponens pollicis. The inner border is in relation with the flexor brevis muscle; the outer is near the metacarpal bone, the opponens pollicis projecting beyond it; cut it across to see the next.

Opponens Pollicis Muscle. The *opponens pollicis* is a fleshy short muscle, situated beneath the preceding, and recognised from the others by its attachment to the whole length of the metacarpal bone: its separation from the short flexor is not always very distinct, but it is best begun near the head of the metacarpal bone, a cellular

Origin. interval being usually found in this position. It *arises* from the anterior surface of the annular ligament beneath the abductor, and from the os trapezium, external to the groove for the tendon of the flexor carpi radialis; the fibres diverge outwards and

Insertion. downwards, the upper being the shortest, to be *inserted* along the outer border of the metacarpal bone of the thumb. The ab-

Relations. ductor pollicis lies on this muscle; the outer border is fixed to the metacarpal bone, and the inner is in contact with the flexor brevis. When the muscle is cut through, it will be seen to cover the metacarpal bone, the articulation between it and the trapezium, as well as the trapezium and annular ligament.

Flexor Pollicis Muscle. The *flexor pollicis brevis* muscle is situated deeper in the hand than the others, is the largest of the muscles of the thumb, and bifid at each extremity; its separation from the remaining muscle — the adductor — is very distinct. The outer head or portion

Origin. of the muscle *arises* from the ridge of the os trapezium, from the sheath of the flexor carpi radialis, and from the lower part of the annular ligament, below and beneath the opponens; the inner, the larger, *arises* from the os trapezoides, os magnum, and

head of the third metacarpal bone. From these numerous points of origin, the fibres of the two portions or heads converge to form one muscle, which again separates into two parts, the outer being *inserted,* with the tendon of the abductor, into the outer side of the first phalanx, the inner, with the adductor pollicis, into the inner side of the same bone. A sesamoid bone is placed in each tendon, near its insertion into the phalanx. The muscle is covered by the opponens pollicis and tendon of the long flexor, and is partly subcutaneous; and the inner head by the tendons of the flexor profundus, and two first lumbricales muscles. The outer border touches the opponens, the inner is nearly parallel to the adductor pollicis; and between the lower bifurcation of the muscle into two processes, are the tendon of the flexor longus, and the magna pollicis artery which supplies the thumb, and coming from beneath the inner head is the deep palmar arch of the radial artery. Detach the inner head from its origin, taking care of the arteries and nerves, and the muscle is seen to cover the abductor indicis or first interosseous muscle, the divisions of the radial artery in the palm, the sheath of the flexor carpi radialis, the head of the second metacarpal bone, as well as the bones from which it arises.

Insertion. Relations.

The *adductor pollicis* muscle, the last and most distinct of the muscles of the thenar eminence, is wide internally, but pointed at the thumb. Its *origin* is from the lower two thirds of the anterior surface of the metacarpal bone of the middle finger: the fibres are directed outwards, and converge, forming a roundish muscle, which is *inserted,* along with the internal head of the flexor brevis, into the inner side of the base of the first phalanx of the thumb. The cutaneous surface is covered by the two external tendons of the flexor profundus and by the two corresponding lumbricales, by the branches of the median nerve, and by the communicating artery from the radialis indicis to the superficial arch; it lies on the abductor indicis muscle in the first interosseous space, also on the second space and muscles, as well as on the second and third metacarpal bones. The upper border is nearly parallel to the short flexor; and the lower, near its insertion, is subcutaneous.

Adductor Pollicis. Origin. Insertion. Relations.

The muscles of the little finger, forming the hypothenar eminence, are an abductor, flexor brevis often absent, and an adductor minimi digiti: these are rather more distinct than those of the thumb.

Muscles of the Little Finger.

The *abductor minimi digiti,* the most internal of the muscles of the little finger, is similar in form to the abductor pollicis. It *arises* by tendinous fibres from the pisiform bone, at which point they are continuous with the tendon of the flexor carpi ulnaris: the fibres form a thin fleshy muscle, which is *inserted* by a tendon, which unites with that of the short flexor, into the inner side of the metacarpal phalanx of the little finger, and a portion

Abductor Minimi Digiti. Origin. Insertion.

Relations. extends to its dorsum, to join the expansion of the tendons. The muscle is subcutaneous, but above, it is covered by the palmaris brevis muscle; the radial border is in contact with the flexor brevis when this is present, the deep branch of the ulnar artery and nerve passing between them. The opponens or adductor is beneath the abductor.

Flexor Brevis. Origin. Insertion. Relations. The *flexor brevis minimi digiti* muscle, often absent, appears, by the direction of its fibres, as if only a part of the abductor, to the radial side of which it is placed: it *arises* from the annular ligament and process of the os unciforme, and the fibres form a thin narrow muscle which is *inserted* with the tendon of the abductor into the inner side of the base of the same phalanx. The palmaris brevis covers the muscle; the ulnar border is parallel to the abductor, separated above by the deep branches of the ulnar artery and nerve, and it lies on the adductor: cut this muscle across to see the next which is beneath it.

Adductor or Opponens. Origin. Insertion. Relations. The *adductor* or *opponens minimi digiti muscle* is similar to the opponens of the thumb, in being attached to the whole length of the metacarpal bone. Its *origin* is from the annular ligament, and process of the unciform bone: the fibres descend, the inferior being the longest, to be *inserted* into the inner part of the anterior surface of the metacarpal bone of the little finger. It is covered by the flexor brevis and abductor; it lies on the last interosseous space and metacarpal bone, as on the deep branches of the ulnar artery and nerve, which pass beneath its upper part, and it covers the carpo-metacarpal articulation belonging to the little finger: along the radial border lie the long tendons of the little finger; and its ulnar border, fixed to the metacarpal bone, has a branch of the dorsal cutaneous nerve, and of the metacarpal branch of artery running on it.

Dissection. Clean the deep palmar arch, and ultimate divisions of the radial artery in the palm, which are now seen between the two first metacarpal bones, since the inner head of the flexor brevis pollicis is separated from its attachment; follow the branch of the ulnar nerve, which accompanies the arch: in doing this, it may be necessary to remove the fascia from the interossei muscles, but let the dissector observe that they are covered by a fascia which is connected, in front, to a transverse ligament uniting the phalangeal extremities of the metacarpal bones.

Radial Artery in the Palm. The *radial artery* enters the palm of the hand in the first interosseous space, by passing between the two heads of the abductor indicis muscle, and, covered by the flexor brevis, it divides immediately into a branch for the sides of the thumb, another for the radial side of the index finger, and a third which crosses the hand to assist in forming the deep arch; so that it supplies the thumb, and remaining side of one finger to which the ulnar did not give branches, and forms the deep arch, the superficial being the continuation of the ulnar artery.

The *arteria magna pollicis* runs outwards from its point of origin along the ulnar border of the first metacarpal bone, and beneath the outer head of the flexor pollicis, to reach the interval between the heads of insertion of this muscle; and in this spot, behind the tendon of the long flexor, it divides into two branches which run along the borders of the thumb to the last phalanx, and unite on it, as in the other fingers, to form an arch. The same branches are given off in their course along the sides of the thumb, as from the other digital arteries. Branches. Magna Pollicis.

The *radialis indicis* branch passes forwards along the radial border of the metacarpal bone of the index finger, beneath the inner head of the flexor brevis, and the adductor pollicis muscle, and lying on the abductor indicis; at the lower border of this last muscle it is superficial, continues to the end of the finger with the digital branch of the nerve, and unites on the last phalanx with the digital artery furnished to the other side of the finger by the ulnar artery. The branch connecting it to the superficial arch joins it close to the lower border of the adductor pollicis. Radialis Indicis.

The *arteria palmaris profunda* is the largest branch of division of the radial artery; it is directed across the hand to its ulnar border, beneath the inner head of the flexor brevis, and across the heads of the metacarpal bones, to join with the communicating branch from the ulnar to give rise to the deep palmar arch. The *deep arch* is formed chiefly by the radial, a small branch only of the ulnar uniting with it; whilst the superficial, which is the continuation of the ulnar artery, is joined by one or two small branches from the radial. Its extent is from the first interosseous space to the head of the metacarpal bone of the little finger. In its course across the hand it forms an arch, whose convexity is directed forwards and concavity backwards; it is nearer the heads of the metacarpal bones than the superficial arch, and much deeper in the hand than it, since it lies on the metacarpal bones and interossei muscles, and is covered by the flexor tendons in the centre, and at its extremities by the muscles of the thumb and little finger. It is accompanied by the deep branch of the ulnar nerve, which supplies the deep muscles in the hand. From its convexity branches pass forwards to join those of the superficial arch, and from the concavity and upper part other small arteries are given off to the carpus and hand: the muscles of the thenar and hypothenar eminences receive their branches from the radial and ulnar arteries. Palmaris profunda. Deep Palmar Arch.

The *posterior* or *recurrent branches*, from the concavity of the arch, ascend in front of the carpal bones, supply the articulations, and anastomose with the carpal branches sent to this part from the radial and ulnar arteries. Branches. Recurrent.

The *posterior perforating*, three in number, perforate the pos- Posterior Perforating.

terior part of the interosseous spaces, and anastomose with the interosseous arteries of the dorsum.

Anterior or Interosseous.

The *anterior* or *palmar interosseous arteries* are generally three in number, which lie in the three ulnar interosseous spaces, supply the muscles, and terminate at the anterior part by joining, at the clefts of the fingers, the digital branches of the superficial arch: these are very subject to vary in size and distribution.

Veins.

The arteries of the hand, both from the ulnar and radial, are accompanied by veins which have the same anatomy, and which, from their unimportance, have not been separately noticed. The great varieties, too, in the distribution of the radial and ulnar arteries in the hand will much perplex at first the young dissector.

Deep branch of the Ulnar Nerve.

The *deep branch of the ulnar nerve* passes between the short flexor and the abductor minimi digiti, with the communicating artery to the deep arch; it then turns to the radial side of the hand beneath the adductor minimi digiti, enlarges in size, and is distributed by many branches to the muscles. At its origin, it gives off a branch, which divides into three, to supply the muscles of the little finger; and the large branches which continue its direction, cross the palm, enter beneath the adductor pollicis, supplying it, the flexor brevis pollicis, and the abductor indicis muscle. Besides these the nerve gives a branch or branches to each interosseous space, which supply the dorsal and palmar interosseous muscles, and the two nerves that go to the two palmar interossei of the ulnar side send also filaments to supply the two inner lumbricales muscles.

Transverse Metacarpal Ligament.

The *transverse metacarpal ligament* is a strong band of ligamentous fibres, connecting together the digital extremities of the metacarpal bones of the fingers; and it is closely united to the articulations beneath. The cutaneous surface is hollowed out where the flexor tendons cross it, and to the sides of the depressions are united the processes of the palmar fascia, which arch down on each side of the tendons. The posterior border is connected to a fascia which covers over the interossei muscles; in the intervals between the metacarpal bones the ligament is crossed by the lumbricales muscles, and digital nerves and arteries; and the interossei, in each space, lie beneath it as they pass forwards to their insertion. Remove this ligament in the intervals between the bones, as well as the fascia which covers the interossei.

Interossei Muscles.

The *interossei muscles*, so named from occupying the intervals between the bones, are seven in number, and all are seen in this dissection, though the origins of the dorsal ones will be better perceived on the back of the hand: two muscles occupy each space, with the exception of the first, in which there is only one, and they have been called, from their position, palmar and dorsal. In those spaces in which there are two, one is inserted into

the radial, and the other into the ulnar side of the first phalanx of the fingers between which they are placed: they all end by being inserted into the phalanx, and sending off an expansion to its dorsum to unite with the long extensor tendon.

The *palmar* are three in number, and may be considered adductors to an imaginary line passing through the centre of the middle finger*; thus, when the palm is uppermost, one will be inserted into the ulnar side of the index, one into the radial side of the ring, and the other into the same side of the little finger: by which means the three fingers will be drawn to the middle one. The palmar are smaller than the dorsal, arise by single heads, and lie on the palmar surface of the metacarpal bones of the same fingers into which they are inserted, and consequently project more into the hand than the dorsal interossei. They resemble each other in arising from the anterior and lateral surfaces of the metacarpal bones, in the fibres ending in tendons, which pass by the metacarpo-phalangeal articulations to be inserted into the sides of the phalanx, and sending an expansion to the dorsum. Palmar.

The *dorsal*, four in number, are abductors from the same imaginary line: thus, one is inserted into the radial side of the index, and one into the ulnar side of the ring finger to separate these from the middle one, and two go to the middle finger, one to each side, to move this either to the right or left of the line passing through its centre. The dorsal are larger than the palmar, are situated nearer the back of the hand, and arise from the lateral surface of both metacarpal bones, between which they lie; the fibres end, as the others, in tendons, which are inserted into the sides of the first phalanx of the fingers on which they act, and send an expansion to the dorsum of the same bone. The posterior perforating arteries pass between their attachments. Dorsal.

The interossei are situated between the metacarpal bones; they are covered by a fascia, by the deep arch and branches, and by the transverse metacarpal ligament: the dorsal are also perforated by the posterior perforating arteries. Relations.

The *abductor indicis muscle*, classed as the first dorsal interosseous in function, is usually, from its size and relations, described separately from the other interossei; to see it, divide the other head of the flexor brevis pollicis. It is triangular in shape, is situated in the interval between the two first metacarpal bones, and *arises* from the radial border of the metacarpal bone of the index finger, and from the upper half of the ulnar border of that of the thumb: the fibres pass downwards, converging to a tendon which passes by the radial side of the metacarpo- Abductor Indicis Muscle. Origin.

* This excellent method to facilitate the understanding of these muscles is taken from Cruveilhier, *Anatomie Descriptive*, t. ii. p. 207.

Insertion. phalangeal articulation of the first finger, is *inserted* into the outer side of its first phalanx, and sends an expansion to the dorsum.

Relations. The posterior surface is subcutaneous, and the anterior is covered by the flexor brevis and adductor pollicis, and the lower part, projecting below these, is subcutaneous; the radial artery perforates between the two heads of origin to enter the palm, and the radialis indicis artery descends on it near its attachment to the first finger.

Dissection. Dissect the origins of the muscles of the thenar and hypothenar eminences from the front of the annular ligament, and follow its attachments to each side. The sides may be placed sufficiently in contact to study its anatomy.

Anterior Annular Ligament. The *annular ligament* is a firm, strong, ligamentous band, almost square, which, by being placed in front of the carpal bones, forms an arch over the long tendons and median nerve, as they pass from the arm to the hand. The upper border is continuous with the aponeurosis of the forearm, and the lower is joined by the palmar fascia. It is attached externally to the front of the scaphoid bone and ridge of the os trapezium, the tendon of the flexor carpi radialis separating the two, and internally by two portions, one transverse to the process of the unciform, and one oblique to the pisiform bone; this last is continuous with the ligament attaching the pisiform to the unciform bone. The cutaneous surface is covered by the muscles of the thumb and little finger, by the palmaris longus tendon, and by the ulnar artery and nerve, which are fixed to the ligament by some tendinous fibres from the insertion of the flexor carpi ulnaris; the posterior is in contact with the tendons of the flexor sublimis, and median nerve, and is covered by the synovial membrane.

Tendon of the Flexor Carpi radialis. The *tendon of the flexor carpi radialis* has been followed to the annular ligament; it then passes beneath this ligament, enters a groove in the trapezium, bound down in it by a fibrous sheath, and so it reaches the head of the metacarpal bone of the index finger, into the palmar surface of which it is inserted. The sheath of this tendon is formed in part by the annular ligament, and in part by a fibrous expansion stretched from the trapezium to the os trapezoides and metacarpal bone; open the sheath to see the synovial membrane which lines it and surrounds the tendon.

The insertions of the brachialis anticus and biceps, left in the dissection of the front, may be examined before turning to the back of the forearm.

Insertion of the Brachialis. The *brachialis anticus* is *inserted* by a broad and thick tendon, which commences in the centre of the fleshy fibres above the joint and is more marked on the outer side, into the anterior surface of the ulna in front of the coronoid process, and it is surrounded by the digitated origin of the flexor profundus, as the insertion of the deltoid is by its superior attachment. Cut

across the muscle to see the origin from the capsule of the articulation, and from the humerus nearly down to this.

As the *tendon of the biceps* sinks into the hollow of the bend of the elbow, its surfaces change their direction, the anterior becoming external and the posterior internal; and it is *inserted* into the posterior part of the bicipital tuberosity of the radius, a large bursa separating it from the bone. At its attachment, it is closely surrounded by the supinator brevis, whose line of insertion is interrupted by the presence of the tendon. Tendon of the Biceps.

DISSECTION OF THE BACK OF THE FOREARM.

Turn over the arm and hand, remove the integuments from any of the fingers, should it not be done. Make an incision along the centre of the fascia, and remove it to the posterior annular ligament; also remove it and the cutaneous nerves and vessels from the back of the hand, so as to trace up the tendons to the extremities of the fingers. Dissection.

The *posterior annular ligament* is a band of the fascia of the arm thickened by transverse fibres; its direction is obliquely downward and inward, and it is placed, at its inner termination, below the extremity of the ulna; it is attached, externally, to the radius and fascia of the arm, and internally, to the pisiform bone and palmar fascia. The upper and lower borders are continuous with the fascia of the extremity. From its deep surface, processes pass vertically down to the bone, separating the space beneath into compartments or sheaths, which are lined by synovial membrane, and allow the tendons to pass through them to reach the hand: the most external sheath is for the tendon of the extensor of the metacarpal bone, and that of the first phalanx of the thumb; next, a larger one for the two radial extensors of the wrist; a very small one to the ulnar side of this, for the extensor of the second phalanx of the thumb; then one for the tendons of the common extensor of the fingers, and the indicator; one for the extensor of the little finger; and lastly, one for the ulnar extensor of the wrist. Posterior Annular Ligament.

The muscles on the back and outer part of the forearm arise mostly by a common tendon from the outer condyle. They are antagonists in their action to the muscles placed on the front and inner side, so that a flexor in front has its extensor behind; they are also divided into a superficial and deep layer, and as the superficial layer in front consisted of both a pronator and flexors, so the similar one behind has a corresponding supinator and extensors; and the last are again classed into radial and ulnar extensors of the wrist, and common extensor of the fin- Muscles on the back of the Forearm.

gers. The deep layer, too, consists of a supinator and extensors, the similar one in front having a pronator and flexors. The following are the muscles in the superficial layer: in proceeding from without inwards, the supinator radii longus, extensor carpi radialis longior and brevior; then, lying close to the ulna, the extensor carpi ulnaris, and between these the extensor communis, and the small extensor minimi digiti; and another extensor muscle which cannot be classed with them, is the small anconeus.

Supinator longus Muscle. Origin.

The *supinator radii longus,* the most external and superficial of the muscles forming the outer prominence of the forearm, limits also externally the hollow of the bend of the elbow; it is situated partly in the arm and forearm. It *arises* from the ridge leading to the outer condyle of the humerus, commencing below the groove in this bone, and extending downwards for two thirds of its extent, and from the intermuscular septum behind it, which separates it from the triceps: the fibres descend to form a fleshy belly, which, above the elbow, has its borders directed forwards and backwards, but below the articulation, where the muscle is largest, inwards and outwards; and it ends above the middle of the forearm in a tendon which descends along the radius, narrowing in its course, to be *inserted* by an expansion into the base of the styloid process of this bone. The muscle is subcutaneous in its extent, except at the insertion which is crossed by the two extensors of the thumb; and it lies on the extensor carpi longus, the supinator brevis, the insertion of the pronator teres, the radial origin of the flexor sublimis, the radial nerve which escapes from beneath it two inches and a half above the extremity of the radius, and lastly, on the radius. Along its inner side, above, is placed the brachialis anticus, the musculo-spiral nerve being between the two; it next forms the outer boundary of the hollow of the bend of the elbow, and is in relation with the tendon of the biceps, thence to its termination the radial artery lies close to it, and it is this border of the muscle which is the guide to this vessel in the middle and lower thirds of the forearm; to the outer side, above the elbow, are the triceps and intermuscular septum, and below, the radial extensor.

Insertion. Relations.

Extensor Carpi radialis longus Muscle. Origin.

The *extensor carpi radialis longior muscle* is exposed by turning aside the preceding, with which its fibres are sometimes united, and its tendon of insertion should also be separated from the tendon of the next muscle, to which it is closely connected. The muscle *arises* from the lower third of the ridge leading to the outer condyle, the surface of the bone being marked for this attachment, and from the intermuscular septum behind it. The fibres descend, forming a muscle that is flattened, like the supinator longus, and ends in a tendon about the middle of the forearm, which descends vertically on the other radial extensor, and

beneath two of the extensors of the thumb, to the annular ligament, enters beneath this structure in the division appropriated to it and the other radial extensor lying on the same level, and in the large groove marked in the posterior surface of the lower extremity of the radius; and below the ligament it is directed backwards, beneath the tendon of the extensor of the second phalanx of the thumb, to be *inserted* into the posterior and outer part of the head of the metacarpal bone of the index finger. It is covered by the supinator longus, and about two inches from the extremity of the radius by the extensor ossis metacarpi and primi internodii pollicis muscles, and below the annular ligament it is crossed again by the extensor secundi internodii pollicis: it lies on the extensor carpi radialis brevior, supinator brevis, and below, on the radius and wrist joint. The anterior border is in relation with the radial nerve till it becomes cutaneous, and the posterior touches the extensor brevior which projects beyond it. The part of the tendon below the annular ligament is surrounded by a fibrous sheath, which contains a prolongation of the synovial membrane of the partition of the annular ligament through which it passed.

Insertion. Relations.

The *extensor carpi radialis brevior* is the last muscle which assists to form the prominence on the outer side of the forearm; it is situated beneath the other two, and does not extend above the condyle of the humerus. Its *origin* is from the outer condyle by means of a tendon common to it and the remaining muscles of the superficial layer, viz. the extensor communis, extensor minimi digiti, and extensor carpi ulnaris; from an aponeurotic septum between it and the extensor communis, and from an aponeurosis prolonged on its under surface from the common tendon: the fibres descend lower than those of the other extensor to a tendon, which, placed beneath that of the extensor longior, reaches to the annular ligament, passes through the same partition and groove in the radius, escaped from this and surrounded by a fibrous sheath lined by synovial membrane, it passes backwards from the other, and is *inserted* into the posterior part of the head of the metacarpal bone of the middle finger. It is covered by the two preceding muscles, but its ulnar border projects beyond them; the extensors of the metacarpal bone and of the first phalanx of the thumb cross it above the ligament, and that of the second phalanx, below the ligament. The ulnar border in the upper half of the forearm is in contact with the extensor communis, but below this the extensors of the thumb intervene. Separate this muscle from the extensor of the fingers, and it is seen to lie on the supinator brevis, on the radius and insertion of the pronator teres, on the origin of the extensor ossis metacarpi, on the lower part of the radius, and back of the wrist joint and carpus. Separate upwards from each other the following muscles of the superficial layer.

Extensor Carpi radialis brevis Muscle. Origin.

Insertion. Relations.

Extensor Digitorum. Origin.

The *extensor digitorum communis muscle* is long and tapering, and is placed to the ulnar side of the last; it is undivided above, but below it ends in four tendons for the fingers. It *arises* from the common tendon attached to the outer condyle, from the aponeurosis between it and the muscles around, and from the aponeurosis of the forearm. The fibres descend to form a muscle which soon increases in size, and divides about the middle of the forearm into three portions, whose tendons become free from muscular fibres above the wrist, enter the sheath in the annular ligament appropriated to them and the indicator muscle, and lie in the groove of the radius to the ulnar side of the small one for the extensor of the second phalanx of the thumb, in which they are surrounded by synovial membrane; escaped from the ligament, the ulnar tendon divides into two, and the four for the fingers diverge from each other, to reach the metacarpo-phalangeal articulations, over which they are placed, and send down on the sides of each a process to join the capsule of the articulation: each tendon now forms on the dorsum of the first phalanx a tendinous expansion, which is joined by that from the interossei and lumbricales, and, on the index and little fingers, by their proper extensor tendons; at its digital extremity the expansion is divided into three portions, a central one which passes over the articulation between the first and second phalanges, to be *inserted* into the base of the second, and two lateral, which continue along its sides, converge and unite at its fore part, to be inserted into the base of the ungual or last phalanx. The muscle is subcutaneous, except beneath the annular ligament; the radial border is in contact with the extensor carpi radialis brevior, and the ulnar with the extensor minimi digiti; and the muscle covers the deep layer, consisting of the supinator brevis, the three extensors of the thumb, the indicator muscle, the posterior interosseous vessels and nerve, and the carpal and phalangeal articulations and bones. The tendon of the index finger crosses, below the wrist, the second interosseous space, and joins, at the metacarpo-phalangeal articulation, with that of the indicator which is to its ulnar side; and the tendon of the little finger lies on the fourth metacarpal bone, and joins that of its proper muscle at the corresponding articulation. The tendon for the ring finger, often split longitudinally, sends, a little above the head of the fourth metacarpal bone, an oblique tendinous band to each side to join the collateral tendons, and these prevent the extension of this finger when the middle and little ones are flexed.

Insertion.

Relations.

Extensor minimi Digiti Muscle. Origin.

The *extensor minimi digiti*, the most slender muscle on this surface of the forearm, is placed between the extensor ulnaris and extensor communis, and it appears only a portion of the last muscle separated by an aponeurosis. It *arises* from the common tendon, and from aponeuroses which surround it as the extensor

communis: the fibres descend to a tendon, which receives muscular fibres down to the annular ligament, then enters beneath this in a sheath distinct from that of the extensor communis, escapes from the ligament, and is divided, longitudinally, into two portions, which run along the metacarpal bone to the ulnar side of the tendon from the common extensor, and unite together as well as with this, opposite the articulation, to give rise to the expansion on the first phalanx, which is distributed as the rest. It is in contact with the fascia of the forearm, it lies on the deep layer of muscles, and is situated between the extensor digitorum communis and extensor carpi ulnaris muscles. Insertion. Relations.

The *extensor carpi ulnaris muscle*, the most internal of the superficial layer, lies on the ulna, and *arises* from the common tendon, from the middle third of the posterior ridge of the ulna below the anconeus muscle, from the fascia of the arm, and a septum between it and the extensor of the little finger. The fibres are directed downwards to a tendon which commences on the cutaneous surface about the middle of the forearm, and receives fleshy fibres to the annular ligament, then passes through a separate division in this structure, lying in a groove in the posterior surface of the ulna, and having a synovial membrane reflected around it; and below the ligament the tendon is surrounded by a fibrous sheath which accompanies it to its *insertion* into the inner and posterior part of the head of the metacarpal bone of the little finger. This muscle is in contact with the fascia of the arm; the ulnar border corresponds to the insertion of the anconeus and to the ulna; the radial, to the extensor of the little finger; and beneath the muscle are the supinator brevis, indicator muscle, and ulna. Extensor Carpi ulnaris Muscle. Origin. Insertion. Relations.

The *anconeus* is a small triangular muscle of this layer, and seems to be a continuation of the triceps extensor. It *arises* by a tendon from the outer condyle of the humerus, which is distinct from the common tendon, and posterior to it. From it the fibres diverge, the upper the shortest, and parallel to the lowest fibres of the outer head of the triceps, transversely, and the others obliquely, to be *inserted* into the outer side of the olecranon, and into the triangular impression on the upper part of the posterior surface of the ulna. It is in contact with the skin and fascia; and it rests on the ulna, supinator brevis, and external lateral ligament, on the recurrent interosseus artery which enters beneath its lower border, and on the branch of nerve from the musculo-spiral, and artery from the superior profunda. The lower border is parallel to the extensor carpi ulnaris, and the upper to the fibres of the outer head of the triceps, with which it is continuous. Anconeus Muscle. Origin. Insertion. Relations.

Detach the extensor communis and minimi digiti muscles from their common origin, and throw them to one side; separate Dissection.

also the origin of the extensor carpi ulnaris, and turn this muscle aside, but in doing it, avoid the external lateral ligament: the branches of the nerve and artery that it will be necessary to divide should be noticed; they are from the posterior interosseous, and are to be dissected: the cellular membrane is next to be removed from the muscles. The line of separation of the small muscles of this layer is often indistinct.

Deep Layer of Muscles.

The deep layer of muscles of the back of the forearm consists of a supinator, to correspond to a deep pronator in front, and of extensors of the thumb and index finger. The highest muscle, surrounding the upper extremity of the radius, is the supinator brevis: below this are four other muscles crossing to the radial side of the arm; the three highest are the extensors of the thumb, viz. extensor ossis metacarpi, primi internodii, and secundi internodii, and the lowest or most vertical on the ulna, is the indicator muscle.

Extensor Ossis metacarpi Muscle. Origin.

The *extensor ossis metacarpi pollicis,* the largest of the extensor muscles of the thumb, is placed more externally than the others, and its tendon is closely united, below, to that of the extensor primi internodii. The muscle arises from the posterior surface of the radius and ulna for about three inches, immediately below the insertion of the supinator brevis, with which muscle the fibres are sometimes united, also from the interosseous membrane between the bones. From this origin the fibres run outwards and downwards to join a flat tendon which crosses the radial extensors of the wrist about two inches above the extremity of the radius, enters the outer partition in the annular ligament, with the small tendon of the extensor primi internodii, from which it is separated by one of the fibrous processes; it then leaves the ligament, crosses the radial artery, and is *inserted* into the outer part of the carpal end of the metacarpal bone of the thumb, and it often sends a prolongation to the abductor pollicis muscle. It is covered by the extensor of the fingers, by that of the little finger, and by the interosseous nerve and artery; and it lies on the ulna, interosseous membrane, and radius, on the radial extensors, and on the radial artery winding backwards below the radius. The upper border is in contact with the supinator brevis, and posterior interosseous artery which appears between the two; the lower touches the extensor primi and secundi internodii pollicis muscles.

Insertion.

Relations.

Extensor primi internodii Muscle. Origin.

The *extensor primi internodii pollicis* is a small muscle, and the next in order from above downwards. Its *origin* is from the radius below the preceding for about one inch, from the interosseous membrane, and sometimes from the ulna; the fibres end in a tendon which appears soonest on the border of the muscle in contact with the extensor ossis metacarpi, and this is the guide to separate the two; it then enters the annular ligament with the extensor ossis metacarpi, being separated

from the other tendon by a process of membrane, crosses the radial artery, continues along the metacarpal bone of the thumb, and is *inserted* into the base of its first phalanx. This muscle has the same relations as the former, since it appears between the extensor of the fingers and those of the wrist; it also lies on the same parts, except on the ulna, and below the annular ligament it is placed on the metacarpal bone of the thumb. The upper border is in contact with the extensor ossis metacarpi pollicis muscle. Insertion. Relations.

The *extensor secundi internodii pollicis* is a larger muscle than the last, and is placed on the ulna. It *arises* from the middle third of the ulna, below the insertion of the supinator brevis, and between the extensor ossis metacarpi and anconeus, and from the interosseous membrane. Its fibres are directed downwards and outwards to a tendon, which passes through a separate partition in the annular ligament, corresponding to the groove in the radius between those for the extensors of the wrist and extensor of the fingers; it then leaves the ligament, crosses the tendons of the extensores carpi radiales, and the radial artery, runs along the ulnar side of the metacarpal bone and first phalanx of the thumb, to be *inserted* into the base of the second or ungual phalanx. It is covered by the same muscles as the other two extensors of the thumb, and appears lower down, or nearer the extremity of the radius; it lies on the ulna, interosseous membrane, and radius, and below the annular ligament crosses the tendons of the radial extensors of the wrist, and the radial artery as it is about to enter the palm: this tendon is the guide to the artery in this position; it also lies on the metacarpal bone and on the phalanges. Extensor secundi internodii. Origin. Insertion. Relations.

The *extensor proprius indicis*, or *indicator muscle*, situated on the ulna, *arises* from the middle part of this bone, extending lower than the extensor secundi internodii, and slightly, below, from the interosseous membrane: the fibres descend, as far as the annular ligament, around a tendon, which is then freed from them, enters the same sheath of the ligament as the extensor of the fingers, beneath which it lies, runs along the ulnar side of the tendon from the common extensor to the index finger, as far as to the head of the metacarpal bone, and joins with this tendon, as well as with those of the interossei and lumbricalis, to form an expansion on the first phalanx, as before seen. The muscle is concealed by the superficial extensors above the annular ligament, but below, it is subcutaneous; it is placed between the extensor tendons of the first and second fingers, and lies on the second metacarpal bone. Indicator Muscle. Origin. Insertion. Relations.

The *supinator radii brevis muscle* will be exposed by detaching the anconeus from the external condyle, and by cutting through the supinator longus and radial extensors of the wrist opposite to it; separate in front the process of the flexor pro- Supinator brevis Muscle.

fundus, which lies to the radial side of the insertion of the brachialis anticus muscle. This supinator surrounds the upper extremity of the radius, and extends to its front; it *arises* from the external lateral ligament, and from the coronary ligament surrounding the head of the radius, by aponeurotic fibres; from the outer border of the ulna for about two inches, commencing close below the small sigmoid cavity; and, in front of this border, from a triangular depression, also below the cavity; this last attachment is best seen from before, or by cutting across the muscle when it is finished. From these origins the fibres pass forwards and outwards round the radius, and are *inserted* into the posterior and outer surfaces of the upper third of this bone, extending down to near the insertion of the pronator teres, and forwards to the oblique line which runs outwards from the tubercle to which the flexor sublimis is attached; some fibres are also inserted above the tubercle, and reach farther inwards than the others. The cutaneous surface of the muscle is covered behind by the anconeus and recurrent interosseous artery, by the extensor ulnaris, extensor minimi digiti, and extensor digitorum; on the outer side by the supinator longus and radial extensors of the wrist; and in front the radial artery with its recurrent branch, and the radial nerve lie on it, and the posterior interosseous nerve perforates this surface. The anterior border is fixed to the radius, the fibres above the tubercle reaching to those attached to its posterior surface, but opposite this process the margin is hollowed out for the tendon of the biceps and its synovial membrane, and below this it corresponds to the attachment of the interosseous membrane, and origins of the flexor sublimis and flexor pollicis; and the posterior or ulnar is fixed to the ulna, and is overlapped by the anconeus: the lower border is parallel to the extensor ossis metacarpi, and in contact with it, the posterior interosseous artery appearing between the two; and the upper is in contact with the articulation of the elbow. The muscle lies on the radius, the upper radio-ulnar articulation, and interosseous ligament.

Origin.

Insertion.

Relations.

The *posterior interosseous artery*, arising from the common interosseous trunk opposite the tubercle of the radius in the front of the forearm, passes to the posterior part above the interosseous membrane, giving off its recurrent artery which is nearly as large as the trunk; it then appears between the contiguous borders of the supinator brevis and extensor ossis metacarpi pollicis, descends between the superficial and deep layers of muscles, decreasing in size, to near the wrist, and it ends by giving some branches to join the dorsal branch of the anterior interosseous artery, which passes backwards below the interosseous membrane, and others to anastomose with the dorsal carpal branches from the radial and ulnar arteries. In its course it supplies branches to the two layers of muscles between which it is

Posterior Interosseous Artery.

situated. The *posterior interosseous recurrent branch*, of nearly equal size with the descending part of the artery from which it springs, is given off before the artery reaches the back of the forearm, perforates some of the fibres of the supinator brevis, ascends on this muscle beneath the anconeus, and divides into two branches; one ascends with a direction outwards to the articulation, the other continues beneath the anconeus, to anastomose with the long branch of the superior profunda, which descends to this muscle, and also with the branches which run along the intermuscular septum. Recurrent branch.

The *posterior interosseous nerve*, a branch of the musculo-spiral in front of the outer condyle of the humerus, and whilst this nerve is covered by the supinator longus muscle, descends on the anterior surface of the supinator brevis, perforates its fibres to gain the back of the forearm, and escapes from the supinator above its lower border. The nerve now gives off numerous branches to the superficial layer of muscles, and one long branch, in direction the continuation of the nerve, descends over the extensor ossis metacarpi and primi internodii pollicis muscles, and about the middle of the forearm passes beneath the extensor secundi internodii to reach the interosseous membrane, at the lower part of which it gives off an internal branch beneath the extensor secundi internodii to supply the indicator. Continuing to descend, it enters the sheath in the annular ligament for the extensor digitorum, and beneath the tendons of this muscle, and on the back of the carpus it is enlarged, and divides into many branches to supply the ligaments and articulations of the carpus. Before this nerve enters the supinator brevis, it gives a branch to the extensor carpi radialis brevior, the extensor longior and supinator longus muscles receiving separate branches from the musculo-spiral, and it supplies filaments to the supinator brevis whilst in the muscle: on the back of the forearm it distributes filaments to the remaining muscles of the superficial layer, except to the anconeus, and the extensor digitorum receives the most. The branches to the deep layer are from the trunk of the nerve as it descends in contact with it. Posterior Interosseous Nerve. Branches. Muscular.

The only part of the radial artery which has not been seen, connects the portion in the forearm with its division in the palm. It is of short extent, and commencing at the lower extremity of the radius, winds from the anterior to the posterior part below the end of the bone; at the carpal extremity of the first interosseous space it enters the palm of the hand between the origins of the abductor indicis, and divides into its terminal branches for the supply of the thumb, radial side of the index finger, and the branch of the deep arch. It is placed, at first, deeply in the hollow below the extremity of the radius, is beneath the extensor ossis metacarpi and primi internodii pollicis, and lies on the external lateral ligament of the wrist-joint; it becomes more Radial Artery below the Radius.

superficial on the back of the carpus, and immediately before passing through the muscle, is crossed by the tendon of the extensor secundi internodii pollicis, which is the guide to the artery. Some filaments of the dorsal branch of the radial nerve and some cutaneous veins cross this part of the vessel, and filaments of the musculo-cutaneous surround it, being continued on it from the front. The deep veins with the artery are continuous with the radial. Numerous but small branches arise from the artery in this part.

Branches.

Dorsal Carpal branch.

The *dorsal carpal artery* is a small branch which leaves the radial as it lies against the carpal articulations, and beneath the tendons of the extensors of the thumb, it passes transversely inwards across the bones of the carpus, and beneath the tendons of the extensors, and unites with the dorsal artery from the ulnar, to form an arch from which branches pass upwards to anastomose with the dorsal branch of the anterior interosseous, and with the posterior interosseous, and others descend to the interosseous spaces.

Metacarpal.

The *metacarpal branch*, which is interosseous in its position, and varies much in size, runs backward on the carpus, and beneath the tendons, to reach the interval between the second and third metacarpal bones; it then continues forwards on the second interosseous muscle, as far as the cleft of the fingers, and terminates by joining the digital branch from the superficial arch: it gives dorsal superficial arteries to the index and middle fingers. The other interosseous or metacarpal arteries for the two last interosseous spaces are small, they are derived from the carpal arch of arteries, and anastomose with the posterior perforating branches. The ulnar side of the little finger is supplied by the metacarpal branch of the ulnar artery.

Dorsal of the Thumb.

The *dorsal arteries of the thumb*, sometimes double, at others united at their origin, arise opposite the head of the metacarpal bone, they are very small, and are distributed to the sides of the thumb.

Dorsal of the Index Finger.

The *dorsal of the index finger* is another small branch given off opposite the former, it runs along the radial side of the back of this finger, to which it is distributed.

Dorsal Interossei Muscles.

Clean the dorsal surface of the posterior interossei muscles. These have a double origin from the sides of the metacarpal bones, between which they are placed. The fibres descend to a tendon in the centre, which becomes free opposite the metacarpo-phalangeal articulation, is inserted into the side of the metacarpal phalanx, and sends an expansion to the dorsum of the same. This surface of the muscles is subcutaneous, and the posterior part of each is perforated by the posterior perforating arteries to join the interosseous. The first has been described as a separate muscle, with the name of abductor indicis: it is perforated by the radial artery.

Divide the supinator brevis by a vertical incision, to see its attachments.

Annular Ligament and Grooves of the Radius.

The sheaths of the annular ligament may be now more readily examined by dividing them over the different tendons that pass through it. They correspond to grooves in the lower part of the posterior aspect of the radius and ulna: thus on the radius, beginning at its outer border, is the groove for the two extensors of the thumb, then a large one for the two radial extensors of the carpus, next a small deep one for the extensor secundi internodii; to the ulnar side of this a large depression for the extensor of the fingers and indicator, and on the inner margin another, better seen in the recent bone, for the extensor of the little finger. The groove in the back of the ulna is for the extensor carpi ulnaris muscle.

DISSECTION OF THE UPPER EXTREMITY.

Dissection.

Continue the dissection of the upper extremity, with the examination of the ligaments, without soaking them in water, unless they should be dry; those of the elbow may be taken first. To expose these, take away the brachialis anticus from the front, the triceps from the back, also the muscles arising from the outer and inner condyles, and detach the supinator brevis and flexor profundus muscles; remove the cellular membrane.

Elbow-joint.

The articulation of the elbow is a ginglymus joint, admitting only of extension and flexion, and into it enter the extremities of the humerus, radius, and ulna, whose articular surfaces are covered with cartilage, and maintained in contact by an anterior, posterior, external, and internal ligament: a synovial membrane is reflected over the whole.

External Lateral Ligament.

The *external lateral ligament* is a small roundish band, easily removed with the muscles which arise from the outer condyle of the humerus; it is pointed above, and is fixed to the external condyle of this bone; but its fibres spread out as they descend, and join below the orbicular ligament surrounding the head of the radius, and the most posterior fibres pass backwards to be inserted into the ridge of the ulna, to which the supinator brevis is attached. This ligament gives origin to the supinator brevis, and is covered by the muscles which arise from the outer condyle.

Internal.

The *internal lateral ligament*, best seen by slightly bending the joint, is a deltoid-shaped process, attached above to the inner condyle or epitrochlea of the humerus; the fibres descend, radiating, to be inserted by an anterior portion, the strongest,

into the inner lip of the coronoid process, and by a posterior, into the inner side of the olecranon, whilst the middle fibres join a transverse ligamentous band, stretched from the olecranon to the coronoid process over a notch in their angle of junction. Its cutaneous surface is covered by the tendon of the muscles arising from the inner tuberosity, as well as by the ulnar nerve and artery, which supply branches to the articulation.

Anterior Ligament. The *anterior ligament* is a thin membrane placed in front of the joint, and connected, on the sides, with the lateral ligaments; it is fixed, above, to the front of the humerus above its articular surface, and below, to the anterior part of the coronoid process and to the orbicular ligament. The superficial fibres, oblique downwards and outwards, cross the deep, which are vertical; they are separated also by intervals containing cellular membrane. The brachialis anticus lies on it.

Posterior. The *posterior ligament*, very thin, in consequence of being covered by the tendon of the triceps extensor, is also best seen by flexing the elbow; it is continuous with the lateral ligaments, this union being best seen on the inner side, and it has some transverse fibres which are stretched across the fossa on the posterior surface of the humerus. The synovial membrane will be seen when the upper articulation of the radius and ulna have been dissected, for it serves to line their contiguous articular surfaces.

Union of the Radius and Ulna. The radius is united to the ulna, both above and below, by means of ligaments; but there is a separate articulation and synovial membrane between them only below, since the ligaments joining the bones above are lined by the synovial membrane of the elbow: the shafts of the bones are also united by an interosseous ligament. The upper cup-shaped articular surface of this bone enters into the elbow-joint, and the lower into the articulation of the wrist.

Upper Radio-ulnar Articulation. The *upper radio-ulnar articulation* results from the reception of the convex head of the radius into the small sigmoid fossa of the ulna, in which it is kept by an orbicular ligament, and the articular surfaces are covered by synovial membrane.

Orbicular Ligament. The *orbicular* or *annular ligament*, surrounding the head of the radius, is best seen by making a transverse incision through the anterior ligament of the elbow-joint, between the extremities of the humerus and radius, from the coronoid process in front to the olecranon behind. It is a strong, flat, fibrous band, about a quarter of an inch wide, and forms, with the small sigmoid cavity of the ulna, a circle, in which the head of the radius freely moves, since no ligamentous structure is inserted into the bone, and the synovial membrane projects between it and the ligament. It is attached, in front, to the anterior part of the sigmoid cavity, and behind, to its posterior margin, and to a depression on the ulna below the cavity; its fibres are transverse,

and the posterior attachment is wider than the anterior. The upper border is united to the anterior, and the external lateral ligament; the inferior, free, surrounds the neck of the radius, from which it is separated by a *cul-de-sac* of the synovial membrane. The ligament is covered by the supinator brevis, and by the muscles which arise by a common tendon from the outer condyle of the humerus.

Dissection. Open the articulation of the elbow by carrying the incision transversely inwards to the olecranon, and disarticulate the bones, to see the surfaces which enter into it.

Articular Surfaces of the Elbow-joint. In the elbow-joint, the ulna presents its large articulating or sigmoid cavity, which is covered with cartilage, except on the inner side, is narrow in the centre, and deprived also of cartilage at this part, but is expanded in front and behind by means of the coronoid and olecranon processes. A slightly raised line extends from the front to the back of the cavity, and is received into the hollow of the pulley-like surface of the humerus. The upper extremity of the radius has a circular depression with a raised margin. The lower end of the humerus, in this articulation, presents, internally, a large pulley-like surface, hollowed out in the centre, to receive the eminence in the articular surface of the ulna, and it is limited internally and externally by prominent lines; the internal, the most marked, reaches lowest, and the external corresponds to the interval between the head of the radius and that of the ulna. On the outer side of the bone is a rounded articular surface, covered with cartilage, and placed only on the front; this is in contact with the head of the radius only in flexion of the articulation; for, during extension, this bone does not touch the humerus; a slight depression separates this articular surface from the line which limits externally the pulley, and it receives the margin surrounding the hollow in the head of the radius. On the anterior surface, above the pulley, is a depression to receive the coronoid process during flexion, and on the posterior, a large one for the olecranon in extension of the forearm.

Synovial Membrane. The *synovial membrane* covers the under surface of the anterior ligament, passes to the articular surfaces of the radius and ulna, sends a process into the small sigmoid cavity, and a *cul-de-sac* between the head of the radius and its orbicular ligament, then lines the posterior ligament, and so reaches the lower extremity of the humerus, over which it is reflected.

Dissection. Cut across the orbicular ligament, to see its attachments in front of the small sigmoid cavity, as well as behind it: the cavity is now seen.

Interosseous Ligament. The *interosseous ligament* or *membrane*, situated between the radius and ulna, is seen by removing the muscles from its front and back. It is a thin aponeurotic septum between the muscles of the anterior and posterior part of the forearm, and is attached

to the margins of the radius and ulna, which look towards the space across which it is placed; it is larger in the middle than at the extremities, and the fibres composing it are directed obliquely upwards and outwards from the ulna to the radius; some fibres on the posterior surface have an opposite direction, so as to cross them. The membrane is fixed above to the radius, to within about an inch of the tubercle, but to the ulna rather higher, so that an aperture is left above it to allow the posterior interosseous artery to reach the back of the forearm; below, it reaches to the extremities of the bones. About two inches above the lower border is a small aperture, near the radius, for the dorsal branch of the anterior interosseous artery; other small foramina for vessels are found in it. The anterior surface is covered by the flexor profundus digitorum and flexor pollicis, with the anterior interosseous nerve and artery, which are in contact with it; the posterior is in relation with the supinator brevis, the three extensors of the thumb, and the indicator muscle; the interosseous artery and nerve do not touch the membrane above, but below, the nerve reaches it. Above the upper attachment of the ligament, the supinator brevis and flexor profundus are close to each other.

Round Ligament.

The *round ligament* is a ligamentous fasciculus, extended obliquely between the upper extremities of the radius and ulna above the interosseous ligament; it is attached to the front of the ulna below the insertion of the brachialis anticus; its fibres run downwards and outwards in a direction opposite to those of the interosseous ligament, superficial to which they are placed, and are fixed to the radius below its tubercle; it is situated beneath the flexor sublimis, and divides the space above the interosseous membrane into two parts: through the lower of these passes the posterior interosseous artery.

Wrist-joint.

Before the lower radio-ulnar articulation can be seen, dissect the wrist-joint. To see the *radio-carpal articulation* remove the tendons and annular ligament both from before and behind it, clean away the cellular membrane and small vessels from the surface of the ligaments. In the wrist-joint the lower end of the radius articulates with some of the first row of the carpal bones, but the ulna is entirely shut out from the articulation by means of a piece of cartilage which intervenes between its lower end and the carpal row, and enters into the wrist-joint. The surfaces of bone are kept in position by an anterior, posterior, internal, and external ligament.

External Lateral Ligament.

The *external lateral ligament* is a short and small band which extends from the styloid process of the radius to the upper part of the scaphoid bone, external to its articular surface; the fibres diverge from each other. This is crossed by the radial artery, and is connected to the anterior and posterior ligaments.

Internal.

The *internal lateral ligament*, smaller than the external, but

longer than it, is attached, above, to the styloid process of the ulna, and below, to the rough upper part of the cuneiform bone, internal to its articular surface; and some of the anterior fibres pass forwards to the pisiform bone.

The *anterior ligament*, strong, though short, is fixed to the lower end of the radius, above the articular surface of the bone, and some fibres come from the lower part of the ulna; it is inserted, below, into the front of the first row of carpal bones, except into the pisiform, which does not receive any; it is covered by the flexor tendons, and is perforated by small arteries from the carpal arch. Anterior Ligament.

The *posterior ligament*, like the anterior, is a fibrous expansion, with oblique fibres directed downwards and inwards; it is attached, above, to the posterior aspect of the lower ends of the radius and ulna, and below, to the posterior surface of the same three bones of the carpal row, its fibres being continuous at this insertion with the posterior ligament between the two rows of the bones. The extensor tendons, the posterior carpal arch of arteries, and the posterior interosseous nerve lie on this ligament. Posterior.

Open the articulation by a transverse incision across the posterior ligament near the carpal bones. The three first bones of the carpal row are united together by ligaments, and form an oval, convex or condyloid portion, which is received into the hollow above. The surfaces in the articulation are covered with cartilage, which extends further on their posterior than anterior part; the scaphoid and semilunar bones touch, above, the lower end of the radius, but the cuneiform, which presents a very small articular surface, is in contact only with the inter-articular cartilage which excludes the ulna from the wrist-joint. The lower end of the radius, and the inter-articular fibro-cartilage below the end of the ulna, are united together to form an arch, into which the convexity of the carpal row projects. The articular surface of the radius is covered with cartilage, and marked in the centre by a prominent line that divides it into an external triangular surface, which the scaphoid bone touches, and an internal square one, which corresponds to the semilunar bone. The inter-articular cartilage is placed over the cuneiform bone. Articular Surfaces.

The *synovial membrane* covers the articular surfaces of the radius and inter-articular fibro-cartilage, and is reflected along the anterior and posterior ligaments to the bones of the carpus. Sometimes, this membrane joins that in the lower radio-ulnar articulation by means of an aperture through the inter-articular cartilage; and at others, the synovial membrane investing the bones of the carpus, which sends prolongations up to it between the bones of the first row. Synovial Membrane.

The *lower radio-ulnar articulation* is formed by the convex Lower

Radio-ulnar Articulation.

head of the lower part of the ulna being received into a concavity on the radius: which is an arrangement the opposite to that above; since in the upper articulation, the convex head of the radius is received into a concavity of the ulna. The chief means of union between the bones is a process of fibro-cartilage; and a kind of capsule, consisting of scattered fibres, surrounds the extremity of the ulna, it is looser and larger in front than behind: the synovial membrane is very loose.

Triangular-fibro-cartilage.

The *triangular* or *inter-articular fibro-cartilage* of this articulation will be seen by taking away the capsule, by detaching the radius and ulna from the first row of the carpal bones, and by removing the articular end of the ulna, so as to leave untouched the styloid process of this bone. It attaches the radius to the ulna, and is placed transversely beneath the lower extremity of the last; it is triangular in shape, its base is fixed to the ridge which separates the carpal from the ulnar articulating surface of the radius, and its apex to the depression at the root of the styloid process of the ulna; it is thicker at its margins and apex than at its centre or base. The anterior border is more closely united to the anterior ligament of the wrist, than the posterior is to its ligament. The upper surface is in contact with the ulna, which it separates from the wrist-joint, and is covered by the synovial membrane of the radio-ulnar articulation; the lower forms part of the wrist-joint, is opposite to the cuneiform bone, and is covered by the synovial membrane of the wrist. Occasionally, this cartilage is perforated by an aperture near the radius through which the synovial membranes communicate.

Synovial Membrane.

The *synovial membrane*, called *sacciformis* from its looseness, covers the upper surface of the inter-articular cartilage, and the lower part of the ulna in contact with it, and is then reflected up between the articular surfaces of the radius and ulna, covering them, and the capsule of the articulation.

Articulation of the Carpal Bones.

The carpal bones are articulated together by surfaces covered with cartilage, and by dorsal, palmar, and interosseous ligaments which join them into two separate rows; and these, again, have an anterior, posterior, internal, and external ligament to unite them. One synovial membrane serves for the investment of the articular surfaces of all the carpal bones, except those between the cuneiform and pisiform bones. To see the ligaments, clean carefully their surface.

First row. Dorsal Bands. Palmar. Interosseous Ligament. Pisiform and Cuneiform Bones.

The *carpal bones of the first row* are united together by a *dorsal* transverse band from the scaphoid to the semilunar, and by another from the semilunar to the cuneiform bone; the same are found on the palmar surface. An *interosseous* ligament is placed between the scaphoid and semilunar, and between the semilunar and cuneiform bones. The pisiform bone has a separate capsule attaching it to the articular surface in front of the cuneiform, and a distinct synovial membrane is placed between

the bones; two ligaments, in addition, connect the pisiform bone; one small one passes to the process of the unciform, and another larger one forwards to the head of the metacarpal bone of the little finger.

The *bones of the second row* are connected together in the same way as those of the first, a band being found between the os trapezium and trapezoides, between the os trapezoides and magnum, and between the os magnum and unciforme, both on the dorsal and palmar surface; the dorsal bands are stronger than the palmar. An interosseous ligament is also found between the os magnum and unciforme, and between the magnum and trapezoides.

The second row. Dorsal. Palmar. Interosseous.

The two rows of carpal bones are connected together by an *anterior ligament*, which is formed by some irregularly radiating fibres, and is attached, above, to the three first bones of the upper, and below, to the palmar surface of the second row. The *posterior*, loose and strong, is more like a separate ligament, but the greater number of its fibres are transverse; it is fixed, above, to the posterior surface of the three first bones of the upper, and descends to the second row, into which it is inserted. The *lateral* ligaments consist of an external, the strongest, attached between the trapezium and the scaphoid bone, and an internal between the cuneiform and unciform bones. Divide the external and internal lateral, as well as the posterior ligament between the two, and the first row of bones is seen to form an arch into which the convexity of the second is received; of the bones of the second row, the os magnum and unciforme are the most prominent, and give rise to a condyloid projection which is received into the arch of the three bones of the first row; external to the os magnum is a flat surface formed by the trapezium and trapezoides, much below the level of the other, for articulation with the scaphoid bone. The *synovial membrane* for this articulation lines the surfaces of the bones, sends two prolongations upwards between the three bones of the first row, the pisiform having a separate one, and three prolongations downwards between the four bones of the second row: the processes downwards extend horizontally between these and the metacarpal bones of the four fingers. The thumb has a separate synovial membrane.

One row to the other. Anterior Ligament. Posterior. Lateral. Articular Surfaces. Synovial Membrane.

The *metacarpal bones* are united at their posterior or carpal extremities by dorsal, palmar, and interosseous ligaments, and at their anterior, by a transverse ligament. The *dorsal and palmar* ligaments are short fasciculi of fibres, which pass from the head of one bone to that next it: they are three in number, both above and beneath, to connect the metacarpal bones of the four fingers; the palmar ligaments are the strongest. The *interosseous ligaments* are short, strong fibrous processes, situated between the four inner bones, and attached to the rough portions

Metacarpal Bones to each other. Dorsal and Palmar Ligaments. Interosseous.

below the articular surfaces: they are very strong. The surfaces of the metacarpal bones in contact are covered with cartilage, and are invested by prolongations from the synovial membrane of the carpo-metacarpal articulation. The *transverse metacarpal ligament* connects together the digital extremities of the four inner metacarpal bones; it consists of small ligamentous bundles, which pass from one metacarpo-phalangeal articulation to the next: it has been dissected with the hand.

Transverse.

Metacarpal to the Carpal Bones. Dorsal Bands.

The metacarpal bones of the four fingers are articulated to the last row of carpal bones, by dorsal and palmar ligaments; and the first has a separate capsule and synovial membrane. The *dorsal ligaments*, stronger than the palmar, are longitudinal bands which extend between the bones. The metacarpal bone of the index finger has one band from the os trapezium, and another from the os trapezoides; that of the middle finger, one from the os magnum and a second from the os trapezoides; that of the ring, one from the os magnum and another from the os unciforme; and the head of the metacarpal bone of the little finger has but one from the os unciforme. The *palmar ligaments* are weaker than the dorsal; the index finger has none, since the tendon of the flexor radialis supplies its place; the metacarpal bone of the middle finger has one from the os magnum, and from the unciform bone, besides a lateral ligament connecting it to the os magnum; that of the ring finger has one from the unciform bone, and the place of that to the little finger is supplied by the ligament from the pisiform bone. The *first metacarpal bone*, or that of the thumb, has a separate *orbicular* ligament surrounding the articular surfaces of it and the trapezium; it is thicker behind than before, and is strengthened by the tendon of the extensor ossis metacarpi pollicis; the radial artery is in contact with this articulation, as it enters the palm of the hand. A separate *synovial membrane* is found between the bones. Open the articulation between the metacarpus and carpus, to see the line formed by the *articulating surfaces* of the bones. The fifth and fourth metacarpal bones are nearly straight, and articulate with the unciform bone; the third projects farther back in a direction upwards and outwards, and articulates with the surface of the os magnum inclined in the same direction; the second reaches to the same height as the tip of the third, and therefore its line of articulation across the hand is posterior to the others; it presents a V-shaped surface, into the hollow of which projects the prominence of the os trapezoides, while the angular projections reach the os trapezium externally, and the os magnum internally. The articulation of the thumb is oval transversely, and in front of that of the index finger. The *synovial membrane* has been already seen; by separating the heads of the metacarpal bones, their interosseous ligaments may be observed.

Palmar.

First Metacarpal. Capsular.

Synovial.

Articular Surfaces.

Synovial Membrane.

Separate the carpal bones, to examine the attachments of the interosseous ligaments before spoken of as existing between them. Those in the first row of carpal bones, two in number, are very thin, and one is situated between the os semilunare and scaphoides, and one between the os semilunare and cuneiforme; they are seen between the upper parts of the bones, and extend up to the surfaces entering into the wrist-joint: those between the bones of the second row are much stronger; one is placed on each side of the os magnum, uniting this bone to the trapezoides on the one hand, and to the unciform on the other; the ligament between the os magnum and unciforme is the strongest. Interosseous Ligaments of the Carpal Bones.

In the articulations between the metacarpal bones and the phalanges, the head of the metacarpal bone is convex, rounded, the articular surface being wider on the palmar than dorsal surface, and is received into a shallow oval cavity of the phalanx; the bones are provided with an internal and external lateral, and an inferior ligament. The extensor tendon sends down an expansion on each side; but the chief means of maintaining these articular surfaces in contact are the tendons which are placed above and below them. One of them may be opened to see the articular surfaces, and the ligaments can be dissected on another. The *lateral ligaments* are two, an internal and external, and to see them the tendinous expansion on each side of the articulation must be removed; they are attached behind to the tubercles on the sides of the metacarpal bones; the fibres pass downwards and forwards, diverging, to be inserted into the sides of the phalanges, and of the inferior ligament: these ligaments may be considered only a part of a general capsule thickened at the sides and below. The *inferior ligament* is a longitudinal thick band, almost cartilaginous, which is fixed firmly to the phalanx in front of its articular surface, but loosely to the metacarpal bone behind its head: to its sides are attached the lateral ligaments. Its palmar surface is hollowed by the flexor tendon, and is united to the transverse metacarpal ligament; its articular, is concave to receive the head of the bone during extension of the finger, and it is stronger near the phalanx than near the metacarpal bone. A *synovial membrane* invests the articular surfaces, and projects, above, between the bones, the ligamentous fibres being very thin and scattered at this part. The tendon of the extensor serves as a superior ligament. In the articulation between the metacarpal bone of the thumb and its phalanx, two sesamoid bones are found connected to the cartilaginous inferior ligament; and to these are attached the greater number of the fibres of the lateral ligaments. Metacarpal to the Phalanges. Lateral Ligament. Inferior. Synovial Membrane. In the Thumb.

In *the articulation of the phalanges* the distal extremity of the one phalanx is marked by a pulley-like depression, as in the lower end of the humerus, which is prolonged farthest on the Union of the Phalanges.

palmar aspect of the bone, is received into a transversely hollowed fossa of the other phalanx, separated into two portions by a crest that fits into the central excavation on the opposite articular surface. Open one of the articulations to see this. The *lateral ligaments* are attached to the sides of the distal extremity of the phalanx, and are inserted below, as in the metacarpo-phalangeal articulations, to an inferior ligament. The *inferior ligament* has the same mode of attachment to the extremities of the bones, but is not so strong or marked, as in the metacarpo-phalangeal articulations, and there are no transverse ligaments united to it. A *synovial membrane* is present between the bones, and has the same arrangement as in the metacarpo-phalangeal articulation.

Lateral Ligaments.

Inferior.

Synovial Membrane.

The articulation of the ungual with the second phalanx is the same as in the preceding, both in the number and disposition of its ligaments; but they are much less strongly marked, and the lateral ligaments are nearly straight. In the thumb there is but one phalangeal articulation, since there are but two phalanges.

TABLE OF THE ARTERIES OF THE UPPER EXTREMITY AND THORAX.

- Arteries arising from the heart are
  - Aorta from the left ventricle
    - Right coronary
    - left coronary
    - brachio-cephalic
      - Right subclavian * *continued in the arm by*
        - 1. Axillary
          - Superior thoracic
          - acromial thoracic — Muscular; inferior acromial.
          - long thoracic
          - alar thoracic
          - subscapular — Dorsal artery — Infra-scapular descending.; muscular thoracic.
          - anterior circumflex
          - posterior circumflex.
        - 2. brachial
          - To coraco-brachialis
          - superior profunda — Muscular to triceps; to the anconeus; anastomotic.
          - nutritious
          - inferior profunda — Muscular to triceps; anastomotic
          - anastomotic — To brachialis anticus; anastomotic.
          - muscular.
        - 3. radial
          - Recurrent
          - muscular
          - superficialis volæ
          - posterior carpal
          - anterior carpal
          - metacarpal
          - dorsal of the thumb
          - dorsal of the index
          - princeps pollicis
          - radialis indicis
          - deep arch — Recurrent; perforating; interosseous; communicating.
        - 4. ulnar
          - Auterior recurrent
          - posterior recurrent
          - interosseous — Anterior — Nutritious; muscular; anastomotic. ; posterior — Recurrent; muscular; anastomotic.
          - muscular
          - dorsal of the hand, or metacarpal — Dorsal carpal; metacarpal or interosseous.
          - anterior carpal
          - superficial arch — Communicating; four digital branches; cutaneous; muscular.
      - right carotid — Seen in the neck.
    - left carotid; left subclavian — Seen in the neck.
    - bronchial — Superior; inferior.
    - œsophageal
    - intercostal or vertebro-costal
      - Anterior or intercostal — Muscular; cutaneous; anastomotic.
      - posterior
        - Spinal — To the bodies of the vertebræ; to the spinal cord.
        - internal dorsal — Muscular; cutaneous in the eight upper.
        - external dorsal — Muscular; cutaneous in the four lower.
  - Pulmonary artery from the right — Right pulmonary; left pulmonary; ductus arteriosus.

* The branches of this artery will be found in the Table of the Head and Neck.

TABLE OF THE VEINS OF THE UPPER EXTREMITY AND THORAX.

- Veins joining the heart.
  - Superior cava.
    - Brachio-cephalic
      - Internal jugular — Seen in the neck
      - subclavian* *continued in the arm by*
        - 1. Axillary
          - Cephalic
            - Cephalic of the thumb from the dorsal arch
            - cutaneous radial veins
            - median cephalic
            - cutaneous of the arm.
          - basilic
            - Salvatella of the dorsal arch
            - anterior ulnar
            - posterior ulnar
            - median basilic and median vein.
          - superior thoracic
          - acromial thoracic
          - long thoracic
          - alar thoracic
          - subscapular
            - Thoracic branches
            - dorsal branch — Infra-scapular.
          - posterior circumflex
          - anterior circumflex.
        - 2. brachial
          - Superior profunda
          - nutritious
          - inferior profunda
          - anastomotic
          - muscular
          - basilic (*sometimes*).
        - 3. radial
          - Deep arch
            - Recurrent interosseous
            - perforating.
          - radialis indicis
          - magna pollicis
          - dorsal of index finger
          - dorsal of thumb
          - metacarpal
          - carpal
          - superficialis volæ
          - communicating to cutaneous radial
          - muscular
          - recurrent.
        - 4. ulnar
          - Superficial arch
            - Communicating to the deep arch
            - digital.
          - metacarpal
          - carpal
          - communicating to ulnar cutaneous
          - muscular
          - interosseous
            - Anterior — Nutritious muscular.
            - posterior — Recurrent muscular carpal.
          - posterior recurrent
          - anterior recurrent.

* The veins that accompany the branches of the subclavian artery, found in these dissections, are the same as the arteries, and will be seen in the table of veins of the head and neck.

TABLE OF THE VEINS OF THE THORAX—*continued.*

- Veins joining the heart.
  - Superior cava
    - azygos
      - Branch from a lumbar vein, or the inferior cava
      - eight inferior intercostal or vertebro-costal of the right side; which have
        - Anterior or intercostal
          - Muscular cutaneous anastomotic branches with internal mammary.
        - posterior
          - Dorsal branch
            - Muscular cutaneous communicating with dorsi-spinal.
          - intra-spinal
            - Veins from the cord
            - anterior longitudinal plexus
            - transverse veins of the vertebræ
            - posterior spinal plexus
            - posterior transverse branches to dorsi-spinal.
      - small azygos
        - Branch to renal vein (*occasionally*)
        - four or five inferior intercostal or vertebro-costal of left side.
      - left superior intercostal
        - Three or four left upper vertebro-costal
        - left bronchial.
      - right superior intercostal (*sometimes*)
      - right bronchial
      - œsophageal
      - mediastinal.
    - right internal mammary
    - right inferior thyroid
      - *Occasionally.*
    - right superior phrenic
    - thymic
    - mediastinal
    - pericardiac.
  - Inferior cava
  - pulmonary - Two for each side.
  - coronary - Single.

SPINAL NERVES OF THE THORAX AND UPPER EXTREMITY.

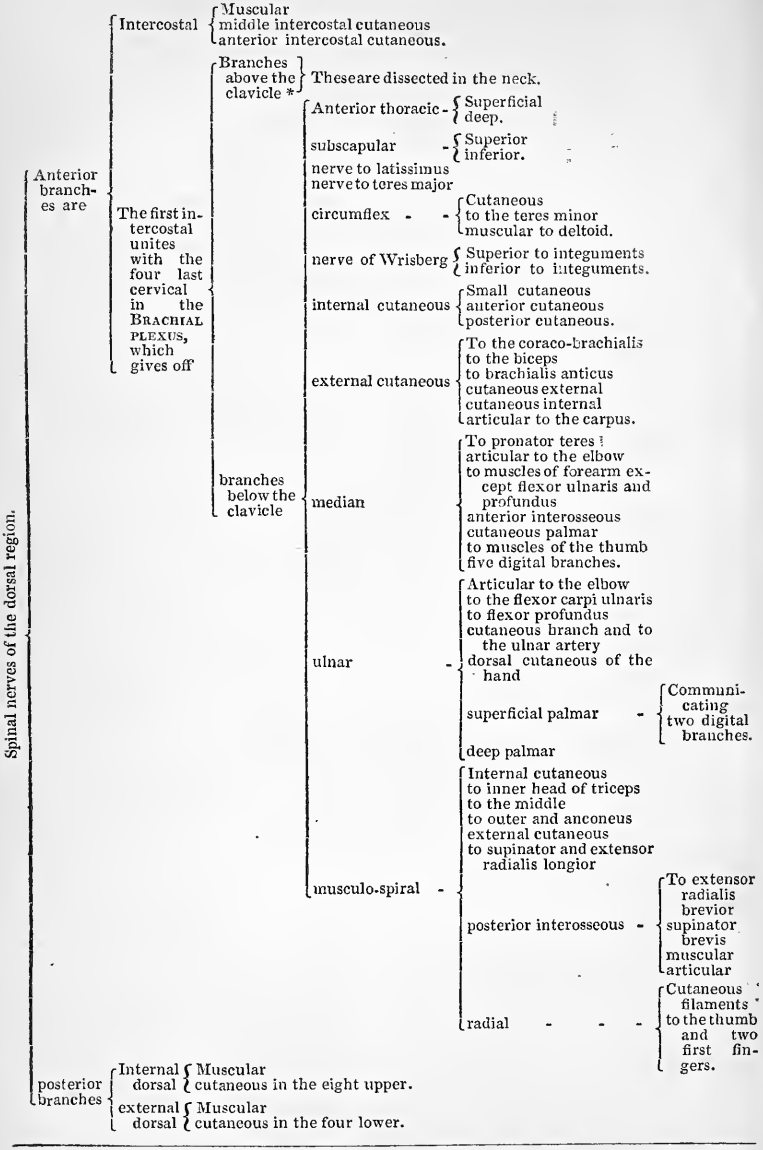
Spinal nerves of the dorsal region.
Anterior branches are
Intercostal
Muscular
middle intercostal cutaneous
anterior intercostal cutaneous.
The first intercostal unites with the four last cervical in the BRACHIAL PLEXUS, which gives off
Branches above the clavicle *
These are dissected in the neck.
branches below the clavicle
Anterior thoracic - Superficial deep.
subscapular - Superior inferior.
nerve to latissimus
nerve to teres major
circumflex - - Cutaneous to the teres minor muscular to deltoid.
nerve of Wrisberg Superior to integuments inferior to integuments.
internal cutaneous Small cutaneous anterior cutaneous posterior cutaneous.
external cutaneous To the coraco-brachialis to the biceps to brachialis anticus cutaneous external cutaneous internal articular to the carpus.
median To pronator teres articular to the elbow to muscles of forearm except flexor ulnaris and profundus anterior interosseous cutaneous palmar to muscles of the thumb five digital branches.
ulnar - Articular to the elbow to the flexor carpi ulnaris to flexor profundus cutaneous branch and to the ulnar artery dorsal cutaneous of the hand
superficial palmar - Communicating two digital branches.
deep palmar
musculo-spiral - Internal cutaneous to inner head of triceps to the middle to outer and anconeus external cutaneous to supinator and extensor radialis longior
posterior interosseous - To extensor radialis brevior supinator brevis muscular articular
radial - - - Cutaneous filaments to the thumb and two first fingers.
posterior branches
Internal dorsal Muscular cutaneous in the eight upper.
external dorsal Muscular cutaneous in the four lower.
* Branch given off above the clavicle and distributed below in the arm - Supra-scapular Supra-spinal infra-spinal.

TABLE OF THE MUSCLES MOVING THE THORAX AND UPPER EXTREMITY.*

THE CAPACITY OF THE THORAX IS

enlarged by the

Intercostales externi (*when the upper ribs are fixed*)
Levatores costarum
Serrati postici superiores
Scaleni antici et postici, and descent of the diaphragm.

assisted by the

Pectorales
Serrati majores
Latissimi
Subclavii (*when the arms are fixed*).

and by the

Cervicales ascendentes
Sterno-mastoidei (*when the head and neck are fixed*).

diminished by the

Intercostales interni (*when the lower ribs are fixed*)
Serrati postici inferiores
Triangulares sterni, and ascent of the diaphragm.

assisted by the

Recti, Obliqui, Transversales } abdominis.

and by the

Quadrati lumborum
Sacro-lumbales
Longissimi dorsi.

THE SCAPULA IS MOVED

upwards by

Trapezius
Levator scapulæ
Rhomboidei.

downwards by

Lower part of trapezius
Latissimus dorsi
Pectoralis minor.

forwards by

Pectoralis minor
Serratus magnus.

backwards by

Part of trapezius
Rhomboidei
Latissimus dorsi.

THE HUMERUS IS MOVED

forwards by

Part of deltoid
Part of pectoralis major.

assisted, in some circumstances, by

Biceps
Coraco-brachialis.

backwards by

Part of deltoid
Teres major
Teres minor
Long head of triceps
Latissimus dorsi.

inwards by

Part of pectoralis major
Latissimus dorsi.

rotated inwards by

Subscapularis.

assisted, occasionally, by

Pectoralis major
Latissimus and teres major.

outwards by

Supra-spinatus
Infra-spinatus
Teres minor.

THE FOREARM IS MOVED

forwards by

Biceps
Brachialis anticus
Pronator teres.

assisted by

Flexor carpi radialis
Flexor sublimis
Flexor ulnaris
Supinator longus.

backwards by

Triceps
Anconeus

rotated inwards by

Pronator teres
Flexor carpi radialis
Palmaris longus
Flexor sublimis
Pronator quadratus.

outwards by

Biceps
Supinator brevis
Extensor secundi internodii.

THE CARPUS IS MOVED

forwards by

Flexor carpi radialis
Palmaris longus
Flexor sublimis
Flexor carpi ulnaris
Flexor profundus
Flexor longus pollicis.

backwards by

Extensor carpi radialis longior
Extensor carpi radialis brevior
Extensor secundi internodii
Indicator
Extensor communis digitorum
Extensor proprius pollicis.

outwards by

Flexor carpi radialis
Extensor carpi radialis longior
Extensor carpi radialis brevior
Extensor ossis metacarpi
Extensor primi internodii.

inwards by

Flexor sublimis
Flexor carpi ulnaris
Flexor profundus
Extensor communis digitorum
Extensor minimi digiti
Extensor carpi ulnaris.

* The portion of this table beginning "The scapula is moved," is copied from Quain's Elements of Anatomy.

TABLE OF THE MUSCLES, &c. *continued.*

THE THUMB IS MOVED

inwards and forwards across the palm by	*outwards and backwards by*	*upwards and forwards away from the other fingers by*	*backwards and inwards to the other fingers by*
Opponens pollicis Flexor brevis Flexor longus.	Extensor ossis metacarpi pollicis Extensor primi internodii Extensor secundi internodii pollicis.	Abductor, assisted by part of the Flexor brevis.	Adductor Extensor primi internodii Extensor secundi internodii.

THE FINGERS ARE MOVED

forwards or flexed by	*backwards or extended by*	*outwards to radial border by*	*inwards by*
Flexor sublimis Flexor profundus Lumbricales Inter-ossei Flexor brevis digiti minimi Abductor digiti minimi.	Extensor communis Extensor minimi digiti Indicator.	Abductor indicis Adductor digiti minimi Inter-ossei.	Abductor digiti minimi Inter-ossei.

PNEUMO-GASTRIC AND PHRENIC NERVES IN THE THORAX.

- **Pneumo-gastric portion of the eighth nerve gives off**
  - Recurrent, particularly of the left side
  - cardiac branches
  - œsophageal
  - tracheal
  - anterior pulmonary and plexus
  - posterior pulmonary and plexus
  - œsophageal and plexus gulæ.
- **Phrenic**
  - Is oftentimes joined by a branch from the brachial plexus in the upper part of the thorax
  - near the diaphragm it divides into its final branches of distribution.

SYMPATHETIC NERVE IN THE THORAX.

- **Prevertebral or cardiac plexus consists of**
  - Superficial portion, or cardiac ganglion *, which gives off
    - Filaments to the great vessels
    - filaments to the anterior coronary plexus.
  - deep portion, or great cardiac plexus †, which gives off
    - Filaments to the heart
    - to anterior coronary plexus
    - to posterior coronary plexus
    - to the pulmonary plexus.
- **Gangliated cord by the side of the spine gives off**
  - External branches
    - One or two to each spinal or intercostal nerve
  - internal branches
    - Aortic filaments as well as to the posterior pulmonary plexus, from the six upper ganglia
    - the great splanchnic nerve, by filaments from the sixth to the tenth
    - the small splanchnic, by those from the tenth to the twelfth.

---

* The cardiac ganglion receives from the neck
- Left superior cardiac nerve
- part of right superior (*sometimes*) cardiac of the left pneumo-gastric.

† Deep or great cardiac plexus receives from the neck
- Superior
- middle
- inferior cardiac nerves — Of the right side.
- cardiac of right pneumo-gastric
- middle and
- inferior cardiac nerves — Of the left side.

DISSECTION OF THE PERINÆUM.

Directions, and Position of the Subject.

THE dissection of the perinæum should be made early, since the distinctness of the parts is quickly destroyed after death, and its examination will then be very unsatisfactory. This part is usually assigned, in the distribution of the body, to the dissectors of the abdomen; and it will be advisable for them to commence with this region.* The subject being placed on the back, draw it to the lower part of the table until the buttocks hang slightly over the edge, then fasten up the legs by flexing them on the trunk and binding them to the hands, as in the operation for lithotomy; or leave the upper extremities free for dissection, and raise the legs as before, after they are crossed at the ankles and tied together by a piece of cord, which is to be carried to the opposite end of the table, and secured beneath it; raise the scrotum, and place a small quantity of cotton wool or tow in the rectum, but not sufficient to distend it, and so to fill up the greater part of the outlet of the pelvis. It will be necessary to place a block beneath the pelvis, to raise the perinæum to a height convenient for dissection.

Boundaries and Markings of the Surface.

The region of the perinæum corresponds to the inferior aperture or the outlet of the pelvis, and in it, both in the male and female, are seen the parts that occupy this space. Its limits between the scrotum in front, and the thighs and nates behind, can be judged of, at present, by reference to a prepared pelvis on which the ligaments remain entire; or, with a knowledge of these, the finger will be able to feel its firm and unyielding boundaries. Thus on each side of the anus is the prominent tuberosity of the ischium, and if the finger be passed forwards from this it will detect the rami of this bone and the pubes, which bound, laterally, the front of the space; and a line drawn backwards from the projection to the coccyx marks the lateral boundary of the posterior half, this being formed beneath the skin by the great sciatic ligament, and the margin of the gluteus maximus muscle: in front of the space is the arch of the pubes and sub-pubic ligament, and behind, the tip of the coccyx. With an articulated pelvis it will be seen that these structures enclose a lozenge-shaped space, the antero-posterior measurement being about four inches, and the transverse, from the tu-

* The important operation of the introduction of the catheter should be practised in this stage before the legs are tied up; and for a full and perfect description of the different methods of introducing it, as well as the obstacles to be avoided in its execution, see Morton, *On the Surgical Anatomy of the Perinæum*, p. 61.

berosity of one ischium to the other, from two inches and a half to three inches: this last line divides the space into two triangular portions, the anterior containing the urethral aperture, the muscles connected to it, also the crura of the penis, with their muscles; and the posterior, the anus with its muscles. The depth from the surface to the neck of the bladder is about three inches opposite the margin of the anus; but this varies much. The surface is of a dark colour and covered with hairs which are continuous with those on the scrotum. Along the middle, in the male, is a prominent line, the *raphé*, which divides it into two equal parts; but it is interrupted, behind, by the aperture of the anus, which is situated in the centre of the perinæal region, and posterior to a line extended from the tuberosity of the ischium of one side to that of the other. In front of the anus, the surface is slightly convex, from the position of the bulb of the urethra beneath; but between it and the tuberosities it is rather concave, and around the margin of the opening are numerous converging folds, which are more or less destroyed by the insertion of cotton wool into the rectum: the hæmorrhoidal veins, too, are very generally enlarged and project around the anus, giving rise to hæmorrhoids. In the female, the outlet of the pelvis, larger than that of the male, has about four inches to the transverse measurement, or nearly the same as the antero-posterior; but the perinæum is not so deep as in the male; and on the surface are the apertures of the anus and vulva, the former being situated farther back than in the other sex, and the latter reaches in front to the symphysis of the pubis, and is bounded on each side by the labia majora. Within the vulva, at the lower part, is the aperture of the vagina, partially closed in the child by the hymen, and above this, the aperture of the urethra: in the upper angle is the clitoris, and extending downwards from it, on both sides, the labia minora or nymphæ, which are folds of mucous membrane situated within the majora.

Dissection. Make an incision through the skin along the middle line, from the scrotum to the margin of the anus, carry it round the sides of this aperture, and then continue it backwards to about one inch beyond the tip of the coccyx; make a transverse incision at each extremity of the longitudinal one, and let it be sufficient to allow the integuments to be turned back from the space on to the thighs: raise now the two flaps, beginning either before or behind, and the subcutaneous cellular membrane is exposed: in separating the skin from the circumference of the anus, care must be taken in order to avoid cutting away the superficial sphincter muscle which encircles the aperture. The perinæum is divided longitudinally into two similar parts, and as the dissector may find some difficulty in exposing both the anatomical and surgical anatomy on the same side, it will be advisable to appropriate one half, say the left, for the more general examin-

ation without much reference to the vessels and nerves; but on the opposite, the distribution of these is to be followed with care. The subcutaneous cellular membrane, now exposed, is thin and moveable in front, but is thick and granular behind, and around the margin of the anus; it has special relations in front of a line extended from the tuberosity of the ischium to the anus, and this is therefore to remain, now, untouched; but, behind this, it is to be removed freely, to expose a larger space—the ischio-rectal fossa—between the os innominatum and the anus. The presence and extent of this fossa may be ascertained before clearing out the cellular membrane, by cutting through the more condensed part of the superficial fascia that covers it in, and by inserting the finger into it, and freely moving it about. To clean out the cellular membrane, begin on the side of the anus at the margin of the sphincter muscle, reflect outwards the superficial portion, continue it forwards to the line before said, backwards to the margin of the gluteus maximus, and follow the sphincter ani to the coccyx: the fat that fills the fossa is granular, something like that in the orbit, and very easily taken away: descending, internally, to the anus, is the levator ani muscle, which is sometimes very thin, and may be removed; and on the outer boundary of the space are the pudic vessels and nerve, but they are covered by fascia, and a small aperture is to be made in it to show their position. Expose now the margin of the gluteus maximus muscle which limits, posteriorly, this space; and the superficial fascia on the surface of the thigh of the left side, external to the ramus of the ischium, is to be raised from the strong fascia lata beneath, by means of an incision along the line of attachment of the reflected skin, and to be turned inwards to the rami of the ischium and pubes to which it is connected. On the opposite side take away the fat and superficial fascia from the ischio-rectal fossa, to see the nerves and vessels crossing it; the fasciæ on the levator and gluteus are not to be removed, nor is the superficial fascia on the inner part of the thigh to be reflected. The nerves and vessels in the space are branches of the pudic which lie against the outer wall, and also of the sciatic: in its posterior angle are two or three nerves and arteries turning round the inferior border of the gluteus maximus, some superficial to the fascia that covers it, and some beneath it; these are cutaneous branches of the small sciatic nerve and artery: in front of this, and near the centre of the space, the inferior hæmorrhoidal nerve, which gives branches inwards to the sphincter, forwards to the integuments of the front of the perinæum, and is accompanied by two or three branches of the same name from the pudic artery; and entering the front of the fossa, near the line of reflection downwards of the superficial fascia, is a cutaneous perinæal branch of the pudic nerve, which sends a branch

inwards to the middle line to join with the inferior hæmorrhoidal, and then disappears by perforating the fascia: some small arteries to the levator ani muscle accompany it.

Ischio-rectal Fossa.

The *ischio-rectal fossa**, named from its situation between the rectum and the ischial portion of the os innominatum, is an irregularly-shaped space, larger behind than before, and contains much granular fat; its breadth is about one inch, and its depth about two. It is bounded internally by the sphincter, and levator ani which is descending from the wall of the pelvis to be inserted into the rectum and central line of the perinæum,—a thin fascia, prolonged from the margin of the deep triangular ligament, covers the surface of this muscle; externally is the os ischii with the obturator internus muscle, and this again is covered by the obturator fascia: the pudic vessels lie on the wall, contained in a sheath of fascia, and are placed one inch and a quarter above the tuberosity of the ischium, the nerve being below the artery; but they approach nearer to the margin of the ramus of this bone as they reach to the front of the space, and the base of the triangular ligament: in front it is limited by the triangular ligament and superficial fascia, which is dipping down to join it; and behind is the gluteus maximus, together with the great sacro-sciatic ligament which is concealed by the muscle. Some branches of the small sciatic nerve and artery appear in its posterior angle; and crossing it about its centre are the inferior hæmorrhoidal nerve and arteries: in the front is a superficial perinæal nerve of the pudic, which gives a branch to the middle line, and then leaves the fossa by perforating the superficial fascia. Into this space the operator makes his incision in the lateral operation of lithotomy; and the loose nature of the cellular membrane will readily suggest the possibility of abscesses extending in it to a great depth.

Dissection.

Examine the anatomy and attachments of the superficial fascia in front of the left ischio-rectal fossa; and for this purpose it will be necessary to remove the cellular tissue superficial to a more condensed portion which is connected to the triangular ligament and os innominatum, and so determines the direction of fluids beneath it; and if an aperture be made through this, and air blown beneath, it will be found to pass only forwards, and to distend the scrotum. At a certain point in the scrotum the adipose substance disappears, and its peculiar looking tissue alone remains. Divide this condensed layer of the fascia along the middle line, and reflect it outwards to the line of attachment to the bone, and backwards to its union with the triangular ligament. The superficial fascia of the opposite half is not to be interfered with.

* This is so named by M. Velpeau, in the second volume of the *Traité complet d'Anatomie Chirurgicale*, p. 213.

The *superficial fascia* * of the perinæum resembles that of the inguinal region, in having a subcutaneous portion, in which is deposited the fat, and a deep compact layer that is of limited extent, and is united inseparably, by its borders, to the rami of the bones beneath. The subcutaneous portion is continuous with that of the rest of the body, and therefore reaches backwards around the anus, in which part it is loaded with much fat, on each side to the thigh, and in front to the scrotum; but in this last direction the fat soon disappears, and the characteristic reddish-looking cellular layer takes its place; so that, should fluid, as the urine, have escaped from beneath the deep or condensed layer, it may permeate this structure in any direction. Its depth, and the quantity of fat, will vary in the different states of obesity of subjects. The deep or condensed layer, to which reference is more particularly made when the superficial fascia is spoken of, is thin, but of a more uniform degree of thickness, and occupies only the part of the perinæal space in front of the ischio-rectal fossa, across which it is stretched; and it covers in the different parts situate in this portion of the space. The air, when blown beneath it, has been seen to pass only in the direction forwards; and if the connections of the fascia be examined on the side where it is reflected back, it will be found to be fixed, externally, to the borders of the rami of the ischium and pubes, to the outer side of the attachment of the crus penis and its erector, extending backwards as low as the insertion of these parts to the inner side of the tuberosity of the ischium, furnishing them with a sheath, and joining at this part the obturator fascia that lies on the outer wall of the ischio-rectal fossa: posteriorly, it ends by dipping downwards to be attached to the lower part or base of the triangular ligament, and this line of termination is oblique upwards and inwards from the tuberosity of the ischium to the central point of the perinæum: in front it is unattached, and is continued forwards to the scrotum, assists with the other layer to form the dartos, and then ascends to each inguinal region, forming an enveloping tube around the cord, and being continuous with the cellular structure surrounding the penis; so that a pouch is formed, open only in front, and should urine be effused beneath this layer, it will be directed forwards as long as this remains entire, since the posterior and lateral attachments prevent it from coming backwards, and it will then be continued onwards, through the scrotum, to the inguinal region and front of the abdomen, as well as to the penis.† A cellular band dips down, on each side, between the urethra and crus penis, from the under

Superficial Fascia.

* "L'aponévrose inférieure," Blandin. *Traité d'Anatomie Topographique*, p. 369.

† The attachments of this fascia, the progress of effused urine and its effects, were fully described by M. Colles, in the first part of a *Treatise on Surgical Anatomy*, 1811. p. 174.

surface of the fascia to join the triangular ligament, and the space beneath is therefore divided, behind, into three compartments, but these disappear in front. The superficial fascia is perforated by cutaneous vessels and nerves, and covers in the urethro-genital portion of the perinæal space, with the muscles, vessels, and nerves beneath, and it gives a covering to the penis and urethra. In the female it is of less extent, but is continued forwards, giving rise to the labia majora, and then upwards into the inguinal region.

Dissection. Divide the superficial fascia of the opposite side in front of the ischio-rectal fossa, and follow forwards the branch of the pudic nerve, that was seen perforating its posterior part; beneath it is also another superficial perinæal branch of the pudic, accompanied by the artery of the same name, and both extend forwards to the front of the scrotum. The nerve gives many branches inwards to the muscles of this part, and accompanying these is the transverse artery: the superficial perinæal artery chiefly supplies the muscles with branches. External to the rami of the ischium and pubes, and in the fascia of the inner and upper part of the thigh, is the inferior pudendal nerve, which perforates the fascia lata rather in front of the tuberosity of the ischium and external to it, and then runs inwards to the back of the scrotum: this nerve must have been seen in removing the superficial fascia from the fascia lata of the opposite side, and one or two other small branches from the small sciatic frequently perforate the fascia near the lower border of the gluteus maximus. After these nerves are found and followed, take away the cellular membrane which obscures them, and the anatomy of the cutaneous nerves and vessels may be next seen on the right side.

Cutaneous Nerves. From the small Sciatic. The *posterior* and *internal cutaneous branches* of the small sciatic nerve are seen turning round the lower free border of the gluteus maximus; one very small, lies close to the coccyx in the posterior angle of the ischio-rectal fossa, and one or two, larger, are external to this; they are distributed to the integuments over the inner and lower part of the gluteus, and are accompanied by small branches of the sciatic artery. The largest branch from the nerve to the perinæal space is the inferior pudendal, to be afterwards seen.

Inferior Hæmorrhoidal. The *inferior hæmorrhoidal nerve*, the next in order from behind forwards, either a separate nerve from the sacral plexus or a branch of the pudic, perforates the obturator fascia, crosses the centre of the ischio-rectal fossa, with branches of arteries of the same name, to reach the margin of the anus, and it divides into filaments to supply the middle and posterior parts of the sphincter muscle, as well as the integuments around the anus. This nerve gives cutaneous branches, which run forwards in the interval between the margin of the anus and tuberosity of the ischium, some being directed inwards to the middle line, to the

integument and superficial fascia of the perinæal space in front of the anus, and join with a branch from the most posterior of the two superficial perinæal nerves of the internal pudic; and others pass outwards over the tuberosity of the ischium to join the inferior pudendal on the thigh.

Superficial Perinæal.

The remaining branches of nerves are from the trunk of the internal pudic, which lies along the outer wall of the space, but cannot now be seen. There are two superficial perinæal branches; the most *posterior* (external perinæal, Cruveilhier) perforates, about half an inch behind the tuberosity of the ischium, the obturator fascia binding down the trunk of the nerve: it appears, for a short distance, in the front of the ischio-rectal fossa, passes through the superficial fascia, where it is turning down to join the triangular ligament, and then, placed beneath it, runs forwards along the anterior part of the perinæal space, internal to the rami of the ischium and pubes, in the interval between the urethra in the middle line, and the crus penis externally, with the other superficial perinæal branch of the pudic nerve, and the artery of the same name; and at the back of the scrotum it divides into many branches which extend to the front, and join, externally, with the inferior pudendal, and internally, with the other superficial perinæal nerve. Before this nerve leaves the ischio-rectal fossa, by perforating the superficial fascia, it gives a branch inwards to the integuments in front of the anus, and this joins with the one sent forwards from the inferior hæmorrhoidal, and it also gives filaments to the front of the sphincter and levator ani muscles; when it is covered by the fascia, it joins, by means of a large branch, with the other perinæal nerve. The *anterior branch* appears rather further forwards than the preceding, and perforates the obturator fascia, either close to the base of the triangular ligament, or it may come through its lower part; it then passes over or under the transversalis muscle with the perinæal artery, runs forwards with it beneath the superficial fascia, and in the same interval as the other nerve, internal to which it lies, and from which it receives a large branch of communication, to be distributed also to the central part of the scrotum by very long and numerous filaments, which extend to its front and join with those of the other superficial perinæal, and some may be followed even along the under surface of the penis to its extremity. As soon as it appears in the perinæal space it gives inwards numerous muscular branches to supply the front of the levator ani, the ejaculator urinæ, and the transversalis muscle: the nerve that supplies these muscles appears almost a separate branch, since it leaves the trunk as soon as this passes through the obturator fascia, and runs inwards under the transversalis muscle. At this same point other muscular branches are given off, but these will be afterwards examined.

Posterior.

Anterior.

Inferior Pudendal.

The *long inferior pudendal nerve* (Soemmering), a branch of the small sciatic, turns round to the perinæum and scrotum, from beneath the lower border of the gluteus maximus, and appears on the inner and upper surface of the thigh, by passing through the fascia lata, about one inch in front of the tuberosity of the ischium, and nearly the same from the margin of the ramus of this bone; it runs upwards and inwards to the middle line, perforates the superficial fascia, joins with the posterior of the two superficial perinæal nerves, and its filaments, which are numerous, extend forwards, supplying the outer and anterior part of the scrotum and integuments of the cord, joining, on this part, with cutaneous branches of the ilio-inguinal, and some may be followed to the root of the penis. This branch in the female, and also the anterior of the superficial perinæal, are distributed to the labia majora.

Other small branches of the sciatic come from beneath the border of the gluteus, and perforate the fascia to end in the integuments of the thigh, and front of the perinæum or back of the scrotum.

Vessels. Branches of the Sciatic.

In the posterior part of the fossa, with the nerves from the sciatic, are some small branches from the sciatic artery: they appear on the inner surface and lower border of the gluteus, some being distributed to the under surface of the muscle, and some become cutaneous with the nerves.

Inferior Hæmorrhoidal Artery.

The *inferior hæmorrhoidal arteries*, branches of the pudic, two or more in number, are given off from the trunk whilst it is internal to the tuberosity of the ischium; they pass inwards with the nerve, divide into branches, and supply the levator ani, the sphincter, and the skin. Some cutaneous branches pass over the front of the fossa, joining with the superficial perinæal, and others run outwards over the tuberosity of the ischium to the same destination as the nerves. It anastomoses with that of the opposite side, and on the rectum with the middle hæmorrhoidal from the internal iliac.

Superficial Perinæal Artery.

The *superficial perinæal artery* has the same course and distribution as the nerve of the same name. It arises from the pudic opposite the base of the triangular ligament, which it generally perforates near the lower border, turns forwards with the nerve over or under the transversalis perinæi muscle, runs in the interval between the erector penis which is attached to the ramus of the ischium externally, and the ejaculator urinæ which covers the urethra in the middle line, and at the back of the scrotum divides into many branches which become flexous, and are distributed to the integuments and the dartos, and anastomose anteriorly with the branches given to this part from the femoral and spermatic arteries; when it is about to turn forwards, it sends off some deep branches with the filaments of the nerve to the levator ani. As the artery lies in the space before

mentioned, it is beneath the superficial fascia; it has by the side of it the superficial perinæal nerves and a large vein, and gives off branches to supply the ejaculator urinæ, the erector penis, and the transversalis muscles: numerous branches supply the integuments, and others anastomose with those of the opposite side.

Transverse Artery.

The *transverse artery* of the perinæum arises from the pudic at the same point as the superficial, perforates the base of the triangular ligament, and is then directed inwards to the middle line beneath the superficial fascia, and along the transversalis muscle, to the centre of the perinæum; and it ends by dividing into branches, which are distributed to the integuments and muscles, and anastomose with the one of the opposite side, and with the inferior hæmorrhoidal arteries. It often arises from the superficial perinæal.

Veins.

The arteries have branches of veins that correspond to them in their distribution, and open into the pudic vein by the side of the trunk of the artery.

Dissection.

Remove the superficial fascia from the anterior half of the perinæal space, as well as the vessels and nerves now dissected; beneath will be seen a thin aponeurotic layer which closely envelops the muscles, and when this is removed the muscles of this region are, in the middle line, the ejaculator urinæ, covering the urethra; on each side, the erector penis, on the crus penis; and crossing from the tuberosity of the ischium to the small white central point of the perinæum, the transversales perinæi. In cleaning the erector penis of the right side be careful of a separate nerve and artery it receives, and some thin scattered fibres that extend outwards from the ejaculator to the ramus of the pubes on each side, in front of the triangular ligament, are not to be taken away. In the posterior part of the space are the sphincter muscle, and part of the levator ani. The fascia is still to be left entire on the outer wall of the left ischio-rectal fossa; and on the right side take care not to injure the nerves and arteries which have yet to be seen.

Sphincter Ani externus.

Origin.

The *sphincter ani externus* is a flat, thin, orbicular muscle which surrounds the lower part of the rectum, and, like the orbicular muscle of the mouth and eyelids, the fibres are semi-eliptical and leave an aperture in the centre. The deep fibres *arise* posteriorly, by a pointed portion, from the tip of the coccyx, to which it is connected by a fibrous process; and the superficial commence in the subcutaneous cellular membrane in front of the coccyx: the fibres, at first collected into a bundle, pass forwards to the back of the anus, then diverge, encircling this aperture, and come into contact again at its front, the deep being *inserted* by a pointed process into the central point of the perinæum, and the superficial join the *raphé* in the integument. This muscle lies close beneath the skin, and above the superficial fascia which passes beneath its outer border; and it conceals the

Insertion.

Relations.

fibres of the levator ani, which are descending to be attached to the rectum. Its outer border reaches to a variable distance across the ischio-rectal fossa, and to it come the inferior hæmorrhoidal vessels and nerves; and the inner, surrounding the extremity of the rectum, is in contact with the fibres of the internal sphincter, from which it is distinguished by the difference in the colour and texture of this muscle.

Sphincter internus Muscle. The *sphincter ani internus*, vel *orbicularis*, is situated close around the extremity of the intestinal tube, internal to the other sphincter, and is seen in the oval aperture in its centre by removing the mucous membrane: the fibres of this muscle, pale, and of a finer texture than those of the external sphincter, encircle the lower part of the rectum in the form of a muscular band, which lies close beneath the mucous membrane. It is not connected behind, as the other, to the tip of the coccyx, but in front it joins the central point of the perinæum.

Levator Ani Muscle. The *levator ani* can be but partially examined now, since its origin is concealed by the osseous boundaries of the pelvis, but this will be afterwards seen. The muscle descends from the side of the pelvis towards the middle line of the perinæum, and the interval left between it and the bone is the ischio-rectal fossa. Each muscle is convex below and concave above, and by their union below they close the greater part of the outlet of the pelvis, that corresponds to the perinæal space, but they leave an interval above, between their most anterior fibres, for the passage of the urethra from the pelvis, and posterior to this is another aperture for the rectum: in the female, too, a third aperture exists for the vagina. The anterior fibres support, as it were in a sling, the membranous part of the urethra, beneath which those of the opposite sides join, and the posterior unite in the same manner beneath the rectum; the anterior, from the posterior part of the symphysis of the pubes, incline inwards with a direction backwards, and after passing by the side of the membranous part of the urethra, appear beneath the triangular ligament, and are

Insertion. *inserted* into the central point of the perinæum and front of the rectum, uniting with the fibres of the opposite side; the middle are connected to the lateral part of the rectum, and pass beneath the border of the sphincter to join with the muscular parietes of the intestine; and the posterior join, behind the rectum, with those of the opposite side in a central white tendinous line, which reaches from the anus to the coccyx, and some are also inserted into the two last bones of the coccyx: the posterior attachment of the sphincter may be cut across to see the posterior insertion.

Relations. The pelvic surface of the muscle is covered by the vesical fascia, and the perinæal, by a thin fascia prolonged from the base of the triangular ligament: the fat, vessels, and nerves, contained in the ischio-rectal fossa, are also on this surface. The anterior border touches the side of the membranous part of the urethra, and the

posterior is parallel to the coccygeus muscle, and in contact with it.

The *transversalis perinæi* is mostly a small thin muscle, and is often absent; its position is almost transverse across the perinæum, opposite the base of the triangular ligament. It *arises* by a tendon from the inside of the tuberosity of the ischium, above the attachment of the erector penis: the fleshy fibres, that soon commence, run inwards and rather forwards to end in the central point of the perinæum, which is a common point of union of this muscle, the sphincter, and the ejaculator; or very commonly its fibres join with the posterior of the accelerator. It lies beneath the superficial fascia, and is placed on a line with the reflection downwards of the superficial fascia to join the triangular ligament; the superficial perinæal nerves and artery lie on the muscle, or are beneath it, and the transverse perinæal artery runs along it.

Transversalis Perinæi Muscle. Origin. Insertion. Relations.

A second small muscular slip, the *transversalis alter*, is sometimes found anterior to this muscle: it arises from the same part, has the same relations as the preceding, and ends by joining the ejaculator urinæ.

Transversalis alter.

The *erector penis*, the most external of the muscles of the perinæal region, and situated close against the bone, is of a lengthened form, and narrower at each aponeurotic extremity, than in the centre. It *arises* from the inner surface of the tuberosity of the ischium by a fleshy and aponeurotic attachment: the fleshy fibres soon succeed, form the belly of the muscle, and ascend to terminate by an internal and external slip, the latter being the larger, in an aponeurosis, which is *inserted* into the fibrous structure of the crus of the corpus cavernosum of the penis. The superficial fascia gives a sheath to it, and if the muscle be cut across on the left side, it will be seen to lie on the crus penis and the bone.

Erector Penis. Origin. Insertion. Relations.

The *accelerator urinæ muscle*, better dissected by blowing up the urethra or placing a sound in it, is situated in the middle line of the perinæum; it conceals beneath it the urethra, and extends along this canal as far as to where the penis bends in front of the pubes. Each muscle is united along the middle line to the one of the opposite side, by a central median tendon, as far forwards as before said, and behind, to the central point of the perinæum with the transversalis and sphincter muscles. The fibres are directed upwards and outwards, forming a thin muscle, which is curved around the convexity of the urethra, and sends off at different points muscular processes of insertion: the most posterior, given off near the posterior extremity of the muscle, is thin, and passes upwards and outwards over the triangular ligament, to be inserted by aponeurotic fibres into the inner part of the ramus of the pubes; the anterior fasciculus, the longest, and best marked, passes outwards on the body of the penis, to

Accelerator Urinæ Muscle. Origin. Insertion.

be inserted into the fibrous tissue on the outer surface of this organ, in front of the symphysis; and the middle or intervening portion, thin, and of considerable extent, turns round the urethra, passing between it and the body of the penis, and unites by tendinous fibres with the muscle of the opposite side: this last arrangement will be seen by dividing, longitudinally, the muscle, and turning it outwards off the urethra. The accelerator supports and covers the urethra and its bulb, from its point of passing through the triangular ligament to the back of the scrotum; and it is covered by the superficial fascia: the erector penis lies slightly in front of the posterior fibres attached to the ramus. A triangular space is now observed between the muscles examined, and it is formed internally by the accelerator, externally by the erector penis, and the base corresponds to the transversalis, which extends inwards to the middle line: in the area of this space is the triangular ligament of the perinæum, and running from behind forwards in it are the superficial perinæal artery and nerves, whilst the transversalis perinæi artery extends along the base with the muscle. It is into this space that the knife is made to enter in the incisions for the lateral operation of lithotomy, and, in carrying it downwards and outwards into the ischio-rectal fossa, it will be seen that the transversalis muscle and artery will be divided, possibly, the superficial perinæal, and in the fossa, the inferior hæmorrhoidal vessels and nerves; but the number of these last will depend upon the extent backwards of the incision between the margin of the anus and tuberosity of the ischium.

Relations.

Take away the accelerator urinæ from the urethra, also the fibres that extend outwards in front of the triangular ligament; remove also on the left side the erector penis from the ramus of the ischium and from the crus penis: on the right, the erector may be divided in front of the branch of the nerve and artery that it receives, and its anterior portion removed from the crus. The triangular ligament of the urethra, or deep perinæal fascia, is now seen to be stretched across the front of the outlet of the pelvis, and running between the fibres, near the base, or on it, is a nerve that passes inwards to the bulb of the urethra. The urethra reaches the surface by perforating this structure, and it is then applied to the under surface of the cylindrical body of the penis; and on each side, attached to the bone, is the crus or prolongation from the body of the penis, by which this organ is connected to the osseous part of the pelvis; and it is inserted into the inner surface of the ascending ramus of the ischium by a narrow pointed process, which is also connected to the descending ramus of the pubes, and opposite the symphysis, it is directed inwards to unite with the one of the opposite side in the body or corpus cavernosum. Detach the crus penis and fasten it up with hooks; the pudic artery, placed be-

Dissection.

tween it and the bone, divides into a branch for the structure of the penis — the artery to the corpus cavernosum, and one for the upper surface — the dorsal artery of the penis; the pudic has however perforated the triangular ligament before this. To see the triangular ligament more distinctly, the same might be done on the right side, but the vessels and nerves are to be preserved entire.

Triangular Ligament.

The *deep perinæal fascia*, or *triangular ligament** of the urethra, is a rather strong process of fascia situated deeply in the perinæal space, and assisting to close the interval between the parallel borders of the levatores ani in the front of the inferior outlet of the pelvis. This structure is triangular in form, is about one inch and a half deep, and the greater number of its fibres are transverse; the apex is above at the symphysis pubis, on which it is prolonged, and joins the periosteum; the sides are attached to the ascending ramus of the ischium above the origin of the erector muscle, and to the descending ramus of the pubes; and the base, looking towards the rectum and the levatores ani, whose fibres appear beneath it, is oblique upwards and inwards towards the central point of the perinæum, which it joins; and from this border a thin fascia is prolonged over the levatores in the ischio-rectal fossa, and is applied externally to the obturator fascia on the outer wall of the pelvis, at the point of separation of the levator from it: it is this thin prolonged part of the fascia which is sometimes considered as a portion of the deep perinæal fascia, through which passes the lower part of the rectum, and in the female the vagina. Perforating the centre of the ligament, about one inch below the symphysis pubis, is the urethral canal, which receives from the membrane a fibrous prolongation both forwards and backwards, and this obscures the margins of the aperture; above this, in the middle line, or about half an inch below the symphysis, are the apertures for the dorsal veins of the penis; and on each side of this, near the attachment to the bone, it is perforated by the dorsal artery and nerve of the penis, the latter being highest. The anterior surface, inclined slightly downwards and forwards, is in contact with the accelerators urinæ muscles, and with the erectores penis, as well as the transversales, and the vessels and nerves that lie in the hollow or space between the muscles; and united to it in front, near its lower border, is the superficial fascia that dips down behind the transversalis muscle: the junction of the two fascia, as before explained, determines the direction of effused urine. The pos-

* This was described by the name of "triangular ligament of the urethra" by M. Colles, in the number of his *Surgical Anatomy* before mentioned; it is called the "l'aponévrose moyenne, by Blandin" (*Traité d'Anatomie Topographique*); and "ligament périnéal," by M. Carcassonne (*Thèse*, Montpellier, 1821.)

terior surface is in relation with the levatores ani, whose fibres descend behind it, as well as with the prostate gland, and a tube is prolonged back from it to join the pelvic fascia on the prostate. The ligament serves to support the thin membranous portion of the urethra which passes through it, and it divides the canal of the urethra into a spongy portion external to the pelvis, whose extent backwards is marked by the enlargement of the bulb close to the triangular ligament, and into a portion within the cavity of the pelvis, which includes its membranous and prostatic divisions. It consists of two layers: the superficial, now apparent, is very thin, and allows the pudic artery to be seen through it; it is attached firmly to the bone on each side, and if it be divided carefully near this insertion, and thrown towards the urethra on both sides, its posterior layer, with the parts between the two, will come into view by means of a little dissection. The posterior layer of the ligament is an extension of the obturator fascia across the space included by the arched borders of the rami of the pubes and ischium; it is continued upwards to the posterior part of the symphysis on which it ends, and below, it joins the anterior layer, and the prolongation over the levator. The space included between the layers is larger below than above, and in it are placed the sub-pubic ligament close to the pubes, with the dorsal veins of the penis perforating it; the membranous portion of the urethra, which occupies the centre of the ligament, together with the compressor urethræ muscle acting on this part of the urethral canal, and consisting of a vertical fasciculus of fibres from the pubes, and a transverse from the tuberosity of the ischium; and below the urethra and beneath the fibres of the muscle is, on each side, Cowper's gland; along the rami of the ischium and pubes are the trunks of the pudic vessels and nerve, the artery giving its transverse artery to the bulb between the two layers; and running in the same course is a nerve to the same part of the urethra. Some large veins are also found between the layers.

Compressor Urethræ Muscle.

The *compressor urethræ muscle**, well marked in some subjects,

* The muscle here named compressor urethræ, has had its vertical and transverse portions described as separate muscles by different authors; but we think with Guthrie, that it is better to consider them as one muscle. The vertical fibres and inferior tendon are described by Wilson in the first volume of the *Medico-Chirurgical Transactions*, in a paper entitled "A Description of Two Muscles surrounding the membranous Part of the Urethra," 1808. These have been named Wilson's muscles; but there is great difference of opinion, whether they are within the layers of the triangular ligament, or are only a part of the levator ani; but from a careful perusal of the paper, we consider that Wilson intended to point out the fibres between the layers of the ligament. The transverse fasciculus of muscular fibres is pointed out by Santorini in his *Observationes Anatomicæ*, 1724, cap. x. § viii. as an "elevator, or ejaculator of the urethra;" and he states that it is inserted into the lower part of the urethra. This is delineated in plate 3.

in others less so, is situated between the layers of the triangular ligament, and acts in diminishing the caliber of the membranous portion of the urethra, which is surrounded by its tendon. The muscle consists, on each side, of a vertical and a horizontal fleshy portion, united by a central tendon; the vertical portion *arises* above by a tendon attached to the posterior part of the symphysis, about one eighth of an inch above its lower border, and it is also united to the posterior layer of the triangular ligament: fleshy fibres soon succeed to the tendon, and these separate near the urethra into two muscular bands, which, opposite the side of the urethra, spread themselves out through the whole extent of its membranous part, and end below in a median tendon. The transverse portions commence, one on each side, by a wide but thin tendon from the ascending ramus of the ischium, a little below its junction with the descending ramus of the pubes, and beneath the crus and its erector; the fleshy fibres are directed almost transversely inwards to the membranous part of the urethra, and end in a tendon which joins with its fellows and that of the other portion, both above and below this tube, so as to incase it in a tendinous sheath, the line of tendon below the urethra being *inserted*, behind, into the under part of the front of the prostate, and before, to the central point of the perinæum; and the upper line of tendon is fixed, behind, to the upper surface of the front of the prostate, and before, to the urethra in front of the triangular ligament. The transverse portion of this muscle sometimes lies on the pudic artery, but at others is beneath it, and it conceals Cowper's gland which is still deeper: the vertical part is separated from the anterior fibres of the levator ani, running something in the same direction, by the posterior layer of the triangular ligament. The tendinous lines of insertion cannot be seen in the front view, since they require a lateral one; but if the urethra be separated from the body of the penis, and pulled down a little, a better view of them will be obtained.

Origin.

Insertion.

Relations.

Cowper's, or the *anti-prostatic glands*, are contained between the layers of the triangular ligament, below the membranous portion of the urethra, and close behind the bulb, the transverse

Cowper's Glands.

---

fig. 5. in the *Observationes*, and in plate 16. fig. 1. in the *Septemdecim Tabulæ*. Santorini has moreover described the same muscle in the female, in his *Observationes*, cap. xi. § iv. as passing over the urethra, and he named it the "depressor urethræ;" and it is shown in plate 2. fig. 1. as well as in plate 17. fig. 1. of the *Septemdecim Tabulæ*. Guthrie, in his work, *On the Anatomy and Diseases of the Neck of the Bladder and of the Urethra*, 1834, page 34 and following, makes mention of these muscles of Wilson and Santorini as one, contained within the layers of the triangular ligament; and he specifies also the points of insertion of the median line of tendon both above and below the urethral canal.

portion of the compressor urethræ concealing the gland of each side, and they lie, oftentimes, close to the artery of the bulb, but below it. Each is a small conglomerate gland, varying in size from that of a small pea to the size of a coffee berry: a small duct, near an inch in length, is connected with each, and perforates obliquely the spongy portion of the urethra to open into the under and lateral part of the canal, about the same distance from the triangular ligament, by an aperture that will scarcely admit a bristle. These bodies are sometimes so small as to escape detection, or there may be a second glandular body in front of them.

Dissection. The pudic artery is seen between the layers of the triangular ligament to divide into its terminal branches; and the dorsal branch of the pudic nerve, deeper than the artery, is observed to perforate the border of the sub-pubic ligament to reach the dorsum of the penis: these are to be followed back along the outer wall of the ischio-rectal fossa of the right side, and the tubular sheath of fascia that incases them, laid open as far as to where they appear in the fossa, and the remaining anatomy of both the nerve and artery will be exposed. The cutaneous branches of both have been previously dissected; but these may be again referred to, if needed, with the general description of the trunks.

Pudic Artery. The *pudic artery*, a branch of the internal iliac in the pelvis, leaves this cavity by the great sacro-sciatic notch, enters the ischio-rectal fossa through the small notch, and supplies the external genital organs, both in the male and female, as well as the parts of the perinæum. It is the last portion only of the artery that is now dissected: it enters the ischio-rectal fossa at the posterior part, extends forwards along its outer boundary, placed against the obturator internus muscle, but separated from it by the fascia, and it lies in an aponeurotic canal together with the pudic nerve and vein, the nerve being below the artery; and opposite the tuberosity of the ischium it is one inch and a half above this prominence of bone, and about two inches from the surface, but as the artery approaches the front of the fossa or base of the triangular ligament, it is nearer the surface: it now enters between the layers of the triangular ligament, ascends along the rami of the ischium and pubes, either covered by the compressor urethræ muscle or lying on part of it, and near the sub-pubic ligament perforates the superficial layer of the triangular; and in its position between the ramus of the pubes and the crus penis, divides into the arteria corporis cavernosi and the arteria dorsalis penis. Its branches are distributed to the central parts of the perinæum and the external genitals; thus—

Branches.

Inferior Hæmorrhoidal. *Inferior hæmorrhoidal* arteries supply the lower part of the

rectum, sphincter, and the parts in the fossa, joining those of the opposite side.

The *superficial perinæal* is distributed to the central part of the perinæum in front of the anus, and to the scrotum: this anastomoses with its fellow. The *transverse perinæal* passes also to the middle line of the perinæum. In this part the pudic gives a separate artery to the erector penis muscle. These arteries have been already dissected with the cutaneous nerves, and the description will be found with them. Superficial Perinæal. Transverse.

The *artery of the bulb*, the most important branch of this vessel, arises from the pudic when it has entered between the layers of the triangular ligament, runs almost horizontally inwards between the layers, at a variable height above its base, but usually about a quarter of an inch, reaches the bulb of the urethra, and ends by perforating the spongy substance in which it ramifies. Near the urethra it sends downwards a small branch to Cowper's gland; but this is not seen unless it is a successful injection of the arteries of this part. It is this artery that it is so important not to injure in the operation of lithotomy, since its large size, and the density of the ligament in which it is placed preventing its retraction, occasion serious hæmorrhage. Artery of the Bulb.

The *artery of the corpus cavernosum*, one of the terminating branches, lies for a short distance between the crus and the bone, and then perforates the fibrous tissue of the penis to ramify in its cellular structure; but the distribution of this vessel in the interior of the cavernous body, will be seen in the examination of the penis. Artery to the Corpus cavernosum.

The *dorsal artery of the penis* runs upwards and inwards between the crus penis and the bone, and in front of the sub-pubic ligament, coming into relation with the nerve of the same name which is now superficial, and they both pass forwards between the layers of the suspensory ligament, and along the dorsum of the penis to which they are distributed; but their final divisions will be dissected afterwards. This branch is very small in the female: it is sometimes a separate branch from the internal iliac, and perforates the triangular ligament to reach the penis. Dorsal branch.

The pudic artery is accompanied by a *vein* which has the same relations as the artery, and the same branches, with the exception of the dorsal vein that perforates the sub-pubic and triangular ligaments, to open into the plexus of veins on the sides of the prostate gland. Pudic Vein.

The *pudic nerve*, a branch of the sacral plexus, enters the ischio-rectal fossa with the artery, and soon divides into a large inferior branch to supply the parts in the perinæum, and a small one that continues the direction of the nerve with the vessel, and ends on the dorsum of the penis. The large *inferior division*, or *perinæal branch*, situated below the artery, and contained in the same sheath of fascia, extends forwards nearly to Pudic Nerve. Inferior or Perinæal Division.

the base of the triangular ligament, and ends by dividing into many branches to supply the muscles and bulb of the urethra.

Branches. The branches of this nerve are numerous, but much resemble those of the artery.

Inferior Hæmorrhoidal. The *inferior hæmorrhoidal* nerves, sometimes branches of the pudic, and sometimes of a distinct nerve of this name from the sacral plexus, run inwards to the lower part of the rectum and sphincter, and central part of the perinæum.

Posterior Superficial Perinæal. The *posterior branch* of the two superficial perinæal nerves, or the external perinæal, appears in the front of the ischio-rectal fossa, and then runs forwards to be distributed to the scrotum,

Anterior Superficial branch. The *anterior superficial perinæal* perforates the obturator fascia near the base of the triangular ligament, and turns forwards with the artery of the same name, to end in the scrotum and perinæum: this supplies muscular branches to the transversalis and accelerator urinæ muscles.

Nerve to the Bulb. The *nerve of the bulb* is one of the numerous branches into which the perinæal portion divides near the base of the triangular ligament: it perforates the obturator fascia with the rest, and passes upwards and inwards, commonly between the fibres of the base of the triangular ligament, to reach the bulb of the urethra, to which and to the spongy portion of this tube it is distributed: one or more very long and slender filaments run for some distance on the surface of the spongy substance of the urethra, before perforating it.

Muscular. *Muscular branches* are given off also from the division of this portion of the nerve. One passes outwards to supply the erector penis, which it enters by its under surface; and a small nerve extends forwards from it, perforates the base of the triangular ligament, and supplies the compressor urethræ: this small nerve may be a distinct branch. The other muscular branches may arise either separately from the superficial perinæal, or by a single branch which passes beneath the transversalis muscle, and divides to supply them.

Superior division, or Dorsal Nerve. The *superior branch* from the division of the pudic nerve in the posterior part of the fossa, becomes the dorsal nerve of the penis: it accompanies the artery, and placed above this vessel, runs with it upwards and forwards, enters with it between the layers of the triangular ligament, but situated deeper than it; and when the vessel perforates this structure to divide between the crus penis and bone, the nerve still continues between the layers, passes through the base of the sub-pubic, next perforates the superficial layer of the triangular ligament, and then comes into contact with the branch of artery of the same name, passes with it between the layers of the suspensory ligament, and is distributed to the penis and its integuments. The size of this nerve varies according to the sex, since it is small in the female, but the opposite in the male: its anatomy on the penis is dissected with the abdomen.

Parts divided in the lateral operation of lithotomy. To obtain an accurate notion of the structures divided in the lateral operation of lithotomy, it would be necessary to perform

the operation, and then to examine the perinæum on the same subject; but, with only the present dissected one, the dissector must endeavour to recall to his memory the anatomy of the different parts as they were exposed.* The incision to reach the bladder is commenced on the surface, in the *raphé* of the perinæum, about an inch in front of the anus, and is carried down, on the left side, to between the tuberosity of the ischium and the anus; this divides the skin, superficial fascia and vessels, and ends in the ischio-rectal fossa. The next step is to carry the knife into the posterior part of the interval between the erector penis and accelerator urinæ, to cut across the transverse muscle and artery, and probably, the superficial perinæal vessels and nerves, together with the lower part of the triangular ligament and the anterior fibres of the levator ani, in order to expose the staff in the membranous part of the urethra. When the staff is reached, the knife is to be conveyed in its groove into the bladder, dividing this part of the urethra and the posterior layer of the triangular ligament; and the prostate gland that surrounds the neck of the bladder, but not now exposed, is to be cut downwards and outwards; the capsule that surrounds this body will be divided at the same time, and the bladder will be opened. The previous dissection will have shown that the rectum in the middle line, and the pudic vessels on the outer wall of the ischio-rectal fossa, together with the bulb and its artery in the triangular ligament, are the parts to be avoided in the operation. The artery and bulb will be cut only by making the first and following incisions to reach the urethra too far forwards: the rectum will escape being wounded if it be held aside with the left hand during the previous incisions, and if the knife be made to divide the parts in the same line as that of the division of the integuments, instead of being turned too much inwards to the middle line; and the pudic artery will be avoided by the same means: this is so well secured from injury by the wall of the pelvis, that it seems almost impossible to reach it if the knife be skilfully used. In dividing the prostate, the incision is to be directed downwards and outwards in the left lateral lobe of the gland, this being its largest measurement; and the same inclination is to be given to the knife to avoid the common ejaculatory duct which lies nearer the middle line; but these facts will be verified in the examination of the prostate.

Operation of Lithotomy.

When the perinæum is completed, fasten together the flaps of skin with a few stitches, and put down the extremities.

* I have followed the example of the *Dublin Dissector*, and that of *Quain's Anatomy*, in introducing these surgical remarks.

DISSECTION OF THE FEMALE PERINÆUM.

In the female, the perinæum differs more from that of the male in its external form than in its internal anatomy, though it has parts proper to it, as the aperture of the vagina, surrounded by its sphincter muscle, and the existence of labia instead of a scrotum. The different steps in the dissection of the other will serve for that of the female, and the same description will suffice, generally, for the two. The boundaries of the space, and markings of the surface, are referred to in the general description of this part in the male.

Dissection. Make a transverse incision above the vulva to the thighs, and another at the tip of the coccyx, and connect the two together by an incision in the middle line, carrying it round both sides of the vulva and of the anus: raise the flaps, as in the male; clean away now the fat from the ischio-rectal fossa, on one side, to a line with the front of the anus; and on the opposite do the same, dissecting out the nerves and vessels, which are similar to those in the male, but smaller.

Examine next the attachments of the superficial fascia on the left side: externally and behind it ends as in the male, but internally and in front it ceases in the labium; and on the opposite side, follow the cutaneous nerves and vessels in the fat: they are the same in number, but are much smaller, and are distributed to the labium and integuments.

Dissection. Remove the labia and the cellular membrane from the front of the perinæum, and the sphincter vaginæ surrounding the entrance of the vagina is exposed; the erector clitoridis, on the rami of the pubes and ischium; and the transversalis perinæi, crossing from the tuberosity of the ischium to the middle line.

Sphincter Vaginæ Muscle. Origin. The *sphincter vaginæ muscle* consists of orbicular fibres around the orifice of the vagina, and it is attached, posteriorly, to a central point in the perinæum, midway between the posterior extremity of the vulva and the anus, and it here mixes with the muscular fibres of the sphincter and transversalis: the fibres are directed forwards on both sides of the aperture of the vagina,

Insertion. and are *inserted*, above, into the body of the clitoris, with the erectores clitoridis muscles. This muscle surrounds the orifice

Relations. of the vagina, and some of the deeper fibres are in close contact with its walls.

The *erector clitoridis* is the same in its anatomy as the erector penis; and the *transversalis* is also similar to the same muscle in the male.

Dissection. Detach the erector and crus from the rami of the pubes and ischium, and remove the outer circular fibres of the sphincter

vaginæ from the front of the triangular ligament: this structure is the same as in the male, except that the vagina, in addition to the urethra, passes through it.

Raise one layer of the triangular ligament, and the compressor urethræ muscle is exposed: the transverse part of it, or the depressor of Santorini, is sometimes very well marked. The nerves and arteries between the layers of the triangular ligament are the same as before described; but those to the clitoris, instead of being the largest, as in the male, are the smallest; and the branches of the pudic artery and nerve, that correspond to the bulb, are distributed to the wall of the vagina. Cowper's glands are smaller, and the ducts from them open into the vagina. Dissection.

Follow back now the trunks of the pudic vessels and nerve, and complete their anatomy.

DISSECTION OF THE ABDOMEN.

Dissection. The dissection of the abdomen follows after that of the perinæum. This part is sufficiently raised by the blocks beneath the buttocks and chest, as recommended for the extremities; and one beneath the loins would prevent the following back the abdominal muscles to their posterior attachments. To render the muscles tense, inflate the abdomen by an aperture through the umbilicus; and then make one incision outwards, over the side of the chest, from the ensiform cartilage to about midway between the sternum and spine; another, below, from midway between the umbilicus and pubes to the front of the crest of the ilium, continue this along the crest till nearly opposite the termination of the one above, and then connect the two by a vertical incision along the side of the chest: raise the portion of integument towards the middle line, and leave untouched, for the present, the small piece of skin in the inguinal region. In the cellular membrane or superficial fascia beneath the skin, will be found, on the side of the abdomen, near the vertical incision in the integuments, the middle cutaneous branches of the intercostal nerves, which run downwards and forwards; and near the middle line, the anterior cutaneous branches of the same. If it is the dissection only of the muscles that is required, take the cellular membrane as well as the skin from the muscular fibres, and clean the muscle in the direction of its fibres, or of the incision along the side of the chest.

Cutaneous Nerves. The cutaneous nerves of the abdominal wall are branches of the intercostal nerves, which, in the lower spaces, enter between the abdominal muscles; and, like the cutaneous nerves of the thorax, they consist of a lateral and a median set. The *lateral set* or *middle intercostal cutaneous*, six or seven in number, enter the integuments along the side, about midway between the spine and middle line in front, and form an arch as they emerge, the lowest being the most posterior; the upper ones appear between the digitations of the serratus magnus, and the lower between those of the external oblique muscle. These nerves, with the exception of the last, run downwards and forwards, at first between the oblique muscle and its fascia, then perforate the fascia, and are directed towards the linea semilunaris, supplying the integuments of the side of the abdomen. The last of these, or the cutaneous branch of the last dorsal nerve, larger than the others, instead of being distributed on the abdomen, passes vertically downwards over the crest of the ilium, and supplies the integuments over the upper part of the gluteal

Middle Intercostal.

region: it is occasionally very small. Another small nerve from the ilio-inguinal branch of the lumbar plexus perforates the external oblique muscle near the crest of the ilium, descends with the anterior branch of the last dorsal nerve but posterior to it, over the crest, and is lost in the integuments on the gluteal muscles: its size depends upon that of the last dorsal nerve. The *central* or *median set* of cutaneous nerves correspond to the *anterior cutaneous* branches of the intercostal nerves of the thorax, and are the terminal branches of the same nerves in the wall of the abdomen. They become cutaneous by perforating the sheath of the rectus muscle, and turn outwards to supply with the lateral cutaneous nerves, the integument of the abdomen. The number of these is very irregular, nor do they perforate in a continued line, some being much nearer the centre of the body than the others. Both this and the other set of the nerves are accompanied by small cutaneous arteries which end in the integuments.

Cutaneous of the Ilio-inguinal.

Anterior Intercostal Cutaneous.

Throw down to the thigh the remaining piece of skin which covers the inguinal region, without disturbing the cellular membrane, by means of an incision along the middle line to the pubes: divide the skin along the dorsum of the penis, as well as vertically that of the scrotum, and raise it from these parts to expose the continuity of the cellular layer with that of the abdomen, and next examine the subcutaneous cellular membrane or superficial fascia in the inguinal region.

Dissection.

The *superficial fascia* of the greater part of the abdomen has received no especial notice, but that covering the inguinal region has been attentively studied, because of its relation to inguinal hernia. * In the groin it is continuous with that of the rest of the abdomen, and is divisible near Poupart's ligament into two layers, like that of the thigh, by the same cutaneous vessels which are enclosed in it. The superficial of the two layers is now to be separated from the deep, by a transverse incision from the spine of the ilium to the middle line, and by another from this last spot to the pubes, the line of division being marked by the cutaneous vessels which ramify between them, and by a condensed whitish portion. It contains the adipose matter, varies in thickness according to the condition of the subject, and is separated from the deep, by the superficial vessels and by the inguinal glands along Poupart's ligament; above, it is continuous with the superficial fascia of the abdomen, and below with that of the thigh; and as it passes over Poupart's ligament it is unconnected to this structure, the superficial vessels and glands intervening, as is seen in the dissection of it in the thigh. Around the cord it sends a tubular prolongation, which is easily separated from it, descends into the scrotum, assisting to form

Superficial Fascia.

Superficial Layer.

* This is described by Camper, in his *Icones Herniarum*, p. 11.

the dartos, and is there destitute of adipose tissue. If this layer be divided down to the bottom of the scrotum, it will be seen to become very thin, to be of a reddish colour, and to be traversed by numerous veins which are visible through the thin skin of this part. After surrounding the testicle in the scrotum, it is prolonged backwards into the perinæal space, and is continuous with the superficial fascia of that part; which explains the fact of effusions of urine into this region finding their way through the scrotum to the abdomen. The sheath or prolongation sent around the cord on one side is distinct, in the scrotum, from that of the other, and by their contact in the middle they form the septum scroti. In the middle line of the abdomen it is thicker, contains masses of fat, and is not so separable from the layer beneath; it is continued below to the penis, and loses also, as in the scrotum, the adipose tissue which abounds in it in the other parts.

Superficial Vessels. The *superficial vessels*, which may be next cleaned and followed, are branches of the femoral artery, which turn up over Poupart's ligament between the layers of the fascia, and ramify in its substance.

Superficial External Pudic. The *superficial external pudic* artery, the most internal in position, crosses the cord, supplying it with branches, and is then directed to the penis, to the integuments of which it is distributed: it is accompanied by the ilio-inguinal nerve which perforates the deep layer of the fascia. The deep external pudic beneath the fascia lata of the thigh, is distributed to the inner and posterior part of the scrotum.

Superficial Epigastric. The *superficial epigastric artery* ascends over Poupart's ligament, near its centre, and reaches as high as the umbilicus, supplying the integuments.

Superficial Circumflex Ilii. The *superficial circumflex ilii*, smaller than the other two, ends in the integument and superficial fascia near the crest of the ilium; it may not turn upwards to the abdomen. These arteries are accompanied by veins of the same name, which join the saphenous vein in the thigh.

Lymphatic Glands. The *lymphatic inguinal glands*, seen also in the thigh, are three or four in number, lie parallel to Poupart's ligament, receive the lymphatics from the genital organs, from the upper and outer part of the thigh, and from the abdomen, and send their efferent tubes through the saphenous opening.

Dissection. The scrotum may now be pulled forwards, and the incision in it continued back to that made in the perinæal space, so as to trace forwards the cutaneous nerves and vessels already seen, which supply the outer and under surface of the scrotum and lower part of the penis with branches. Reflect the deep layer of the fascia by a transverse incision from the crest of the ilium to the linea alba, and by a vertical one from this to the pubes: its union to Poupart's ligament is very intimate, and is not to be

broken or cut through. In separating it from the cord be careful not to destroy a thin fascia, the spermatic, which surrounds the cord: follow it both into the scrotum and along the penis, cutting through the coverings that it sends to these parts. In raising it, one or two branches of nerve are seen to perforate the tendon of the external oblique muscle, as well as to pass through the external abdominal ring with the cord.

Deep Layer of the Superficial Fascia.

The *deep layer of the superficial fascia**, thinner and more membranous than the other, is closely united to the tendon of the external oblique beneath, by cellular processes free from fat; and as it passes over Poupart's ligament to the thigh,—where a part of it is named cribriform fascia,—it is connected to it, in its whole length, by cellulo-fibrous membrane, which serves as a partition between the thigh and abdomen; and if this be divided, and the handle of the knife passed beneath, its continuity on the thigh will be apparent; but it extends only a short way below Poupart's ligament, since the under portion of the layer joins the fascia lata, as is seen in the dissection of the femoral region. A portion of it, deprived of its adipose substance, descends into the scrotum, unites with the other layer, and forms with it the dartos and septum scroti. The connection of this to the cord is very close, so that the subjacent thin covering may be removed without care in separating it. By the descent of the fascia into the scrotum and into the perinæal space, in which part it forms the deep layer attached to the rami of the ischium and pubes and to the triangular ligament, urine effused beneath it is directed forwards to the abdomen, but it is prevented from passing down on the thigh by the attachment to Poupart's ligament. Along the middle line, or linea alba, the processes that connect it to the tendon beneath are long and almost fibrous, and some of these fibres, near the pubes, serve as a superficial suspensory ligament to the penis. The penis receives also a thin investment from this portion of the fascia. In the female the superficial fascia of the inguinal region is separable as in the male, and instead of the layers descending into the scrotum, they pass into the labium. The round ligament of the uterus is lost in the cellular membrane of the groin.

Cutaneous Filaments of the Ilio-inguinal Nerve.

One or two filaments of cutaneous nerves, seen perforating the tendon of the external oblique muscle, are the terminal filaments of the abdominal branch of the *ilio-inguinal* nerve, to be afterwards dissected, and these end in the integuments of the ingui-

* This portion of the fascia is described as one to avoid confusion; but, strictly speaking, it consists of a cellular part, continuous with the superficial fascia of the thigh, which is very thin; and of a deep aponeurotic portion, described by Scarpa as the "aponeurosis of the fascia lata," which is a prolongation from the fascia lata below it, and is attached to Poupart's ligament as it passes over. See *Scarpa on Hernia*, translated by Wishart, pp. 23. 247.

nal region. The inguinal branch of the same nerve leaves the wall of the abdomen at the external abdominal ring, perforates the coverings of the cord, as well as the deep portion of the superficial fascia, and is distributed to the superficial of the two layers and to the integuments of the cord. In the female this nerve supplies the labium.

Dissection. Remove some cellular membrane from the middle line or root of the penis and its suspensory ligament is exposed: follow forwards the cutaneous vessels on the dorsum of this body, so as to complete the anatomy of the external part of the pudic vessels and the nerve, which were commenced in the perinæum.

Suspensory Ligament of the Penis. The *suspensory ligament* of the penis consists of a triangular process of fibrous tissue, which is attached above, by a pointed portion, to the anterior and lower part of the symphysis pubis: from this attachment it descends, becoming wider, to the penis, and divides into two portions, which separate to be fixed to the upper surface of the corpus cavernosum, along which they extend for some distance: in the interval left by the divergence of the two sides of the ligament, are the dorsal vessels and nerves of the penis.

Dorsal Artery of the Penis. The *dorsal artery* of the penis is the terminal branch of the pudic, and its commencement was seen in the perinæal space, between the crus penis and the ramus of the pubes. The branch ascends along the ramus of the pubes, and in front of the subpubic ligament, to reach the interval between the layers of the suspensory ligament. It then passes forwards on the dorsum of the penis, being covered only by the skin and superficial fascia, to reach the corona glandis, at which it divides into many branches that surround this structure before perforating it to anastomose with the arteries supplied to the corpus spongiosum urethræ: some of the branches are given to the integuments of the glans. Along the penis, it is accompanied by the dorsal veins and nerves of this organ, lies in the central median depression, and is covered by a fibrous tissue. This artery may come from the pelvis, through the triangular ligament, instead of being a branch of the pudic in the perinæal space.

Dorsal Veins. The *dorsal veins* of the penis commence at the glans, by numerous branches both from its substance and from the prepuce, which unite together to give rise to two or more veins that run backwards with the artery, receive some small branches from the corpus cavernosum, pass between the layers of the suspensory ligament, beneath the tendon of the compressor venæ dorsalis penis, and then through the apertures in the triangular and sub-pubic ligaments of the perinæum, to join the prostatic plexus of veins in the pelvis.

Dorsal Nerve. The *dorsal nerve* of the penis, one on each side, is the continuation of the pudic, which perforates the triangular ligament of the perinæum, passes to the dorsum of the penis between

the layers of the suspensory ligament, and continues forwards to the glans, at which it divides into numerous filaments to enter this body and supply its papillæ. Each nerve gives off a large branch, that passes to the side of the penis, and divides into many filaments which are distributed to the integuments of the side and upper part, and to the prepuce, some entering the structure of the corpus cavernosum.

In the female these vessels may be dissected on the clitoris, but they are very much smaller than in the male.

The *compressor venæ dorsalis penis muscle** "arises from the ramus of the pubes above the origin of the erector penis and crus, and ascending in a direction forwards is inserted above the vena dorsalis, by joining with its fellow in the mesian line. It forms a thin stratum of muscular and tendinous fibres, about one inch long and three quarters of an inch broad, and may perhaps be looked upon as a portion of the erector penis, which, instead of being inserted into the side and lower part of the corpus cavernosum, mounts over this body to exert its compressing influence on the vena dorsalis. They enclose between them and the penis, the vein, arteries, and nerves of this region. Its anterior fibres are distinguished from those of the erector by the fibrous attachment of the crus to the pubes; its posterior margin is kept distinct from the front part of the levator ani, known under the name of Wilson's muscle, by the pudic artery, which divides them in its course towards the dorsum of the penis."

Dissection.

Cut through the cutaneous nerves, and throw them back: take away the cellular membrane from the external oblique and front of the abdomen, beginning at its posterior or muscular part, and separate it in the direction of the fibres. The muscular fibres end in a tendon, in a line extended from the side of the chest to the front of the crest of the ilium; and this may be cut through without care, particularly where it passes over the margins of the upper ribs, and is very thin. The posterior margin of the muscle is free in the interval between the last rib and crest of the ilium, and the integuments are to be removed as far back as this.

Muscles of the Abdomen.

The muscles of the abdominal wall are large and flat, partly muscular, partly tendinous, and consist of three layers on each

* This muscle is described by Mr. Houston in the *Dublin Hospital Reports*, vol. v. 1830, from which this extract is taken; but in it the singular is substituted for the plural. He demonstrates also its dissection in the following sentence, p. 474.:—"The insertion of the muscles being in a great measure outside the pelvis, they may also be demonstrated without the section of the bones, by cutting on them in front of the pubes, and looking carefully for their tendon by the side of the vena dorsalis: from the tendon, the knife may be carried downwards and backwards in the course of the fibres, and nearly the whole of the muscle can then be exposed." A section of the pelvis is recommended as the best proceeding to expose it, but this cannot be made. It is only in muscular subjects that it will be found.

side, named, from the direction of their fibres, oblique and transverse. In the middle line, in front and behind, are some additional muscles which pass vertically, and are incased in the splitting of the tendons of the lateral ones. The part of the abdominal wall in which the muscles are absent, is in the inguinal region, since they here present a free border over the vessels passing to the thigh, and moreover, allow the cord to pass either below their border or through their substance. From this deficiency in the wall, the power to confine the contents of the abdominal cavity is necessarily impaired, and the viscera protrude more readily at this part than at any other, forming one or other kinds of hernia.

External Oblique Muscle.

The *external oblique muscle*, the most superficial in the abdominal wall, is fleshy externally, and marked by digitations which attach it to the ribs, and tendinous internally, between the chest and pelvis. It *arises*, by fleshy digitations, from the outer surface and lower border of the seven or eight lower ribs, the four or five upper digitations alternating with those of the serratus magnus, and the three or four lower with the latissimus dorsi. From the attachment to the ribs, the fibres diverge: the lower ones pass vertically downwards to be fixed to the anterior half of the outer border of the crest of the ilium; the upper, thin and weak, horizontally inwards; and the middle fibres, longer than the rest, more or less obliquely forwards, to end opposite a line drawn from the eighth rib to the anterior part of the crest of the ilium, or the linea semilunaris, in a wide aponeurosis which extends forwards to the middle line, joining with that of the opposite side to form the linea alba; downwards to the pelvis, giving rise, in the interval between the crest of the ilium and the pubes, to the firm rounded cord of Poupart's ligament; and upwards it is continued to the thorax, and gives attachment to the great pectoral muscle. The muscle is covered by the integument and superficial fascia, and by the cutaneous nerves and vessels, and sometimes it is overlapped behind by the latissimus dorsi. The posterior border is free in the space between the last rib and crest of the ilium, and is either covered by the latissimus dorsi, or placed by its side, a portion of the internal oblique muscle appearing between them. Its upper part is connected to the thorax, and the fibres are continuous with the external intercostal muscle: it joins the aponeurosis in the middle line. The parts that the muscle covers will be seen when it is divided.

Origin.

Insertion.

Relations.

Aponeurosis of the External Oblique.

The *aponeurosis of the external oblique muscles* is a wide, somewhat square tendon, situated in front of the abdomen, and extending laterally beyond the margin of the rectus muscle, whose limit is seen by a white semilunar line. In the lower part it is widest, occupies the whole interval between the crest of the ilium of both sides, and is attached to the pubes in the

middle line; but between these points it forms a thickened border, called Poupart's ligament. About the centre of the abdomen it is rather narrowed, and expands again, above, to be attached to the thorax and xiphoid cartilage. In it are seen numerous small apertures near the middle line, to give exit to cutaneous nerves and arteries; and near the pubes is the external abdominal ring for the spermatic cord in the male, and round ligament in the female. Along its centre are the linea alba and projection of the umbilicus; on each side, running nearly in the same direction, the linea semilunaris; and crossing from one to the other, the lineæ transversæ. The lower part of each half of the aponeurosis has been more particularly examined than the rest, because of its connection to inguinal hernia which escapes through the opening for the passage of the cord. This portion of the tendon corresponds to the inguinal region, and may be artificially limited by a line from the anterior superior spine of the ilium to the linea alba. Its fibres, more separate and distinct than in the other parts, are also stronger, and run downwards and inwards to be fixed to the pubes, or to end in Poupart's ligament. Near the pubes they are separated by an interval, which extends upwards and outwards to the muscular fibres, is wide below but narrow and pointed above, and closed to within about an inch of the pubes by some transverse fibres, the intercolumnar, which cross the tendinous ones of the external oblique aponeurosis in their course to the linea alba. The opening left unclosed at the lower part of this interval has been called the *external abdominal ring*, or lower abdominal aperture, the sides, or bounding portions of tendon, the pillars, and through it the cord escapes from a canal between the muscles of the wall of the abdomen, in which it lies. Its position is a little above and to the outer side of the crest of the pubes, and it is rather triangular in shape, the base being downwards and inwards at the crest of this bone, and the apex upwards and outwards, pointing in the direction of the crest of the ilium: the longest measurement of the aperture, from above downwards, is about one inch and a half, the transverse being about half an inch; but these may vary much. From its tendinous margins is given off a membranous prolongation, the fascia spermatica or intercolumnar fascia, which obscures the sides, and is derived from the intercolumnar fibres, which become more aggregated together near the opening, and give a covering to the cord which escapes from it. The inner tendinous boundary, or the *inner pillar** of the external abdominal ring, is wide, flat, and thin, and is continued forwards to the lower part of the linea alba, and to the front of the symphysis pubis, into which it is inserted, and on which it crosses the corresponding part of the tendon of the ex-

External Abdominal Ring.

Inner Pillar.

* This is called also superior or anterior.

ternal oblique of the opposite side, the portion from the right muscle being superficial to that from the left. The outer side of the opening, or the *outer pillar** of the ring, does not present a straight margin like the inner, but is bent forwards by the cord which lies on it in a kind of groove or canal; it is continuous with the part of the tendon which forms Poupart's ligament, and is inserted into the projecting spine of the pubes with the cord-like portion of this ligament. Through the ring passes the spermatic cord, which rests on the outer pillar, and receives a covering from the intercolumnar fascia: the inguinal hernia escapes from the wall of the abdomen through the same aperture, and is also covered by the fascia attached to its margins; and this constitutes one of the coverings of an inguinal hernia.

Outer Pillar.

Intercolumnar Fibres.

The *intercolumnar fibres* are mostly superficial to those of the aponeurosis of the external oblique, and cross their direction: they commence by a pointed process connected to the outer third of Poupart's ligament, and this can be followed outwards to the crest of the ilium: from this point, the fibres diverge over the lower part of the tendon of the external oblique muscle, some ascending to the linea alba above the upper margin of the ring, and some descending in front of the outer pillar to be fixed to the bone anterior to Gimbernat's ligament. It is the layer formed by these fibres that limits above the aperture of the external abdominal ring, and closes the upper part of the fissure or interval between the fibres of the tendon of the external oblique. When it is removed from the surface of the aponeurosis, which is readily done, the prolongation, named *intercolumnar* or *spermatic fascia*, sent from it along the cord, or round ligament in the female, is seen to form a thin covering, which is separable from the part that it invests.

Linea alba.

The *linea alba*, or the central white line, extended from the xiphoid cartilage to the pubes, serves as a point of union of the tendons of the muscles of the two sides, and as a ligament to connect the thorax and pelvis. Its breadth is wider above than below; it is perforated by small apertures, which allow granular masses of fat to protrude; and a little below the centre, by the aperture of the umbilicus, which permits the hypogastric vessels, urachus, and umbilical vein, to pass through it in the fœtus. The position of this opening varies in different subjects; and in the adult it is closed by a fibrous structure which is closely connected to the surrounding tendon. The umbilicus projects now beyond the surface, but before the skin was removed it was depressed by the close connection of the skin to it; in old and fat subjects this is more marked: this part has been injured by inflating the abdomen. It is through the umbilicus that a protrusion of intestine sometimes takes place.

* It is named also inferior and posterior.

The *linea semilunaris*, the other line external to the linea alba, marks the division of the tendon of the internal oblique into two parts, to incase the rectus muscle, whose outer border extends to this point. A line drawn from the eighth rib to the tuberosity of the pubes, would mark the position of the linea semilunaris. Linea semilunaris.

The *lineæ transversæ* cross from the linea alba to the semilunaris, and are caused by tendinous intersections of the rectus muscle, which appear through the aponeurosis of the external oblique. The number of these varies, but more are placed above the umbilicus than below it: when there are three, one is opposite the umbilicus, and the other two above it; when there are four, one is below; and when five, two are below the umbilicus. Lineæ transversæ.

To see the remaining part of the anatomy of the tendon, or Poupart's ligament, it will be necessary to reflect the lower portion towards the thigh by means of an incision from the anterior superior spinous process of the ilium to the middle line, and by a vertical one from this point to the pubes; the scalpel should pass only through the thin aponeurosis. Raise this portion by inserting the handle of the scalpel beneath it; and detach it from the tendons beneath, to which it is closely united near the linea alba: in separating the inner pillar of the ring, be careful not to remove the fibres of the triangular ligament or fascia beneath it. On the one side of the body this may be left unreflected, to examine the hernia, after the knowledge of the muscles and parts concerned in it is perfectly acquired. Dissection.

The portion of the tendon of the external oblique muscle called *Poupart's ligament*, or *the crural arch*, is the lower border situated between the crest of the ilium and the pubes. It is a firm cord, easily felt through the integuments, and its fibres, oblique in direction, join with some fibrous structure near the ilium: its external attachment, round and strong, is to the anterior superior spinous process of the ilium; but the internal is wide, and presents, at its insertion into the pubes, two parts very different in appearance and strength: one, the anterior, of the same round and firm character as the ligament of which it is the direct continuation, is inserted into the spine of the pubes, and is continuous above with the internal pillar of the ring; the other, much thinner, almost membranous, and formed by some of the lower fibres which are weaker than those to the spine of the bone, turns upwards and backwards beneath the spermatic cord, to be fixed to the pectineal line of the pubes for about three fourths of an inch, or an inch of its length, giving rise to Gimbernat's ligament, which thus appears to be formed by the fibres—too numerous to be fixed to a point of bone such as the spine of the pubes—being extended from this along the pectineal Poupart's Ligament.

line for a certain distance.* The line of Poupart's ligament between the ilium and pubes is not direct, but is oblique in about its outer half, or to the outer side of the femoral vessels, and is retained in this position by the close adherence of the strong fascia lata and iliaca; but the inner half is almost horizontal in front of the femoral vessels. If the thigh has been dissected and the fascia lata removed, this appearance is destroyed. At the point where it changes its direction, some fibres are detached from it, and pass forwards to the pubes, below the level of the ligament but over the vessels, uniting with the fascia transversalis, and constituting the deep arch to be afterwards seen. To its posterior surface are fixed the internal oblique and transversalis muscles of the abdomen, and the fascia transversalis; passing over the upper surface of its lower third is the spermatic cord, contained in a hollow or groove, formed in front, by the aponeurotic fibres curving forwards over it instead of being direct, and behind, by the lower fibres of the ligament turning backwards to join the pectineal line. The fibres of insertion of Poupart's ligament, which constitute *Gimbernat's ligament*, are best seen by raising the cord or round ligament from its position. This structure consists of fibres much weaker than those of the round cord-like part attached to the spine of the pubes, and it is inserted into the pectineal line of this bone for about an inch. In the natural position of Poupart's ligament, it is triangular in shape, the apex being at the spine of the pubes and the base outwards, directed to the space on the inner side of the femoral vein, or to the crural ring. †

Gimbernat's Ligament.

When the cord with its coverings is separated from the channel in which it lies, the fibres of the *triangular ligament* ‡ are observed to run upwards and outwards to the linea alba, from the insertion of Poupart's ligament into the spine and pectineal line of the pubes, and they terminate by joining the tendinous structures in this part. The fascia or ligament formed by them is placed opposite to the external abdominal ring or behind it, projects beyond the edge of the rectus and pyramidalis muscles; and when it is large, it crosses a part of the space through which a direct hernia protrudes, but when small, scarcely extends beyond the margin of the rectus.

Triangular Ligament.

Dissection.

On the side on which the aponeurosis has been divided, throw

* The attachment of the aponeurosis of the external oblique of each side, to the different points of the pubes, has caused some to speak of its three insertions into this bone; the connection of the internal pillar to the front of the body of the pubes being the first insertion; the outer pillar to the spine, the second; and the fibres to the pectineal line to form Gimbernat's ligament, the third insertion.

† For a more particular description of this ligament see the dissection of the thigh and parts concerned in crural hernia.

‡ Or triangular fascia, or diagonal brace, which was described by Colles.

forwards the external oblique muscle to the linea alba, by dividing it near its digitations on the ribs as far back as its free margin, and by cutting through the attachment to the crista ilii; but on the opposite side of the body, an incision should be carried forwards from the anterior spinous process to the linea alba, and none of the muscles should be exposed lower than this, until the dissector examines afterwards the surgical anatomy of this region, unless its anatomy has been previously acquired, in which case this part may be dissected before the muscles, and before it is flaccid from the escape of air: for the separate description of this part, refer to inguinal hernia. Between the external, and the internal oblique muscle, is a cellular layer, marking the separation: on the ribs, the tendon of the external is inseparably united to that of the pectoral, and a little below the ribs, the tendon of the internal oblique may be cut through without care. It cannot be separated farther forwards than about midway between the linea alba and semilunaris, and numerous vessels and nerves are cut through in reflecting it, but avoid the last dorsal and ilio-inguinal, which are to be dissected out.. Remove the cellular membrane from the muscle beneath.

Parts that the External Oblique covers.

The external oblique muscle covers the internal oblique, the cartilages of the seven or eight lower ribs, and the intercostal muscles between them. At the lower part of the abdomen, or in the inguinal region, it conceals the cord which escapes from beneath the internal oblique, with its covering of the cremaster muscle: near the middle line, the tendon passes in front of the rectus. Numerous small branches of nerves and arteries run between the two muscles, and supply the external oblique: near the middle line it is perforated by the central set of cutaneous nerves, and near the ribs, by the lateral; also by the last dorsal nerve, and by the cutaneous branch of the ilio-inguinal, or ilio-hypogastric. In the inguinal region, the abdominal branch of the same nerve lies between the external and the internal oblique, and then perforates the tendon of the former to be distributed to the integuments.

Internal Oblique Muscle.

The *internal oblique muscle* differs from the external in being fleshy below and tendinous above. The fibres ascend obliquely, so as to cross the direction of those of the external oblique, with the exception of the lower ones which descend. The muscle *arises* from the upper surface of the outer inclined portion or half of Poupart's ligament, from the three anterior fourths of the crest of the ilium as far back as to the lumbar aponeurosis, and from this same aponeurosis in the interval between the last rib and crest of the ilium. The fibres diverge from these points: those from the lumbar aponeurosis and posterior part of the crest ascend, almost vertically, to be *inserted* by fleshy processes into the lower border of the cartilages of the three or four lower ribs, the fibres being continuous, in the

Origin.

Insertion.

intervals between them, with the internal intercostal muscle of the two lower spaces: the fibres from the anterior part of the crest, the longest and most oblique, ascend, and those from Poupart's ligament pass either horizontally forwards or obliquely downwards, to end in an aponeurosis which covers the front of the abdomen,—joining with its fellow in the linea alba in the same way as that of the external oblique,—is wider near the thorax than the pelvis, and is inserted, above, into the margin of the cartilage of the last true rib and of those below it, above the fleshy attachment of the muscle; below, it is joined by the fibres from Poupart's ligament, and is inserted into the crest of the pubes from the angle to the spine, in front of the insertion of the rectus muscle; and, external to the angle of this bone and outer margin of the rectus muscle, it is fixed to the pectineal line for about half an inch, uniting with the tendon of the transversalis muscle beneath, to form the *conjoined tendon*, which is placed behind Gimbernat's ligament and the external abdominal ring, and with the fibres of the triangular ligament, strengthens the abdominal wall opposite the aperture in the external oblique tendon. The outer border of the aponeurosis is nearer the linea semilunaris than that of the external oblique, except above, where it is wide; and at this line, or the margin of the rectus, it divides into two layers: one of these passes to the linea alba in front of the rectus, united inseparably to the aponeurosis of the external oblique; the other is continued behind the rectus with the aponeurosis of the transversalis muscle, which is beneath it, to reach the linea alba, so that the muscle is enclosed in a tendinous sheath, formed in front by the one layer of the aponeurosis of the internal oblique joined to that of the external oblique, and behind by the other layer of the division, with the aponeurosis of the transversalis muscle. But the sheath has not this regular arrangement above, in consequence of the thinness of the aponeurosis, and because the transversalis muscle is fleshy beneath the rectus; and, midway between the umbilicus and pubes, the aponeurosis ceases to divide at the margin of the rectus, and the aponeuroses of all the lateral abdominal muscles pass in front of it, by which it is left without any posterior portion of sheath, and is in contact behind with the fascia transversalis, which separates it from the peritoneum. A well marked line, behind the rectus, shows the termination of its sheath: this will be perceived in the progress of the dissection. To see the division of the aponeurosis at the edge of the rectus, make an incision about two inches long into the front of its sheath, near the external border, and raise the muscle. The external oblique covers this muscle, except behind where it projects farthest, is attached to the fascia lumborum, and comes into contact with the latissimus dorsi. The upper border is attached to the thorax, and the fibres are continuous with the internal intercostal muscle:

Relations.

the lower border is fixed to the pelvis; but between Poupart's ligament, and the pectineal line of the pubes it is free and unattached, and allows the cord to pass from beneath it; it is connected to the cremaster muscle, which is continued along the cord; and as the spermatic cord lies obliquely in the wall of the abdomen, it will rest upon the conjoined tendon before it passes through the abdominal ring, although it is covered, above, by the fleshy portion of the internal oblique. Some branches of nerves and arteries perforate this muscle to supply the external oblique or the integuments, but these have been mentioned, and the parts that the muscle covers cannot be seen till it is thrown forwards.

Cremaster Muscle.

The *cremaster muscle*, named from suspending the testicle, is a fasciculus of muscular fibres, much stronger in some male subjects than in others, and is placed in contact with the lower fibres of the internal oblique muscle, from which it appears to be derived at the time of the descent of the testis. It is usually separated from the lower border of the internal oblique by a cellular interval, or its fibres may ascend beneath those of this muscle; and since it is but a portion of the internal oblique, whose fibres are drawn from a horizontal to a curved direction, it will have the same attachments internally and externally: thus it *arises* externally by a fleshy fasciculus from the inclined part of Poupart's ligament below the internal oblique: the fibres pass through the external abdominal ring, descend on the outer side of the cord, on which they extend different distances, some reaching as far as the tunica vaginalis of the testicle; they then cross the cord, giving rise to loops or arches, whose concavities look upwards, ascend along its inner side, and unite into a fasciculus, smaller than the external, which enters the abdominal ring, and ends in a tendon that is *inserted*, with the tendon of the internal oblique, into the crest of the pubes.* The muscular fibres are connected together by cellular membrane, so as to give a covering to the front of the cord and the testis, which has been named *fascia cremasterica*, in reference to a hernial protrusion which would be covered by it: in some cases this is not only placed on the front and sides of the cord, but extends around it, the testicle having descended through the fibres of the internal oblique muscle. The cremaster is usually only a prolongation of the fibres of the internal oblique, but when the transversalis arises low down from Poupart's ligament, both

Origin.

Insertion.

Relations.

* Sir A. Cooper, in his *Observations on the Structure and Diseases of the Testis*, p. 38., describes the insertion of the cremaster as the following:— "First, it forms a tendinous sling, which envelopes the lower part of the tunica vaginalis. Secondly, it sends tendinous fibres into the inferior part of the testis and epididymis, and into the tunica vaginalis. And, thirdly, it blends with some cords, which surround and enclose the lower part of the vas deferens, and which may be traced to the upper orifice of the inguinal canal, and pass down upon the spermatic vessels."

muscles are united together by their lower borders, and enter into its production. It is perforated by the inguinal branch of the ilio-inguinal or ilio-hypogastric nerve, and is covered, above the abdominal ring, by the external oblique tendon, and below, by the thin fascia spermatica derived from the margin of its opening: it rests on the cord, and the prolongation of the fascia transversalis on it. In the female, this muscle is absent; but in hernia, in this sex, it may be produced by the descent of the tumour beneath the oblique muscle. Divide this covering of the cord along its centre, and follow it down to the testicle, on which it becomes thinner: the inner fasciculus of the muscle is sometimes scarcely visible, and this may depend upon the length of the tendon by which its distance from the pubes is altered.

Dissection. Cut through the internal oblique, near its attachment to the ribs; divide it near the crest of the ilium and Poupart's ligament, connect the two incisions, behind, by a vertical one between the ribs and crest of the ilium, and throw the muscle to the middle line. A small artery, a branch of the circumflex ilii, lies between it and the transversalis along Poupart's ligament, and the front of the crest of the ilium, and is the index of the depth of the oblique. A cellular layer is, moreover, seen here as elsewhere between the muscles, and should be left down in taking up the internal oblique, since the nerves and arteries lie in it. Some branches supplying the oblique must be cut, but the last dorsal and ilio-inguinal, perforating it, should be dissected out of it. Clean the surface of the transversalis and the nerves and vessels on it.

Parts covered by the Internal Oblique. The internal oblique muscle covers the transversalis, and the numerous nerves and vessels between the two. In the lower part of the abdomen it lies on the fascia transversalis, which is usually seen below the border of the transversalis muscle, and on the cord, and prolongation sent on it from the fascia. The rectus is also covered in the middle line by this muscle, and receives a sheath from its aponeurosis.

Transversalis Muscle. The *transversalis muscle*, named from the direction of its fibres, is the third muscular layer which enters into the abdominal wall: it is attached on all sides, except below between the pubes and Poupart's ligament, and at this part it presents a free margin

Origin. which arches over the cord. It *arises* from the under surface of the cartilages of the seven lower ribs by fleshy processes which digitate with similar muscular portions of the diaphragm, and the seventh or highest lies beneath a tendinous arch between the eighth rib and the xiphoid cartilage, and is directly continuous with the fibres of the triangularis sterni muscle; also from the lumbar aponeurosis, between the last rib and crest of the ilium; below this, from the three anterior fourths of the crest, in front of the attachment of the lumbar aponeurosis to it; and from the outer third of Poupart's ligament. The upper fibres

the shortest, and the middle, the longest, pass transversely forwards, but the inferior, from Poupart's ligament, obliquely downwards, to end in front of the abdomen in an aponeurosis, which is widest below, and continues, above, with the posterior division of the aponeurosis of the internal oblique, behind the rectus muscle to join with its fellow of the opposite side in the linea alba, thus assisting to form the posterior part of the sheath of the rectus; but midway between the umbilicus and pubes, this aponeurosis, as well as the whole of that of the internal oblique, passes in front of the muscle to reach the middle line. Its lower attachment is nearly the same as that of the internal oblique to which it is united, viz. to the crest of the pubes in front of the rectus, and external to the spine of this bone to about one inch of the ilio-pectineal line, behind the insertion of Gimbernat's ligament into it; and it unites with the tendon of the internal oblique in the conjoined tendon, which is concerned in the anatomy of direct hernia, for this kind of hernia protrudes through that part of the abdominal wall across which it is stretched as a support: the portion from the transversalis forms the greater part of the conjoined tendon, is beneath that from the internal oblique, and some of its tendinous fibres are scattered on the fascia transversalis, which passes down behind Poupart's ligament. This muscle is covered by the internal and external oblique, and by the branches of the intercostal nerves and arteries to be examined after the dissection of the rectus; it lies on the fascia transversalis which separates it from the peritonæum. The lower border usually lies above the cord and the aperture by which it passes from the abdomen, round which it forms an arch, —fleshy in the outer half but tendinous in the inner; but sometimes the muscle arises as low down as the internal oblique, and covers the cord, or this may pass between its fibres. The aponeurotic portion, united with that of the internal oblique in the conjoined tendon, is also covered by the cord before this leaves the external abdominal ring. The fascia transversalis appears beneath the lower border of the muscle.

Insertion.

Relations.

The *rectus muscle* is exposed by making a vertical incision along its middle, through the aponeurosis covering it, and by throwing this to each side: some of the cutaneous nerves perforating it should be left. The pyramidalis, when present, is also dissected at the same time. The muscle, wider superiorly than inferiorly, reaches from the chest to the pelvis, and is attached, above, to the cartilages of the three last true ribs, and to the ligament between the seventh and the xiphoid cartilage. The fibres descend to give rise to a muscle which, narrowing below, is *inserted* by two tendinous processes into the crest of the pubes between its spine and symphysis. The fibres are interrupted, at intervals, by irregular or undulating tendinous intersections which cross the muscle, seldom extending its whole

Rectus Muscle.

Origin.

Insertion.

breadth or depth, and are united in front and on the outer part to the sheath. The number of these varies: if there are three, one is opposite the umbilicus, one at the xiphoid cartilage, and one between these points; if four, one is below the umbilicus; or if five, two are below; a greater number being always above the umbilicus. The rectus is contained in a sheath formed by the splitting of the aponeurosis of the internal oblique into two layers, one passing before it with the tendon of the external oblique, and one behind with the aponeurosis of the transversalis, to unite in the linea alba; but midway between the umbilicus and pubes the sheath is deficient, the muscle being covered, only in front, by the aponeuroses. The pyramidalis, when present, is superficial to this muscle, and above, the pectoralis major covers it. The inner border is separated from that of the opposite side by the linea alba and umbilicus; the outer corresponds to the linea semilunaris, and conceals the numerous branches of the intercostal nerves and arteries which enter this border. It lies on the fascia transversalis, the posterior part of its sheath, and the cartilages of the ribs to which it is attached. The epigastric and internal mammary arteries run in the sheath, the former entering it above, and the latter at the spot where it presents its lunated edge; and they anastomose in the substance of the muscle. If the rectus be turned aside in its lower half, the arched border in the back of the sheath, marking the point at which the tendons pass in front of the muscle, will be visible; but some scattered fibres generally extend lower than this margin: in doing this the nerves should not be destroyed.

Relations.

Pyramidalis Muscle. Origin.

The *pyramidalis muscle* is placed in the abdominal wall close above the pubes; but it is often absent. The muscle is wide below, and *arises* from the pubes and anterior ligament of the symphysis in front of the rectus. The fibres ascend, the internal vertically, the external obliquely, to be *inserted* into the linea alba, about midway between the umbilicus and pubes. It is contained in an aponeurotic sheath, formed in front by the tendons of the external and internal oblique, and behind by that of the transversalis interposed between it and the rectus, in front of which the pyramidalis is placed. Sometimes more than one pyramidalis is found.

Insertion. Relations.

Nerves. Abdominal portion of the Intercostal.

The *nerves* in the abdominal wall, between the internal oblique and transversalis, are, for the most part, the continuation of the intercostal of the lower spaces; and some of them should be followed back, between the intercostal muscles, to where the middle intercostal cutaneous branch leaves the trunk. The number that enter the wall are six, five coming from the five lower spaces, the last being from the last dorsal nerve, and below the last rib; a greater part of the lower than of the upper nerves is visible, because of the difference in length of the ribs. The intercostal nerves of the lower spaces, after giving off the middle cutaneous branch, run forwards to the front of the intercostal

spaces, enter the abdominal wall between the internal oblique and transversalis muscles, the upper nerves crossing the cartilages of the ribs, where they change their direction and ascend. They now extend forwards to the outer margin of the sheath of the rectus, perforate this, enter the substance of the rectus, in which each divides into branches for the muscle, and a cutaneous, which perforates it near the middle line, and is accompanied by a small artery. Sometimes a cutaneous branch is given off at the edge of the rectus, and appears on the front of the sheath to be distributed to the integuments; but the perforating branches are irregular in number and position. The last dorsal nerve differs from the others, which are named intercostal from their situation between the ribs, in position and relations; it perforates the lumbar aponeurosis, turns forwards between the internal oblique and transversalis muscles, and divides into a cutaneous and an abdominal branch: the cutaneous, the larger, perforates the two superficial muscles of the abdomen as before seen, descends over the crest of the ilium, and is distributed to the integuments over the gluteal region; the abdominal branch runs forward to the sheath of the rectus, like the abdominal portion of the other intercostal nerves, and sends down a branch to join the small ilio-inguinal nerve below it. These nerves supply the muscles of the abdominal wall.

Last Dorsal.

The *ilio-inguinal*, or *ilio-hypogastric* nerve of the lumbar plexus, perforates the transversalis muscle about the centre of the iliac crest, and gives off its cutaneous branch, which perforates the internal and external oblique, and is distributed to the integuments over the gluteal region; it then turns forwards between the internal oblique and transversalis muscles along the crest of the ilium, and divides into an abdominal and an inguinal branch: the *abdominal* runs forwards below the branch of the last dorsal, to which, near the rectus, it is united by a filament, and perforates the tendons of the internal and external oblique, to be distributed to the integuments of the inguinal region; the *inguinal* or scrotal branch communicates at the anterior superior spine of the ilium with a slender nerve from the plexus — the small musculo-cutaneous, runs inwards, parallel to Poupart's ligament, covered by the internal oblique and cremaster, perforates the cremaster, then passes through the external abdominal ring, and is distributed, as before seen, to the integuments of the scrotum, or labium of the female.

Ilio-inguinal Nerve.

Abdominal branch.

Inguinal.

The *small musculo-* or *inguino-cutaneous*, another branch of the lumbar plexus seen in the abdominal wall, perforates the transversalis muscle near the front of the crest of the ilium, and either ends by joining the inguinal branch of the ilio-inguinal nerve, or sends a filament of communication to it, and then runs below it along Poupart's ligament, leaves the abdominal ring with it, perforates the cremaster, and is distributed to the in-

Small Musculo-cutaneous.

teguments of the scrotum or labium: both this and the former nerve supply the lower part of the muscles of the abdomen.

Vessels. Abdominal portion of the Intercostal. Branch of the Circumflex Ilii.

The *arteries* accompanying these portions of the nerves are continued forwards from the intercostal: they supply the muscles between which they lie, and anastomose, near the middle line, with branches of the internal mammary and epigastric. The intercostal veins run with the arteries. Near the crest of the ilium is a small branch from the *circumflex ilii artery* beneath: it comes forward round the lower or free margin of the transversalis muscle, runs upwards parallel to Poupart's ligament between the transversalis and internal oblique, and supplies these muscles with branches. The anatomy of the trunk will be afterward seen.

Dissection.

To see the fascia transversalis, cut through the attachment of the transversalis muscle to Poupart's ligament; make a second incision through the muscle, from the crest of the ilium towards the margin of the rectus, and raise with care this lower portion of it from the fascia.

Fascia transversalis.

The *fascia transversalis*, named and described by Sir A. Cooper, is a thin aponeurotic or fibrous layer, but in some subjects so thin as to appear only like condensed cellular membrane, which is placed between the transversalis muscle and the peritonæum. Some describe it as consisting of two layers, a superficial, fibrous, now seen, and a deep or cellular, which will be perceived in dissecting, on the other side, for the membranes that form the femoral sheath. Its thickness varies much in different parts of the abdomen, since it is strong inferiorly, where it is least supported by muscles, and is moreover joined by some fibres from the tendon of the transversalis: but above this it is weak and unimportant, being continued upwards, on the inner surface of the transversalis muscle, to the diaphragm, becoming mere cellular membrane which it is difficult to dissect and follow; and internally, to the rectus, behind which it unites with that of the opposite side. In the region of the groin it is necessary to study the disposition of the fascia, because of the part that it takes in the coverings of the different herniæ. In the extent of the inner half of Poupart's ligament it is thin, and sends a layer down behind it to form part of a sheath for the femoral vessels: this is readily separated from the ligament, and is joined by some fibres from the tendon of the transversalis; but it is united to the outer half and to the crest of the ilium by a strong, firm process of a semilunar form, the concavity directed upwards, which is prolonged inwards to the pubes below the ligament, with some fibres of which it is united: the circumflex ilii artery lies beneath this portion of the fascia, having perforated the outer part of the sheath sent around the femoral vessels. Passing also through the outer part of the sheath, is the femoral branch of the genito-crural nerve, if it is not removed in the dissection of the

lower extremity. About midway between the anterior superior spinous process of the ilium and the spine of the pubes, and half an inch above Poupart's ligament, is the spot in which the spermatic cord in the male, or the round ligament in the female, traverses the fascia, — or the *internal abdominal ring*. This is no aperture with distinct margins, because a thin tubular or funnel-shaped prolongation is continued around the cord, like one of the divisions of a glove on the finger; but if the cord be pulled forwards, and this cut through, the aperture is seen to be oval in shape, the angles of it being upwards and downwards, and the outer and lower margins, stronger than the inner and upper, are bounded by the semilunar portion of the fascia. If the finger be placed on the fascia, a little to the inner side of the aperture, the epigastric artery will be felt in an injected subject, and a small portion may be cut out of the membrane to show its position on the inner side of the opening, of which it forms, as it were, the inner boundary,—the outer and upper parts of it being limited by the lower border of the transversalis muscle which winds around it. The protrusion of intestine, called, from its position to the outer side of the epigastric artery, external hernia, or, from its course in the wall of the abdomen with the cord, oblique, passes through the fascia transversalis by the internal abdominal ring. Divide the prolongation of the fascia by a vertical incision, and trace it on the cord as far as it is possible: it descends to the testicle, and terminates on the tunica vaginalis.

Internal Abdominal Ring.

Through the opening made in the fascia transversalis, the peritonæal membrane is seen to project slightly forwards, and to be connected to a fibro-cellular process which extends along the front of the cord. In the fœtus, the peritonæum was continued into the scrotum at the time of the descent of the testicle, so that the cavity of the tunica vaginalis of the testis — a prolongation only of this membrane — was one with that of the abdomen; but subsequently to the change of position of this organ, the tube of the peritonæum is obliterated between the internal abdominal ring and the testicle, and becomes a cellular cord. There is great variety in the form and condition of the remains of this process; for, sometimes, it is a fine cellular band, extending to the tunica vaginalis; at others, it reaches but a short distance on the cord, which is most frequent; or the process is wanting, and the peritonæum only projects at this part. The tube may be obliterated only at intervals, forming a sacculated cord, or one large pouch may be found in the part occupying the inguinal canal. In the adult male it may remain open in its whole extent; and in such a case, the intestine can readily pass from the cavity of the abdomen to the scrotum, giving rise to that kind of hernial protrusion called congenital hernia. In the female there is, sometimes, a cellular band on the round liga-

Peritonæum.

ment, or a small tube pervious for some short distance—the *canal of Nuck.*

Spermatic Cord. The *spermatic cord* extends from the internal abdominal ring to the testis, and consists of an artery for the supply of the testicle, veins to return the blood, an efferent duct to bring back the secretion of the organ, with nerves and lymphatics: these are united together by certain coverings derived from the different layers of the abdominal wall. The course of the cord is not straight or vertical in its whole extent; since, as the internal ring, or opening by which it enters the wall of the abdomen, is not opposite the external, by which it leaves the wall, it must pass obliquely downwards and inwards to reach its aperture of exit; but below this it is nearly vertical in direction. It thus lies in an oblique canal, the inguinal, between the abdominal muscles; and it is placed at first between the fascia transversalis and internal oblique, and in front of the epigastric artery; then, having escaped from the lower border of this muscle, it is situated between the conjoined tendon behind, and the aponeurosis of the external oblique in front; and as it is passing through the external abdominal ring, it lies in a groove of the outer pillar of this opening. The coverings that it receives have been dissected with the parts from which they are derived; thus the constituents of the cord come into contact at the internal abdominal ring, through which they pass, and are invested by a layer of the subserous cellular membrane which closely surrounds them, extends to the testicle, and varies much in different subjects, and with this may be seen the remains of the prolongation of the peritonæum; next, it receives the tube, or sheath of the fascia transversalis, named sometimes infundibuliform; then the covering of the cremaster muscle, or cremasteric fascia, from the lower border of the internal oblique muscle; after, the prolongation of the intercolumnar or spermatic fascia, from the margins of the external abdominal ring; and lastly, it is surrounded by the tubular prolongations of the superficial fascia into the scrotum, and by the skin. In the female, the inguinal canal is occupied by the round ligament, or suspensory cord of the uterus, which enters by the internal abdominal ring, and ends in the cellular membrane of the groin. Its coverings are the same as in the cord of the male, except the cremasteric, of which it is deprived.

Dissection. The cellular membrane may now be removed from the vessels and nerves of the cord, between the testicle and internal abdominal ring: to the cremasteric covering of the cord are distributed branches of the genito-crural nerve, and of the epigastric artery.

Constituents. Spermatic Artery. The *spermatic artery*, a branch of the aorta, descends, almost vertically, to the internal abdominal ring, through which it passes to join with the other vessels in the cord; it then

descends to near the testis, and divides into branches; some of these supply the vas deferens, and extend along it to the epididymis, and others enter the substance of the testicle. In the female, this artery is distributed to the ovary in the abdomen, and does not run with the round ligament. The *spermatic veins* commence in the testicle, leave it at the posterior part, receive branches from the epididymis, ascend in the cord in front of the vas deferens, and divide, and anastomose above the testicle to form the *spermatic plexus;* the branches then pass through the abdominal ring and unite into one, that of the right side opening into the ascending cava, and that of the left into the left renal vein. The *spermatic plexus* of nerves from the sympathetic in the abdomen accompanies the artery to the testicle, and perforates the posterior part of this organ. The lymphatics come from the testis and epididymis, accompany the spermatic vessels through the abdominal ring, and join the lumbar lymphatic glands. The *vas deferens* from the testis approaches the other constituents of the cord above the upper extremity of this organ, continues with them through the inguinal canal, lying posterior to them in the cord, and is easily distinguished by its wiry or whip-cord like feel. As it lies in the canal it is placed in front of the epigastric artery, separated only by the fascia transversalis, it then passes through the internal abdominal ring, internal to the spermatic vessels, turning round the outer side of the epigastric, and it finally bends down into the pelvis behind the epigastric, and along the side of the bladder to the prostate gland; but its anatomy in the abdomen will be deferred. Supplying the cremaster muscle is the *genital* branch of the genito-crural nerve, which leaves the abdomen through the internal abdominal ring, and descends to the cremaster muscle. The epigastric artery gives a *cremasteric branch* to the cord which lies over it, to be distributed to the cremaster muscle, and the coverings of the cord.*

Spermatic Veins. Plexus. Spermatic Nerves. Lymphatics. Vas deferens. Genito-crural Nerve. Cremasteric Artery.

Cut across the cord near the abdominal ring, and turn it up on the abdomen; the deep arch will be better seen from the inner side.

Dissection.

About the centre of Poupart's ligament, or from the termination of its oblique part, some fibres pass downwards and inwards to the pubes, below the level of the other fibres going to the spine and pectineal line; these are united also to the concave thickened portion of the fascia transversalis, which bounds, below, the internal abdominal ring, and is prolonged inwards beneath Poupart's ligament; thus formed, the deep arch lies in front of the femoral sheath, and, becoming wider at the pubes, is inserted into the pectineal line, on the inner or abdominal

Deep Crural Arch.

* The body of the testicle may be examined now, or its anatomy may be passed by, till the rest of the abdominal wall is completed.

surface of Gimbernat's ligament. The cremaster muscle is attached, externally, to this portion of the crural arch.

Epigastric Artery.

The *epigastric artery*, seen by removing sufficient of the fascia transversalis, arises from the external iliac, a little above Poupart's ligament. It first passes inwards and downwards over the external iliac vein, and is placed internal to the point of exit of the cord; it now changes its direction, ascends obliquely upwards and inwards between the fascia transversalis and the peritonæum, about three lines to the inner side of the internal abdominal ring, to reach the outer border of the rectus, below where its sheath is deficient; it then perforates the fascia transversalis, enters the sheath of the rectus, ascends on the posterior surface of the muscle, to about its middle, enters into its substance, and anastomoses above with the abdominal branch of the internal mammary. Previously to reaching the margin of the rectus, the vessel is covered by the fascia transversalis, and above this by the internal oblique and the transversalis muscle, as well as, superficially to these, by the external oblique; and it lies on the peritonæum; it passes behind the round ligament in the female, or the spermatic cord in the male, the vas deferens winding round its outer side, to be placed posterior to it as it descends to the pelvis. The artery forms also the outer boundary of a space, comprised between it and the rectus, in which a hernial protrusion, called internal from its position to the artery, may take place; and to the outer side of the vessel is the internal abdominal ring, through which comes the other, or external inguinal hernia.

Branches. Transverse.

The first branch that the epigastric artery gives off is a small *transverse artery*, which runs inwards behind Poupart's ligament to anastomose with the one of the opposite side behind the pubes, but this will be seen when dissecting, from within, the crural ring on the opposite side. A *communicating* branch is generally sent down into the pelvis to inosculate with the obturator artery: the next branch is the *cremasteric artery* to the coverings of the cord and cremaster muscle. In the abdominal wall the epigastric gives some *muscular branches*, and in the sheath of the rectus it divides into numerous arteries which ascend in the substance of this muscle to anastomose with the abdominal branch of the internal mammary: this anastomosis is not usually injected, because the fluid enters the vessels from two sources, and carries the coagulated blood to the midpoint of their communication, but the vessels may be followed in the fibres. Some *cutaneous* branches perforate the rectus, and accompany the cutaneous nerves to the integuments on the side of the linea alba.

Communicating.

Cremasteric.

Muscular.

Cutaneous.

Veins.

This artery is accompanied by one or two veins which open into the external iliac vein.

Abdominal

The *abdominal branch of the internal mammary artery*, with

which the epigastric anastomoses, enters the sheath of the rectus by passing beneath the cartilage of the seventh rib; it then descends external to the xiphoid cartilage, and in the sheath, to below the upper linea transversa of the rectus, enters the substance of the muscle, and joins with the epigastric, which ascends to meet it. branch of the Internal Mammary.

The *circumflex ilii artery*, the other branch of the external iliac, is partly exposed now, but it will be better seen when the fascia that covers it is removed, and this may be done either now, or in a future stage, after the abdomen is opened. It arises from the external iliac, opposite the epigastric, and whilst this vessel is contained in the tube of fascia which is prolonged around it and the femoral artery; it passes outwards, perforates the sheath of the vessels, runs parallel to Poupart's ligament, but below it, and the portion of fascia transversalis fixed to it, and it is shut out from the cavity of the abdomen by the fascia; the artery then perforates the fascia a little external to the anterior superior spinous process, and, placed beneath the transversalis muscle, runs outwards to the middle of the crest, passes through the substance of the transversalis, and is continued backwards between it and the internal oblique, along the crest of the ilium, to anastomose, at its posterior part, with the ilio-lumbar artery, a branch of the internal iliac. This artery gives, near the front of the crest, a small *ascending* branch, which passes upwards between the internal oblique and transversalis muscles, external to the epigastric artery, and supplies the muscles between which it is placed. The other branches of the artery are muscular, to the wall of the abdomen or the muscle in the iliac fossa, and anastomotic with the ilio-lumbar, gluteal, and lumbar arteries. Circumflex Iliii Artery. Branches. Ascending. Muscular.

Two *veins* run with it; these cross the external iliac artery near its termination, to join the external iliac vein which lies to its inner side. Veins.

On the opposite side of the subject, continue now with the dissection of the surgical anatomy of that part of the abdomen which has been reserved for this purpose. The skin and superficial fascia are already removed, and the two layers of the latter, and the vessels lying between them, have been seen; the tendon of the external oblique, whose fibres are directed downwards and inwards, now comes into view, and between the divergence of some of these to separate points of bone, is the aperture of the external abdominal ring, above and to the outer side of the pubes. Through it passes the cord or round ligament, which lies in the groove of the outer pillar, and prolonged from its margins is the intercolumnar or spermatic fascia: the inguinal hernia passes from the abdominal wall through this outlet, and will be covered by the fascia from its margins. Throw down the tendon of the external oblique muscle, as on the other side, Dissection for Inguinal Hernia.

or, if the muscles be undissected, by one incision from the crest of the ilium transversely to the linea alba, and another from this point to the pubes; when separating the tendon from the front of the rectus, introduce the handle of the scalpel between them, and pass this also into the abdominal ring from the inner side, to separate the fascia of the opening from the cord. The internal oblique muscle, now exposed, is fleshy to its lower margin, and the cord escapes from beneath this border, instead of through the fibres, though, occasionally, the cord may perforate them; and the fibres run downwards and inwards to a tendon which is inserted, in front of the rectus, into the crest of the pubes as far as its spine, and into the pectineal line external to this, for about half an inch: this part unites with the tendon of the transversalis beneath in the conjoined tendon. The lower fibres are prolonged on the cord, giving it a covering, the cremasteric fascia, which should be divided and raised from it to show its existence as a distinct membrane: this is absent in the female. The part of the cord now exposed is surrounded by the cremaster muscle, is inclined obliquely downwards and inwards in a part of the inguinal canal, and has in front of it the tendon of the external oblique, and behind it the conjoined tendon of the internal oblique and transversalis; it is supported below, before passing by the aperture in the tendon of the external oblique, in the groove that the fibres form by their insertion into the pectineal line behind those into the spine of the pubes. Detach the internal oblique from Poupart's ligament and the muscle beneath, and in a subject otherwise undissected, make an incision forwards from the crest of the ilium to the linea alba: the transversalis muscle, now brought into view, is closely united, sometimes inseparably so, to the oblique, but a cellular interval, and a small artery from the circumflex ilii, mark the line of separation between the two. It is observed to arise, usually, from only about the upper third of Poupart's ligament*, and to leave a space below its inferior border in which is seen the fascia transversalis. Its fibres arch downwards and inwards over the cord, to end in a tendon which is inserted into the linea alba and crest of the pubes, and unites with that of the internal oblique to be attached to the pectineal

* The attachment of this muscle to Poupart's ligament is subject to great variation; sometimes it is fixed as low as the internal oblique, covers the cord, and is connected to the cremaster; at others, lower still, and sends some fibres below as well as above the cord, so as to encircle it with muscular fibres. For a notice of the different variations in the origin and insertion of the lower parts of the internal oblique and the transversalis muscle, see *Anatomy and Surgical Treatment of Inguinal and Congenital Hernia*, fol. Lond. 1804; and *Observations on the Structure and Diseases of the Testis*, p. 36. 4to. Lond. 1830. By Sir A. Cooper. *Recherches Anatomiques sur les Hernies de l'Abdomen*, pp. 13. 23. 4to. Paris, 1817. By Cloquet: and *On some Points connected with the Anatomy and Surgery of Inguinal and Femoral Herniæ*, p. 13. 4to. Lond. 1833. By Guthrie.

line for about one inch, giving rise to the conjoined tendon of which it forms the greater share. Crossing the interval between the transversalis muscle above, and Poupart's ligament below, and covered by the fascia transversalis, is the epigastric artery, which runs upwards and inwards to the margin of the rectus, so as to limit, externally, a triangular space, the inner side of which is the margin of the rectus, and the base Poupart's ligament; a piece of fascia may be removed from the vessel as it lies on the inner side of the cord or round ligament. In the space internal to the epigastric, an internal hernia may occur, and external to it is the aperture in the fascia transversalis for the escape of the cord, and through it an external hernia may protrude. The internal abdominal ring, or aperture in the fascia transversalis, by which the cord enters the wall of the abdomen, is placed midway between the anterior superior spinous process of the ilium and the spine of the pubes, and about half an inch from Poupart's ligament; it is bounded, externally and below, by the strong process of the fascia transversalis, which is fixed to the outer half of Poupart's ligament, internally is the epigastric artery, and superiorly and internally, the lower border of the transversalis muscle, partly tendinous, and partly muscular: a prolongation is sent on the cord from the margin of the opening. Before the cord has passed the lower border of the internal oblique muscle, or in the part now seen, it is covered by the internal oblique, which is in front of it, and superficial to this is the external oblique; and it lies on the fascia transversalis.

Inguinal Canal.

In consequence of the internal abdominal ring not being opposite to the external, the cord lies in an oblique passage — the *inguinal canal*— in the wall of the abdomen, and passes from the one aperture to the other, below the borders of the internal oblique and transversalis, which are unattached in the interval between the pubes and Poupart's ligament; it communicates, above, with the cavity of the abdomen, by the internal ring, the point of entrance of the cord or hernia, and ends below in the external abdominal ring, the spot for the exit of its contents. A correct knowledge of its anatomy is necessary to direct, successfully, the manual efforts made to replace a portion of protruded intestine, or to divide the constriction which prevents its return into the cavity of the abdomen. Its direction is obliquely downwards and inwards, nearly parallel to Poupart's ligament, but a little above it; and its length, from the inner border of the internal abdominal ring to the outer border of the external, is about one inch and a half. The boundaries of the canal, which is only an interval for the cord between the different muscles or layers of the abdominal wall, will be the same as were before mentioned in speaking of the relations of the cord: thus, in the upper third, the muscular portion of the internal oblique, and the tendinous

part of the external oblique, are in front or nearer the surface, and the fascia transversalis covering the epigastric artery bounds it behind, or is next the abdomen; above, it is closed by the juxtaposition of the internal oblique and transversalis muscles, and the fascia transversalis, and below, by the union of the fascia transversalis and internal oblique with Poupart's ligament. Below the border of the oblique muscle, or in about the two lower thirds, there is only the tendon of the external oblique in front, and behind is the conjoined tendon of the internal oblique and transversalis, with a portion of the triangular fascia or ligament behind the abdominal ring, near the pubes; and beneath the conjoined tendon is the fascia transversalis, but the cord does not touch the fascia in this part: the limit to the extent upwards of this portion of the canal, is, as in the upper third, only the contact of the oblique muscles, and it can therefore be dilated in this direction to almost any extent, but below it does not admit of enlargement, and is bounded by the groove in the tendon of the external oblique, in which the cord lies, and which is formed by the fibres turning backwards and upwards to the pectineal line.

Hernia. The natural deficiency in the wall of the abdomen above the pubes, and therefore in the muscular support to the viscera contained within it, and the passage of the cord or round ligament through an aperture in the wall, predispose to a hernia or protrusion of the contents of the cavity, in the same manner as the exit of the vessels from the abdomen, below Poupart's ligament, admits the escape of the intestine with them. The intestinal protrusion in the inguinal region may enter into the abdominal parietes through any spot that is unsupported, besides passing through the internal abdominal ring with the cord, and it will occupy more or less of the inguinal canal, according as it may enter it at a higher or lower point; though all kinds of inguinal herniæ escape on the surface by the aperture of the external abdominal ring. The herniæ of the inguinal region are of two kinds, and distinguished by names which refer, either to their position to the epigastric vessel, or to their direction; thus the hernia that escapes at the internal ring and accompanies the cord, is called either external, from its position to the epigastric artery, or oblique, from its direction; and the other through another part of the abdominal wall, internal, because it is on the inner side of the epigastric, or direct, because of its protrusion, almost in a direct line, behind the external abdominal ring.*

* Other different names have been given to inguinal herniæ, and these depend, either upon its having passed certain points in the wall of the abdomen — the hernia being called imperfect whilst lodged in the canal, or perfect if it has escaped from it; if it has only passed the external abdominal ring it receives the name of bubonocele, but if it has extended into the scrotum,

The *external* or *oblique inguinal* hernia escapes from the abdomen with the cord through the internal ring, turns downwards and inwards in the inguinal canal, rendering its anterior boundary prominent, and leaves it by the external abdominal ring to descend into the scrotum. The coverings that a piece of intestine receives in traversing the canal are the same as those of the cord, since it passes by the same parts; thus, a portion of intestine, in being thrust outwards, carries before it the general lining peritonæum of the abdomen, which is the sac of the hernia, and enters into the tube of fascia transversalis surrounding the spermatic vessels; the size of the protruding intestine still increasing, it is directed by the internal oblique, which prevents it from coming forwards, to its lower border, where there is least resistance, because of the cord or round ligament having the same direction; escaped from beneath the border of the internal oblique, it will enter into the suspensory fibres of the cremaster, which gives it the cremasteric fascia; and then the hernia, still enlarging, and bound down by the tendon of the external oblique, continues downwards and inwards in the direction of the external abdominal ring through which it passes, lying usually in front of the cord, and it receives, at this point, the next covering of the intercolumnar or spermatic fascia, and in the scrotum it has in addition the superficial fascia and the skin. The coverings that will be found on this kind of hernia, after it has passed the external abdominal ring, are those of the skin, superficial fascia, spermatic and cremasteric fasciæ, the fascia transversalis, and lastly, peritonæum or sac of the hernia. In the female, the cremasteric fascia is usually absent. In a hernia that has not escaped by the external ring, the different layers that invest it will depend upon its position in the canal. The different laminæ which, in the natural state, are thin and indistinct, become thickened and very apparent on a hernia, and are readily separated from it. In the case of strangulation of the intestine, the stricture is found, in the order of frequency, first, in the internal opening or neck of the sac; secondly, in the inguinal canal, at the lower border of the internal oblique; or thirdly, in the external aperture: this last is very rare. In dividing the stricture in the neck of the sac, the incision is to be made directly upwards,

External or Oblique Inguinal.

---

the appellation of scrotal rupture or oscheocele;—or upon the condition of the prolongation of the peritonæum which accompanies the cord, for when this is unobliterated, so that the intestine protrudes in it and reaches its lower part, the term congenital hernia is employed; but if this prolongation is obliterated only in the extent of the inguinal canal, so that the hernia, descending with its own peritonæal covering, projects into the lower unclosed sac, like a viscus into a serous membrane, without being in the cavity of the sac, the hernia is named infantile.

to avoid injuring the epigastric artery which is placed to the inner side.

Anatomy of internal Inguinal Hernia.

Between the epigastric artery on the outer side, the rectus muscle on the inner, and the internal half of Poupart's ligament below, is a circumscribed space, through the lower part of which a hernial protrusion may also take place. It has been before seen, when speaking of the anatomy of external or oblique hernia, that this part forms the posterior boundary of the inguinal canal, and that the outer third of its extent is only fascia transversalis, whilst over the two inner thirds the conjoined tendon of the transversalis and internal oblique reaches to be inserted into the pectineal line. The obliterated hypogastric artery lies beneath the fascia transversalis, and extends upwards to the umbilicus, crossing the space in the line of union of the outer third, which is formed by the fascia transversalis, with the two inner thirds, covered by the conjoined tendon, so as to divide the interval into two portions, through either of which an internal hernia may pass into the inguinal canal.* On the inner side of the abdominal wall a pouch or depression of the peritonæum, on each side of the obliterated hypogastric, corresponds to the two subdivisions of the space included between the epigastric artery and margin of the rectus. Any hernia in this spot, internal to the epigastric, must carry before it or rupture the different parietal structures, since there is no aperture or tube in which it can descend, as in the external or oblique hernia.

Internal or direct Inguinal.

The *internal* or *direct inguinal hernia*, nearer the middle line than the preceding kind, passes through the abdominal wall in the part limited by the epigastric artery, rectus, and Poupart's ligament, and its course is usually direct through the abdominal parietes behind the external abdominal ring; but its direction and extent in the inguinal canal, and the coverings, will vary as it protrudes on the iliac or pubic side of the remains of the hypogastric artery; and it is therefore divided into superior, between the obliterated hypogastric and epigastric, and inferior, between this cord and the edge of the rectus. The more common kind of the direct hernia, or the inferior, occurs internal to the obliterated hypogastric, or through that portion covered by the conjoined tendon. In this case the intestine carries before it the peritonæum, which forms its sac, also the fascia transversalis which is placed external to it, but in contact with it; after this it either pushes before it the conjoined tendon, elongating it, or, as takes place in sudden ruptures, the fibres separate and

Inferior.

* The position of this vessel is very variable. Cloquet says, that it is most frequently placed behind the epigastric. See *Recherches Anatomiques sur les Hernies de l'Abdomen*, note to page 89. In such a case there will be but one hernia on its inner side.

allow it to pass between them; situated, now, opposite the external abdominal ring, it passes through this, lying to the pubic side of the cord, receives the fascia spermatica, then enters the scrotum, and is covered by the superficial fascia and the skin: so that when this hernia is complete, it is covered, proceeding from without inwards, by the skin, superficial fascia, spermatic fascia, sometimes the conjoined tendon, fascia transversalis, and lastly the peritonæum or sac. This species of internal hernia is altogether removed from the epigastric artery, and strangulation of it may be either in the neck of the sac, at the aperture of the conjoined tendon when it is ruptured, or at the external abdominal ring: in dividing it, the incision should be directed upwards. The other internal hernia, or the superior, whose existence depends upon the position of the hypogastric cord, is less frequent, has fewer claims to the term direct, since it passes through the portion of the space on the outer side of the remains of the hypogastric artery and close to the epigastric, descends through nearly the whole of the inguinal canal, and is covered also by the cremaster.* This hernia, enveloped by its peritonæal investment, pushes before it the fascia transversalis, in the interval between the epigastric artery on the outer side, and the obliterated hypogastric on the inner, enters now beneath the cremaster, descends in the inguinal canal, passes through the external abdominal ring, and is covered by the spermatic and superficial fasciæ, and by the integuments, as the other kind; it has the same number of coverings as the external, is nearly as oblique in direction, and is difficult to be distinguished from it. In dividing the stricture in the neck of the sac, it must be remembered that the epigastric artery is on the outer side, but very near to it, and the incision is therefore to be made upwards. The direction to divide the stricture upwards should be adhered to in all instances, since, in consequence of the internal abdominal ring being so moveable as to be carried inwards by a large external hernia until it is impossible to distinguish whether the protrusion at the first was an external or an internal one, a deviation from the upright direction, in a tumour, whose nature is doubtful, might be attended by the division of the artery.

Superior.

Open the abdomen by a transverse incision through the umbilicus, hold up the lower flap, and certain elevations ascending towards the umbilicus will appear on the inner side; these are better seen if the muscles have not been dissected.

Dissection.

In the middle line is the prominence of the remains of the urachus, which reaches from the summit of the bladder to the umbilicus; on each side of it, and extending from the side of

Projections on the inner surface of the Wall.

* "The sac of the internal inguinal hernia sometimes passes between the sheath of the spermatic vessels, and the cremaster muscle which is then found in front of it." Cloquet, *Recherches Anatomiques, &c.*, proposition xxxviii. See also xxxiv. and lii.

the pelvis to the same spot, is the obliterated hypogastric artery, which projects more than the former from the wall of the abdomen, is covered by the peritonæum which forms a hollow or depression on each side of it, and its most prominent part is in the inguinal region, for near the bladder it is oftentimes mere cellular membrane; in some instances it is directly behind the epigastric, and there is, therefore, only one cord on each side; or it may come from the apex of the bladder to the umbilicus. External to this cord, on each side, is the prominent line of the epigastric artery, and in an injected subject this is more marked; its direction is to the margin of the rectus muscle.

Pouches of the Perito-næum.

The peritonæum, which lines the interior of the abdomen, presents, opposite the inguinal region, two pouches on each side, the one being between the urachus and obliterated hypogastric artery, and the other external to the remains of this vessel. The internal, the smallest, extends lower than the other, is opposite to that part of the abdomen which, in the triangular space for an internal hernia, is supported by the conjoined tendon; and in this fossa or depression the more common form of internal hernia escapes from the abdomen. The pouch external to the hypogastric artery is larger than the other, does not reach so low down, and is divided into two by the epigastric artery: the one internal to this vessel, or between it and the obliterated hypogastric, corresponds to the upper third of the inguinal canal, and receives the superior internal hernia, or that form which is less common, and is covered by the cremaster muscle; and the depression on the outer side of the epigastric marks the position of the internal abdominal ring, and at this point the external hernia commences. When the hypogastric artery is behind the epigastric, there can be but two fossæ. The existence of the fossæ predisposes to herniæ, and when these occur in the inguinal region the protrusion takes place in one of the depressions of the peritonæum.

Dissection.

Divide this half of the abdominal wall by an incision, in the centre, from the umbilicus to the pubes, and dissect the membranes which form the femoral sheath, on the side in which inguinal hernia has been studied. Remove the peritonæum from the inguinal region and iliac fossa, and the cord or round ligament is seen to leave the abdomen by perforating the fascia transversalis; cut it across: between the peritonæum, and the fibrous layer of the fascia transversalis, which gives a covering to the cord, is the thin cellular portion of the same fascia, which can be separated from the other as a distinct membrane, for about two inches above Poupart's ligament, and, if followed down to the iliac vessels, is found to be stretched across an interval — the crural ring — on their inner side, and covers an inguinal gland. Raise it from its position; the other layer is seen to be united along the outer half of Poupart's ligament to a strong

fascia lining the iliac fossa, but between this point and the pubes it passes beneath the ligament, forming the anterior part of a membranous investment for the femoral vessels, or the femoral sheath. In the iliac fossa is the strong iliac fascia that forms the posterior part of the same sheath by being continued down beneath the vessels, and unites with the fascia transversalis external to them. Take away any cellular membrane that occupies the upper part of the femoral sheath, so as more distinctly to see this structure; on the iliac artery is the genito-crural nerve, and crossing it are the circumflex ilii veins; and the inguinal gland on its inner side may be removed or turned aside. The sheath is commonly destroyed by the dissectors of the lower extremities, before it can be traced from the inner surface of the abdomen.

The *fascia transversalis*, before partly seen to form a fibro-membranous lining for the inner surface of the abdominal wall, is divided by some * into two layers, a cellular and fibrous. The *cellular layer* † varies much in thickness in different subjects, and is more readily separated from the fibrous layer, over and external to the vessels, than behind the pubes; it is now detached from the other, and from the upper part of the sheath, over which it is extended, instead of descending into it around the vessels. In the interval between the femoral vein and Gimbernat's ligament, it covers an inguinal gland, is connected to some cellular membrane around the vessels and forms what has been named by Cloquet the "*septum crurale*," or cellular partition extended across the upper aperture of the crural canal: the upper surface of this is concave, the lower convex towards the thigh; it is perforated by apertures for the ducts of the inguinal glands, and sometimes a gland is placed in one of them. The *fibrous layer* enters into the formation of the femoral sheath, is strongest in the inguinal region, and is also thin and cellular, as before seen, when followed upwards beneath the transversalis muscle. It is connected, below, to the pubes, with the insertion of Gimbernat's ligament; and along the line of Poupart's ligament it is united, in the outer half, to the fascia iliaca, but passes beneath it in the inner, to form the anterior part of the sheath which surrounds the femoral vessels, and resembles that sent around the spermatic cord or round ligament.

Fascia transversalis.

Cellular layer.

Fibrous.

The *fascia iliaca*, which will be subsequently examined, occupies the iliac fossa and covers the iliacus muscle; it consists of strong transverse fibres, is attached externally to the crest of the ilium; internally to the line of the pelvis; above, it is thin and

Fascia iliaca.

* See Cloquet, *Recherches Anatomiques sur les Hernies de l'Abdomen*; and Guthrie, *On some Points connected with the Anatomy and Surgery of Inguinal and Femoral Herniæ*.

† Or subserous cellular membrane, or fascia propria of the French.

weak, and is prolonged on the wall; below, it is joined, external to the femoral vessels, to the fascia transversalis along the line of Poupart's ligament, but internal to this, their presence prevents its coming forwards, and it is directed downwards to the thigh to form the posterior portion of the femoral sheath; so that, by the union of these fasciæ, the space beneath the crural arch is closed, except in the portion occupied by the tubular sheath derived from them, which contains the femoral vessels.

Femoral Sheath.

The *femoral sheath*, or tube of membrane which surrounds the vessels entering the thigh, is formed, in front, by a prolongation from the fascia transversalis, and behind, by that from the iliac: it is not entirely filled by the artery and vein, but a space — the *crural ring*, or entrance to the portion unoccupied by them — is found between the vein and Gimbernat's ligament. The boundaries of this interval, which is about half an inch wide, are, in front, Poupart's ligament and the deep crural arch; behind, the pubes and pectineal portion of the fascia lata; internally, Gimbernat's ligament; and externally, the femoral vein, from which it is separated by a thin process of membrane. Along its front is a small artery from the epigastric, and its vein, which run to the posterior part of the pubes; the spermatic cord in the male, or round ligament in the female, is placed above and in front of it; and the epigastric vein, and farther out, the epigastric artery, cross also the upper and outer angle of the aperture, so that the ring is surrounded by vessels on all sides, except behind and internally; but in the cases of variety in the origin of the obturator artery from the epigastric, a vessel may be placed even on its inner side, for this vessel may either pass on the outer part close to the vein, or it may arch along the anterior and inner boundary near to Gimbernat's ligament, to reach the obturator foramen which is situated below. The position of the artery on the outer side of the ring is the most frequent and least dangerous; but when it follows the other course, the ring is altogether encircled by vessels, except posteriorly, and the artery surrounding the neck of the sac, above and internally is very liable to be divided in an operation, when directing the knife inwards to remove the constricting part in the neck of the sac.

Crural Ring.

Femoral Hernia.

Femoral or *crural hernia* leaves the abdomen below Poupart's ligament, — inguinal being above it. The close connection of the fasciæ lining the abdominal wall, to the outer half of the ligament and to the fascia lata, prevents the protrusion of intestine at this spot, and it is therefore in the part occupied by the sheath of the vessels that the hernia descends. The hernia leaves the abdomen by the space in the aperture of the femoral sheath, or by the crural ring, descends in its canal, or in the part of the tube internal to the vein, and escapes by its external aperture or the saphenous opening. A portion of in-

testine protruding, receives a general covering of peritonæum from the abdomen, then reaches the septum crurale, which is either elongated before it, or allows it to pass through one of its apertures; the gland is next absorbed or moved from its position, and the tumour, continuing to descend, carries before it, through the saphenous opening, the inner side of the sheath, as well as the cribriform fascia, which is extended across the aperture, and is fixed to its margins, and it lastly receives the coverings of the superficial parts; but the dissection of the thigh, with that of the saphenous opening, may be referred to for these facts. As stricture may take place in the neck of the sac, too much attention cannot be given to obtain an accurate knowledge of the position of the vessels around the crural ring; since, in directing the knife to one point or another of its circumference, to divide the stricture, some vessel may be wounded. The direction of the incision to release the stricture, is not determined so unanimously as in the inguinal hernia; some recommending that it should be made inwards, by which alone the strangulation is removed, and the obturator artery will be divided only in those rare cases of the occurrence of the variety on the inner side of the sac; but others advise that the knife should be carried upwards and inwards, by which the attachment of the femoral ligament to Gimbernat's — the more frequent seat of constriction — is cut through, and the probability of wounding the cord diminished more than in the incision directly upwards for the same purpose.

Dissection of the Testis.

The anatomy of the testis may be studied before the abdomen, and for this purpose cut across the cord, and remove it from the scrotum; follow the vessels to the posterior part of the testis, between the reflections of the tunica vaginalis or serous membrane, which may be inflated.

Tunica vaginalis.

The *tunica vaginalis* is a serous membrane, which, in fœtal life, was continuous with the prolongation of the peritonæum from the cavity of the abdomen, in front of the cord, but the communication with this cavity is afterward destroyed by the obliteration of the connecting tube; like other serous membranes, it is reflected over the testicle which is external to its cavity, and also on the coverings of the cord; it is smooth in its interior, and secretes a thin vapour which lubricates the surfaces, but, when increased in quantity, collects in the cavity, and forms the disease of hydrocele. The portion of the sac which covers the testis is the *visceral* or reflected layer, it is closely or inseparably united to the proper fibrous coat of this body, and continues upwards on the cord to a variable height. On the outer side it projects between the testis, and the epididymis which is placed as an arch on this organ, so as to separate one from the other, the two extremities of the epididymis being attached, at the same time, by the serous mem-

brane reflected over them; it does not extend so far back on the inner surface, and the spermatic vessels entering the testis intervene between it and the epididymis. The layer of membrane lining the coverings of the cord, or the *parietal*, is more extensive than the other, and projects downwards and upwards beyond the testis, but higher on the inner than the outer side, so that when the cavity is distended with air or water, this organ is placed behind it about two thirds down: open it, to see its interior, and remove it from the testis.

The Testes. The *testes*, two in number, are the glandular organs for the secretion of the semen, and are situated in the scrotum, being suspended by the cord and its envelopes. Each is oval in shape, slightly flattened on the sides, and suspended obliquely, the upper part being directed upwards and outwards, and the lower downwards and inwards; the anterior border is convex, and covered by the tunica vaginalis, the posterior is flatter, and is perforated by the vessels; its vertical measurement is about one inch and a half, and the transverse about eight lines. Along the posterior part of the testis, and extending from the upper to the lower extremity, is the epididymis, or the convoluted excretory duct. Occasionally, only one testis will be found in the scrotum, the other not having descended from the cavity of the abdomen; the left is frequently larger than the right, and is suspended below its level: by which these bodies escape compression.

Dissection. Place the testis on its outer side, or on that on which the epididymis is situated, fix it by some pins through the fibrous coat near the anterior part; make an incision through this covering and raise it backwards from the convex border, to where the vessels enter; some very delicate laminæ or septa will be seen to pass into the substance of the testis, dividing it into compartments, in which lie the convoluted seminiferal tubes. These septa are to be followed back to the centre, where they join a prolongation of the fibrous membrane: great care must be taken in removing the tubes, not to injure the septa: this may be done with greater ease under a current of water.

Tunica albuginea. The *tunica albuginea* or *fibrous* coat of the testis is white, inelastic, resembles the sclerotic coat of the eye, and many small veins ramify in it. It is dense and fibrous, determines the form of the testis, and at the upper and posterior parts sends a portion inwards with the blood-vessels which perforate it; this prolongation of the membrane, called *corpus Highmorianum* or *mediastinum testis*, is a white fibrous process, which projects into the testis for the extent of a few lines, is wider above than below, and contains in its substance, the vessels, nerves, and ducts of the testis; to its sides are attached, also, the septa between the seminiferal tubes. The outer surface is in contact with the serous membrane, except in the interval, at the posterior part, for the pas-

Mediastinum.

sage of the vessels; and where the epididymis is placed. The inner is in relation with the seminiferal tubes, and from it pass two sets of processes; one round, cord-like, project upwards and backwards, from different parts of the fibrous covering to the corpus Highmori, supporting the form of the organ; the other consists of thin delicate membranous septa, which are longest at the upper part of the testicle, pass backwards also to the mediastinum, and divide the cavity of the tunica albuginea into many compartments for the seminiferous tubes.

Tunica vasculosa.

Lining the interior of the different compartments of the testis is a thin delicate vascular layer, the *tunica vasculosa* of Sir A. Cooper, which results from the union, by cellular membrane, of the extreme ramifications of the vessels before they are distributed to the seminiferal tubes lodged in the compartments.

Structure. Tubuli seminiferi. Lobules.

The glandular or secreting portion of the testis consists of long convoluted tubes, the *tubuli seminiferi*, which are contained in the spaces between the septa, giving rise to the lobules of this organ; each *lobule* presents a conical form, the base to the circumference, and the apex to the corpus Highmori, and each may contain one, two, or more seminiferal tubes which present a free extremity, and anastomose with each other, according to Lauth, many times. The tubes are convoluted in their course, and Lauth reckons the number at 840, and the length of each at two feet three inches; but Monro says the length of each is sixteen feet. When they approach the mediastinum, they unite together, forming tubes of greater diameter—the vasa recta, which become straight about two lines before perforating this fibrous process to enter between its layers. The *vasa recta* about twenty in number, enter into the fibrous structure of the corpus Highmori, and, situated in its anterior part, in front of the vessels, run upwards, anastomosing together to form the *rete testis*, from which issue, above, the *vasa efferentia* or *coni vasculosi*, which, from nine to thirty in number, are larger than the other tubes, of which they are a continuation; and, at first straight, become convoluted before joining the epididymis. The *arteries* of the testis perforate between the layers of the mediastinum, divide into branches that are accompanied by the nerves, and end in the tunica vasculosa, to be distributed on the walls of the small seminiferal canals: the vessels are behind the rete testis in the corpus Highmori. The *veins* commence at the termination of the arteries in the testis, pass from this organ at the posterior part, and have been seen in the cord.

Vasa recta. Rete Testis. Coni vasculosi. Vessels.

Epididymis.

The *epididymis*, named from its position, extends in an arched manner from the upper to the lower extremity of the testicle, and is situated external to the entrance of the vessels; the upper part is closely united to the testis by the vasa efferentia, which will be seen by taking away the tunica vaginalis, and turn-

ing aside the epididymis; the lower end is attached also to the testis, but only by the reflection of the serous membrane, and the central part is separated by a pouch of the tunica vaginalis which projects between them. It is enlarged above, and forms the head or *globus major*, it terminates at the lower part of the testis in the tail or *globus minor*, which ends in the vas deferens, and the intervening portion of the epididymis along the testis is called the *body*. When the cellular and serous membranes are removed from this body, it will be seen to be formed by a single tube very much convoluted, the turnings of which are united together by cellular structure; and by its upper part it receives the vasa efferentia which open into it at different distances. The *vas deferens*, or excretory tube of the testis, is a continuation of the epididymis; it commences at the globus minor, is at first slightly convoluted, runs upwards along the inner side of the testis and epididymis, with the spermatic vessels, and its course and relations in the cord have been seen; it then passes through the internal abdominal ring, and along the side of the bladder, and passes through the prostate to open into the part of the urethra contained in this gland.

Vas deferens.

Vasculum aberrans.

In the angle of union of the vas deferens and the epididymis is sometimes found a small cæcal appendage to this tube, or the *vasculum aberrans* of Haller. Its length when unravelled is from one to fourteen inches, it is wider at its closed extremity than at the other, and opens either into the termination of the epididymis, or the commencement of the vas deferens. Its use is unknown.

Attached to the upper part of the testis, in front of the epididymis, is a small conical body whose use and nature are not ascertained. Its shape and size vary much.

Complete the opening of the abdomen by an incision carried up to the xiphoid cartilage, rather on the left side of the linea alba, and throw back the flaps.

DISSECTION OF THE CAVITY OF THE ABDOMEN.

Abdomen.

The abdomen, the largest cavity* in the body, is of an oval shape, the greatest measurement being from above downwards; and it contains the digestive apparatus, the urinary, and part of the generative organs, with the vessels, nerves, and lymphatics connected with them, and with the lower extremities, these last

* Although there is no cavity during life, since the viscera completely fill what appears, when dissecting it, to be a space, the term is employed in accordance with the commonly received nomenclature.

being continued upwards into the cavity, or through it to the thorax. It is limited above by the arch of the diaphragm, below by the pelvis, and the structures that close the outlet of this part; in front and on the sides are the abdominal muscles, and behind is the spine, with the psoas and quadratus lumborum muscles on each side. The space within is wider in the upper than in the lower part, and is sometimes divided into the cavity of the abdomen, which reaches to the brim of the true pelvis; and into that of the pelvis, which is situated below, and contains more especially the generative and urinary organs. The portion above the pelvis is moreover artificially separated into regions by imaginary lines crossing it in different directions; thus one carried round the body, opposite the projection of the cartilage of the ninth rib, marks off the *epigastric* above it; and a second circular line, on a level with the most prominent point of the crest of the ilium, divides the remaining part into *hypogastric*, below, and *umbilical* region, between it and the epigastric; and by drawing, on each side, a vertical line from the ninth rib to the anterior superior spine of the crest of the ilium, each of the regions is subdivided into three, the lateral portions of the upper or epigastric being called right and left *hypochondriac*, the centre still retaining the appellation of epigastric, or *scrobiculus cordis;* the middle zone or circle is composed of umbilical in the centre, and right and left *lumbar* on the sides; and the lower circle consists, in like manner, of hypogastric in the centre, and the lateral parts are the right and left *iliac* regions. The regions of this lower circle have been sometimes again distinguished by the lower part of the hypogastric being named *pubic*, and the lower portion of the iliac, right or left *inguinal* region.

Divisions. Regions. Epigastric. Hypogastric. Umbilical. Hypochondriac. Lumbar. Iliac. Pubic. Inguinal.

The abdomen, like the chest, is lined by a serous membrane,—the peritonæum,—which is reflected around the viscera, and in the portion above the pelvis is contained the digestive apparatus, which consists of the alimentary tube or canal, and its appendages assisting in the function of digestion; together with the kidneys, which belong to the urinary organs, and are situated in the lumbar regions. From the manifest variety in the form of the different portions of the tube or canal have arisen the divisions of it into stomach or dilated cavity, into which the food is received, and in which digestion or chymification takes place; into small intestine (intestinum tenue) in which chylification and absorption of nutritive matter go on; and into large intestine (intestinum crassum), which continues the tube to the exterior, and in which the ingesta of the body acquire their excrementitious character or fæcal odour. The small intestine has been again subdivided into duodenum, which extends from the right extremity of the stomach to the convolutions of the small intestine on the left side of the spine; and into jejunum and

Contents. Divisions of the Alimentary Canal.

ilium*, which continue it to the large, which it joins in the right iliac region. The large intestine has been named, from its size, cœcum, or caput cœcum coli, which is the commencement of the colon or large intestine, and is joined by the small; or from its course, right ascending, transverse, and descending colon, with the sigmoid flexure, a remarkable turn in the left iliac fossa, and rectum or termination of the tube, which is continued through the cavity of the pelvis. The appendages to the alimentary tube, or the accessories to the function of digestion, are, the liver, the pancreas, and the spleen.

Parts in contact with the Wall.

When a healthy abdomen is opened, the following are the parts that present themselves:—On the right side, above, is the liver, with the remains of the umbilical vein ascending to it from the umbilicus; on the left, the stomach and spleen, the stomach being overlapped by the liver at its right extremity; from the great curvature of the stomach descends a fold of peritonæum,—the great omentum,—enclosing within its layers the transverse part of the great intestine, or the transverse arch of the colon, together with cellular membrane and vessels; and it reaches to the lower part of the abdomen or to the pelvis, so as nearly to conceal the whole of the small and large intestines. This process of the peritonæum is found, in some subjects, folded upwards in the left hypochondriac region, leaving the whole of the remainder of the intestines in contact with the wall, and exposed to view when this is cut through. If the bladder be distended, a slight part of it may be seen below against the wall of the pelvis. The relations of the viscera to the different regions, and to each other, are to be next examined.

Relations of the Stomach.

The *stomach*, or upper portion of the alimentary tube in the abdomen, intervenes between the œsophagus and duodenum, is situated in the left hypochondriac region, and crosses the epigastric to the right hypochondriac; and it is maintained in its position by the folds of the peritonæum attached to its upper part and left extremity, and by the union, at the ends, with the œsophagus and the duodenum. When it is empty, or nearly so, the surfaces look forwards and backwards, and the borders upwards and downwards; but when it is distended with food or air, they look upwards and downwards, and the borders backwards and forwards. The anterior surface is in contact with the diaphragm, which separates it from the five or six lower ribs, and from the cavity of the chest; with the abdominal wall in the epigastric region, and with the liver which slightly overlaps the right extremity: the extent of the relations of this will vary with the state of distention or collapse of the organ. The upper border has attached to it a fold of peritonæum, or serous membrane,

* The term duodenum has been applied, because this part measures about twelve fingers' breadth; jejunum, because it is usually found empty; and ilium, since it chiefly occupies the left iliac fossa.

— the small omentum, or gastro-hepatic omentum, — extended between the liver and stomach; it looks upwards when the organ is empty, but when distended, almost backwards towards the spine, and receives between its extremities the posterior fleshy attachment or pillars of the diaphragm, and the artery of the cœliac axis that arises from the aorta. The lower border, much larger and longer than the upper, is convex, and has attached to it another fold of the peritonæum, or the great omentum or epiploon, which contains, as the small omentum, vessels between its layers; below it, and extended transversely across the abdomen, is the transverse colon, and it is in contact with the wall of the abdomen and cartilages of the last ribs; but this relation varies with the dilatation, since the border is directed altogether forwards when the stomach is full. The posterior surface cannot now be seen, but it has behind it the pancreas, the pillars of the diaphragm, the aorta, left kidney, and the solar plexus of nerves; it looks down to the transverse meso-colon and the last part of the duodenum when the stomach is rotated upon its extremities by fulness. The left end occupies the left hypochondrium, and is in relation with the spleen, to which it is united by a fold of peritonæum, or the splenic omentum containing vessels; when it is enlarged, it pushes the diaphragm upwards, and encroaches on the lung of this side; and the right end or extremity reaches to the gall-bladder of the liver, is in contact with the liver above, and in front with the wall of the abdomen. The position of the stomach may be varied by the enlargement of any organ surrounding it; it may be dragged down by the traction of the great omentum which has passed from the cavity of the abdomen into a hernia, or it may be forced down by tight stays, which constrict and diminish the natural space for it: the right extremity being more moveable than the left, departs most from the normal position.

The upper part of the small intestine or duodenum cannot well be seen now, since it is concealed by the ascending colon and peritonæum; it will therefore be examined afterwards.

Relations of the Jejunum and Ilium.

The *jejunum* and *ilium*, or remaining portion of the small intestine, commence on the left side of the spine or aorta, opposite the second lumbar vertebra, without any mark of separation between them and the duodenum, and are continued through numerous coils and convolutions to the cœcum or caput coli in the right iliac fossa; they occupy by their circumvolutions the umbilical, hypogastric, right and left iliac, and lumbar regions, and descend more or less into the cavity of the pelvis, behind the bladder and uterus; the two upper fifths of the tube are referred to the jejunum, and the three lower fifths to the ilium. Surrounding the small intestine is the colon, the descending portion of which is more covered by it than the ascending, since the jejunum and ilium are directed over to the left side of the body.

In front of the convolutions is the floating omentum, and bounding them, above, is a septum of the peritonæum—the transverse meso-colon—attaching the transverse colon to the spine; they are fixed by the mesentery, and the artery that supplies them, to the spine, in a line extended obliquely downwards from the left side of the body of the second lumbar vertebra to the right sacro-iliac junction; but their anterior surface is convex, free, and in contact with the epiploon, or wall of the abdomen. In hernia this intestine will descend into the cavity of the sac far from its natural position.

Great Intestine.

The *large intestine* or *colon* * the continuation of the alimentary tube, begins in the right iliac fossa, in a dilated extremity or head, the caput coli or cœcum; it then ascends to the liver through the right iliac, lumbar, and hypochondriac regions, makes a turn, crosses the abdomen below the stomach, lying between the epigastric and umbilical regions, or more commonly in the latter, to reach the left hypochondriac, below the spleen. At this part it is curved downwards, and descends through the same regions on the left side as it occupied on the right, forms in the left iliac region the sigmoid flexure, and ends, opposite the brim of the pelvis, in the rectum which is placed in this cavity, and will be seen with its contents. Its course resembles an arch whose concavity looks downwards, and it surrounds the small intestine; it is sacculated in appearance, and is less moveable than the small intestine, being retained in position by folds of the peritonæum.

Relations of the Cœcum.

The *cœcum* or *caput coli*, the sacculated and dilated commencement of the colon, with which it is continuous above,—there being no line of separation between the two,—is situated in the right iliac fossa, in which it is bound down by the peritonæum stretched over it so as to cover only the superficial surface. In front of it, when not distended, are the convolutions of the small intestine, but when it is prominent it comes into contact with the abdominal wall; behind the cœcum is much loose cellular membrane separating it from the iliac fascia; internally, it is joined by the termination of the ilium,—a valve limiting, within, the extent of the small intestine. The lower part is roundish, and has appended to its inner side the vermiform appendix.

Of the Ascending Colon.

The *ascending* or *right colon* reaches from the cœcum to the turn below the liver, and touches the under surface of the right lobe of this viscus, to the right of the gall-bladder. It is fixed to the wall, external to the position of the kidney and duodenum, by the peritonæum, which does not surround more than two thirds of its circumference. The convolutions of the small intestine are to its inner side, and in front of it, except

* If this is very flaccid, its relations will be better seen by moderately distending it with air introduced through the termination of the ilium.

when it is dilated, and reaches the abdominal wall; it lies over the quadratus lumborum muscle, cellular membrane and the fascia of its sheath only intervening; and above, on the right kidney, the posterior surface being uncovered by peritonæum. On its inner side is the psoas muscle, with the convolutions of the small intestine, and the middle or descending portion of the duodenum lies also internal to it.

Of the Transverse Colon.

The *transverse colon* reaches obliquely upwards and to the left side along the curvature of the stomach, from the lower surface of the right lobe of the liver to the under part of the spleen, being fixed to the abdominal wall by a fold of peritonæum — the transverse meso-colon — which separates the small intestines from the stomach, liver, spleen, and pancreas above; and it may be seen by raising the transverse colon on the margin of the ribs. In front of this portion of the colon is the free floating fold of the omentum, separating it from the wall of the abdomen; behind, is the descending portion of the duodenum, which it crosses, together with the transverse meso-colon, and it is placed superficially to the third portion of the duodenum, but separated by the superior mesenteric vessels and the peritonæum; below, are the convolutions of the small intestine, and above, the liver with its gall-bladder, the superior transverse portion of the duodenum, the stomach, and the spleen. Small processes of the peritonæum containing fat — the appendices epiploïcæ — are attached to it. This portion of the intestine is very moveable, and liable to alter its relations.

Of the Descending Colon.

The *descending colon* commences at the second turn of the colon below the spleen, and reaches to the sigmoid flexure; it is fixed, like the right, by the peritonæum which encloses a smaller portion of its tube, and it is smaller in diameter than the right. The convolutions of the small intestine are more in front of it than on the right side, and its upper part lies deeply in the left hypochondriac region; it rests on the kidney and quadratus lumborum muscle; and to the inner side is the small intestine.

Of the Sigmoid Flexure.

The *sigmoid flexure* of the colon is situated in the left iliac fossa, being limited above by the crest of the ilium, below by the sacro-iliac junction, and it is attached by a fold of peritonæum, — the sigmoid meso-colon. The intestine makes two turns, like the letter S (whence its name), but its position is often more or less in the cavity of the pelvis. It is covered by the small intestine, it lies on the iliacus muscle and its fascia, crosses the iliac vessels, and ends in the rectum.

Rectum.

The *rectum* continues downwards into the pelvis, being nearly uniform in shape, and it will be examined with the contents of this cavity.

Relations of the Liver.

The *liver* is the large glandular organ for the secretion of the bile which is passed into the duodenum; it is situated in the

right hypochondriac region, part of the epigastric, and sometimes it reaches to the left hypochondriac; some folds of the peritonæum retain it in its natural position, and these have been named ligaments, there being a suspensory in the middle line, and a lateral one on each side, which fix it to the diaphragm. The upper surface, convex, is in contact with the under part of the diaphragm, and the falciform ligament extends along it; it projects upwards into the cavity of the chest, being separated only by the diaphragm from the base of the right lung, which is moulded upon it, and it corresponds to the six or seven lower ribs of the right side. In the epigastric region, it is also in contact with the abdominal wall below the borders of the ribs, but the extent of this relation depends upon the size of the liver; in the fœtus, much of this surface reaches the wall. The under surface is in contact with the right extremity of the stomach, with the upper angle of the ascending colon, with the duodenum, and behind this with the right kidney: a process of peritonæum — the small omentum — descends from it to the upper border of the stomach, and contains the vessels which enter the liver. The anterior border, thin, projects beyond the margin of the thorax, and is to be felt in the erect position of the body by the fingers introduced beneath the ribs: the gall-bladder extends beyond it against the abdominal wall. The posterior border may be observed, by pulling the liver forwards, to be thick and round, and it lies on the crura of the diaphragm, on the spine, also on the vena cava and aorta; the lateral ligaments attach this part to the diaphragm, but they are connected rather to the upper surface, near this border, than to the border itself. The relations of the liver to the surrounding parts may be altered by disease, by enlargement of any tumour, or collection of fluid in the thorax or abdomen, the former pushing it downwards, and the latter upwards; or it may be altered in a state of health by respiration, which changes the condition of the diaphragm and liver; by the upright position, in which it descends; or by the horizontal, when it is carried backwards and upwards within the margin of the thorax.

Of the Spleen.

The *spleen* is situated deeply in the left hypochondriac region, and to see it the left extremity of the stomach must be pulled forwards; it is retained in its position, like the other viscera, by folds of the peritonæum, one — the splenic omentum — which contains its vessels, attaching it to the left extremity of the stomach, and it is also fixed to the diaphragm by the peritonæum reflected on it from this boundary of the abdomen. Its position, in the empty state of the stomach, is vertical; the outer surface, convex, corresponds to the diaphragm, and the two or three last ribs; the inner, concave, is applied to the stomach, has attached to it the splenic omentum and its vessels, and is also in contact with the left extremity of the pancreas; below it is the kidney.

When the stomach is distended, the spleen is in close apposition with it, and is placed on the posterior part of its left extremity. The relative anatomy of the pancreas and duodenum will be omitted now, because their examination would interfere with the anatomy of the peritonæum, but, if it is wished, they may be referred to.

Relations of the Kidney.

The *kidney* or organ for the secretion of urine, is to be examined on the left side, since to expose the right, would destroy the relative anatomy of the duodenum: raise the descending colon from the wall of the abdomen, together with its peritonæum. This viscus is surrounded by much fat, is situated in the lumbar region, on the side of the vertebral column, occupying the space of about the last dorsal, and the two or three upper lumbar vertebræ; the right is lower than the left, because of the position of the liver. The peritonæum touches the upper part of each kidney, is separated from it below, by the layer of cellular membrane, and it covers more of the right than of the left; it assists in retaining this organ in its position. The anterior surface of the left is in contact with the descending colon which is destitute, behind, of peritonæum, and above, the spleen is placed in front of it; and that of the right, with the ascending colon, and a small portion of the duodenum: the posterior surface rests on the psoas, on the quadratus lumborum, and anterior layer of fascia which forms its sheath, and on the diaphragm which intervenes between it and the two last ribs. Above the left is the spleen, but above the right the liver; and below each is the crest of the ilium. The inner border looks to the spine and receives the vessels; but, on the right side, it is parallel to the duodenum. The supra-renal capsule is placed on its upper part. One or both kidneys may be found, out of their natural position, in the cavity of the pelvis, or the two may be united in front of the aorta.

The relative anatomy of the remaining urinary organs, and the generative, will be considered with that of the pelvis.

Peritonæum.

The *peritonæum,* or serous membrane of the cavity of the abdomen, is now to be traced in its different windings and reflections. It is the largest serous membrane in the body, it is a closed sac, one portion of it lining the wall of the cavity, and one covering or being reflected around the different viscera, so as, for the most part, to enclose them, except where the vessels enter for the function of nutrition, — these bodies and their vessels being behind the membrane, and external to its cavity, although protruded into it from behind. Now the abdomen is laid open, the bag of the membrane is cut into; but that it was a closed sac, capable of containing air, was proved by the inflation of the abdomen before dissecting it, and the accumulation of fluid in it in dropsy demonstrates the continuity of its surface; but in the female it is perforated at the aperture

of the Fallopian tube, and is here continuous with the lining mucous membrane. The surface, now looked upon, is smooth, and is the interior of the sac, but the outer is rough, and in contact with the viscera and wall of the abdomen: the peritonæum may be detached from a part of the parietes to see this; where it lines the wall of the cavity it is called *parietal*, and as it is continued over the viscera, *visceral*. Its adherence to the wall of the abdomen, and the coverings that the viscera receive, vary in different parts; thus the cœcum is covered only on the anterior surface, and the ascending and descending colon only in front, whilst the stomach and transverse colon are surrounded by it; in the iliac and lumbar regions, it is but very loosely connected by cellular membrane to the wall, as already seen, but along the linea alba the union is very close. The different folds which attach the viscera to the wall, connect one organ to the other, or hang loosely in the cavity, consist of two portions or layers which, in most instances, enclose the vessels: there are some exceptions to this. The transparency of some of these, as in the falciform ligament of the liver, which contains the remains of the umbilical vein, would lead to the supposition that there could not be two layers in it; but, with a little care, in some subjects, these may be separated down to the surface of the liver, and the obliterated vessel detached from the membrane; indeed, if the peritonæum were separable from the different viscera and vessels that it covers, it would be possible to remove it as one large sac. The continuity of the membrane may now be traced through the different folds and inflections that it makes at different points, and, if it be an uninterrupted bag, by commencing at any spot we must return to the same both in a horizontal or vertical direction.* If the peritonæum is followed upwards from the umbilicus, it can be seen to adhere to the wall of the abdomen and abdominal surface of the diaphragm, as far as a line, limited, on the left side, by the passage through it of the œsophagus, and on the right, by the vena cava which is much deeper; prevented thus from covering the whole of the diaphragm, and so passing back to the spine, it is next continued forwards on the upper surface of the liver, on the right side, forming one layer of each lateral

* It is advisable to trace first the peritonæum on a diagram, to learn the appellations affixed to the different folds of it, as well as to become accustomed to the technicality of the description of layers, &c. In the common diagram of a vertical section there are two distinct bags delineated, one larger than the other; but the dissector must remember that the piece connecting the two, at the border of the gastro hepatic or little omentum between the stomach and liver, is removed by the section, and that the smaller bag is only a prolongation from the other, continued through an aperture behind this fold; and, supposing this small bag to be unattached, it could be drawn back again into the large cavity, so as to leave part of the stomach, liver, colon, pancreas, and spine uncovered.

ligament, on the anterior surface of the stomach, and on the spleen on the left, but in the right and left hypochondriac regions it extends much deeper than in the centre. As it ascends to the diaphragm it is arrested by the umbilical vein, but it passes on each side of this vessel, forming a falciform-shaped fold, — the falciform ligament of the liver: the enveloping this vessel with peritonæum resembles the reflection of the synovial membrane of the shoulder joint around the tendon of the biceps muscle. Following the membrane on the spleen, it is traced to the stomach, forming the splenic omentum; on the liver, it turns over its free margin, and, covering the under surface, passes on its left lobe back again to the diaphragm, constituting the under layer of the lateral ligament; on the extreme of its right side, also back to the lower part of the diaphragm and wall of the abdomen, but, in the centre, it meets with the vessels that supply this viscus, and so it is prolonged downwards in front of them to the anterior part of the stomach. At the free margin or right side of the vessels it sends a portion round to their posterior part through a space — the foramen of Winslow — between them and the spine; and this, after covering their posterior surface, giving rise to the posterior layer of the little omentum, spreads out upwards and downwards to constitute the bag of the omentum, as it is called; in being prolonged upwards it covers that part of the liver which is behind the vessels, and therefore not covered before in tracing the membrane on its under surface, and so it reaches the posterior part of the diaphragm and the spine, where it may be left to follow the descending portion of this pouch or bag. In being continued downwards, it descends also beneath the hepatic vessels, reaches the back of the stomach, covers it, and is applied, at its lower border, to the portion of serous membrane in front of it and the vessels. These two portions or layers from the front and back of the stomach are applied together in the great omentum or epiploon, which descends from the lower border of the stomach to the lower part of the abdomen, turns upon itself at this part, and ascends again to be fixed to the spine, encircling the transverse colon, one layer being above and one below it, and the portion of the fold which reaches from the colon to the spine is named transverse meso-colon. Raise up the transverse colon, make an incision into the transverse meso-colon, and its two layers will be seen to separate, at the spine, into ascending and descending: to see the ascending, cut through a part of the great omentum near the stomach, and raise up this organ; it runs upwards, on the pancreas and spine, to join or be continuous with the portion of the peritonæum which was left at this spot; thus completing the continuity of the pouch or bag of the omentum. The descending portion of the transverse meso-colon continues in the middle line over the aorta, superior mesenteric

artery and duodenum, to the small intestine, encircles this, and returns on the posterior part of its artery to the aorta and spine, forming the mesentery which fixes the jejunum and ilium. The membrane can now be followed into both iliac fossæ, attaching the cœcum in the right, and the sigmoid flexure in the left; and into the pelvis in the middle line, being reflected around the rectum, and connecting it to the sacrum by a short fold,— the meso-rectum; it then projects forwards between the rectum and bladder in a *cul-de-sac*, covers the back and part of the sides of the bladder, — the false ligaments of this organ being only the reflections of the peritonæum from it to the walls of the abdomen; and it is then to be traced upwards over the ligamentous remains of the urachus and hypogastric arteries, forming the inguinal pouches, to the umbilicus, from which the dissector began to trace it. In the female pelvis, the peritonæum passes from the rectum to the upper and posterior part of the vagina, covers the uterus, being reflected on each side over the appendages of this organ, to constitute the broad ligaments; from the uterus it continues to the back of the bladder without reaching the vagina in front, and is then disposed of as in the male. It is in the peritonæum surrounding the extremity of the Fallopian tube of the uterus that the communication between the serous and mucous membranes will be found. To trace circularly its reflections in the umbilical region, begin at the umbilicus; follow it outwards, on either side, to the transverse colon, over which it turns to reach the vessels that come to its inner side, and along which it is continued to the spine; it then passes over the aorta, along the artery to the small intestine, and returns along its other surface to the spine, fixing the small intestine by the mesentery; it is next prolonged outwards to the colon of the opposite side, turns over its inner and anterior part, comes into contact with the wall of the abdomen, and so reaches the umbilicus; the posterior part, therefore, of both the ascending and descending colon is uncovered by peritonæum, and the process that connects each to the abdominal wall is called meso-colon, there being an ascending and a descending. The principal folds or processes of the peritonæum are, the small and great omentum, the splenic omentum, the transverse, right, and left meso-colon, the appendices epiploïcæ, the mesentery, meso-cœcum and meso-rectum. The folds called ligaments, as those to the liver and bladder, will be seen with these organs. Before examining the folds, see the relations of the duodenum to the serous membrane.

Peritonæal covering of the Duodenum.

The portions of the duodenum differ much in the extent of the covering of peritonæum that they receive, and also in their mobility. The upper part, or that continuous with the stomach, is enveloped before and behind by the same portions of serous membrane, and is loose and moveable, like the stomach; the

second or descending portion, in front of the vessels of the kidney, is covered by peritonæum only on the front, or by the layer which passes from the upper part of the ascending meso-colon inwards to the mesentery and the middle line: to see this portion of the intestine, the ascending colon is to be thrown down. The last part of the duodenum, which reaches across the spine, is less surrounded than either of the others, since it lies, at first, in the interval between the two layers of the transverse meso-colon, and then passes behind the superior mesenteric vessels which separate it from the peritonæum. This portion of the duodenum is seen projecting through the under layer of the transverse meso-colon.

The *gastro-hepatic* or *small omentum* is a process of peritonæum between the liver and stomach, and contains the hepatic artery duct, and vena portæ, with the hepatic plexus. Its attachment, below, is to the upper border of the stomach and duodenum, the œsophagus limiting it on the left; the right border is free, and bounds anteriorly the space of the foramen of Winslow, through which the peritonæum is pushed, as it were, to form the bag of the omentum. At the upper border of the stomach the two layers of this process separate, to pass before and behind it: the coronary vessels are between its layers. Small Omentum.

The *gastro-colic omentum*, or *great omentum*, or *epiploon*, the largest fold of the serous membrane, consists also of two layers, which enclose vessels, and are continuous with those on the stomach. It is attached above to the lower border of the stomach and to the spleen, descends in front of the intestines to the lower part of the abdomen, and usually lower on the left than on the right side; it then bends backwards, ascends to the transverse colon, which it incases, and is continued to the spine as the transverse meso-colon. Near the stomach, the two layers of which it consists are separated by the arteries of the stomach, which send branches downwards between them, and these are accompanied by cellular membrane, veins, and nerves. This fold, by turning upon itself, limits, below, the cavity of the pouch or small bag. The *transverse meso-colon*, named from its attachments, is a septum between the epigastric and umbilical regions, or between the small intestine and the viscera in the upper part of the abdominal cavity; it is formed of a layer of membrane on each side of the vessels to the transverse colon, it is fixed by the one side to the colon, and by the other to the spine, below the pancreas, where its layers separate as before seen. Great Omentum. Transverse Meso-colon.

The *cavity of the omentum*, or interior of the small bag of the peritonæum, which is prolonged inwards, as a pouch, through the foramen of Winslow, is now seen through the aperture made in the great omentum below the stomach; it is bounded, in front, by the small omentum, stomach, and great omentum; behind, Cavity of the Omentum.

by the ascending portion of the great omentum, the transverse colon, and transverse meso-colon, and by the ascending layer from it; above is the liver, and below, the doubling of the great omentum on itself. The aperture by which the cavity communicates with that of the rest of the abdomen is by the *foramen* of *Winslow*, which is a space behind the vessels in the little omentum, and is occasioned by their coming forwards from the spine to reach the middle of the under surface of the liver; it is therefore bounded, in front, by the little omentum, behind by the spine and cava, above by the liver and lobulus Spigelii, and below by the duodenum. If the bag of the omentum were perfect, it would be possible to inflate it by the foramen of Winslow, or if it were loose, it could be everted and drawn into the general cavity; by which proceeding, part of the stomach, liver, transverse colon, and the pancreas would be deprived of peritonæal covering, and one layer would be removed from the great omentum, and by replacing it, these parts would be again covered. The possibility of everting the bag, supposing it to be unattached, will readily explain the manner in which the vessels reach the different viscera without perforating the peritonæum, since, when it is removed, they can readily pass to the organs; and it is as easy to conceive how a small pouch can be inserted against the surfaces of the vessels and the viscera.

Foramen of Winslow.

Splenic Omentum.

The *splenic omentum* reaches from the concave surface of the spleen to the great extremity of the stomach, contains the vessels which pass between them, and is continued below into the great omentum.

Appendices epiploïcæ.

The *appendices epiploïcæ* are small processes of the peritonæum attached to the large intestine, but, for the most part, to the transverse colon: they contain fat in their interior.

Meso-colon.

The *right* and the *left meso-colon* fix the ascending and the descending colon to the wall of the abdomen.

Meso-cœcum, — colon, — rectum.

The *meso-cœcum* attaches the cœcum in the right iliac fossa; and the sigmoid *meso-colon*, the sigmoid flexure in the left. The *meso-rectum* contains the vessels of this part of the canal, and connects the intestine to the sacrum.

Mesentery.

The *mesentery*, a very strong process of peritonæum, supports the small intestine; it is narrow at the spine, and is fixed to it in an oblique line, from the left side of the second lumbar vertebra to the right ilio-sacral articulation. The other extremity of the fold is wide, and is connected to the convolutions of the *jejunum* and *ilium* intestine. Between the two layers of which it is composed are found the superior mesenteric artery and vein, with numerous nerves, lacteals, and lymphatic glands.

Dissection.

Dissect now the vessels and nerves to the intestinal canal, except to its upper and lower parts; they lie in the folds of peritonæum which connect it to the wall, and come from the posterior part of the abdomen, where they are placed behind the

serous membrane: the superior mesenteric artery, vein, and plexus of nerves, and mesenteric glands, are contained between the layers of the mesentery; and the inferior mesenteric runs downwards and inwards towards the descending colon and sigmoid flexure. To expose the superior mesenteric, place the great omentum and transverse arch of the colon on the margin of the ribs, and the vessel being apparent in the mesentery, raise its anterior layer to trace the branches to the small intestine. In removing the cellular membrane, the nerves will be exposed, accompanying the branches of the artery to which they are closely united; they will be best seen encircling the upper part of the vessel, and may then be followed down; if they are carefully dissected in a small space, it will suffice to show their distribution. The veins will be cleaned at the same time, and, occasionally, the lacteals running to the mesenteric glands are visible without injection, but to be satisfactorily exposed, they should be filled with mercury: the posterior layer of the mesentery is to be left to support the vessels. The branches of the vessels and nerves that are distributed to the right side to the ascending and transverse colon are to be next dissected. The upper part of the superior mesenteric artery, surrounded by nerves, is to be followed back by raising the lower border of the pancreas which covers it.

Superior Mesenteric.

The *superior mesenteric artery* arises from the aorta soon after it has entered the abdomen, and about a quarter of an inch below the cœliac axis; it supplies with branches all the small intestine, except the duodenum; and the ascending, and the transverse colon. It descends in front of the aorta, and behind the pancreas and splenic vein to the lower border of this gland, and appears in the angle of separation of the two layers of the transverse meso-colon; it now passes over the third part of the duodenum and the left emulgent vein, which are placed between it and the aorta, enters between the layers of the mesentery, runs obliquely downwards and to the right side in its fixed border, forming an arch whose convexity looks to the left, and it terminates in small branches to the cœcum and lower part of the small intestine. The trunk of the artery is closely surrounded by nerves, and accompanied by the superior mesenteric vein. The branches that it gives off are some small ones beneath the pancreas, to this body and the duodenum; from the convexity of the arch fifteen or twenty branches — rami intestinales — to the small intestine; and from the concave side two or three branches — the ilio-colic, colica dextra, and colica media arteries — to the great intestine.

Branches.

Pancreatic.

The *pancreatic branches* are three or four small arteries to the pancreas and duodenum, which anastomose with those supplied from the pancreatico-duodenalis artery, a branch of the hepatic from the trunk of the *cœliac* axis.

Intestinal. The *branches to the small intestine* (rami intestinales), fifteen or twenty in number, arise from the left side of the artery, run downwards and outwards, nearly parallel to each other, between the layers of the mesentery, to reach the small intestine to which they are distributed: their size varies much, the upper ones being usually the largest in calibre, but the middle are the longest. Each, about two or three inches from the origin, divides into two that anastomose, on each side, with a similar division of the contiguous branch, to form an arch, from the convexity of which smaller vessels proceed towards the intestine; these again branch, and communicate with the collateral arteries in a second series of arches nearer the intestine, and the offsets from them, still smaller than those from the first, unite in a similar manner in a third set of arches: in the middle of the small intestine a fourth or fifth arch is found. From the convexities of the last arches the intestinal branches pass both on the front and back of the tube, and end in superficial branches which pass between the peritonæal and muscular coats, to anastomose on the convex border with those from the under side, and in deep ones which perforate the muscular coat, and are distributed to the mucous. The ramifications of the divisions of this artery constitute a remarkable network on the intestine, and the anastomosis from one branch to the other is very free and complete: the superior vessels, supplied to the jejunum, communicate with those to the duodenum from the pancreatico-duodenalis, and the lower to the ilium, freely inosculate with the arteries to the cœcum.

Ilio-colic. The *ilio-colic artery*, in direction the continuation of the superior mesenteric, runs downwards to the cœcum, and divides into an ascending branch, to join the colica dextra of the ascending colon; and a descending, to anastomose, on the termination of the small intestine, with the arteries from the other side of the mesenteric; and the intervening ones run forwards to the cœcum, divide, and unite with those on each side, to form one or two sets of arches, from which the small arteries are distributed to the intestine by a superficial and deep set, as in the small intestine.

Colica dextra. The *right colic artery* is most frequently a branch from the ilio-colic about two inches from its commencement; it runs upwards and to the right side, beneath the peritonæum which extends from the spine to the ascending colon, and, near the intestine, divides into an ascending branch to join the middle colic, a descending to the ilio-colic artery, and intervening to the intestine; small arches result from the division and union of its branches, and supply the small arterial ramifications to the intestine. This artery may be a separate trunk from the mesenteric.

Colica media. The *middle colic* arises from the upper part of the artery,

opposite the transverse meso-colon; it passes upwards and forwards between the layers of this process, and divides, about its centre, into two large diverging branches; — the right joining the ascending from the right colic artery, and the left anastomosing, on the descending colon, with the ascending division of the left colic from the inferior mesenteric. From these two large branches arteries pass forwards to the transverse colon, uniting into arches, from which the small intestinal branches are derived. The distribution on the intestine is the same as in the other parts of the tube. It is this branch that anastomoses with the inferior mesenteric artery.

Superior Mesenteric Vein.

The *superior mesenteric vein* commences by small radicles, both superficial and deep, corresponding to the divisions of the arteries in the large and small intestines; the small branches ascend, and unite together, forming larger ones, which, situated beneath the arteries, unite into one trunk that lies on the right side of the superior mesenteric artery, and enters with it beneath the pancreas, to join with the splenic in the vena portæ. This vein is joined, occasionally, by the inferior mesenteric vein.

Sympathetic Nerves of the Abdomen.

The nerves in the abdomen for the supply of the viscera are, with one or two exceptions, derived solely from the sympathetic system in the cavity, and they accompany the different arteries, around which they form plexuses. The intestinal canal is supplied by these, except the upper part or the stomach, in which the pneumo-gastric nerves end, and the termination or the rectum to which branches of the sacral plexus are distributed; the bladder and the vagina are the only other organs supplied by nerves from the spinal system. In the abdomen, the arrangement in the disposition of the trunk and branches is the same as in the thorax, for there is a gangliated longitudinal cord extended along each side of the vertebral column, from which branches are sent forwards to the viscera and parts in front of it; and there is, besides, a large central prevertebral plexus, the solar, similar to the cardiac in constitution, since it is not formed by branches from the nerve in the cavity, but by those which arise from the sympathetic in another region of the body; and like it also in distribution, for from it numerous branches pass to supply the viscera. The solar plexus surrounds the cœliac axis, and superior mesenteric artery, and sends nerves on each branch of a vessel from these trunks; these form plexuses which have received the same name as that of the vessel which they accompany, but the special anatomy of the solar plexus will be afterwards seen.

Superior Mesenteric Plexus.

The *superior mesenteric plexus* of nerves, a continuation downwards of the right side of the solar plexus, the greater number of branches being found on the right side of the mesenteric artery, is covered by the pancreas, which must be a little raised to see it; it closely surrounds the artery in a sheath, de-

scending on its branches, and supplying, as it, the whole of the small intestine, except the duodenum; and the ascending and transverse colon. When the branches of the nerves approach the attached or concave border of the intestine, they quit the arteries, and continue forwards so much diminished in size that it requires great care to follow them, and the filaments that accompany the arteries to the great intestine leave the vessels sooner than those to the small intestine. Opposite the last arch of the arteries, some of the filaments divide and subdivide, uniting with others in arches before entering the intestine, but others run forwards without division: they then pass between the peritonæal and muscular tunics supplying these, and some perforate the latter, to be distributed to the mucous membrane.

Lymphatics. The *lymphatic* or *mesenteric glands*, very numerous, are about the size of almonds in the natural state, but when diseased, much larger. They are placed between the layers of the mesentery, in the intervals between the vessels, near the intestine, and along the course of the artery at a distance from it: a large group is found near the cœcum. The glands of the large intestine lie along the arteries. The lymphatic and lacteal vessels of the intestines pass through these, in their course to the glands on the sides of the aorta and cava.

Dissection. In the dissection of the inferior mesenteric artery and its nerves, with the aortic and hypogastric plexuses, it will be necessary to turn over to the right side, and fasten with hooks, the whole of the small intestine with the posterior portion of the mesentery; and the large intestine still remaining on the chest, to remove the layer of peritonæum which passes outwards from the aorta to the descending colon, that a view may be obtained of the inferior mesenteric artery beneath it, with its nerves and veins. This vessel supplies the whole of the remaining portion of the intestinal canal, but if the part of it to the colon and sigmoid flexure be exposed, it will be sufficient, since the branches that descend into the pelvis will be dissected with that cavity; the nerves with it are larger and more numerous than those with the superior mesenteric. Follow up the inferior mesenteric vein either to the splenic or to the superior mesenteric. Crossing beneath the inferior mesenteric, is the spermatic artery with the spermatic plexus of nerves; these are also to be traced upwards now the peritonæum of the left side is removed; the nerves will be found to come from the renal and aortic plexuses, and the artery from the aorta below the renal. Remove next, with care, the layer of peritonæum from the front of the aorta as high as to the origin of the superior mesenteric; beneath it, in some dense cellular membrane and lymphatic glands, is the aortic plexus, whose branches are derived from the ganglia on each side of the spine, also some descend from the plexus surrounding the superior mesenteric artery. Take

away the portion of peritonæum from the front of the sacrum, and follow the nerves down over the aorta, and over the iliac artery on each side, to the hypogastric plexus, which is situated partly in the meso-rectum, the greater portion of it being on the left side; it is enveloped in cellular membrane, and sends branches forwards with the arteries of the inferior mesenteric and internal iliac to the rectum and bladder, or uterus and vagina in the female; its final distribution cannot be followed in this stage of the dissection.

Inferior Mesenteric Artery.

The *inferior mesenteric artery*, smaller than the superior, arises from the front of the aorta about half an inch above its division into the iliac arteries. It descends in front of the aorta, then inclines to its left side, is continued over the left common iliac artery, enters the fold of the meso-rectum, and terminates by dividing into two branches—the superior hæmorrhoidal—for the supply of the sides of the rectum: it supplies the descending colon, the sigmoid flexure, and the rectum, and anastomoses, above, with the middle colic artery of the superior mesenteric, and below, with the middle hæmorrhoidal from the internal iliac, and with the inferior hæmorrhoidal from the pudic in the perineal space. The following branches arise from it.

Branches.

Colica sinistra.

The *left colic artery*, the first branch, ascends in front of the psoas muscle and left kidney, and divides into an ascending branch to join the descending of the middle colic, and a descending, to anastomose with the artery to the sigmoid flexure; the arteries to the intestine from these branches form one or more arches, and are then distributed to it like the intestinal arteries from the superior mesenteric.

Sigmoidea.

The *sigmoid artery* runs transversely outwards over the psoas to the sigmoid flexure of the colon, divides into large branches which supply this part of the intestine, and sends an anastomosing branch upwards to join the left colic, and downwards to the superior hæmorrhoidal arteries.

Superior Hæmorrhoidal.

The *superior hæmorrhoidal artery*, the continuation of the trunk, descends to the pelvis, surrounded by many branches of nerves, enters between the layers of the meso-rectum, and supplies the rectum.

Inferior Mesenteric Vein.

The *inferior mesenteric vein*, of smaller size than the superior, returns the blood from the part of the intestinal tube supplied by the inferior mesenteric artery, and ascends along the psoas muscle, beneath the peritonæum, but distant from the artery of the same name, to enter the splenic vein about its centre, beneath the pancreas: it may join the superior mesenteric vein. Its branches begin in the intestine in the same manner as those of the superior, and they, as well as the trunks of both these veins, are destitute of valves, so that they may be injected from the trunk to the branches. The superior and inferior mesenteric veins unite with the splenic to give rise to the vena portæ,

which conveys the blood from the organs concerned in the process of digestion to the liver, for the secretion of the bile.

Lymphatic Glands. The *lymphatic glands* with the inferior mesenteric artery are fewer than with the superior, and the lymphatics that come from the intestine pass through the glands, and open into those along the side of the aorta in the lumbar region.

Lumbo-aortic Plexus. The *lumbo-aortic plexus* of the sympathetic, now dissected, is a plexiform arrangement of the nerves in front of the aorta, and extends from the origin of the superior mesenteric, to its bifurcation into the iliac arteries. It is in part a continuation from the great solar plexus, and in part formed by the branches from the gangliated cords on the sides of the spine; it receives above and on the right side, from beneath the duodenum, the filaments from the portion of the solar plexus surrounding the superior mesenteric artery, and some from the renal plexuses; and the branches derived from the ganglia on the side of the spine, greater in number than the others, are more numerous on the left side than on the right, and those of the right pass over the vena cava. The plexus ends, below, in branches which descend over the common iliac arteries to join the hypogastric or central plexus of the pelvis; it sends off a plexus to accompany each visceral branch that arises from the aorta below the renal, and superior mesenteric; and filaments from it supply the aorta and vena cava.

Spermatic. The *spermatic plexus* is a prolongation from both the aortic, and the renal plexus. The filaments from the front of the aorta accompany the spermatic artery, and unite in front of the psoas, and external to the left colic artery, with the filaments from the renal plexus, forming a small gangliform body, similar to that of the descendens noni in the neck, from which branches proceed with the vessel to the testicle, by passing with it through the internal abdominal ring. These have been examined with the cord and testicle. In the female, these filaments run on the spermatic artery into the pelvis, to be distributed to the ovary and uterus.

Inferior Mesenteric. The *inferior mesenteric plexus*, also an offset from the aortic, accompanies the artery of the same name, being closely applied to its coats, as in the superior. The filaments from it extend forwards with the vessels to supply the ascending colon, the sigmoid flexure, and the rectum, and the lower ones join with those of the hypogastric plexus to the rectum. The nerves of this plexus are more readily followed to the intestine than those of the superior, particularly in the branches distributed to the sigmoid flexure; and the union with each other, before perforating the coats of the intestine, is much better marked: this is a very easy dissection; but to expose the intestinal branches of the superior mesenteric plexus requires some care.

Hypogastric Plexus. The *hypogastric plexus*, or large prevertebral centre for the supply of the viscera of the pelvis, is situated in front of the

sacrum, below the divergence of the common iliac arteries, and beneath the layer of peritonæum descending into this cavity to form the meso-rectum. It is continuous above with the aortic plexus, and receives branches from the lumbar ganglia on each side, as well as some small filaments from the sacral ganglia; it consists of large flat nerves united together in plexiform masses, and these are whiter than the usual sympathetic enlargements in the other parts of the abdomen; its left side is larger than the right, and unites with the inferior mesenteric plexus. A right and left hypogastric plexus have been described, in consequence of the lateral enlargements. The branches to the viscera of the pelvis pass forwards from its lower part, between the layers of the meso-rectum and posterior false ligaments of the bladder, accompany the branches of the internal iliac artery, and give rise to secondary plexuses of the same names as the vessels. The lower filaments that run forwards to supply the rectum and bladder, join with the nerves from the sacral plexus to these viscera.

Dissection.

The relations of the abdominal aorta and vena cava are to be next studied, and before any of the viscera are removed from the cavity. Replace the intestines; detach the great omentum from the border of the stomach, beyond the gastro-epiploic artery that runs along it; turn up the stomach and spleen, the former not being distended, and the cavity of the great omentum is more completely opened. Raise from the surface of the pancreas and the spine, the ascending layer of peritonæum of the transverse meso-colon, and the aorta will be exposed above the border of the pancreas, giving off the trunk of the cœliac axis; but this is not to be cleaned, or the branches of nerves accompanying it will be cut away. The remaining part of the artery, below this viscus, will be seen by turning the small intestines over to the right side, since the layer of peritoneum, which covers it, has been taken away to dissect the aortic plexus of nerves; the vena cava is exposed by the same proceeding. The branches of the aorta are not to be dissected out as they are mentioned, because each is examined with the viscus to which it is supplied.

Abdominal Aorta.

The *abdominal aorta* extends from the opening between the fleshy pillars of the diaphragm, opposite the last dorsal vertebra, to the left side of the body of the fourth or fifth lumbar vertebra, and divides into the right and left common iliac arteries; it is placed in the middle line at the diaphragm, but inclines to the left side as it descends. It is covered by the ascending layer of peritonæum from the transverse meso-colon, by the pancreas and the splenic vein; and in front of these, again, are the stomach and small omentum. Below the pancreas the third portion of the duodenum crosses it, also the left renal vein to join the cava: these two lie between the aorta and the

superior mesenteric artery; the transverse meso-colon is opposite to it in the interval between the pancreas and duodenum. It is then concealed by the mesentery and superior mesenteric artery, and below this to its termination, only by the descending layer of peritonæum which is continued into the pelvis; this part of the vessel is surrounded by the aortic plexus, and in front of it are the convolutions of the small intestine. The aorta lies on the lumbar vertebræ, and is convex forwards; on the right side is the vena cava, and on the left the psoas muscle and the sympathetic nerve. The branches from the aorta are for the supply of the walls of the abdomen, and for the viscera contained in it; the latter are much the largest, and most important. The phrenic or diaphragmatic, not now visible, are the first; close to these is the trunk of the cœliac axis, which appears at the upper border of the pancreas; next, the superior mesenteric, immediately below, is seen to come beneath the lower border of the pancreas; about half an inch lower down, on each side, is the renal, and the spermatic arise close below, and from the lateral part; the inferior mesenteric is given off about half an inch above the bifurcation of the aorta; the lumbar arteries, corresponding to the intercostals of the chest, spring from the back of the vessel, and the middle sacral from the angle of division. The distance of these branches from each other, at their origin, will be better seen in a future stage.

Branches.

Vena cava inferior.

The *vena cava inferior* or *ascendens*, the channel by which the blood, distributed to the lower extremities and abdomen, is returned to the heart and lungs, lies in front of the spine, and to the right side of the aorta. It commences below, opposite the interval between the fourth and fifth lumbar vertebræ, by the union of the right and left common iliac veins, and has the same relations to peritoneum and the viscera, up to the point at which the aorta passes through the diaphragm, except that it crosses in front of the right renal artery; above this opening it ascends to the right side, separated from the artery by the right crus of the diaphragm, forms the posterior boundary of the foramen of Winslow, and reaches the posterior surface of the liver; it then perforates the tendinous centre of the diaphragm, and opens into the right auricle. The inferior cava receives the veins corresponding to the arteries supplied to the wall of the abdomen, and to the generative and urinary organs; but those in connection with the arteries of the alimentary canal, liver, pancreas, and spleen, open into the vena portæ. The large veins of the liver, uniting with it at the diaphragm, do not correspond to the hepatic artery, but are connected with the function of the liver in the secretion of the bile. The left spermatic vein opens into the renal vein instead of into the vena cava.

Branches.

Dissection.

Place two ligatures on the upper part of the jejunum, and

divide the intestine between them; do the same near the termination of the sigmoid flexure of the colon, and cut across the branches of the vessels and nerves that supply this detached portion of the intestinal tube; this should not be done close to the intestine, but about midway in the vessels. Divide, at the same time, the processes of peritonæum connecting it to the abdominal wall, and remove it from the body; set it aside in water, till, the stomach and duodenum being removed, the structure of the whole can be examined at the same time, and during the interval in which the body is turned on the face for the dissection of the muscles of the back. Inflate moderately the stomach and duodenum, by blowing into the jejunum where it is cut across on the left side of the spine, and then proceed to clean the stomach, duodenum, pancreas, and their vessels. Raise the liver as high as can be done, or, what is better, let it be held up; remove carefully the small omentum from the cœliac axis, to expose its three branches, viz. coronary, hepatic, and splenic; and from the upper curve of the stomach, along which an arterial arch is situated,—the branch at the right extremity being from the hepatic, and that at the left from the coronary artery: this is accompanied by an arch of veins, and, near the left extremity, by the pneumo-gastric nerves, the left being in front, and the right behind it. Follow the small coronary artery towards the left side, to the stomach; and the hepatic, to the right, to the liver, without, however, stripping from them the plexuses of nerves, which will be dissected with the solar plexus; with the artery to the liver, are the vena portæ, the bile duct, and many branches of large nerves on the portal vein. Along the great curvature of the stomach is also another vascular arch both of arteries and veins; the right portion is from the hepatic, and the left from the splenic. Raise the stomach, remove the ascending layer of peritonæum from the pancreas, for the splenic artery and vein which are behind it, near the upper border; follow them to the spleen, and trace the superior mesenteric artery and vein beneath the pancreas, if it is not already done; clean the right extremity of this viscus, in contact with the duodenum; and the pancreatico-duodenalis artery, a branch of the hepatic, is seen in front, between the two, and if the intestine be gently raised, the duct of the liver will be found between them, near the posterior surface. The duodenum must be replaced in its natural position, that the relations of it may be observed.

Stomach. The *stomach* or dilated receptacle for the food is situated between the œsophagus and duodenum, which, with the processes of peritonæum attaching it to the liver, spleen, and diaphragm, retain it in its position in the abdomen. It is of a Form. conical form, the sides being flattened, with the base to the left, and the apex to the right side, and it is directed obliquely from

Size. above downwards, and from left to right. Its size varies much in different individuals, and in some it is much constricted in its

Divisions. centre. When the stomach is partially distended, it presents two surfaces, an anterior and posterior; two curvatures or borders, the upper or small, and the lower or great curvature; two extremities, the left and right; and two orifices, the cardiac

Surfaces. Anterior. and pyloric. The *anterior surface* looks upwards and forwards, or upwards when distended; it is flat when the organ is empty, but convex when it is filled, and is applied against the diaphragm,

Posterior. abdominal wall, and liver; the *posterior*, directed downwards and backwards, or directly downwards, is flat or convex according to its state of dilatation, and corresponds to the transverse

Curvatures. Small. meso-colon and pancreas. The *small curvature*, directed upwards, or slightly backwards, extends from the entrance of the œsophagus to the pyloric or right extremity; it is concave towards the left side, but convex near the right; to it are attached the small omentum and the coronary vessels. The

Large. *great curvature* or lower border, directed downwards, or forwards against the wall of the abdomen when the stomach is full, is of much larger extent than the upper, and is convex, except near the right extremity, and here it is concave, opposite to the convexity of the upper curvature: to it is attached the great

Extremities. Left. omentum, and an arterial arch runs along it. The *left extremity* or tuberosity is the largest part of the organ, and consists of the portion or pouch to the left of the opening of the œsophagus; it is situated deeply in the left hypochondriac region, superior to the right extremity, and is connected to the spleen by the

Right. vasa brevia, and the gastro-splenic omentum. The *right* or *pyloric extremity* is much smaller than the other, is cylindrical, forms the apex of the cone to which the stomach is likened, and situated below the level of the left, is also nearer the abdominal wall; its position varies from the gall-bladder, which it touches,

Orifices. Cardiac. to the umbilical region. The *cardiac orifice*, or opening of the œsophagus, is to the right of the left extremity, or about three inches from it, and is the highest point of the stomach. The

Pyloric. *pyloric orifice* is the aperture of communication with the duodenum, and its position is marked by a firm circular ring; it limits the extent of the cavity within, is situated to the right side of the spine, in contact with the gall-bladder, and much below the level of the cardiac orifice.

Duodenum. The *duodenum*, or upper part of the small intestine, extends from the pyloric orifice of the stomach to the left side of the second lumbar vertebra, and terminates in the jejunum. It passes at first upwards and to the right, to the neck of the gall-bladder, then descends along the right side of the pancreas, and finally turns to the left below the inferior border of this viscus, so as to describe a curve, with the convexity to the right side and the concavity to the left, which surrounds the head of the

pancreas. It is situated in the right hypochondriac, right lumbar, and umbilical regions, and is retained in its natural position by the reflections of the peritonæum over or around it. Its course around the pancreas may be divided into three portions; the first, or *superior transverse*, from the pylorus to the neck of the gall-bladder, is about two inches in length, it is free and moveable, is surrounded by peritonæum, and is in contact with the wall of the abdomen in front, with the liver and gall-bladder above, and with the bile-duct and vena portæ behind. The second or *vertical* portion descends to opposite the third lumbar vertebra, is from two to three inches long, and is covered only in front by peritonæum; superficial to this part is the upper end of the ascending colon, and it is crossed by the transverse; behind are the vessels of the kidney, and the inner border of this viscus; on the outer side is the ascending colon, and on the inner or left, the pancreas, with the pancreatico-duodenalis artery between the two, in front, and the ductus communis choledochus or common bile-duct behind. If the duct be followed down, it will be found to enter this portion of the duodenum on the side in contact with the pancreas, and at a point below its middle. Usually, before perforating the coats of the intestine, it is joined by the duct of the pancreas, which is easily exposed in the substance of the gland, near the posterior surface, by scraping near the entrance of the bile-duct into the duodenum. The third or *inferior transverse* is continued across the spine to the left side of the body of the second lumbar vertebra, is covered by peritonæum only on the anterior surface, and it has been seen projecting through the descending layer of the transverse meso-colon. In front of it is the superior mesenteric artery, vein, and plexus of nerves; behind, are the vena cava and aorta; and above, the pancreas; and the left renal vein is either above or rather behind it. In this portion of the small intestine, the chyme is mixed with the bile, and in it the process of chylification begins.

Superior transverse portion. Vertical. Inferior transverse.

The *pancreas* is a glandular organ, which secretes a fluid to assist in the process of chylification in the small intestine; it is placed behind the stomach, and extends downwards and to the right across the spine, from the spleen to the duodenum. It is about seven inches in length, the right extremity or head being much larger than the left, from which cause it has been divided into head, tail, and body; and it lies in the left hypochondriac, the umbilical, and the right lumbar region. This body has a transverse and a vertical portion: the transverse, the longest, extends across the spine, is bifurcated at its left extremity, and, in its extent between this and the head, is curved over the vertebral column and the vessels situated on it; its narrowest portion is to the right of this, where it is twisted, and its widest is rather to the left. The vertical portion

Pancreas. Divisions and Form.

Small Pancreas. or the *small pancreas* occupies the concavity of the duodenum, joining with the transverse, above which it projects, and it sends also a process to the left, along its lower border, beneath the superior mesenteric vessel, so as to partially encircle them.

Relations. Surfaces. Anterior. The *anterior surface*, inclined forwards below, is covered by the ascending layer of the transverse meso-colon; and to expose the pancreas in its position in the abdomen, it is only necessary to detach the great omentum from the arch of the stomach, to raise this, and to take away the process of peritonæum that covers it on the spine: in front of it is the stomach. The

Posterior. *posterior surface*, uncovered by peritonæum, crosses the vertebral column opposite the first lumbar vertebra, and lies on the left supra-renal capsule, and on the left kidney, the aorta, cava, and pillars of the diaphragm; on the superior mesenteric and renal vessels, the splenic vein, and the commencement of the porta

Borders. Anterior. to the right of the aorta. The *upper border* is thick, and above it, in the centre, appears the cœliac axis; to the left of this, the splenic artery and vein lie along it; and to the right, the

Lower. hepatic artery and first portion of the duodenum. The *lower border* is rather raised forwards by the superior mesenteric vessels which appear below it in the centre, and to the left of this, the inferior mesenteric vein passes beneath it to join the splenic; near the left extremity it touches the kidney, and at the right, it is in contact with the third portion of the duo-

Extremities. Left. Right. denum. The *left extremity* or the *tail of the pancreas* touches the spleen; and the *right extremity* or *head* is received into the concavity of the duodenum, and rather projects on the front of the intestine, the pancreatico-duodenalis artery running between the two in front, and the common bile-duct behind.

Spleen. The *spleen*, an organ whose use is unknown, is situated in the hypochondriac region, and is attached to the left extremity of the stomach. Its shape is that of an ellipse, the longest diameter being vertical; it is convex externally towards the ribs, and flat or slightly concave internally; and this surface, turned to the stomach, is marked by a fissure or *hilus* in which the vessels enter; it is attached by the gastro-splenic omentum, and is in relation with the tail of the pancreas. The posterior border is thicker than the anterior; and the lower angle, the most pointed, is in contact with the kidney and the supra-renal capsule. There may be more than one appendage to the spleen, and it is oftentimes divided by fissures into lobules.

Arteries. Cœliac Axis. The *cœliac axis*, a short trunk about half an inch long, is the first branch of the abdominal aorta, and arises from its front opposite the first lumbar vertebra. It is placed between the pillars of the diaphragm, above the pancreas, and on each side is the semilunar ganglion, whose branches in the solar plexus completely surround and cover it, and to the right is the lobulus Spigelii of the liver; the small omentum and stomach are in

front of the artery and conceal it. The cœliac axis supplies the stomach, spleen, pancreas, liver, and duodenum, and divides into coronary, hepatic, and splenic arteries.

The *coronary artery*, the smallest of the three branches, passes to the left above the splenic, ascending at the same time between the layers of the little omentum to reach the cardiac orifice of the stomach: at this point it gives off œsophageal branches, then turns to the right along the small curvature, and between the laminæ of the small omentum, to anastomose with the superior pyloric of the hepatic. As it lies along the upper border it sends down gastric branches to supply both sides of the stomach, and those to the cardiac extremity anastomose in the coats with branches of the splenic artery. The *œsophageal branches* ascend on the œsophagus, passing from the abdomen through the œsophagean opening in the diaphragm, to anastomose with the branches supplied to this tube from the thoracic aorta. Coronary Artery. Œsophageal branches.

The *superior coronary vein*, with this artery, commences in the œsophagus and in the cardiac extremity of the stomach; it then continues to the right, along the small curvature, being joined by branches, accompanies the superior pyloric artery, and opens into the vena portæ near the liver. Vein.

The *splenic artery*, to be seen by raising the stomach, is, in the adult, the largest of the branches of the cœliac axis; it is very tortuous, runs almost horizontally outwards beneath the ascending layer of the transverse meso-colon, and behind the upper border of the pancreas, with its accompanying vein, above which it lies; and near the fissure of the spleen it divides into numerous branches, which perforate the concave surface, either by its fissure, or by apertures in it, and are distributed in its structure. In this course it crosses the left crus of the diaphragm, and to see it in an undissected subject will require the same dissection as for the pancreas. The branches of this artery are the following:—the *pancreaticæ parvæ*, which are distributed to the gland as the artery runs along it. In the same position it gives off a larger branch, the *pancreatica magna*, which is often absent; it arises from the splenic, near the left extremity of the pancreas, runs to the right in its substance with the duct of the gland, and supplies its structure. The small *vasa brevia* arise, commonly, from the divisions of the splenic, turn back in the gastro-splenic omentum to the left extremity of the stomach, and ramify in its coats, anastomosing with the branches of the coronary, and with the following. The *gastro-epiploïca sinistra*, the last branch of the artery, is often derived from one of the divisions of the splenic; it turns downwards and to the right side, enters between the layers of the great omentum, runs along the great curvature of the stomach, and anastomoses with the right gastro-epiploic artery Splenic Artery. Branches. Small Pancreatic. Large. Vasa brevia. Left gastro-epiploic.

from the hepatic; it distributes branches to both surfaces of the stomach, to ramify in its coats, and supply the mucous membrane, and it sends long branches downwards between the layers of the great omentum. The artery is placed at some distance from the stomach, unless this is distended, and it is accompanied by a vein which opens into the splenic.

Vein. The *splenic vein*, of very large size, commences in the spleen, and the branches issuing from it unite together to form the trunk, which runs to the right behind the upper border of the pancreas, but below the artery; and opposite the aorta it crosses to the lower border of the gland, and joins with the superior mesenteric in front of the vena cava, to form the vena portæ. It receives the veins corresponding to the vasa brevia, to the gastro-epiploic, and to the pancreatic arteries, and it is joined, about its middle, by the inferior mesenteric vein.

Hepatic Artery. The *hepatic artery*, intermediate in size between the other two, but in the fœtus the largest of the three, is surrounded by the greatest plexus of nerves. It runs to the right side, between the layers of the small omentum, above the curvature of the stomach, and passes over the right crus of the diaphragm and vena portæ to reach the pyloric extremity of the stomach, at which spot it gives off its principal branches, the gastro-duodenalis, and the superior pyloric; it then ascends to the right, in the peritonæum in front of the foramen of Winslow, with the bile-duct and the vena portæ,—the artery being to the left, the duct to the right, and the vena portæ behind and between the other two,—and near the transverse fissure of the liver it divides into

Branches. right and left hepatic arteries: the left, the smaller branch, perforates the left lobe to supply it, and the right, after giving off

Cystic. the *cystic* artery, which crosses the bile-duct to be distributed on the gall-bladder, enters the under surface of the right lobe.

Superior Pyloric. The *superior pyloric* branch arises from the hepatic, near the pyloric extremity of the stomach, descends to it, turns along its upper border from right to left, and anastomoses with the coronary artery; it gives small arterial twigs to both surfaces of the stomach. The vein by its side was seen in dissecting the coro-

Gastro-duodenalis. nary. The *gastro-duodenalis* artery, much larger than the preceding, is a short trunk, extending only behind the upper transverse portion of the duodenum, and dividing at its lower border into the gastro-epiploïca dextra, and pancreatico-duodenalis branches. As it lies behind the duodenum, it gives some small branches—*inferior pyloric*—to the lower part of the pyloric extremity of the stomach and to the pancreas. The stomach must be moved in different directions to see it, and the two

Pancreatico-duodenalis branch. following. The *pancreatico-duodenalis*, the smaller branch of division, continues along the curve of the duodenum, lying between it and the pancreas, both of which it supplies, and it anastomoses, below, with the upper branches of the superior mesenteric to these organs; a similar branch is seen on the

posterior surface between the head of the pancreas and the concavity of the duodenum. The *gastro-epiploïca dextra* branch, the continuation in size of the gastro-duodenalis, turns from right to left along the great curvature of the stomach, and between the layers of the transverse meso-colon, to meet the gastro-epiploïca sinistra from the splenic, with which it anastomoses; like the left gastro-epiploic artery, it gives branches to both surfaces of the stomach, and to the great omentum, and is surrounded by cellular membrane between its laminæ. The *vein* that corresponds to this artery opens into the superior mesenteric, between its crossing the duodenum and the junction with the splenic vein.

Right Gastro-epiploic branch.

Vein.

The *vena portæ* receives the blood returned by the veins from the alimentary canal, pancreas, and spleen, and it differs from other veins in dividing into numerous branches which ramify through the structure of the liver in a manner similar to an artery. It commences behind the pancreas, but near its lower border, in front of the inferior cava, and about two inches from the right extremity of the gland, by the union of the splenic and superior mesenteric veins; it is about four inches long, ascends to the right in the layers of the small omentum with the hepatic artery and bile-duct, and in front of the foramen of Winslow, to reach the left extremity of the transverse fissure of the liver, and divides into a right and left branch for the lobes. In this course it is joined, near the liver, by the cystic vein and that from the upper curvature of the stomach.

Vena Portæ.

The *hepatic duct*, or excretory tube to carry the bile from the liver, consists of two portions, a right and left, as it appears in the transverse fissure of the liver; but these soon join to form the common hepatic duct, which, after descending for one inch or an inch and a half, unites at an acute angle with the duct of the gall-bladder in the common bile-duct — the *ductus communis choledochus*, — which measures about two inches and a half in length, is vertical, and continues in the same direction, lying, at first, in the small omentum in front of the vena portæ, and to the right of the hepatic artery; it then crosses behind the first portion of the duodenum with the gastro-duodenalis artery of the hepatic, but to the right side of this vessel, passes between the vertical portion and the pancreas, nearer the posterior than the anterior surface, and perforates, obliquely, the wall of the intestine about the middle of this division. Before opening into the duodenum it is joined by the small pancreatic duct, or the two may open separately. To see the duct between the duodenum and the pancreas, the intestine must be turned forwards.

Hepatic Duct.

Common Duct.

The *pneumo-gastric nerves* are now seen terminating in the abdomen on the stomach, one being on each surface of it. The *left* enters with the œsophagus, and, lying on the front, descends

Pneumo-gastric Nerve.

Left.

to the cardiac extremity; it then divides into many branches. Some of these continue forwards on the anterior surface of the cardiac extremity before perforating the muscular coat, others lie along the small curvature with the coronary artery, extending as far as the duodenum, and some filaments leave this curvature, ascend to the liver, and join the hepatic plexus of the sympathetic. The *right* nerve, situated behind the œsophagus as this tube enters the abdomen, remains still posterior to it, and on the back of the stomach divides into branches to be distributed to its posterior part, and some join also the solar plexus of the sympathetic.

Right.

Dissection.

The dissection necessary for the semilunar ganglion and solar plexus, with the different plexuses of nerves that are continuous with it, is rather tedious, and will require some care and dexterity. Let the air escape from the stomach and duodenum, divide the vena portæ, gastro-duodenalis artery, and common bile-duct, behind the pylorus; and turn the stomach, duodenum, and pancreas over to the left side, fasten them with hooks, and raise up well the liver; remove some cellular membrane, and the vena cava is exposed; next divide this vein above where it is joined by the renal, and draw down its lower end. Beneath it is the large reddish-looking semilunar ganglion of the right side, enveloped with cellular membrane; the great splanchnic nerve is seen to pass between the fibres of the crus of the diaphragm to end in this body; and deeper than it, and usually lying in the same interval between the fibres, is the small splanchnic, which sends some filaments to join the nerves from the ganglion, but the greater number descend to the renal plexus. Filaments of nerves are directed outwards to the kidney along its artery, and to the supra-renal capsule; but by far the greatest number pass inwards over the crura of the diaphragm, and around the cœliac axis and superior mesenteric artery, constituting the solar plexus, from which the secondary plexuses are to be followed on the arteries of the cœliac axis, on the superior mesenteric, on the aorta, and on the diaphragmatic. The branches from the right pneumo-gastric nerve are to be sought joining the plexus, and also the filaments of the phrenic, which join above, near the cava, the plexus accompanying the diaphragmatic artery; but the phrenic will be better seen when the liver is removed. In the spaces between the nerves of the solar plexus numerous lymphatic glands and ducts will be found, and the whole is surrounded by a dense cellular membrane which it is difficult to remove.

Sympathetic Nerve.

Semilunar Ganglia.

Right.

The *semilunar ganglia* of the sympathetic are two in number, one for the right and one for the left side; they are the largest ganglia of the sympathetic. The *right*, the only one exposed, is of an oval or very irregular shape, but smaller below than above, and frequently separated into smaller ganglia, which

continue the lower portion in front of the aorta, to join the opposite one. It is situated on the outer part of the crus of the diaphragm, between it and the supra-renal capsule, opposite to the cœliac axis, and is covered by the vena cava. By its upper and outer part it is joined by the great splanchnic nerve, which is a branch of the thoracic ganglia, and perforates the crus of the diaphragm; from the outer side nerves are directed to the supra-renal capsule and renal plexus, and from the inner and lower arise the numerous branches and ganglia of the solar plexus. The *left* ganglion is placed on the left crus of the diaphragm, and internal to the supra-renal capsule, is usually smaller than the right, receives in the same manner the splanchnic nerve, and is covered by the pancreas. Left.

The *solar plexus*, or great prevertebral centre of the sympathetic system in the abdomen, from which branches proceed to supply the viscera in the portion of the cavity above the pelvis, consists of a large network of nerves continued from one semilunar ganglion to the other, and of numerous small ganglia connected together by filaments, so as to leave spaces or areolæ, in which are placed lymphatic glands. The plexus occupies the middle line of the body behind the stomach and small omentum, in front of the pillars of the diaphragm and of the aorta, and above the pancreas. It is joined by the branches from the semilunar ganglion of each side, by those from the small splanchnic nerve, and some filaments from the pneumo-gastric nerve behind the stomach also join it. The branches given off from the plexus accompany the cœliac axis, an offset being sent to each artery from it; as well as the diaphragmatic artery, the renal and capsular, the superior mesenteric, aorta, spermatic, and inferior mesenteric arteries. Around these the nerves still form plexuses, similar to those of the solar, and continue with the vessels to the different viscera: those with the aorta, superior and inferior mesenteric arteries, have been dissected. Solar Plexus.

The *cœliac plexus*, a prolongation from the nerves of the solar, closely surrounds the short trunk of the artery, and divides into secondary plexuses to accompany its branches. The *coronary*, the smallest, runs with the coronary artery, is joined by filaments from the right pneumo-gastric, and is distributed to the surface of the stomach along the small curvature. The *splenic* is formed of very small filaments which closely entwine around the artery, and from it filaments or plexuses are given off with the branches of the vessel to the stomach and the pancreas; it is then distributed to the spleen with the artery. The *hepatic*, the largest, is divided into an anterior and a posterior portion; the anterior encircles the hepatic artery, is joined by some filaments from the pneumo-gastric near the pyloric end of the stomach, sends secondary plexuses to the branches of this artery, viz. with those to the stomach, duodenum, and pancreas, Cœliac.

and a cystic to the gall-bladder, and then enters the transverse fissure of the liver with the vessel; the posterior, consisting of larger branches than the anterior, is continued on the vena portæ to the liver, and the nerves that enter into it are from the right side of the plexus, and right semilunar ganglion: it is finally distributed to the liver with the branches of the vein.

Diaphragmatic. The *diaphragmatic* plexus, one on each side, is very small, and is continued upwards on the artery of the same name to the diaphragm; but the nerves soon leave the artery, perforate the substance of the muscle, and join with the filaments of the phrenic nerve.

Renal and small Splanchnic Nerve. The *renal plexus* receives many small nerves which are continued to it from the lower and outer parts of the semilunar ganglion and solar plexus, it is joined also by the descending filaments of the *small splanchnic;* for this nerve, after it has passed through the crus of the diaphragm, divides into branches to join, internally, the solar plexus, inferiorly, — and these are the largest, — the renal plexus, and it also unites with the great splanchnic nerve. The plexus of nerves is continued to the kidney with the divisions of the artery. From the lower part some filaments are detached to join with others from the aortic plexus, to give rise to the spermatic, which supplies the testicle, or the ovary and the uterus.

Supra-renal. The *supra-renal plexus*, very small, is formed by some filaments from the outer part of the semilunar ganglion; it passes with the artery to the supra-renal capsule, to which it is distributed.

The direct continuation of the superior mesenteric with the substance of the solar plexus is now observable, and its distribution has been dissected with the branches of the artery to the intestine.

Dissection. To remove the stomach, duodenum, pancreas, and spleen from the body, tie the œsophagus as soon as it has passed through the diaphragm, and then cut it across; divide the branches of the cœliac axis and the nerves which are distributed to these organs; these may now be readily taken out to examine their structure with the rest of the intestinal canal, during the time that the body is placed on the face for the dissection of the back. If the dissector has sufficient time, before the change in the position of the body, he may proceed with the anatomy of the ligaments of the liver, which may be referred to, and then this viscus may be also taken out, to examine its structure; but otherwise these parts must remain till the body is turned back again. After the viscera are removed, detach the spleen from the stomach, cut through the duodenum near the pylorus, and distend the stomach with air, dissect off the peritonæal coat from its front and from a small part of the duodenum, and the extent of this coat, and the arrangement of the muscular, are seen.

In the substance of the stomach are found four layers, — an external peritonæal, an internal mucous, and intervening muscular and fibrous, with vessels and nerves between them. The *peritonæum* gives a perfect covering, except at the small and large curvatures, where an interval exists between the layers of the membrane in the small and great omentum, and into it the stomach protrudes when it is dilated; in this space are contained some cellular membrane, the arteries of the curvatures, and their nerves. Along the borders, too, it is less adherent than over the centre of the organ. The *muscular coat* consists of three planes or layers of fibres: the most superficial is constituted of longitudinal fibres which are continuous with those of the œsophagus, and they expand over the great extremity, and sides of the stomach, diverging from each other; along the small curvature they are arranged as a distinct band, and on the surface they are prolonged to the pyloric extremity, becoming more marked at this part. The middle layer is formed by orbicular fibres, which describe parts of circles, are more numerous in the centre and near the pyloric orifice, and, by their projection into the cavity of the stomach, the muscular and firm ring of the pylorus is constituted. The third or deep plane of the fibres, but little marked, is found at the great extremity of the stomach, over which they pass obliquely, instead of circularly, from the left of the cardiac orifice towards the right end, and on both surfaces of the organ. The muscular coat may be removed from a portion of the stomach, and this is most readily done near the pylorus, in order to see its thickness, which varies in different parts. The fibrous layer is now seen between the muscular and the mucous coats.

Structure of the Stomach. Peritonæum. Muscular Coat.

Enlarge a little the cardiac orifice, turn the stomach inside out, again distend it, but not too forcibly, and remove the layer of the mucous membrane from the fibrous; raise it also over the same extent as the spot from which the muscular was taken away, and at the same time detach it, in part, from the ring of the pylorus, whose prominence into the cavity is now marked, to see the muscular fibres surrounding it.

Dissection.

The *fibrous coat*, if the stomach be not too much distended, is strong enough to prevent the bursting of the mucous lining; it is white and shining, and gives resistance and strength to the viscus, so that if it be divided at any point, the mucous membrane protrudes through it; it is more closely united to the muscular than to the mucous coat, though a separate layer of cellular membrane is found on each side of it. The *mucous coat*, the most internal, is connected by its outer surface to the fibrous, by a thick layer of cellular membrane, and this union is more intimate at the cardiac than the pyloric extremity; it is also much thicker near the pylorus, and is raised into a prominent fold at this part by the subjacent ring of muscular fibre. Cut

Fibrous Coat. Mucous Coat.

open the stomach, and the appearance of the mucous membrane, when not stretched out, is seen; it is covered by small folds or rugæ, which allow of its enlargement in distention of this organ. It is soft to the feel, and in the natural and healthy condition is of a pale red or rose colour. This lining of the stomach is covered by the epithelium prolonged from the œsophagus, and its surface, when examined by means of a lens, is found to present small hexagonal depressions or cells, and into the bottom of these, small vertical tubes, situate between the mucous and cellular layer, are seen to open *; the margins of the cells are raised in parts, particularly near the pylorus. Some small mucous follicles of a roundish shape are scattered over the

Arteries. membrane. The branches of the *arteries* perforate the muscular layer, and, supplying it, ramify in the submucous cellular tissue, and are finally distributed to the mucous membrane.

Veins. The *veins* have the same distribution, beginning in the tissues

Nerves. in which the arteries end. The *nerves* from the pneumo-gastric can be followed to the muscular coat, and those from the sympathetic, on the arteries, also to the mucous.

Structure of the Duodenum. The *duodenum* or upper portion of the small intestine is larger in size than the jejunum or ilium, and has also thicker coats, which are similar in number to those of the stomach, and may be dissected in the same way, by distending it. The

Peritonæal. serous or *peritonæal*, is only partial, the first portion of the duodenum being covered as the stomach and remaining part of the small intestine, but the two others are destitute of a tube of the membrane, and are only in contact with it in front. The

Muscular Coat. *muscular coat*, thinner than in the stomach, consists of only two planes of fibres; a superficial, with fibres longitudinal in direction and difficult to see, since they are very thin; and a deep, with stronger circular fibres, which extend round the tube of the in-

Fibrous. testine. If the muscular coat be divided, the *fibrous* will be seen between it and the mucous.

Dissection. Invert the intestine and distend it with air, but not too forcibly, or the cellular membrane between the coats and beneath the mucous membrane will be distended, and destroy the appearance of the valvulæ conniventes, or folds on the inner surface of the mucous lining.

Mucous Coat. The *mucous coat*, attached by one surface to the fibrous, by a layer of cellular tissue, free by the other in the interior of the intestine, is covered by a mucous secretion, and is marked by

Valvulæ conniventes. numerous prominent folds of the membrane, the *valvulæ conniventes*, which project into the interior of the canal amongst the alimentary mass, serving to retard its progress, and to present a greater surface for the absorption of the alimentary matter.

* For a description of these, refer to Dr. Sprott Boyd's inaugural *Essay on the Structure of the Mucous Membrane of the Stomach.* Edinb. 1836.

These commence in the duodenum, about two inches from the pylorus, increase in number about its middle, and are prolonged into the jejunum; they do not extend round the intestine forming perfect circles, but about two thirds of the circumference of the tube, and they then bifurcate or are inflected to either side from the line of the circle; the centre of each is the deepest, and is near a quarter of an inch. Each fold is a projection of the mucous membrane, containing within it cellular membrane, with the submucous layer of vessels and nerves, and the fibrous coat is thickened opposite to it. Opening into the lower angle of the duodenum, on its inner side, is the aperture of the pancreatic and common bile-ducts, in a small papilla, but they may have separate orifices. When a blow-pipe or probe is passed into both ducts, the common is found to perforate the coats obliquely, lying for rather more than half an inch in them, and it is accompanied by the duct of the pancreas, which joins with it before it perforates the lining coat. There may be a second pancreatic duct opening separately. If a portion of the mucous membrane from the lower part of the intestine be gently washed, to remove the mucus from the surface, and then examined with a microscope, it will be seen to be covered with numerous conical or cylindrical-shaped processes, which give to the surface the appearance of velvet; these are the *intestinal villi*, which occupy the inner surface of the small intestine; their length is from one fourth of a line to a line, and in their interior is found a plexus of bloodvessels, and lacteal vessels. Covering the whole surface of the membrane between the villi are numerous small apertures, by which the *follicles of Lieberkuehn* open into the intestine; these foramina are in some parts so numerous that the membrane resembles a sieve. Reinvert the intestine, distend it, and seek the *glands of Brunner* near the pyloric end, by removing the peritoneal, muscular, and fibrous coats; they are small conglomerate glands, situate in the cellular structure beneath the mucous membrane, are visible without a lens, are found in greatest quantity in the upper part of the duodenum, and cease in the commencement of the jejunum.

Aperture of the Bile-duct.

Villi.

Follicles of Lieberkuehn.

Glands of Brunner.

The remaining part of the small intestine or the *jejunum* and *ilium*, about twenty feet in length, has no perceptible line to mark the termination of the one, or the commencement of the other; but the two upper fifths are assigned to the jejunum, and the three lower to the ilium; the former has thicker coats than the latter, because of its greater number of valvulæ conniventes, and it is also of larger size.

The Jejunum and Ilium.

Take a portion of the upper part of the jejunum, a piece of the ilium near the termination, and another from the centre of the small intestine; let each be about four inches in length, and distend it with air, to dissect the coats, as in the stomach.

Dissection.

Structure. The *peritonæal covering* is complete except on the side next
Peritonæal Covering. the attachment by the mesentery, and here the vessels and nerves enter. It is very closely united to the muscular, so that in taking it away in a small space the longitudinal fibres be-
Muscular Coat. neath are usually removed with it. The *muscular coat*, seen when the peritonæal is removed, has a longitudinal and circular layer of fibres, which completely surround the intestinal tube, the circular being the strongest. Dissect off this coat in a small
Fibrous. extent, to see the *fibrous*, which is similar to that of the duodenum and stomach; a cellular layer is also found on each side of this partition; open the three portions of intestine and
Mucous Coat. wash them out. The *mucous coat* in the portion of the jejunum is very similar to that in the duodenum, since the valvulæ conniventes are present in it, but in the ilium they have altogether disappeared. When a piece of the mucous membrane is examined under the microscope, the villi and follicles of Lieberkuehn are seen as in the duodenum; and in it will
Glands of Peyer. be seen at intervals the *glandulæ agminatæ* or *glands of Peyer*, which are oval patches situate on the side of the intestine opposite to the attachment of the mesentery, and in a healthy intestine they appear as white spots about a line in diameter, generally free from villi, and slightly raised in the centre, but without any aperture, according to Boehm, by which the whitish mucus that they contain can escape. Several of the spots are contained in one patch, and each is surrounded by a number of openings resembling Lieberkuehn's follicles, but they are not so circular. In the intervals of the membrane between the white spots, are seen the villi, rather larger than in the other parts of the intestine, and also the follicles of Lieberkuehn. In fever, these glands ulcerate, and leave cavities in the position of the white spots. Near the termination of the ilium, and in the lower part of the small intestine, are the single scattered
Glandulæ solitariæ. *glandulæ solitariæ*, which Boehm states to be of the same nature as the white spots in the glands of Peyer; they are surrounded like them by a circle of apertures, are covered with villi, have
Vessels and Nerves. no aperture, but contain a whitish mucus. The *vessels* and *nerves* in the small intestine perforate the muscular layer, supplying it, and then the fibrous, to be distributed to the mucous coat, as in the stomach. The lacteals and lymphatics, commencing in the mucous membrane and its villi, run to the lymphatic glands between the layers of the mesentery.

Layers of Cellular Tissue. Turn inside out a piece of the small intestine, after having cut through, here and there, the peritonæal and muscular coats, and inflate it forcibly; by this means the air distends the cellular membrane in the wall of the intestine, and by cutting it when dry, its disposition will be seen. If the intestine is half putrid, this will fail, because the air escapes.

The large The *large intestine*, about five feet long, or one fourth of the

intestinal tube, is larger at its commencement in the cœcum and ascending colon, than either the descending colon or sigmoid flexure, which are often reduced to the size of the small intestine. Of greater capacity than the jejunum or ilium, it differs also in being sacculated, and having three longitudinal muscular bands extending along it; and in having small processes of peritonæum — the *appendices epiploïcæ* — containing fat, attached to it, but chiefly to the transverse colon. The coats, too, of this intestine are thinner than in the duodenum or jejunum, and are also of a lighter colour. In the rectum, the large intestine again dilates, and the longitudinal bands are lost by their diffusion over the surface. Intestine.

Take the cœcum with a part of the ilium entering it, another portion from the centre of the large intestine, and a third from near the sigmoid flexure of the colon; distend them with air, and clean the cellular membrane from the cœcum without removing the bands from its surface. Dissection.

The *cœcum*, the largest portion of the intestinal tube, is somewhat of a conical shape, the widest part being above, continuous with the colon, — its extent being limited by the entrance of the small intestine, and the narrowest below, to which is fixed the vermiform process. It is sacculated by means of three longitudinal bands, which begin in the appendix, pass upwards over it, diverging from each other, so as to give rise to three large sacculi or protuberances, an anterior, and two posterior—a right and left: small processes of peritonæum containing fat are also attached to it. By the inner or left side, it is joined by the small intestine, about three fingers' breadth from its lower part; and below this, and rather posterior to it, is the *appendix vermiformis*, a small cœcal tube about the size of a goose quill, and measuring generally about three inches in length; it is connected to the under and inner part of the cœcum by a process of peritonæum, but its position and length vary much. Cœcum. Appendix vermiformis.

In the portion of the intestine taken from the centre of the colon, the same longitudinal bands and sacculated appearance are seen, with the appendices epiploïcæ which are longer, but the calibre of the intestine is diminished; and in that from the sigmoid flexure the sacculated appearance is less marked; the longitudinal bands are sometimes only two instead of three, or they may be disappearing. The diameter of this part of the canal is often very much smaller. The coats of the large, are the same in number and structure as those in the small intestine. Colon.

The *peritonæal coat* gives, generally, only a partial covering to the front of the cœcum, but it surrounds the lower part and fixes the appendix vermiformis to it by a kind of mesentery; at other times it extends behind the cœcum, covering its posterior surface, and forms a suspensory fold which fixes it to the right iliac fossa. On the transverse colon it closely adheres to the Structure. Peritonæal Coat.

upper and lower surfaces of the intestine, and leaves a space both at the anterior and posterior borders, to which the great omentum and transverse meso-colon are attached. On the portion of the sigmoid flexure it is the posterior surface, as before seen, which is uncovered; so that all the colon, except the transverse part, is much less surrounded by the peritonæum than the small intestine; and the surface of either the ascending or the descending colon may be reached by an incision through the posterior wall of the abdomen, without injuring the serous membrane which partially invests it. The *muscular coat* consists of longitudinal and circular fibres: the longitudinal, the most marked, are collected into three bands which extend along the intestine at different parts of its circumference, and these, being shorter than the tube, produce, by their attachment to it, the sacculated or folded form. If the peritonæum be carefully raised from the bands, the fibres will be seen; they commence in the longitudinal muscular coat of the appendix vermiformis, and then diverge from each other, ascending over the cœcum; the anterior, or right band, is larger than the others, and the posterior sometimes unite together on the descending colon; on the rectum they are again scattered over the whole surface. When these bands are divided, the pouches are destroyed, and the intestine is much lengthened. The circular fibres surround the tube of the colon in the same manner as in the small intestine. The *fibrous coat* is exposed by taking away the peritonæal and muscular coats from a portion distended with air; it is the same in the large as in the small intestine, and a layer of cellular membrane is placed on each side of it. The *mucous coat* is to be examined by opening the large intestine, but the cœcum should be hung up to dry, in order that the form of the ilio-cœcal valve may be more readily observed; but to examine its structure, the dissection must be made, at another time, on it in a recent state. When the mucous membrane is placed under a microscope, it is perceived to be covered by numerous small apertures, the mouths of the *simple tubular follicles*, which are placed in the mucous membrane of the large intestine, from the ilio-cœcal valve, at which the villi of the small intestine terminate; and by a vertical section of it these may be seen to extend below its surface. Some larger *solitary follicles* of a conical shape, the base of the cone being downwards, are also found in it, but chiefly in that lining the cœcum and appendix vermiformis. The *vessels*, *nerves*, and lymphatics have the same distribution in the large as in the small intestine.

Muscular Coat.

Fibrous Coat.

Mucous Coat.

Tubular Follicles.

Solitary.

Vessels and Nerves.

When the distended cœcum is dry, make an opening into its lower part, cut a piece out of the ilium close to its junction with it, and take away the portion included in the ligature. On looking into it, small prominent folds corresponding to the depres-

Interior of the Cœcum.

sions between the sacculi on the outer surface are seen to extend into it; one of these, much larger than the rest, projects on the inner side for the extent of half an inch or more, and immediately above the junction of the small with the large intestine, but it gradually subsides as it is continued to the outer and posterior part of the tube, and its extremities end on different parts of the wall. This fold serves to separate the cavity of the cœcum from that of the colon, and by dividing the muscular band which crosses it, it may be seen to be only a folding inwards of the coats, between the layers of which are contained vessels; it assists, also, in forming one side of the aperture of termination of the ilium. Perforating the inner side of the cœcum, below the fold which marks its separation from the colon, is the small intestine, which becomes elongated from before backwards as it is passing through the coats, one half of its circumference being applied to the projection, before described, in the interior, and the other, united to the wall, protrudes into the cavity, and ends by a free margin at a short distance from the former, constituting the opposite side of the aperture between the two. Before the ilium enters the cœcum it is closely united to its inner side by peritonæum and cellular membrane; but, if these be carefully separated in a recent and distended specimen, the passage through the coats is seen to be almost direct: this may be done, too, in the dried preparation, when it will be apparent that the lower or semilunar border of the opening consists of the coats of both the large and small intestine applied to each other. The aperture of communication in a dried preparation is semilunar in shape, with the angles directed forwards and backwards, the upper boundary being straight and formed by the vertical fold of the interior, the lower, semilunar, constituted by the coats of both the cœcum and small intestine, and its size varies with the state of distension of the cœcum; but, as its margins are directed obliquely inwards towards each other, and the extremities are connected to the vertical fold between the cœcum and colon, it has been described as being situated in the folds of a valve — the *ilio-cœcal* — which consists of a vertical or *ilio-colic* portion that extends more or less round the interior of the cœcum, the extremities of it being called the *frœna;* and of a horizontal or *ilio-cœcal* part, which is concave below, and convex above: the former acting as a valve between the colon and ilium, and the latter between the cœcum and ilium. The opening of the vermiform appendix is below and rather behind that for the ilium, a small fold of the mucous membrane partly closing the aperture and acting as a valve; the appendix itself may be opened if distended: it is a hollow tube closed below, whose use is unknown, and in which, in the recen tstate, is contained a thick mucus.

Ilio-cœcal Valve.

Dissection. Place the pancreas on its front, and follow back from right to left the duct already exposed as it perforated the duodenum; and separate from each other some of the lobules of which it consists.

Structure of the Pancreas. The *pancreas* is a conglomerate gland of the same nature as the salivary, it is of a greyish-white colour, and secretes the pancreatic fluid which assists in the process of digestion; it is covered only on the anterior surface by peritonæum, is destitute of any distinct capsule, but is surrounded by cellular tissue which projects into the interior, separating its lobes and lobules. A small duct issues from the different grains composing the lobules, and joins with similar offsets from other granules to form larger tubes that unite together in the *pancreatic duct* or *duct* Duct. of *Wirsung*, which occupies the substance of the pancreas, situated nearer the back than the front, and commences by a small bifurcated extremity in the tail; in its course along the gland it receives other small branches which come from the different lobes, and, increased in size, it is usually joined at the right extremity or head of the pancreas by a large branch from the small pancreas. It then leaves the gland, perforates the duodenum, and opens either conjointly with the common bile-duct, or by a separate aperture, as before seen: the duct from the upper part of the pancreas may also open separately into the duodenum above the point of the common orifice. The duct consists of an external thin coat and of an internal mucous. The *vessels* and *nerves* for the supply of the pancreas have been before mentioned.

Structure of the Spleen. The *spleen* is a vascular, spongy organ, of a reddish or greyish colour, and of a friable texture, easily rupturing and breaking down under pressure; but its use is unknown. Its coverings are a serous and fibrous coat; — the serous, derived from the peritonæum, entirely surrounds the organ, except where the vessels enter, and at this part it is reflected along them to the stomach, forming the splenic omentum; — the fibrous coat, stronger than the peritonæal, closely surrounds the parenchymatous structure, determining the form of the organ, and sends processes into its interior, which cross with others so as to produce a cellular structure similar to that of the corpus cavernosum of the penis. At the fissure on the inner surface the fibrous envelope is continued into the interior around the vessels, giving them sheaths, which send off smaller ones with their branches, and these are joined by the small processes prolonged from the circumference, thus also assisting to form the cellular arrangement: this may be shown by exposing the spleen to a current of water to remove the mass contained in the cells, or by inflating and drying it. When the spleen is cut into, a reddish, pulpy, dirty-looking substance, contained in the cellular structure, may be pressed from it, and this consists of a mass of

globular red-brown granules, easily separated from each other, and about the size of the red particles of the blood. The *arteries* of this organ, very large in proportion to its size, run in a tortuous manner in its substance, accompanied by the fibrous or trabecular tissue which gives them sheaths, and their capillary branches end in the plexuses of the venous canals; but the small arteries ramify in tufts in the mass of granules contained in the cells before joining the veins. The *splenic vein* is remarkable in presenting large venous canals which occupy the intervals of the fibrous structure of the spleen, appear to be destitute of venous coats, and anastomose with each other much in the same manner as the veins in the penis:—the alteration in the size of both these organs depending upon the distention of the canals. The venous plexuses unite together in the splenic vein, which leaves the organ by the fissure, with the artery, and has been seen to run behind the pancreas to join the superior mesenteric in the vena portæ. Connected to the sheaths of the arteries are the *corpuscules* of *Malpighi,* which are difficult to be distinguished in the human spleen, but in that of the pig they are seen by maceration; they are round white bodies, about one seventh or one fourth of a line in diameter, and disposed in clusters which project into the pulpy substance; each contains a fluid white matter, but it is not ascertained whether small branches of the arteries perforate them.*

Arteries. Vein. Corpuscules.

The liver is retained in its position in the right hypochondrium, by folds of peritonæum which attach it to the wall of the abdomen or to the diaphragm, and have been named ligaments. The largest of these — the *suspensory* or *falciform ligament* — is situated between the upper convex surface of the liver and the abdominal wall; it is curved, the base being forwards and the apex backwards; its upper margin, convex, is fixed to the linea alba above the umbilicus, to the rectus muscle of the right side, and to a part of the under surface of the diaphragm; the lower, concave, and of much smaller extent than the upper, adheres to the superior surface of the liver. Two layers of the serous membrane enter into it, they may be separated with care, and be traced to be continuous, below, with that covering the upper surface of the liver, and above, with the membrane on the abdominal wall and diaphragm; in the base or free part is contained the obliterated remains of the umbilical vein, which runs from the umbilicus to the under surface of the liver, and has been named the *round ligament;* and the fold results from the passage of the vein to the liver without perforating the peritonæum. The *left lateral* or *triangular ligament* attaches the left lobe to the diaphragm, and reaches from the suspensory ligament on the right, to the left of the œsophagean opening

Ligaments of the Liver. Suspensory. Round. Left Lateral.

* See Müller's *Physiology,* translated by Baly, p. 569.

in the diaphragm, in front of which it is placed; two layers are also found in it, and they are continuous with the peritonæum on the upper and under surfaces. It is not connected to the posterior margin of the left lobe, but to the upper surface anterior to it. The *right lateral* or *triangular ligament*, formed also as the left of two layers of peritonæum, is not so readily seen, because it lies deeply in the right hypochondriac region, and to obtain a view of it the liver must be brought forwards. It is fixed to the posterior border of the right lobe, and the layers that enter into it are not so close together as in the left; it lies in front of the vena cava which is passing through the diaphragm, and also above the right kidney. The *coronary ligament* is situated at the junction of the right and left lateral with the suspensory; the posterior portion of the peritonæum forming it is flat, and the anterior oblique, so that a triangular space is enclosed between them, in which the liver is uncovered by peritonæum; and between the layers of the other different ligaments it is also uncovered.

Right Lateral.

Coronary.

Dissection.

The relations having been observed, remove the liver from the subject by cutting across the ligaments one after the other; divide the hepatic artery, and the vena cava which will be found lying beneath the posterior border, and rather to the right of the middle line; the vein is to be cut through both where it is perforating the diaphragm, and at its contact with the liver. Place the liver on a table with the under surface uppermost, and remove the cellular membrane from the vessels and duct at the under part of the right lobe, or the transverse fissure; the duct and vena portæ may be distended with air; clean the gall-bladder and its duct after they are inflated, and follow backwards to the vena cava the remains of the umbilical vein, which lies in the longitudinal fissure.

The Liver.

Form.

Borders.

Posterior.

Anterior.

Surfaces. Upper.

The liver, a glandular organ for the secretion of the bile, is the largest viscus in the cavity of the abdomen, but the relative size is smaller in the adult than in the fœtus. It is of an irregular form, the transverse measurement being greater than the antero-posterior, and it is divided into two unequal lobes by the falciform process above, and the longitudinal fissure below; the right side and posterior border are thicker than the other parts of the liver. The *posterior border*, thick, particularly on the right side, is marked by a notch which divides it into a right and left portion, contains the vena cava, and corresponds to the spine and pillars of the diaphragm; to the portion to the right of the excavation is attached the right lateral, and to that on the left, the left lateral ligament. The *anterior border*, thin and convex, is on a level with the margin of the ribs near their attachment to the sternum, and presents two notches or hollowed out portions, one for the umbilical vein, and the other to the right of this is opposite the gall-bladder. The *upper*

surface, convex, is divided into two by the falciform ligament, the right portion being the larger; the *lower*, presenting an irregular surface, is also divided by the umbilical fissure into a right and left lobe, the former being again subdivided into the square lobe, the Spigelian lobe, and the lobulus caudatus. The *left lobe*, or division of the liver, smaller than the right, is separated from it by the fissure for the umbilical vein, and is rather concave on the under surface; the *right* is much thicker than the left, and in it the greater part of the substance of the liver is found; to it is attached the gall-bladder, and the other lobes of the liver are projections on its under surface. The *lobulus quadratus* or *anonymus*, a small oblong-shaped portion, is placed between the gall-bladder and the umbilical fissure, and in front of another,—the transverse,—which extends into the right lobe from the umbilical, and receives the vessels; it reaches forwards to the free margin of the liver. The *lobulus Spigelii* or *middle lobe* is situated behind the transverse fissure and small omentum, and between the umbilical or longitudinal fissure on the left, and that for the vena cava on the right: two narrowed portions are prolonged from it, one backwards towards the posterior border, between the longitudinal fissure and that for the vena cava, and the other horizontally to the right behind the transverse: this last has been called *lobulus caudatus*; it extends to the right as far as the fissure, and then subsides in the substance of the right lobe. The grooves on the under surface for the vessels are named fissures. The *longitudinal* or *horizontal* passes from the anterior thin, to the posterior thick margin of the liver between the right and left lobes; the anterior part, or that in front of the transverse fissure, lodges the obliterated remains of the umbilical vein, which is often covered by a process of the liver — pons hepatis — extended over it: it is deeper than the posterior, and is called the fissure for the umbilical vein; and the posterior portion, situate between the left and the Spigelian lobe, contains the obliterated ductus venosus of the fœtus, or the continuation of the umbilical vein, and is named fissure for the ductus venosus. The *transverse fissure* extends horizontally to the right from the longitudinal, and has in front of it the lobulus quadratus, and behind the lobulus Spigelii and the caudatus; it is placed rather nearer the posterior than the anterior border; the small omentum is attached to this part of the liver, and in it are found the vena portæ, hepatic artery, nerves, and lymphatics, with the biliary duct. The *fissure* for the *vena cava* is to the right of the lobulus Spigelii, or between it and the right lobe, and the liver often forms another arch or bridge over this vessel. The *depression* for the *gall-bladder* is on the right lobe, and to the right of the lobulus quadratus. There are two superficial depressions on the under part of the right lobe, one anteriorly

Lower. Lobes. Left. Right. Square. Spigelian. Caudatus. Fissures. Longitudinal. Transverse. Fissure for the Vena cava. Fossæ for the Gall-bladder.

Colon, Kidney, and Stomach. for the upper angle of the ascending colon, and a larger one behind for the right kidney. The left lobe is also sometimes flattened in a spot corresponding to the stomach, with which it is in contact.

Vessels. Umbilical Vein. The *umbilical vein*, open in uterine life to convey the blood from the placenta to the fœtus, but now, for the most part, an impervious cord, extends upwards and to the right from the umbilicus to the under surface of the liver; and, lying in the longitudinal fissure, it gives branches to the left lobe, and divides, opposite the transverse, into a right branch to join directly the right portion of the vena portæ, and into one, the ductus venosus, which continues it backwards to the vena cava. The blood, conveyed in it at this time, circulated in the left lobe by its own branches; in the right, by means of the divisions of the vena portæ, which are continuous with it, and the remainder of the blood was carried on to the cava; but after birth the vein is closed as far as to the transverse fissure, forming the round ligament; it is also impervious behind this, constituting the obliterated ductus venosus, which is sometimes open, but the branches to the right and left lobes, opposite the fissure, remain unclosed, and serve afterwards as the channel for the portal circulation to the left lobe. In the transverse fissure, the hepatic duct is the most anterior, the artery next, and the vena portæ most posterior of the vessels. The *hepatic ducts* are two in number, one for the right, and one for the left lobe of the liver; they are short, and soon unite in the common bile-duct which, about one inch and a half long, is joined by the cystic to give rise, as before seen, to the ductus communis choledochus. The *hepatic artery* is small for the size of the liver, and supplies the structure of the gland. It is a branch of the cœliac axis of the aorta, and, near the transverse fissure, divides into a right and a left branch; the left enters the substance of the organ at the left part of the transverse fissure, and the right, after giving the cystic branch to the gall-bladder, sinks into the right extremity of the fissure: the distribution of these vessels in the interior of the liver, surrounded by the capsule of Glisson, and accompanied by the branches of the vena portæ, hepatic duct, and nerves and lymphatics, will be followed when dissecting its structure. The *vena portæ*, the most posterior of the vessels, divides into a branch to the right lobe, which enters at the extremity of the transverse fissure, and one to the left, which is much the longest, since it is united to the branches of the umbilical vein which remain open after the obliteration of its trunk; and the third branch is a smaller one to the lobulus Spigelii. The commencement of this vessel has been seen, and it conveys blood from the chylo-poietic viscera to the liver, for the secretion of the bile.

Hepatic Ducts.

Hepatic Artery.

Vena portæ.

Structure. The liver is invested by a *serous membrane* which covers it

except in the intervals of the ligaments, in the transverse and longitudinal fissures occupied by the vessels, and in the parts on which the gall-bladder and vena cava rest. The other envelope is a thin *fibrous membrane* which is closely united to the peritonæum, and sends processes inwards from its under surface, which separate the ultimate particles or the lobules from each other. At the transverse fissure in the right lobe it sends a prolongation or sheath into the interior, with the vena portæ, the hepatic artery, ducts, nerves, and lymphatics; and this, with the cellular membrane that surrounds the vessels, constitutes the capsule of Glisson, which accompanies the branches of the vessels that enter by the transverse fissure, even to the lobules.* The colour of the liver is of a reddish brown, and it is very brittle under the finger. Follow into its substance the vessels that are found in the transverse fissure: their branches run transversely, or from side to side, and if they are cut across they do not remain open, because the sheath that accompanies them allows of their retraction; but another system of vessels, the venæ cavæ hepaticæ, which run from before backwards to join the vena cava, remain open when cut across, inasmuch as they are destitute of a sheath, and therefore the sides are kept apart by the numerous small branches that enter them. When the *hepatic artery* is traced into the liver, it is found that its branches run with the other vessels and nerves that enter the transverse fissure, being enclosed with them in the capsule of Glisson; that its small branches, named *vaginal*, anastomose with each other in the sheath, so as to give it a vascular appearance; and that from the vaginal arteries, small branches, — the *interlobular*, — are sent between the lobules, to supply their structure: this artery also supplies the vasa vasorum to the different other vessels contained in the sheath, as well as to the venæ cavæ hepaticæ. The *veins* corresponding to this artery are continuous, according to Kiernan, with the branches of the vena portæ. The *vena portæ* has a distribution in the liver similar to that of an artery, and the blood flows from the trunk to the branches; entering at the transverse fissure, its primary branches, which lie in channels or spaces in the liver — the portal canals, are enveloped by the cellular sheath, and divide into secondary ones, which occupy smaller spaces, still accompanied by a branch of the artery and duct, nerves, and lymphatics; from these branches smaller offsets — the vaginal — arise, and these, dividing in the sheath into many branches, give off the minute interlobular veins, which surround the various lobules, except at the base, anastomose with each other, and then enter the interior to join the system of vessels of the venæ cavæ

Serous Membrane.

Fibrous Membrane.

Vessels.

Hepatic Artery.

Vein.

Vena portæ.

* For researches into the anatomy and physiology of the liver, see Mr. Kiernan's elaborate paper in the Philosophical Transactions, part ii., 1833, from which the following facts are taken.

hepaticæ. In some of the smaller spaces, the branches of the portæ are often not entirely surrounded by the vascular sheath, and then, instead of supplying vaginal branches, they give off the small interlobular veins. This vein contains the blood from which the bile is secreted, and it commences by one system of vessels in the interior of the liver, from the branches of the hepatic artery, and by another, in the remaining chylo-poietic viscera. The *hepatic duct* commences in plexuses in the interior of the lobules, from which branches pass out to form interlobular ducts, which Kiernan supposes to anastomose with each other around the lobule, as is the case with the interlobular veins of the vena portæ: these small ducts unite into larger or vaginal branches, which join the trunks as they lie in the capsule of Glisson in the portal canals, and these again unite to give rise to the right and left hepatic ducts, which form the common bile-duct by their junction; thus this tube, like the other vessels that enter in the transverse fissure, has both vaginal and interlobular branches. The ducts closely accompany the artery in the portal canals, and are very freely supplied with blood. "From that edge of the liver connected to the ligament (left lateral) numerous ducts emerge, which ramify between the two layers of peritonæum of which the ligament is composed." They divide, anastomose with each other, and, forming arches, return to the liver, to join with others issuing from it. There are also small branches of the hepatic artery, vena portæ, and hepatic veins with absorbents between the layers; and to see them, Kiernan recommends that the ligament should be dried on glass after the ducts are injected with size or mercury. The *nerves* and *lymphatics* have been followed only into the portal canals. The *capsule of Glisson* is described by Kiernan as "a cellulo-vascular membrane, composed of the vaginal branches of the duct, vein, and artery, ramifying in a layer of cellular tissue." A process of this sheath also accompanies the vessels in the intervals between the lobules, forming a cellular layer around each, except at the base; and the cellular membrane is also continued into the interior with the branches of the interlobular veins of the portæ. The *venæ cavæ hepaticæ* run from the anterior to the posterior border of the liver, and are destitute of a sheath of cellular membrane; they commence by a small vein — the intra-lobular — from the interior of each lobule; these unite together in larger veins — the sublobular, — and by the junction of these are formed the hepatic trunks, which leave the posterior part of the liver in its large depression, and open into the cava by means of three or four large orifices. Its divisions lie also in spaces or hepatic venous canals; the sublobular veins, the first branches of the hepatic trunks, have thin coats, and are surrounded on all sides by the bases of the lobules which are deprived of a cellular investment, and from which the intra-

Hepatic Duct.

Nerves and Lymphatics.

Capsule of Glisson.

Venæ cavæ hepaticæ.

lobular veins are received; whilst the hepatic trunks or larger divisions are thicker than the sublobular, receive larger branches of the veins, and lie in canals formed by the surfaces of the lobules, which are invested by the capsule of Glisson. The small apertures marking the junction of the branches are seen in the interior of the veins when they are opened. By an examination with the microscope, the mass of the liver is seen to consist of numerous *lobules*, or *acini* of some anatomists, which resemble leaves in their connection to the small vein that leaves them below, the lobule being analogous to the lamina, and the intra-lobular vein to the petiole of the leaf. "The lobules are not, however, flattened bodies like leaves; for, as the smaller veins enter the central vein in every direction, so small processes project in every direction from the lobules, the number of processes being equal to the number of veins terminating in the central vein." It is surrounded by a sheath of cellular membrane prolonged from the capsule of Glisson, except at the base which is closely united to the sublobular hepatic vein, and from which the intra-lobular vein emerges; the cellular membrane is also continued into the lobule. Around it, in an injected liver, is the anastomotic circle of the interlobular veins of the vena portæ, of the interlobular branches of the hepatic duct, and of the artery; and if one be divided transversely, it presents the central intra-lobular vein, from which branches proceed to the projections on its circumference. Each lobule has in its interior a plexus of biliary ducts, which anastomose together, forming the reticulated *lobular biliary plexus*, which is continuous externally, by branches that perforate its substance, with the interlobular divisions of the ducts in the investment of cellular membrane; on the coats of the ducts in the plexus, the secretory branches of the vena portæ ramify. Within it also is the *lobular venous plexus* of the ultimate branches of the vena portæ, which is derived from the interlobular veins of this same vessel around its exterior; it is situated near the circumference of the lobule, the intervals between its branches being occupied by the lobular biliary plexus of the duct, and from it numerous small branches converge to the centre to end in the intra-lobular vein. From its centre issues the *intra-lobular vein* whose branches are continuous with those of the vena portæ, and it conveys the blood from the lobule, after the secretion of the bile, by opening into the sublobular vein. The *arteries* for the supply of the structure of the lobule are derived from the branches of the hepatic artery, and they end in the lobular venous plexus; but nerves and lymphatics have not yet been followed into their interior, though superficial lymphatics occupy the surface of the liver. The bile is secreted from the branches of the vena portæ in the lobules by means of the lobular

The Lobules or Acini.

Form.

Sheath.

Composition.

Lobular biliary Plexus.

Lobular venous Plexus.

Intra-lobular Vein.

Arteries.

Nerves and Lymphatics.

biliary plexuses, and the blood from which it is secreted is obtained from the chylo-poietic viscera, partly from the ramifications of the hepatic artery in the liver, and partly from the other arteries sent to the remaining organs of this class. The blood from which the bile has been separated is conveyed from the lobules by the intra-lobular veins, and then by the other branches of the hepatic veins to the vena cava; and the bile, the product of the secretion, by the interlobular ducts to the hepatic duct. When congestion of the hepatic venous or intra-lobular vein takes place, the margin of the lobule is pale; but when the portal venous, or lobular venous plexus is congested, the centre appears light coloured in comparison with the circumference.

Gall-bladder. The *gall-bladder*, or receptacle of the secreted bile, is situated in a depression on the under surface of the right lobe, and to the right of the lobulus quadratus; it is conical or pear-shaped, the larger end being directed upwards and forwards to the anterior margin of the liver, beyond which it projects when it is distended, so as to touch the abdominal wall; and the smaller, in the opposite direction, reaches to the transverse fissure, and ends in the cystic duct which is slightly convoluted at this part. Its surface, in contact with the liver, is separated only by cellular membrane, so that it can be readily detached; the other is covered by peritonæum, and is in relation with the upper part of the ascending colon, and with the first part of the duodenum.

Structure. The gall-bladder has a peritonæal, fibrous, and mucous coat, with layers of cellular membrane connecting one to the other.

Peritonæal Coat. The *peritonæal*, is only partial, the membrane being reflected over the under surface, so as to attach it to the liver, and the portions of the two, therefore, in contact, are not covered by the serous membrane. The larger extremity is entirely surrounded, and though it is distended so as to project beyond the margin of the liver against the abdominal wall, is still covered by it.

Fibro-cellular. The *fibro-cellular* coat, similar to that in the wall of the intestines, gives a perfect covering to the sac, and limits, by its strength, the distension of the organ; on the surface of this the cystic vessels ramify, and it is united to the liver by cellular membrane. Muscular fibres have been described as entering

Mucous. into the structure of the coats. The *mucous coat*, the most remarkable, may be studied in one instance, in the recent state, by opening the gall-bladder; but it should also be seen on another specimen distended and dried. In the interior it is thrown into numerous folds or rugæ, and in enlarged bladders, or in those in which gall-stones have existed, the areolar or honeycomb appearance of the membrane is much better marked. It is continued through the cystic into the common bile-duct, and at the commencement of the cystic it forms folds

which are best seen in a dried preparation: they are small horizontal projections into the tube, about nine in number, and placed alternately on the opposite sides of the canal, are fixed to the wall by one margin, and are free in the cavity by the other. Their use is to facilitate the ascent of the fluid into the gall-bladder, by supporting the column. The *cystic duct* in which the gall-bladder ends is about an inch and a half long, and joins the common hepatic at an acute angle to form the common bile-duct. Its coats are the same as those of the gall-bladder, and at the junction of the cystic and hepatic ducts is a fold of the mucous membrane. The *cystic artery* is a branch of the right hepatic, and at the neck of the gall-bladder it divides into two branches, which ramify on the surfaces. The *vein* opens into the vena portæ near the liver; the *nerves* accompany the artery, and are from the hepatic plexus: the lymphatics are numerous.

Cystic Duct.

Cystic Vessels.

Nerves.

The body being turned back again, proceed with the following dissection; or if the position of the subject is not to be changed, continue with the same. Remove the peritonæum from the abdominal surface of the diaphragm, by tearing it off, the knife being used but seldom, and chiefly to detach it from the central tendinous portion of the muscle; clean the semilunar ganglion of the left side; take from the surface of the aorta and cava, in the middle line, the plexuses of the sympathetic, as well as the cellular membrane that covers them, and trace the iliac arteries and veins, or the bifurcations of the aorta and cava, to Poupart's ligament; the iliac artery is crossed by the ureter and spermatic vessels, and near Poupart's ligament the genito-crural nerve lies in front of it: these parts should not be displaced in removing the cellular structure in which they are imbedded. On each side of the spine, clean away the fat from the kidney, its vessels, and supra-renal capsule; then dissect the psoas muscle which is situated beneath it, taking care of the nerves, and reflect inwards the fascia that covers it; but on one side leave this untouched till it is examined. The genito-crural nerve is to be found in front of the lower part of the psoas muscle, since it perforates it about the middle; the ureter and spermatic vessels also cross this surface; along its inner border, close to the bodies of the vertebræ, is a chain of lumbar lymphatic glands, and the abdominal gangliated cord of the sympathetic; and escaping from beneath the outer border are some of the remaining branches of the lumbar plexus, the ilio-inguinal and musculo-cutaneous being above, the external cutaneous at the middle, and the large anterior crural at the lower part: the obturator nerve is found to the inner side of the muscle and below it. External to the psoas, and occupying the interval between the last rib and crest of the ilium, is the quadratus lumborum muscle, covered by a

Dissection.

layer of fascia derived from the fascia lumborum; this may be allowed to remain for the present; and crossing its upper part is the last dorsal nerve, and a branch from a lumbar artery. In the iliac fossa is the iliacus muscle, covered also by the iliac fascia, which is also to be left on the one side.

Branches of the Aorta. The relative anatomy of the aorta and vena cava was seen before the different viscera were removed; but the origin of the branches, as well as the arteries which could not be then dissected, can now be examined. The extent of the abdominal aorta is from the opening between the fleshy pillars of the diaphragm, opposite the last dorsal vertebra, to the left side of the body of the fourth lumbar vertebra, and it here divides into the two common iliac arteries. The phrenic arteries arise from each side of the aorta, immediately after it has entered the abdomen; the cœliac axis springs from it close to the margin of the tendinous ring of the diaphragm, and about a quarter of an inch below is the superior mesenteric artery; half an inch lower are the renal arteries; close above, on each side, the capsular to the renal capsule, and below, the spermatic; about half an inch above the bifurcation is the inferior mesenteric, and from the angle of division is the lateral sacral artery. The small lumbar branches arise from the posterior part of the aorta, one being opposite the centre of each vertebra, as in the thorax. Examine, now, the branches that have not been described, with the exception of the lumbar and middle sacral, to be afterwards seen.

Diaphragmatic Artery. The *diaphragmatic* or *phrenic arteries*, two in number, arise, one on each side of the aorta, as soon as it appears in the abdomen. Each branch is directed upwards and outwards over the corresponding crus of the diaphragm, the left passing behind the œsophagus, and the right behind the vena cava, and it divides into an internal and external branch; the internal turns forwards round the cordiform tendon, and anastomoses with branches from the internal mammary, as well as with its fellow; the external, the larger division, runs outwards to the attachment of the muscle, dividing into branches which supply the diaphragm and supra-renal capsule, and inosculate with the intercostal arteries.

Veins. Two *veins* accompany each artery, and they open into the inferior cava.

Plexus of Nerves. The *diaphragmatic plexus of nerves* is derived from the solar plexus, it encircles the artery at first, but the filaments afterwards leave it, sinking into the diaphragm which they supply, and in it they join with filaments of the phrenic nerve.

Phrenic Nerve. The *phrenic nerve* of the cervical plexus may now be followed to its termination. Its filaments of distribution perforate the diaphragm, and then spread out before entering the fleshy fibres in which they terminate; one filament from the right nerve

passes transversely behind the cava, to join with a similar one from the left, in front of the crura of the diaphragm.

The *renal arteries*, two in number, and of considerable size, arise, one on each side of the aorta, about half an inch below the superior mesenteric, and come off nearly at a right angle with the aorta; each is directed downwards and outwards to the kidney, near which it divides into four or five branches which enter its fissure between the vein and the ureter. The right renal artery is longer than the left, because of the position of the aorta on the left side of the spine, and oftentimes arises lower down; it is covered at first by the vena cava, and then by its corresponding vein, and it crosses the spine and psoas muscle; the duodenum and pancreas are also in front of it. The left is beneath its vein, and crosses the psoas muscle. They supply small branches to the supra-renal capsule, and to the cellular membrane around the kidney. The varieties in their origin are very frequent, there being two or three arteries for one or both kidneys: when there are two to the right side, one may pass before, and one behind the vena cava. Renal Artery.

The *renal vein* commences by four or five branches which leave the kindney at its fissure, and unite into a trunk that runs almost transversely inwards, superficially to its accompanying artery, to join the vena cava. The right is the shortest, this difference depending upon the position of the vena cava on the right side of the spine; and its junction with the cava is situated higher than the union of the left with it. The left vein, longer than the right, crosses the aorta close to the origin of the superior mesenteric artery, beneath which it is placed, and when the inferior transverse portion of the duodenum crosses the aorta near the origin of the mesenteric, the intestine is partly in front of it. Each vein is joined by some small branches from the supra-renal capsule, but the left receives the left capsular veins, and in addition, the left spermatic, which opens into it at a right angle. The size of the vena cava is much increased after the union of the renal veins; and, occasionally, the common iliac of each side extends upwards to the renal, before the left crosses the spine to unite with the right iliac vein in the ascending cava. Vein.

The *capsular arteries* are small branches which leave the aorta, one on each side, close above the origin of the renal. Each runs outwards, giving small branches to the cellular membrane, and near the supra-renal capsule divides into branches which run on the surface of this body, and then perforate it to be distributed in it: in the fœtus, these arteries are as large as the renal. The arteries from the aorta to this body are called the middle capsular, those from the diaphragmatic being named superior, and those from the renal, inferior capsular. Capsular Arteries.

The *veins* commence in the supra-renal capsule, and open on Veins.

the right side into the vena cava, and on the left into the renal vein.

Spermatic Artery.

The *spermatic artery* arises on each side of the aorta close below the renal; it descends with a direction outwards over the psoas muscle, the right passing also over the inferior cava, to reach the vein of the same name; it then continues to the internal abdominal ring, accompanied by its vein, and surrounded by the spermatic plexus of nerves, and crosses in front of the ureter, and the external iliac artery near its termination; as it passes through the ring, it comes into contact with the vas deferens which separates it from the epigastric artery, and its distribution in the cord, and to the testis, are seen with the dissection of these parts. Each is placed beneath the peritonæum, that of the left side being crossed by the sigmoid flexure of the colon, and that of the right by the termination of the ilium in the cœcum. In the female, the spermatic artery descends into the pelvis, enters between the layers of peritonæum in the broad ligament of the uterus, and distributes branches to the ovary, uterus, and Fallopian tubes; these anastomose with the uterine arteries from the internal iliac. These arteries are remarkable for their small size and great length; and in the male their direction is more outwards than in the female: though straight in the first part of their course, they become tortuous near the testis, and in the cord. Whilst the testes were in the abdomen near the kidneys, the spermatic vessels were short, but they elongated with the removal of the testicle from this spot. Its origin varies much on the two sides.

Vein.

The *spermatic vein* commences, in the male, in the testis and epididymis, and in the female, in the uterus, ovary, and Fallopian tube. In the male, it is divided in the cord into many branches, which anastomose, and form the spermatic plexus; it then enters the abdomen by the internal abdominal ring, ascends over the psoas muscle and ureter, and about the middle of the psoas gives rise to another plexus,—the *plexus pampiniforme:* the vein on the left side opens into the left renal, and that of the right into the vena cava, opposite the second or third lumbar vertebra, and below the renal vein. The left spermatic vein sometimes joins with the inferior mesenteric, and, through it, with the system of the vena portæ.

The middle sacral and the lumbar arteries will be dissected with the parts to which they are distributed.

Common Iliac Artery.

The *common iliac* arteries run downwards and outwards from the bifurcation of the aorta on the left side of the body of the fourth lumbar vertebra, to opposite the sacro-ilac symphysis, and at this spot they divide into the internal and external iliac vessels. The right is longer than the left, from the position of the aorta on the spine; each lies on the body of the last lumbar vertebra, is covered by peritonæum, and near its termination is

crossed by the ureter: along the outer side is the psoas muscle. The left is crossed in front by the branches of the inferior mesenteric artery, which descend into the pelvis; and its vein is below it. The right common iliac vein is above and behind the corresponding artery, and that of the left side passes also beneath the right common iliac artery.

The *external iliac artery*, one of the branches of division of the common iliac, extends from the sacro-iliac symphysis to the lower border of Poupart's ligament; it then leaves the pelvis, and takes the name of femoral. A line from the umbilicus to half an inch internal to the centre of Poupart's ligament, will be over its direction in an unopened abdomen. It lies along the inner border of the psoas muscle to near Poupart's ligament, but it then passes in front of the psoas; it is covered by the peritonæum, and by the subserous cellular layer beneath it, which is seen in dissecting femoral hernia, and also by Poupart's ligament; it is crossed oftentimes at its commencement by the ureter: the genito-crural nerve descends on it, and near Poupart's ligament it is also crossed by the spermatic vessels, by the circumflex ilii vein, and by the vas deferens, which, in turning down into the pelvis, touches its inner side; some inguinal glands are found on the inner side. The right is crossed by the ilium, which terminates in the cœcum, and its vein passes behind it to the iliac side, though on the pubes it is internal or to the pubic side of the artery, and on the same level; the left has in front of it the sigmoid flexure of the colon, or commencement of the rectum, and its corresponding vein is internal to it and below it. Some small unnamed branches are given off to the inguinal glands, but near Poupart's ligament, the epigastric and circumflex ilii arteries, already seen in the abdominal wall, arise from it: each of these branches is accompanied by one or two veins.

External Iliac Artery.

Branches.

The *external iliac vein*, the continuation of the femoral, receives the circumflex ilii and epigastric veins, and reaches to the sacro-iliac symphysis to join with the internal, in the common iliac vein. Beneath Poupart's ligament it is placed internal to the artery, and on the pubes between the pectineus and psoas muscles; and the left maintains this position internal to the artery but below it, whilst that of the right side soon passes beneath the external iliac artery to reach its outer side.

Veins.

External Iliac.

The *common iliac veins* extend from the sacro-iliac symphysis to the right side of the body of the fourth lumbar vertebra, to unite in the cava. The right is external to the common iliac artery, and above it; but the left, the longest, lies below the artery of the same name, and moreover, crosses beneath that of the right side to join with the right vein. The relation of the veins is much the same as that of the arteries; each receives the ilio-lumbar and lateral sacral, and the left, the middle sacral vein.

Common Iliac.

Instead of the veins uniting in the cava opposite the bifurcation of the aorta, they may extend upwards on each side of this vessel, as high as the kidney, before the left crosses over it to join the right. There may be also a transposition of these vessels, the cava being on the left, and the aorta on the right of the spine, but this is more rare than the preceding variety.

The Kidney. The *kidney*, a glandular organ for the secretion of the urine, is situated in the lumbar region, and there is usually one on each side of the spine, but it is not very uncommon to find the right and left united into one by a transverse portion across the aorta. The relation of these organs to the surrounding parts was studied before

Form. the removal of the viscera. Each kidney is closely surrounded by a bed of cellular membrane, and when this is taken away, it approaches in shape the form of a French bean; its direction is oblique from within outwards, the upper end being nearer the

Extremities. spine than the lower. The upper extremity, generally the largest, is surmounted by the supra-renal capsule; the lower is

Borders. more pointed. The outer border is convex; and the inner presents a fissure or *hilus* into which the vessels enter, and by

Surfaces. which the excretory duct leaves the organ. The anterior surface is convex; and the posterior, flatter, rests on the diaphragm, psoas, and quadratus lumborum, from which it is separated by the fasciæ that cover them. The kidney of one side is to be distinguished from that of the other, by the greater size of the upper end, and by the greater convexity of the anterior surface.

Vessels in the Fissure. Of the vessels that enter the fissure of the kidney, the divisions of the vein are most anterior, those of the artery in the middle, and the excretory duct or ureter is most posterior; the position of the ureter, which is directed down along the lower part of the kidney, points out with greater precision than the size of the extremities, to which side of the body a kidney may belong. The anatomy of the vessels external to the organ has

Ureter. been seen, with the exception of the duct. The *ureter*, or excretory tube of the kidney, to convey the urine secreted in this organ to the bladder, is about eighteen inches long, dilated at its commencement in the pelvis of the kidney, and narrowed in its middle to about the size of a goose-quill; it enlarges again near its termination in the bladder. Its direction is oblique downwards and inwards to the pelvis and side of the sacrum, and having entered this cavity it again changes its course, and runs almost horizontally forwards between the layers of the peritonæum in the posterior ligament of the bladder, to perforate the lower and posterior part of the organ. In this extent it is placed beneath the peritonæum, passes over the quadratus lumborum and psoas muscles, and a little below the middle of the last it is crossed by the spermatic vessels; it then enters the pelvis by passing in front of the common iliac or external iliac vessels, beneath the sigmoid flexure on the left side, and the

end of the ilium on the right; and placed on the inner side of the vessels, it extends forwards to the bladder, forming an arch below the obliterated hypogastric artery, and when near the bladder, the vas deferens lies between it and this viscus. In the female it is situated along the side of the neck of the uterus, and upper part of the vagina. These relations in the pelvis will be seen more clearly with the dissection of that part. This tube is sometimes double.

Dissection.

Cut across the vessels that go to the kidney, and remove it to examine its structure; for this purpose the kidney may be divided by a vertical incision from the outer to the inner border, or the portion of the organ above the entrance of the vessels may be gradually removed, following in, at the same time, the artery, vein, and duct, that enter at the hilus.

Structure.

Fibrous Coat.

Besides a partial peritonæal and cellular investment, a *fibrous* covering surrounds the kidney, and sends numerous small processes into the interior of the organ, and at the hilus, one around the vessels that enter at this part, like the envelope of the liver. The colour is of a brownish red, and the tissue is firmer, and less brittle than that of the spleen or the liver: two distinct structures are also seen to enter into the texture of the kidney; an external granular investing portion,—the cortical or glandular; and an internal, of a darker colour,—the medullary or tubular. The *medullary* or *tubular portions* of the kidney are pyramidal in shape, and situated in the centre of the organ; they are from ten to twenty in number, the base of each being directed towards the circumference or cortical part, and the apex inwards to the fissure; and each ends below in a rounded projecting part — the mamilla — which is perforated by numerous apertures from which urine may be pressed, and it is surrounded by a division of the excretory tube or a calyx, into which the urine is received from the orifices in the extremity. Each pyramidal portion is surrounded by the cortical, except at the apex where it joins the excretory duct; and in the fœtus the kidney consisted of as many separate portions or renculi as there are pyramidal processes, each of them being enveloped by a layer of the cortical substance, and supplied by distinct branches of the vessels and duct, by which they were connected together near the fissure or hilus; but these subsequently unite together, though the cortical envelope still projects between them, separating one from the other. When these portions are examined with a lens, or injected by exposing the surface of the organ to the vacuum of an air pump, they are found to consist of tubes,—the *tubuli uriniferi*, or tubes of Bellini,—placed side by side, which open below by the apertures in the pointed extremity; but above, they project into the cortical substance, of which they form the greater part; and, instead of being straight, they separate from each other, and become convo-

Tubular Substance.

Tubuli urinigeri.

luted, some anastomosing together, and some ending in cœcal extremities; and on them the minute vessels ramify to secrete the urine. The *cortical substance* surrounds all the tubular portions, giving a general covering to them of about two lines in depth, and sending prolongations inwards between them; it is softer than the tubular substance, and of a browner colour. The microscope and injection of the vessels show that it is one mass of convoluted uriniferous tubes, with the capillary network of the vessels of the kidney. Between the ramifications of the tubuli uriniferi are seen, in an injected kidney, the *corpora Malpighiana*, or glomeruli, which are small vascular bodies connected with the arteries; and into each a small artery enters, is convoluted in its interior, and then passes from it. The *ureter*, in entering the fissure of the kidney, is dilated into a pouch, — the pelvis, which is situated behind the vessels, divides generally into three large tubes, and these again into nearly as many calyces or infundibula as there are pyramidal processes, since each of the calyces surrounds the free extremity or mamilla of the pyramidal portion, though sometimes more than one mamilla opens into a calyx. The calyces receive the secretion from the apertures in the mamilla. Instead of the ureter being described as dividing into calyces, it may be said to commence in the calyces, which join in the pelvis, and this ends in the ureter. This duct consists of two coats; an external fibrous, and an internal mucous, which is prolonged into the tubuli uriniferi through the apertures in the mamilla. The *renal artery*, when entering the fissure of the kidney, divides into numerous branches, which extend to the cortical or vascular portion of the kidney by passing between the pyramidal processes; and in it they terminate in many ramifications which unite together to form a capillary network, occupying the intervals between the tubes, on whose walls these minute vessels ramify to secrete the urine; some of the small arteries run to the corpora Malpighiana, and others are distributed on the straight portions of the tubuli uriniferi, running towards the mamilla, on which they form an anastomosis, but their size is diminutive. The communication between the renal artery and vein is very free; and the branches of the artery are distributed to separate parts of the kidney, as in the fœtus. The *renal vein* commences by radicles in the cortical and tubular substance; these unite into branches, which run with the arteries between the pyramidal processes and divisions of the ureter, and leave the fissure of the kidney to unite in the renal vein. The *nerves* and lymphatics accompany the vessels into the interior of the organ, but their distribution has not been followed. The urine is secreted in the ramified tubuli uriniferi in the cortical substance, passes along the straight part of the tubuli, and through their lower apertures in the mamilla into the calyces, by which

Cortical Substance.

Corpora Malpighiana.

Ureter.

Renal Artery.

Vein.

Nerves.

it reaches the ureter, and is conveyed to the bladder or its receptacle.

The *supra-renal capsule*, whose use is unknown, is a flattened body, situated like a cap on the upper extremity of the kidney. On the right side it is in contact, above, with the liver, and on the left with the spleen; it lies on the pillars of the diaphragm, and its base which rests on the kidney is slightly hollowed; it is invested by a cellular layer, and by a fibrous, which sends processes into it. When it is cut across a cavity is exposed, in which is some dirty brown coloured fluid. The external or cortical part of the capsule is firm and yellowish, and the internal, soft and pulpy, is of a dark brown colour. The vessels of this body have been seen; the nerves that supply it are very numerous, and come from the semilunar ganglion and solar plexus. To the third month of uterine fœtation these bodies are larger than the kidneys, but from this period they lose this relative proportion, and finally are smaller than these organs. No duct has been discovered in connection with them. Supra-renal Capsule.

Remove the fascia and cellular membrane from the spot occupied by the kidney, and the diaphragm, which is dissected, may be next examined. If the margin of the thorax has fallen down, it must be raised and supported, but the natural shape can be seen only when the cavity of the thorax has not been opened, and the muscle is therefore kept in a state of convexity by the attachment of the pericardium and pleuræ to it. Dissection.

The *diaphragm*, partly a voluntary, and partly an involuntary muscle, is placed transversely across the interior of the trunk, and, as the name expresses, serves to divide the space into two chambers, the upper one being the cavity of the thorax, and the lower that of the abdomen, towards which it is vaulted or concave. Next the abdominal cavity it presents a tendinous centre, surrounded by fleshy fibres which are attached to the ribs on the sides and in front, and to the vertebral column behind, the latter being much the strongest; and from the shape of the thorax its greatest measurement is in the transverse direction; its sides are not altogether symmetrical. The muscle *arises*, in front and on the sides, by fleshy digitations from the under surface of the xiphoid cartilage near its apex, from the cartilage of the seventh rib external to the attachment of the transversalis muscle, and between the two from a tendinous arch over the digitation of the transversalis, a slight cellular interval is seen between these portions; it is attached, likewise, by fleshy processes to the inner surface of the cartilages of the ribs, below the seventh, as well as to the osseous part of the two or three last ribs, and all these indigitate with portions of the transversalis: between the last rib and the transverse process of the first lumbar vertebra, the fibres, which are thin and scattered, arise from a band of fascia stretched between these The Diaphragm. Origin.

points, and continuous with the layer of the fascia lumborum which passes in front of the quadratus lumborum muscle; this is sometimes called the *ligamentum arcuatum externum*, because of its position: in the middle line behind, it presents two tendinous processes, the crura or pillars, which soon give rise to fleshy fibres; in the interval between these it arises from a tendinous band over the aorta, and external to them from another arch, *arcus interior*, or *ligamentum arcuatum internum*, which is continued outwards from the tendon of the crus, over the upper part of the psoas muscle and sympathetic nerve, to the transverse process of the first lumbar vertebra, into which the other arch was inserted. From these different origins at the circumference, the fibres pass inwards to the central tendon with different degrees of obliquity as well as of strength;—those from the xiphoid cartilage directly backwards, those from the seventh and eighth ribs run obliquely inwards and backwards, and are longer and stronger than the posterior, which are directed forwards to it: a cellular interval is often found between the digitation to the last rib, and the origin from the ligamentum arcuatum externum. From the ligamenta arcuata the fibres pass upwards and forwards to the tendon; but those connected with the crura, thicker than the rest, diverge from each other, the external and middle being directed forwards and outwards to it, whilst the internal ascend by the side of the aorta, bounding on each side its aperture; and in front of it each crus sends inwards a process which decussates with the opposite,—the one from the right being the larger and in front of that from the left,—so as to separate the opening of the œsophagus, which is in front of them, from the aorta behind; and they further form the sides of the œsophagean orifice by turning upwards to join the central tendon: the fibres of each crus are separated by the passage of the splanchnic nerves between them. The *central tendon* (cordiform tendon, phrenic centre) or aponeurosis of the diaphragm, surrounded on all sides by fleshy fibres, is of a pearly white colour, and the aponeurotic fibres that enter into it cross each other in different planes and in different directions, the greater number passing from the centre to the circumference. It resembles a trefoil leaf, notched behind towards the spine; the anterior division or leaflet is the largest, and the left the smallest, and between the right and anterior divisions is an aperture, bounded by bundles of fibres, which gives passage to the inferior vena cava. Of the *crura*, the right is the larger, is placed in front of the spine, and is fixed by tendinous processes, which join the anterior common ligament, to the three upper vertebræ, and to the intervertebral substance between the third and the fourth; but the left, situated more on the side of the vertebræ and covered by the aorta, is inserted into the bodies of the three upper vertebræ; between the crura is placed the aorta,

Ligamentum arcuatum externum.

Internum.

Insertion.

Tendon.

Crura.

and a tendinous arch is continued over it from them. The abdominal surface of the muscle is concave, and the arch of it projects higher on the right than on the left side. It is covered by peritonæum, except in the space included between the laminæ of the coronary ligament, and where the cava and œsophagus pass through it; and in contact with it, on the right side, is the liver and kidney, and on the left, the stomach, spleen, and left kidney. In front of the crura are the duodenum, pancreas, and solar plexus; on the right crus, the right semilunar ganglion, supra-renal capsule, and vena cava; on the left, the splenic vessels, left semilunar ganglion, and supra-renal capsule; and through each pass the splanchnic nerves. This surface has three apertures; one in front of the spine, between the pillars of the muscle, for the aorta, thoracic duct, and vena azygos; one above and to the left of the aortic, for the œsophagus and pneumo-gastric nerves, is opposite to the body of the ninth or tenth dorsal vertebra; and its sides, which are fleshy, are formed by the fibres of the pillars, which decussate behind it, separating it from the aortic, and then continue around it to the posterior part of the central tendon; and the last aperture, for the vena cava, is through the right portion of the tendon, or at the point of junction of the right and left, but near the posterior part, and to the right side of the tenth dorsal vertebra; tendinous fibres surround it, and attach the vein to its margins. The diaphragmatic arteries and nerves, with the phrenic nerve, ramify on this surface. The circumference of the muscle is in relation, in front, with the xiphoid cartilage, and seventh and eighth ribs, an interval existing between the digitation to the cartilage and that to the seventh rib, through which the cellular membrane of the abdomen is continuous with that of the thorax; on the sides it corresponds to the ribs and origin of the transversalis muscle, and the intercostal nerves and arteries perforate between its digitations; behind, the crura lie on the lumbar vertebræ; the internal arched tendinous process is over the psoas muscle and sympathetic nerve, and the external over the quadratus lumborum muscle and last dorsal nerve and accompanying artery. The relations of the upper surface are seen with the dissection of the chest. From the moveable nature of this partition between the thorax and the abdomen, the size of both of these cavities is altered by its action; for in inspiration, when it descends, the cavity of the thorax is enlarged, but that of the abdomen is diminished, and the viscera forced downwards; but during expiration, the capacity of the two is reversed, and the viscera are again replaced in their natural position by the abdominal muscles.

Relations.

To follow the sympathetic nerve from the thorax, as well as the splanchnic through the fibres of the crus to the semilunar ganglion, and to see the relations of the aorta, and commencement

Dissection.

of the vena azygos and thoracic duct, cut through, on the right side, the few ribs that support the diaphragm, except the last, and all the right portion of the diaphragm, except the crus; seek the vein, nerves, and duct in the thorax, where they have been dissected, and trace them to the abdomen: cut across also the tendinous arch over the aorta.

The Aorta between the Crura of the Diaphragm.

The aorta, in passing from the cavity of the thorax to that of the abdomen, lies in a canal about an inch in length, formed behind by the body of the last dorsal vertebra, laterally by the crura of the diaphragm, and in front by the tendinous arch continued over it from one crus to the other. The thoracic duct and vena azygos pass through the same aperture, lying between the aorta and the right crus: the cellular membrane of the abdomen is continued into the cavity of the thorax through it. The diaphragmatic arteries arise from this portion of the aorta.

Receptaculum Chyli.

The commencement of the thoracic duct will be seen by cutting through this part of the aorta, and by removing a part of it. The duct begins opposite the first or second lumbar vertebra in a dilated portion, the *receptaculum chyli*, to which three or four large lymphatic tubes which receive the lymph from the lumbar ganglia, and the chyle from the mesentery, are connected. It is usually rather behind, and to the right side of the aorta, but its position as well as the branches joining it may vary; it then ascends through the opening of the diaphragm to enter the thorax.

Origin of the Vena azygos.

The *vena azygos* begins on the body of the first or second lumbar vertebra by a small branch which is continuous with the lumbar veins, or it may be connected to the renal, or vena cava; however formed at first, it enters the thorax with the thoracic duct, to the right of which it is placed, and passes through the aortic opening of the diaphragm.

Splanchnic Nerve through the Crus.

The sympathetic nerve enters the abdomen by passing beneath the ligamentum arcuatum internum, and it lies on the psoas muscle. The great and small splanchnic nerves appear in it by perforating between the fibres of the crus in front of the trunk of the nerve, and they are usually transmitted through the same aperture. The small nerve frequently joins the large, and their distribution to the semilunar ganglion and renal plexus has been dissected.

Fascia of the Quadratus.

The *fascia* of the *quadratus lumborum* is a thin membrane which covers the muscle, and it is the layer of the tendon of the transversalis abdominis, or of the fascia lumborum, which is continued in front of the quadratus to the roots of the transverse processes; it is fixed, below, to the crest of the ilium, above, to the under surface of the last rib, and forms the band which has been called the ligamentum arcuatum externum, to which the fibres of the diaphragm are attached. The fascia

is perforated by the last dorsal nerve, and by the ilio-inguinal and musculo-cutaneous of the lumbar plexus.

The *fascia of the iliacus* and psoas muscles forms a partial sheath for these muscles which it covers, is much thicker below than above, and is formed by transverse fibres; where it covers the iliacus, it is attached externally to the margin of the ilium, and is connected to the fascia transversalis; internally, it is united to the margin of the pelvis, and is continued into this cavity to join the pelvic fascia: the tendon of the psoas parvus, when present, sends to it a strong tendinous process at its insertion into the ilio-pectineal line or brim of the pelvis; inferiorly, it passes beneath Poupart's ligament, closely investing the two muscles as far as their insertion into the femur, and is joined laterally by the fascia lata; it is closely united to the outer part of the ligament and the fascia transversalis, external to the femoral vessels, but beneath these it gives off a prolongation which takes a part in the production of the tubular femoral sheath, which surrounds them. When the fascia is followed upwards on the psoas, it becomes thinner as it ascends, and it is connected above to the ligamentum arcuatum over the upper part of the muscle, externally it joins the fascia on the quadratus, and internally it is connected to the borders of the lumbar vertebræ, and to the intervertebral substance, the vessels and nerves preventing the attachment to their centre; and by this means an arched appearance results, the lowest of the arches, and the strongest, being one from the last lumbar vertebra to the brim of the pelvis, and beneath it pass the obturator and lumbo-sacral nerves. This fascia is covered by the thin subserous cellular membrane; the branches of the lumbar plexus are at first beneath it, and the anterior crural does not perforate it till below Poupart's ligament. Take away now the fascia from these muscles, raise the iliac fascia towards the brim of the pelvis, and leave a portion of it, that it may be followed afterwards into this cavity.

Iliac Fascia.

The *psoas magnus muscle*, situate in part in the abdomen, and in part in the thigh, differs in its relations according as one or the other portion is dissected: large above, but small and pointed below Poupart's ligament, it *arises* from the side of the last dorsal, and the five lumbar vertebræ, by digitations attached to the upper and lower borders, and to the intervening fibro-cartilages; but opposite the grooved part of the body, in which lie the lumbar arteries and connecting branches of the sympathetic nerve, from a tendinous arch which is stretched over them, and connects together the digitations; it is also attached to the roots of the transverse processes of the same vertebræ. The fibres run downwards and outwards to form a roundish muscle, which enlarges in the centre, but gradually diminishes towards Poupart's ligament, and ends in a tendon on the outer

Psoas Muscle

Origin.

and anterior part, to which are united the fibres of the iliacus; the two muscles then pass beneath Poupart's ligament, in the groove between the pectineal eminence and the crest of the ilium, and are *inserted* by one attachment into the small trochanter and contiguous surface of the femur: the relations and insertion of the femoral portion are seen in the dissection of the thigh. In the abdomen the psoas is covered by the iliac fascia prolonged on it, by the small psoas when it is present, by the diaphragm and ligamentum arcuatum, also by the kidney and ascending colon on the right side, and by the descending colon on the left; and beneath these the ureter and spermatic vessels cross the muscle; the genito-crural nerve also descends on its front. The inner border is attached by its upper part to the lumbar vertebræ, and corresponds to the sympathetic nerve and chain of lumbar glands; on the right side to the cava, and on the left to the aorta; but below the vertebræ it is free along the margin of the pelvis, the external iliac artery and vein being parallel and close to it, but near Poupart's ligament, the artery is placed on it, and the obturator artery and nerve lie below it: the outer border is in contact with the quadratus lumborum as low as the crest of the ilium, but below that with the iliacus, the anterior crural nerve lying between the two muscles; coming from beneath it, at the upper part, are the ilio-inguinal and musculo-cutaneous nerves, at the middle, the external cutaneous, and at the lower part, the anterior crural nerve. The muscle is situated on the transverse processes, the quadratus lumborum, and os innominatum, and contains in its interior the lumbar plexus. Beneath Poupart's ligament it fills the space external to the ilio-pectineal eminence, and prevents a protrusion of intestine at this spot.

Insertion. Relations.

Iliacus Muscle. Origin.

The *iliacus muscle*, which appears to be a portion of the psoas, is situated in the iliac fossa, and is thicker below, where it joins the tendon, than at its upper part. The fibres *arise* from all the iliac fossa, and from the base of the sacrum, from the crest of the ilium and the ilio-lumbar ligament, and in front, from the anterior spinous processes of this bone, as well as from the inner margin of the notch between them. The fibres pass downwards and inwards, converging, to the tendon of the psoas, which they join on the outer part, and passing also beneath Poupart's ligament, continue to unite with it, even to the insertion into the femur. The portion of the muscle above Poupart's ligament is covered by the fascia iliaca, on the right side the cœcum is in front of it, and on the left the sigmoid flexure, and it is crossed by the external cutaneous nerve from the lumbar plexus; it rests on the concave surface of the ilium, and capsule of the hip-joint. The lower, or outer border is in contact with the sartorius, and the head of the rectus which is fixed to the anterior inferior spinous process of the

Insertion. Relations.

ilium: it unites with the psoas below Poupart's ligament, and its relations are seen in the dissection of the thigh.

Psoas parvus Muscle. Origin.

The *psoas parvus muscle*, situate in front of the psoas magnus, and rather to its inner side, is very commonly absent: it is a thin muscle with a large flat tendon; it *arises* from the lower border of the last dorsal vertebra, and upper margin of the first lumbar, as well as from the intervening fibro-cartilage, it may also arise from the second lumbar vertebra and fibro-cartilage: the fibres descend, and end in a tendon which occupies two thirds of the extent of the muscle, becomes broader as it approaches the ilium, passes to the inner side of the psoas magnus to be *inserted* into the ilio-pectineal eminence and brim of the pelvis, and a strong fascia is given off from its lower part to join the iliac fascia. The upper part is covered by the diaphragm and renal vessels, and the lower by the external iliac artery; and the muscle is in relation with the psoas magnus in its whole course.

Insertion. Relations.

Quadratus Lumborum Muscle. Origin.

The *quadratus lumborum* is a thick short muscle, larger below than above, and is situated in the lumbar region, between the crest of the ilium and the last rib, so as to bound, behind, the cavity of the abdomen. It *arises* by aponeurotic fibres from the ilio-lumbar ligament, and from the crest of the ilium in front of it for about two inches; the fibres pass upwards and inwards to be *inserted* into the inferior edge of the last rib for nearly its whole length, and also by four tendinous processes into the apices of the transverse processes of the four first lumbar vertebræ: there is frequently found a muscular portion in front of this, attached by one extremity to the transverse processes of the two or three upper lumbar vertebræ, and by the other to the last rib. The muscle is incased in the sheath of fascia derived from the tendon of the transversalis abdominis muscle, and in front of it on the right side is the ascending colon, and on the left the descending portion of the same intestine. The kidney and psoas muscle also project to its front, and the diaphragm slightly covers the attachment to the rib; crossing the surface is the last dorsal nerve and its artery, with the musculo-cutaneous nerves of the lumbar plexus. Behind the muscle is the mass of the erector spinæ, which it projects beyond near the crest of the ilium.

Insertion. Relations.

Dissection.

To expose the lumbar nerves and the lumbar plexus in the psoas muscle, scrape away the substance of the muscle as low as the position of the nerves which escape from the canal; but on the one side it may be left untouched, to see the relative anatomy of the branches. It will be necessary to remove it freely, but carefully, near Poupart's ligament, to follow a small branch from the obturator nerve, which lies along the pelvic portion of the inner border, and then turns beneath it to supply the femoral articulation and join the obturator in the thigh. Dissect

now the sympathetic along the vertebral portion of the inner border, by turning up the cava on the right side, and by removing the cellular membrane from it, and from the lumbar lymphatic glands; follow downwards beneath the arches between the attachments of the digitations of the muscle, the branches that the ganglia send along the arteries to join the spinal nerves as they escape from the canal. Seek also a small branch that the last dorsal nerve gives off to join, in the quadratus, with a branch from the first lumbar nerve: this is sometimes named the dorsi-lumbar branch, and connects the last dorsal with the lumbar plexus.

Lumbar Nerves. The *spinal lumbar nerves*, five in number, leave the spinal canal by passing through the inter-vertebral foramina, the first through that between the first and second vertebræ, and the fifth between the last vertebra and the sacrum. Each nerve divides, external to the intervertebral foramen, into an anterior and posterior branch; the *posterior* passes backwards between the transverse processes, internal to the fascia that fills the interval, appears in the back between the longissimus dorsi and multifidus spinæ, and is dissected with that region: these nerves diminish in size from the first to the last. The *anterior* branches of the lumbar nerves, as they escape from the foramina, are joined by filaments sent backwards to them from the lumbar ganglia of the sympathetic nerve, and then unite together in the lumbar plexus, which supplies nerves to the lower extremity and wall of the abdomen. The first nerve is the smallest, and they increase in size to the fifth, which is the largest, and joins altogether the sacral plexus. Each of the anterior branches, except the fifth, gives off nerves; or a branch to a nerve, and a branch to form the plexus by uniting with the others.

Posterior division.

Anterior division.

Lumbar Plexus. The *lumbar plexus*, formed by the union of the anterior branches of the four first lumbar nerves, is situated along the side of the bodies of the lumbar vertebræ, in the substance of the psoas muscle, near its posterior surface, and in front of the transverse processes: it is small and pointed above, but wide and large below. The plexus communicates with the sympathetic through the medium of filaments from the lumbar nerves; it joins above with the last dorsal by means of the *dorsi-lumbar* branch, which unites in the quadratus with a nerve from the first lumbar, and it is connected to the sacral plexus below, by the whole of the anterior branch of the fifth nerve, which receives a communicating portion from the fourth, and forms the *lumbo-sacral* nerve, which descends into the pelvis in front of the lateral part of the base of the sacrum. It is not difficult to trace the branching of the nerves in the plexus, and the following is their disposition: — the anterior branch of the first nerve gives off the two musculo-cutaneous nerves, and a

descending or communicating to the second; that of the second supplies the genito-crural nerve, — though this oftentimes comes from the connecting branch between the first and second, — the external cutaneous nerve, and a descending branch which throws itself into the large anterior crural; that of the third nerve is distributed by a large external branch to the anterior crural, and a descending one to the fourth, from which an offset goes to the obturator nerve; the branch of the fourth sends outwards a large division to the anterior crural, a second branch to the obturator, and a descending one to the fifth, to give rise to the lumbo-sacral to the sacral plexus.

Branches.

The *musculo-cutaneous* branches, two in number, come from the first lumbar nerve; the upper one is largest, and is called ilio-inguinal, and the lower one, the small musculo-cutaneous nerve. Sometimes there is but the large nerve. The large branch or *ilio-inguinal nerve* (ilio-hypogastric Schmidt) appears at the upper part of the outer border of the psoas muscle, and perforates the fascia covering the quadratus; it now runs downwards and outwards to the crest of the ilium across the centre of the quadratus, and surrounded by much fat; it then perforates the transversalis muscle about the middle of the crest of the ilium, and between it and the internal oblique gives its cutaneous branch to the dorsum of the ilium, which perforates both the internal and the external oblique: the trunk of the nerve continues forwards along the crest, between the two muscles, and divides into an abdominal and inguinal branch. The *abdominal branch* has been seen to be distributed between the internal oblique and transversalis, as the other abdominal nerves, and to terminate by becoming cutaneous in the lower part of the abdomen, after perforating both the external and internal oblique; the *inguinal branch*, still directed forwards between the oblique and transversalis, is connected to the small musculo-cutaneous, near the front of the crest, runs parallel to Poupart's ligament, perforates the internal oblique, leaves the abdominal wall by the external ring with the cord, and is distributed to the integuments of the groin and scrotum. The *small musculo-cutaneous* nerve crosses the quadratus lower than the large one, runs over the iliacus below the crest of the ilium, and near the anterior spine of this bone perforates the transversalis muscle, and either ends by joining the inguinal branch of the ilio-inguinal at this spot, or it sends only a small communicating filament to it, then runs forwards parallel to the other but below it, perforates the internal oblique nearer the pubes and below the other, comes into relation with the cord, and passes with it to be distributed to the integuments covering it. This nerve gives filaments to the lower part of the internal oblique and transversalis muscles.

Musculo-cutaneous.

Ilio-inguinal Nerve.

Small Musculo-cutaneous.

The *genito-crural*, or external spermatic, from the communicating branch between the first and second, or from the

Genito-crural Nerve.

second nerve, perforates, at a variable height, the front of the psoas and the fascia covering it, descends on it to its inner border, comes into contact with the external iliac artery, on which it lies near Poupart's ligament, and divides into a genital and a crural branch. Sometimes the nerve is divided beneath the muscle into these two branches which separately pierce the fibres, and run to their destination.*

Genital branch.

The *genital* or spermatic branch crosses the iliac artery, and coming forwards, leaves the abdomen with the cord, is distributed to its cremasteric investment and the integuments, and joins with the inferior pudendal nerve: it gives some filaments to the internal oblique and transversalis, and others to the external iliac, which twine round the artery.

Crural.

The *crural*, or femoral branch, more variable in size, runs downwards beneath Poupart's ligament, and lies to the outer side of the iliac artery in the sheath of fascia sent around it; it crosses the circumflex ilii artery, perforates the sheath of the femoral vessels below Poupart's ligament, and after passing through the fascia lata, near the ligament, is distributed to the integuments of the inguinal region or upper third of the front of the thigh. This division of the nerve is frequently very small, and its place supplied by a large branch of the next nerve or external cutaneous, which then has an extensive distribution on the front and outer part of the thigh, and joins the anterior crural.

External Cutaneous Nerve.

The *external cutaneous*, a branch of the second lumbar nerve, perforates the outer border of the psoas about its middle, crosses the iliacus muscle, superficial to the fascia that covers it, and enveloped in fat, to reach the interval between the anterior superior and inferior spinous processes, by which it passes from the pelvis beneath Poupart's ligament; it is distributed to the anterior and outer part of the thigh, of which it is the anterior and external cutaneous branch. This nerve may come from the outer part of the anterior crural, instead of from the second lumbar nerve; and it sends also, sometimes, a branch to join the femoral division of the genito-crural.

Anterior Crural Nerve.

The *anterior crural nerve*, the largest of those from the lumbar plexus, and formed by branches from the second, third, and fourth nerves, descends in the interval between the psoas and iliacus muscles, and beneath the fascia iliaca, to Poupart's ligament, beneath which it passes, and divides in the thigh into many muscular and cutaneous nerves which are followed in the dissection of this part; as also are the terminal branches of the genito-crural and external cutaneous. In the pelvis it gives from its inner side a branch to the psoas, which turns back-

* In the very elaborate treatise of Schmidt (*Commentarius de Nervis Lumbalibus eorumque Plexu Anatomico-pathologicus.* 1794.) on the anatomy and branches of the lumbar plexus, these divisions are described as separate nerves, the genital branch being named external spermatic, and the crural, the lumbo-inguinal nerve. See pp. 40—43.

wards and upwards before entering the muscle, and from its outer, some small nerves to the iliacus muscle.

The *obturator nerve*, arising from the third and fourth nerves, descends at first beneath the psoas or in its substance, escapes from beneath it at the margin of the pelvis, and passes between the external and internal iliac vessels; it now crosses the pelvis near its side, below the level of the psoas and the external iliac vessels, but above the artery of the same name, leaves the cavity by the aperture in the upper part of the obturator or thyroid foramen, and divides in the thigh into its terminal branches. Soon after its origin, and whilst covered by the psoas, the nerve gives off a small branch, the *accessory of the obturator* *, which continues forwards along the brim of the pelvis, close to the psoas muscle and beneath the iliac fascia, in the same direction as the trunk, but above it, as far as to the upper surface of the pubes, and between the psoas and pectineus muscles divides it into branches; the chief of these are followed over the pubes, and beneath the pectineus, to supply this muscle and join the trunk of the obturator, and one or two filaments enter the ilio-femoral articulation. Occasionally, this branch comes from the plexus, instead of from the obturator. Thomson † has described some small branches from it to the levator ani: these descend into the pelvis to the muscle. Obturator Nerve. Accessory.

The *lumbo-sacral*, or communicating nerve from the lumbar to the sacral plexus, consists of the large fifth lumbar nerve, and the branch sent down to it from the fourth; it descends into the pelvis in front of the lateral part of the sacrum and the sacro-iliac symphysis, beneath the internal iliac artery, vein, and ilio-lumbar artery, and joins in front of the pyramidalis muscle with the first sacral nerve. Before entering the sacral plexus, and when opposite the sciatic notch, it gives from its posterior part the small *superior gluteal nerve*, which leaves the pelvis by this aperture, and appears beneath the gluteus medius muscle. Besides these named branches the plexus supplies many small nerves to the psoas muscle in which it lies. Lumbo-sacral Nerve. Superior Gluteal Nerve.

The *twelfth dorsal nerve* leaves the spinal canal through the intervertebral foramen between the last dorsal and the first lumbar vertebra, and appears below the last rib, parallel to which it is placed; it crosses the upper part of the quadratus lumborum, beneath the fascia that covers it, and at the outer border of the muscle comes into contact with the aponeurosis of the transversalis abdominis, or the fascia lumborum, which it perforates to enter the wall of the abdomen between the transversalis and the internal oblique muscle, where it has been seen dividing into an abdominal and a cutaneous branch: the former Twelfth Dorsal Nerve.

* This nerve was first described by Schmidt, as "Nervus ad obturatorem accessorius inconstans." Op. cit. p. 52.

† See Nos. 94. and 95. of the London Medical and Surgical Journal.

is distributed in the wall as an intercostal nerve; and the cutaneous perforates the internal and external oblique, and is distributed over the gluteal muscles. The artery that accompanies this nerve is the anterior branch of the first lumbar, which is supplied to the wall of the abdomen between the internal oblique and transversalis.

Sympathetic Nerve. The *sympathetic nerve* in the abdomen consists, as before seen, of a gangliated portion situated by the side of the vertebral column, and of prevertebral plexuses. The cord-like part resembles that in the thorax, one knotted nerve being on each side of the spine, both in the lumbar and sacral regions; but in the pelvis, the nerve of one side joins with that of the other on the coccyx: the sacral portion contained in the pelvis is not now visible. The *lumbar division* of the cord, continuous above with the thoracic, by means of a connecting filament beneath the ligamentum arcuatum of the diaphragm, and below with the sacral, by a similar filament to the first sacral ganglion, presents usually four or five ganglia placed opposite the bodies of the vertebræ. It is situated close to the inner border of the psoas muscle, and nearer to the front of the vertebræ than in the thorax; a chain of lumbar glands lies by the side of it. On the right side the vena cava partly conceals the cord. Each ganglion is connected to the one above and below by the trunk of the nerve, and it supplies moreover external and internal branches; the external are two or more filaments to unite with the anterior branch of each spinal lumbar nerve as it emerges from the canal, and before it joins with the collateral ones to form the lumbar plexus: these connecting filaments pass backwards along the centre of the bodies of the vertebræ, with the lumbar arteries, and beneath the arches between the digitated origins of the psoas magnus. The internal branches from the ganglia pass inwards on the aorta and vena cava to enter the lumbo-aortic plexus, and others descend into the pelvis to unite with the hypogastric plexus.

Lymphatics. A chain of lymphatic glands is placed on each side of the spine and continued downwards along the external iliac artery; these receive the lymphatics from the lower extremities and lower half of the body, and open by their lymphatic vessels into the thoracic duct.

Lumbar Arteries. The *lumbar arteries*, four or five in number on each side, arise from the posterior part of the aorta, opposite the centre of the lumbar vertebræ, and sometimes the branches of opposite sides arise by a common trunk; these resemble the aortic intercostal in the thorax in their course and distribution. Each runs backwards along the centre of the body of the vertebra, beneath the sympathetic nerve and psoas muscle, the upper ones also lying beneath the crus of the diaphragm, as far as to the interval between the transverse processes, where it divides into an an-

terior and a posterior branch; the *posterior*, the continuation of the artery in direction, turns backwards with the nerve, between the body of the vertebra and the membrane which fills up the interval between the transverse processes, and is distributed to the deep muscles of the back; it gives an artery to the spinal canal, which divides into branches that perforate the posterior part of the body of the vertebræ, and into others to supply the medulla and its membranes. The *anterior branch* of the lumbar artery, smaller than the posterior, runs outwards beneath the quadratus which it supplies, and enters between the abdominal muscles to which it is distributed. That of the first accompanies the last dorsal nerve between the abdominal muscles, and has a similar termination; those of the fourth and fifth vary much, according to the size of the ilio-lumbar artery of the internal iliac, and supply the iliacus muscle. Poste-rior branch. Ante-rior.

The *lumbar* or *vertebro-lumbar veins* commence by a posterior branch, which brings the blood from the muscles of the lumbar region of the back, and interior of the spinal canal; and by an anterior, from the muscles of the abdominal wall; these unite at the base of the transverse processes, and form a series of arches, which join above, the vena azygos, and below, the ilio-lumbar vein; from these arches the trunks of the veins commence, and they open either singly, or conjointly with the opposite, into the vena cava: they have the same course and relations as the arteries. The left are the longest, and cross beneath the aorta. Veins.

DISSECTION OF THE PELVIS.

The next step in the dissection, is the anatomy of the pelvis, or lower division of the abdomen. The parts contained in it are the termination of the intestinal tube or rectum, the bladder, and the generative organs which differ so much in the two sexes, as almost to make this appear in the female a separate and distinct region; in the male, in connection with the bladder are the prostate, vesiculæ seminales, and vas deferens, with the commencement of the urethra; but in the female, in addition to the bladder and rectum, are the uterus and its appendages —the ovaries, Fallopian tubes, and round ligaments, also the vagina. The vessels and nerves are situated at the posterior part of the cavity. These organs will be best examined by a lateral view obtained by taking away the os innominatum of one side; but before doing so, see the pelvic fascia lining the wall; and for this purpose, cut across, on the left side, the external iliac vessels at their point of origin, and turn them forwards, or remove them altogether; divide also the psoas muscle at the Dissec-tion.

same spot, and take away its anterior part, if it should not have been removed in the dissection of the lumbar plexus, the fascia that covered it having been previously reflected inwards to the margin of the pelvis; cut also the obturator vessels and nerve, and, the peritonæum being drawn inwards from the wall of the pelvis on the left side, scrape away with the handle of the knife the subserous cellular membrane which conceals the fascia beneath.

Insertion of the Iliac Fascia.

The attachment of the iliac fascia to the brim of the pelvis may be examined before the pelvic, to aid the understanding of the latter. If the reflected portion be followed, it is seen to end at the brim of the pelvis by joining the periosteum, and slightly, at one spot, the pelvic fascia attached to the same line; it extends forwards along the brim to the pectineal eminence, and is continuous, at this part, with the pectineal portion of the fascia lata, which ascends to be attached to the pectineal line of the pubes; but, at the sacro-iliac articulation behind, it leaves the brim, extends upwards along the inner margin of the iliacus muscle, as high as the ilio-vertebral ligament, and is fixed to the sacrum internal to its articulation with the ilium.

Pelvic Fascia.

The *pelvic fascia* is the thin membrane lining the wall of the pelvis, through which the obturator muscle is seen; it is attached above to the osseous boundary, and below, to the rami of the ischium and pubes, and great sacro-sciatic ligament; at a certain line in the cavity, which is seen by looking into it from above, it sends inwards a portion to the contained viscera; or it is usually said that the pelvic fascia descends to this point, and divides into two portions; an internal, the vesical, to the organs in the pelvis, and an external one, the continuation of the pelvic in direction, which descends to the margin of the inferior aperture of the pelvis, and is called obturator.* The portion reflected inwards to the viscera, or the vesical, cannot be seen till a section of the pelvis has been made, but the rest of the fascia on the wall, both above and below, can now be examined. The fascia above the giving off of the vesical, or the pelvic, is in close contact with the obturator muscle, and is firmly connected to the bone around its circumference, so that it is not attached, above, entirely to the brim of the pelvis, but only in a small extent of bone between the sacro-iliac symphysis, and the notch in the upper part of the obturator or thyroid foramen, and it here joins, for about one inch, the iliac fascia which is inserted into the brim; near the notch it quits the brim, and, still following the origin of the muscle, forms an arch below the obturator vessels; and from this spot inwards, it is fixed to the

* It would simplify the description of the fascia to call it *obturator* instead of *pelvic*, seeing that it closely incases the obturator muscle from its origin above to the inferior outlet of the pelvis; and to say that, at a certain point, it gave off the *recto-vesical* to the organs in the pelvis.

bone along an oblique line extended to the lower part of the symphysis of the pubes. Opposite the posterior border of the obturator muscle it becomes very thin, is prolonged backwards to the front of the sacrum, passes before the sacral plexus, and the pyriformis muscle, but behind the vessels, which perforate it to pass out of the pelvis. From its attachment above to the bone, it is much longer posteriorly than anteriorly, and a white firm band crosses it obliquely downwards and outwards from the lower part of the symphysis of the pubes to the spine of the ischium, to which it is united; this marks the attachment of the levator ani to the under surface, and from it the fascia is continued inwards to the viscera, forming, close below Poupart's ligament, two white tendinous-looking processes, the anterior ligaments or tendons of the bladder, the dorsal veins of the penis being placed in the depressed interval between them; on each side, by being fixed to the side of the prostate gland and bladder, the lateral true ligament of this viscus; and still posteriorly it passes to the side of the rectum. By the reflection inwards of the fascia to the middle line, it forms a kind of funnel-shaped tube, which is perforated with apertures for the prostate, bladder, and rectum, and in the female for the uterus and vagina; and at the posterior part of the pelvis it is also perforated by the vessels that leave the cavity. Its pelvic surface is in contact with the subserous cellular membrane, with the viscera of the cavity, and with the obturator artery and nerve; the outer is closely applied to the obturator muscle, to the fibres of which it gives attachment.

Dissection.

To see the obturator fascia, below the giving off of the vesical, raise the lower aperture of the pelvis, the perinæum having been previously dissected, and it will be exposed lying on the muscle of the same name, and entering into the outer wall of the ischio-rectal fossa. If a knife be carried upwards in the fossa, it will pass through the pelvic fascia in its line of division into the vesical and obturator, and will mark the origin of the levator ani in the angle of divergence of the two; this attachment is indicated internally by the white line before mentioned. As the levator inclines inwards as it descends, it adheres most strongly to the under surface of the vesical fascia, and it is separated by the fat of the ischio-rectal fossa from the obturator fascia.

Obturator Fascia.

The *obturator fascia*, of smaller extent than the pelvic, reaches from the line at which the vesical is given off, to the inferior outlet of the pelvis; it descends vertically, and in close contact with the obturator muscle, to be attached to the margin of the great sacro-sciatic ligament, and the rami of the ischium and pubes. For a certain distance below the pubic arch it is stretched across the anterior part of the outlet of the pelvis as the posterior layer of the triangular ligament. It covers the

outer boundary of the ischio-rectal fossa, and is joined above by the thin layer of membrane on the levator ani, from the base of the triangular ligament. One surface of it is in relation with the fat of the ischio-rectal fossa, and on it lie the pudic vessels and nerves, but contained in a sheath; and the other touches the obturator muscle.

Dissection. Detach the pelvic fascia on the left side from the wall of the pelvis, and separate it carefully from the obturator muscle as far backwards as to the spine of the ischium, and forwards to the anterior ligament of the bladder of this side: the levator ani arises from its under surface, and is raised with it. Saw through the left os innominatum in front, rather external to the anterior ligament of the bladder; next through the lateral part of the sacrum, internal to its union with the os innominatum; and lastly, cut off the spine of the ischium, so as to leave it attached to the levator ani; the bone can now be separated from the rest of the pelvis, but its removal is to be completed by dividing the parts passing through the sciatic notch, viz. the sacral plexus, the gluteal, sciatic, and pudic vessels and nerves, and the pyriformis muscle. All the muscular substance between the surface and the bone, which it would have been otherwise necessary to cut through in an untouched subject, has been already removed by those who have the other parts of the body. Place a small block beneath the subject to raise it from the table; partially distend the bladder, but not enough to occupy the whole of the pelvis; introduce some cotton wool into the rectum through its upper extremity; and insert another portion into the pouch of peritonæum between the rectum and bladder, in order that this may be prominent on the side. Clean the surface of the levator ani muscle, that presents itself, and is attached to the pelvic fascia which may be held up by hooks; remove the cellular membrane from the coccygeus muscle which is connected to the spine of the ischium, and also from the vessels and nerves that have been cut across.

Parts closing the Outlet of the Pelvis. It will be seen by this side view, that the great space in the lower part of the dried pelvis is closed, for the most part, in the natural state, by muscles extended between different points of the bones, or united to each other in the middle line. Thus, beginning behind, is the pyriformis muscle, now cut across, and above it are the gluteal artery and nerve; next, the coccygeus muscle, triangular in shape, attached by its base to the coccyx and by its apex to the spine of the ischium, and between the contiguous borders of these muscles are the sacral plexus of nerves, and the sciatic and pudic vessels, which lie in front of the pyriformis in the pelvis, but pass from the cavity between its lower border and the coccygeus: the small sacro-sciatic ligament is also behind the coccygeus, and connected to the same points of bone as it. The greater part of the remainder

of the space is closed by the levator ani, which extends forwards, on both sides, from the spine of the ischium to the posterior part of the symphysis of the pubes, and unites below with the coccyx, rectum, and with its fellow in the middle line; but, the anterior fibres being separated to give passage to the urethra, the interval left between them is closed by the triangular ligament of the urethra, stretched across below the arch of the pelvis. The great sacro-sciatic ligament, external to these muscles, assists to close the space, and the fascia supports internally the different viscera, and forms a sort of floor to the cavity of the pelvis.

The *coccygeus muscle*, flat and triangular, is situated in the outlet of the pelvis which it assists to close: it *arises* by a narrow pointed process from the spine of the ischium, also from the surface of the small sciatic ligament situated behind it; the fibres pass inwards, radiating to the side of the coccyx, and lower part of the border of the sacrum, into which they are *inserted*. This muscle is a mixture of fleshy and tendinous fibres, and it forms part of the floor of the pelvis; its anterior or pelvic surface is in contact with the rectum, its posterior with the sciatic ligaments; the upper border is contiguous to the pyriformis, but separated from this muscle by the termination of the sacral plexus, and the sciatic vessels; and the lower or anterior is parallel to the upper border of the levator ani, a cellular interval only existing between the two.

Coccygeus. Origin. Insertion. Relations.

The *levator ani*, a thin flat muscle with fine fasciculi of fibres, is attached to the side of the pelvis along a line extended obliquely downwards and backwards from the symphysis of the pubes to the spine of the ischium; and it hangs almost vertically in the lower aperture, supporting the rectum, prostate, and bladder, beneath which it joins its fellow. The anterior fleshy fibres *arise* from an oblique line on the posterior surface of the body of the pubes, above the transverse band of the pelvic fascia; and the posterior from the inner surface of the spine of the ischium; but between these two portions of bone they are separated from the osseous boundary of the pelvis by the obturator internus muscle, and therefore arise from the surface of the pelvic fascia along its line of division into vesical and obturator. The anterior fibres, the longest, descend by the side of the prostate, and close to the posterior layer of the triangular ligament, to join the fibres of the opposite muscle in the central point of the perinæum*; the more posterior are inserted into the side of the rectum, into the aponeurosis between

Levator Ani. Origin. Insertion.

* The anterior fibres of this muscle are often described as Wilson's muscle, and are said to surround the membranous part of the urethra, below which they unite with those of the opposite side; but the membranous part of the urethra is between the layers of the triangular ligament, and the muscle is behind the fascia that forms the posterior layer.

Relations. it and the coccyx, and also into the coccyx as before seen. The anterior border is in contact with the posterior layer of the triangular ligament, and with the apex of the prostate, separated only by its covering of vesical fascia; the posterior is parallel to the coccygeus, a slight cellular interval being between the two. The outer or perinæal surface, close to the obturator muscle above, the fascia that covers it only intervening, separates from it below, and a space, the ischio-rectal fossa, is found between them; this surface of the muscle is covered by the prolongation from the triangular ligament: the inner or pelvic surface is covered by the vesical fascia.

Dissection. Separate this muscle as well as the coccygeus from the vesical fascia, and a nerve to each will be seen. The portion of the fascia reflected inwards to the viscera descends on the surface of the rectum; and if it be divided by a longitudinal incision and raised upwards to the upper border of the prostate, the splitting of it is seen; a process also passes between the rectum and prostate.

Vesical Fascia. The *vesical*, or *recto-vesical fascia*, a prolongation from the pelvic, on a level with the thickened band that extends from the pubes to the spine of the ischium, passes inwards to the middle line to be attached to the bladder, prostate, and rectum, which perforate it, and to which it gives more or less perfect coverings or sheaths. In the middle line in front it is continued on both sides to the upper surface of the prostate by a strong band, the anterior true ligament of the bladder; behind this, it is attached to the side of the prostate and bladder, forming the lateral true ligament; and when it is followed inwards, it is found to divide at the margin of the prostate into two portions: one is continued upwards on the upper and lateral part of the gland to the bladder, on which it is lost as cellular membrane; and the other descends along the side of the prostate, furnishes it with an entire sheath by sending a portion below it, between it and the rectum, to join with a similar process from the opposite side; forwards on it to unite with the triangular ligament of the urethra; backwards, enveloping in a sheath the vesiculæ seminales which are situated beneath the bladder, and it is then continuous with that on the surface of the rectum, and joins the tube or sheath sent around this viscus when it perforates the fascia; for the rectum receives a prolongation both upwards and downwards from it. The sheath given to the prostate does not closely invest this body, but is separated by a considerable plexus of veins, the prostatic, and by many small arteries; the extent and number of the veins are best seen when the plexus is injected from the dorsal veins of the penis. In the female the fascia is continued down by the side of the vagina, which it envelopes, to the rectum.

Dissection. Take away the pelvic and vesical fasciæ from the organs to

which it is connected, but not the anterior ligament of the bladder, because the muscular fibres of this organ are connected to it, and a muscular fasciculus — the levator prostatæ — is immediately beneath it.* Remove the cellular membrane from the fibres of the lower part of the side of the bladder, but leave untouched the peritonæum which is to be examined; crossing the upper and lateral part of the bladder, is the obliterated hypogastric artery which passes forwards from the posterior part of the pelvis; lower than it, but having the same direction, will be found the ureter; and the vas deferens, in the male, is situated on the lateral region, crosses the hypogastric artery, and descends internal to it and the ureter; and if it be followed to the base of the bladder, the vesicula seminalis will be arrived at in the fibrous structure that surrounds it. Clean away the cellular membrane from the pouch of peritonæum between the rectum and bladder, in which some cotton wool has been placed to render it prominent: the vessels crossing its outer side, from the internal iliac opposite the sacro-iliac symphysis, are the obliterated hypogastric, the vesical and hæmorrhoidal arteries, with the uterine and vaginal in the female, and a large number of veins which correspond to the arteries, and open in front into the prostatic plexus: some branches of nerves, chiefly from the fourth sacral, accompany the arteries. Remove the cellular membrane from the intestine, and partially raise the bladder to clean the surface in contact with the rectum.

Levator prostatæ. Origin. Insertion. Relations.

The *levator prostatæ muscle*†, situated in the anterior fold of the vesical fascia, *arises*, narrow and tendinous, below the levator ani, and immediately above the arch of the pubes; it is also connected to the portion of fascia which separates it from this muscle; its fibres descend, and spreading out, are attached to the side of the prostate and neck of the bladder, some of them being continuous with those of this viscus. It is situated between the posterior layer of the triangular ligament, and the vesical fascia that covers it, and the fibres are paler than those of the levator ani. One muscle is separated from the other by the dorsal veins of the penis. The muscular fibres of the bladder are also seen to be connected to the anterior ligament of the vesical fascia, as well as to the levator prostatæ.

Cavity of the Pelvis.

The cavity of the pelvis, continuous above with the general cavity of the abdomen, contains the lower extremity of the intestinal tube — the rectum — together with a portion of the

* If the dissector should have a female subject, the description of its dissection and of the relative position of the viscera will be found at page 586.

† This is described by Santorini in his *Observationes Anatomicæ*, cap. x. § v., as "prostatæ musculus levator, seu adductor." Winslow, in his *Exposition Anatomique de la Structure du Corps Humain*, notices a superior and an inferior prostatic muscle: the last unites with its fellow of the opposite side beneath the prostate.

generative and urinary organs, and the vessels and nerves that supply them. Most posterior of all the viscera is the rectum, which is convex backwards, and receives into its concavity the bladder and its appendages, or in the female, the uterus and vagina. Connected to the bladder in the male are the prostate and vesiculæ at its lower part, the ureter behind, the urethra in front, and the vas deferens lies on the lateral surface in its course to the vesicula of the same side. In the female the uterus and vagina are interposed between the bladder and rectum, and the vagina is curved forwards somewhat in the same direction as the rectum, but placed above it. These organs are partially surrounded by the serous membrane of the abdomen, — the peritonæum, which may be next examined.

Reflections of the Peritonæum.

The *peritonæum* does not surround the viscera of the pelvis so completely or so firmly as those of the other portion of the abdominal cavity, though it assists in maintaining them in position; and the folds that result from its reflection, and have received distinct names, are occasioned by the vessels which traverse the cavity. If the membrane be followed in the middle line behind, it covers the front of the sacrum, surrounds the upper part of the tube of the rectum, except posteriorly where the vessels enter, and fixes the upper portion of the intestine to the front of the sacrum by a short fold — the *meso-rectum* — which contains the hæmorrhoidal vessels. It is then continued forwards to the posterior part of the bladder, projects for a considerable distance between this viscus and the anterior surface of the rectum, forming the "recto-vesical" pouch, or *cul-de-sac*, which is wide behind, where it corresponds to the interval between the internal iliac arteries, but is narrow and pointed in front, and extends into the interval between the vesiculæ at the base of the bladder, and in some instances to the prostate gland: its anterior termination is usually about four inches from the lower extremity of the intestine, or it reaches forwards to about one inch and a half of the tip of the coccyx: the small intestines are frequently found in it, and it is important to ascertain its extent in front, because of avoiding it in puncturing the bladder from the rectum, in the interval to be afterwards seen between the vesiculæ seminales; in the female it is smaller, is of less practical consequence, and is placed between the uterus and vagina in front, and the rectum behind. On each side of the pouch, the peritonæum is arrested in its descent into the pelvis by the internal iliac artery and ureter, and gives rise to the posterior ligaments of the bladder. It covers the posterior part of each lateral region of the bladder, as far forwards as the course of the obliterated hypogastric artery, but is then reflected off to both sides of the pelvis, as the lateral ligaments; and it is only the posterior portion of the summit of the viscus that is covered in the ascent of the

Meso-rectum.

Recto-Vesical Pouch.

membrane to the abdominal wall; for the same obliterated hypogastric vessels, and the remains of the urachus conduct it upwards, forming the anterior ligament, and so the anterior surface, and front of the upper part of the bladder are uncovered by peritonæum; a fact that is taken advantage of in making an aperture into it above the pubes during its distended state. The folds of the peritonæum from the bladder to the walls of the cavity are named false ligaments, since the reflections of the pelvic fascia are the true: they are five in number, two posterior, two lateral, and one superior. The *posterior* reaches forwards on the side of the rectum from the posterior part of the iliac fossa, it is concave upwards when the bladder is distended, and contains the obliterated hypogastric artery and the ureter, the latter crossing the artery, and then being situated below it. The *lateral ligament* extends from the side of the bladder to the iliac fossa, and its line of reflection from it is the course of the obliterated hypogastric artery; the vas deferens is also situated along the posterior part of its attachment, for it crosses over the hypogastric, and then descends internal to it. The *superior ligament* from the upper part of the bladder to the umbilicus, is also determined, chiefly, by the obliterated hypogastric arteries along which the peritonæum is continued.

False Ligaments of the Bladder. Posterior. Lateral. Superior.

The *rectum*, or lower portion of the great intestine, contained in the cavity of the pelvis, extends from the sacro-iliac symphysis to the anus, and is kept in position by the peritonæum and the pelvic fascia; it is not sacculated like the colon, but is uniform in size, except near its extremity, at which part it is much dilated, particularly in females, but the anus or aperture of termination is contracted by its sphincters, and is narrower than the rest; the fibres are also spread over the surface, instead of being collected into bundles. In this course the rectum is concave forwards, since it follows the curve of the sacrum, and is divided, from the difference in its direction, into three portions; an upper, which inclines obliquely downwards and to the right from the sacro-iliac symphysis, and ends in front of the third piece of the sacrum; a middle, that turns horizontally forwards in the middle line, beneath the bladder, to the extremity of the coccyx; and a third, which bends down from the tip of the coccyx to the anus. The *upper portion* of the intestine, of greater extent than the others, is surrounded almost entirely by the peritonæum which attaches it to the wall of the pelvis, forming the meso-rectum; it inclines obliquely inwards to the centre of the sacrum, and lies on this bone, the pyriformis muscle, and the sacral plexus; the branches of the internal iliac vessels and the ureter are on the left side of it, and the convolutions of the small intestine, when they extend low enough, in front: an interval separates it from the bladder, unless this should be much distended. In some subjects it inclines

Extent and Relations of the Rectum. Upper portion.

further over to the right side, and forms a remarkable curve like the sigmoid flexure. The *middle portion*, directed almost horizontally forwards in the middle line to the tip of the coccyx, is about three inches in length, and is covered by peritonæum to about one inch of its termination, but only on its anterior part; for when this membrane projects downwards to form the pouch, it does not invest the lateral part of the rectum. Above this division, or resting on it, are the prostate, and the base or lower part of the bladder, with the vesiculæ seminales which bound, laterally, a space on its under surface, corresponding to the "trigone vésical" on the inner, and it is in this spot, which is uncovered by peritonæum, that the bladder is entered from the rectum: behind or below it are the coccyx and inferior part of the sacrum, and on each side the coccygeus muscle and levator ani. The *lower portion*, about an inch and a half in length, is curved downwards to open on the surface about one inch in front of the extremity of the coccyx; it is at first very much dilated, but at its termination in the anus it is contracted. It is supported in position by the prolongation downwards of the triangular ligament, and also by the pelvic fascia: above it, or in front when the body is erect, are the prostate gland and membranous portion of the urethra; where it turns down, the bulb of the urethra is applied against it, and a triangular interval is left between the triangular ligament and bulb in front, the prostate behind, and rectum below. It is altogether uncovered by peritonæum, and the levatores ani muscles descend on the sides, and then unite beneath it, supporting it in a sling: the sphinctores ani surround its extremity. The position of the lower half of the rectum to the prostate varies much in different subjects; for sometimes the intestine is dilated, and rises up on both sides of the gland, enclosing it in a kind of sheath, or the prostate may be enlarged and project beyond the rectum: the former is the most common occurrence, and of the most importance with reference to the operation of lithotomy.

Middle.

Lower.

External Anatomy and Relations of the Bladder.

The *bladder*, or receptacle for the urine secreted by the kidneys, is situated in the pelvis, and is kept in position by the vesical fascia reflected to it, and also by the peritonæum which fixes it to the walls, as before seen. Its position and relations vary in the child and adult, and also in the different states of dilatation or collapse; for in the child and fœtus it is still in the hypogastric region, above the brim of the pelvis, but it afterwards descends to the position that it occupies in the adult. If it is contracted, it lies close against the front of the pelvis, and is of a triangular form, the base below, and the apex above behind the symphysis of the pubes; but when it is moderately distended with air or fluid, it is of a conical shape, the largest part being directed towards the rectum, and the apex to the abdominal wall between the pubes and umbilicus. Its axis is a line

passing through it, with an oblique direction from before backwards; if this were prolonged forwards, it would reach the abdominal wall midway between the pubes and umbilicus, and backwards, the extremity of the coccyx. To study the different relations of the parts of the bladder, it has been divided into a summit or superior fundus, a base or inferior fundus; the intervening part is the body, which ends anteriorly in a narrowed part, — the cervix. The *summit*, or superior fundus, is directed forwards, to its centre is connected the urachus, and on each side is the obliterated hypogastric vessel, which is ascending to leave the abdomen with the urachus by the umbilical aperture. The part behind the vessels is covered by peritonæum, but the portion in front is free from it; the small intestines are in contact with it; and if the bladder rise much out of the pelvis, it will touch, in front, the abdominal wall. Summit.

The *base*, or inferior fundus, or "*bas-fond*," directed downwards and backwards, differs most materially in its relations in the male and female. In the male, the vesiculæ seminales and vasa deferentia are attached to it; they are connected in front to the prostate, but diverge from each other as they pass backwards, and enclose a triangular space, whose boundaries are, laterally, the vasa deferentia and vesiculæ; in front, the prostate; and behind, the *cul-de-sac* of the peritonæum. The whole of the base is in contact with the middle portion of the rectum, and its posterior part, in the moderately distended bladder, is covered by peritonæum, but not the triangular interval before mentioned; and it is in this space that the viscus can be opened from the rectum without injuring the peritonæum. When the bladder is contracted, all this region is covered by the serous membrane. Base.

The *anterior surface* of the body is uncovered by peritonæum, and is in relation with the posterior part of the pubes, the sub-pubic ligament, the triangular ligament of the urethra, and the lower part of the abdominal wall; the anterior true ligaments pass to the neck: the absence of the serous membrane allows of the bladder being punctured above the pubes; the *posterior surface* is entirely covered by peritonæum, and the rectum and small intestines are behind it. Anterior surface.

The *lateral surface* is crossed from behind forwards, and near the upper part, by the obliterated hypogastric artery; below, is the ureter which enters the coats of the bladder, and on this surface is the vas deferens, which passes over the hypogastric artery, then turns downwards, passing internal to the ureter, and is finally directed forwards along the base to open into the prostatic portion of the urethra. The part of this region behind the hypogastric artery is in contact with the peritonæum, but all in front of it is uncovered, for it is this vessel that lies along the line of reflection of the lateral ligament: the lateral true ligaments are attached to the side of the bladder near the base. Posterior. Lateral.

Neck. The cervix, or *neck of the bladder*, is the narrow part by which it joins the urethra, and is the most anterior portion of this organ: it is surrounded by the prostate. It is connected to the wall of the pelvis by the vesical fascia, and in the child is the lowest point of the bladder, but in the adult the base extends below it towards the rectum.

True Ligaments of the Bladder. Anterior. The *true ligaments* of the bladder are removed on the left side, but they will be seen by gently separating the bladder from the wall of the pelvis. The *anterior* * of each side is a white tendinous-looking structure, which reaches from the posterior part of the body of the pubes to the upper surface of the prostate and neck of the bladder. It is formed by the reflection inwards of the vesical fascia, contains the muscular fibres of the bladder, which join it, and is placed over the levator prostatæ muscle: the one ligament is separated from the other by a depression, in which are found the dorsal veins of the penis. Lateral. The *lateral ligament*, also a part of the vesical fascia, is much thinner and wider than the anterior; it is attached, also, to the side of the prostate gland, and is then prolonged over this to the bladder.

Pelvic part of the Ureter. The *ureter*, or canal that conveys the urine from the kidney to the bladder, has been dissected in the part that lies on the abdominal wall, as low as to the margin of the pelvis; after it has crossed the common or the internal iliac artery it enters into the pelvis, contained in the posterior ligament of the bladder, it next passes over the internal iliac vessels, and sinks deeply in the cavity on the inner side of them and their branches; and in its extent forwards to reach the bladder, it forms an arch below the level of the obliterated hypogastric, and is crossed near the bladder by the vas deferens. The opening into the bladder is at the base, and rather on the outer surface, and about one inch and a half from the prostate.

Relations of the Prostate Gland. The *prostate gland* surrounds the neck of the bladder, and is situated at the front of the pelvis, and near the symphysis pubis; its shape is that of a cone, the larger end being turned backwards, and the smaller forwards to the triangular ligament of the urethra. The direction of a line carried through its centre is, in this position of the body, oblique, from above and from before, downwards and backwards, but in the erect posture it would be almost horizontal; its size is very variable, though commonly about that of a large horse-chestnut. Upper surface. The *upper surface*, placed about three quarters of an inch below the symphysis pubis, and posterior to a line carried vertically down from it, is in contact above with the anterior ligaments of the bladder, which connect it to the pubes, and with the dorsal veins

* Santorini calls this a ligament of the prostate, and he describes minutely the muscular fibres of the bladder connected to it ("ligamentum prostatæ novum"). — *Observationes Anatomicæ*, cap. x. § xvii.

of the penis. The *under surface*, of greater extent, measures from before backwards about fifteen lines, and is contiguous to the termination of the second and the third portion of the rectum, the capsule of the gland only intervening; it is this part of the prostate that is felt when the finger is passed into the rectum, and its breadth is about one inch and a half. To the *side* of the prostate are connected the lateral ligament and the fibres of the bladder, and the levator ani descends by it to its insertion. The *apex* reaches forwards to the triangular ligament, to which it is united by the capsule of the gland; and the *base*, surrounding the neck of the bladder and common ejaculatory ducts, is in relation with the vesiculæ seminales and vasa deferentia, and forms the anterior boundary of the triangular space at the base of the bladder; this part of the gland projects backwards to a line carried upwards from the tip of the coccyx. The prostate is enveloped by a sheath derived from the vesical fascia, and a plexus of vessels — the prostatic plexus — closely surrounds it. The urethra passes through the gland nearer its upper than its under surface; but this will be afterwards seen.

Under Surface. Lateral. Apex. Base.

The *vesiculæ seminales*, two narrow sacculated bodies, are situated between the bladder and the rectum. Each is pyramidal in form, about two inches in length, and half an inch in breadth; the larger extremity is turned backwards to the ureter, and the smaller forwards, is in contact with the prostate, by which it is surrounded, and ends in a duct which enters this body; along the inner side is the vas deferens, which joins, at the base of the prostate, with the duct from the vesicula. At the prostate gland the vesiculæ are almost close together, but as they pass backwards on the under surface of the bladder, they diverge from each other, leaving between them a triangular space, in which the rectum and bladder are close together, without the intervention of peritonæum. The vesicula is contained in a sheath derived from the fascia that covers the prostate.

Relations of the Vesiculæ seminales.

The *vas deferens*, or excretory duct of the testis, having entered the abdomen by the internal abdominal ring, crosses the external iliac artery and vein, and descends into the pelvis, beneath the peritonæum, to the side of the bladder, along which it runs from before backwards, and external to the position of the obliterated hypogastric: at the posterior part of this organ it turns suddenly over the remains of the hypogastric artery, and continues along the posterior surface of the bladder to the base, passing internal to the ureter: near the posterior part of the vesicula it again changes its direction, and, become enlarged and sacculated, is directed forwards along the inner surface of the vesicula of the same side to the base of the prostate, and joins with the duct of the vesicula to form the common ejaculatory

Relations of the Vas deferens in the Pelvis.

duct which perforates this gland, and opens into the prostatic portion of the urethra in a depression—the sinus pocularis—on the side of the middle line. This will be seen with the urethra and structure of the gland.

Relations of the Urethra.

The *urethra*, the excretory canal for the urine and semen, reaches from the bladder to the extremity of the penis in the male, or to the vulva in the female. Its mean length is about eight inches, and in its course to the surface one or two curves are seen. The direction of the canal is at first horizontally forwards to the triangular ligament of the urethra, through which it passes, is then inclined upwards in front of the symphysis to be applied to the body of the penis, and thus forms the first curve with its concavity upwards. In the rest of the extent it remains applied to the body of the penis, and its condition is determined by the state of this organ; for when pendent in front of the pubes and scrotum, the urethra forms its second larger curve, with the concavity downwards; but this is destroyed by raising the penis towards the abdomen. The canal is divided into a prostatic, membranous, and a spongy portion, whose relations are separate and distinct. The *prostatic* portion, within the cavity of the pelvis, is contained in the prostate, from which it receives its name, and extends from the neck of the bladder to the apex of the gland, or almost close to the triangular ligament; its length is about fifteen lines, and its relations are the same as those of the prostate. The *membranous portion* is the small circular tube of the urethra intervening between the apex of the prostate and the bulb, or corpus spongiosum of the urethra; it is somewhat curved upwards, is about half an inch in length along the under surface, and nearly as much again along the upper: this difference is occasioned by the direction backwards of the bulb. It passes through both layers of the triangular ligament about one inch below the pubes, and all the membranous portion of the urethra, except about the extent of a line, is in front of the posterior layer of the ligament, so that the greater part of it is between the layers of this structure; it is surrounded by the compressor urethræ muscle and by some veins, and below it is the third and last part of the rectum, with Cowper's glands; but it is separated from the intestine by an interval bounded in front by the bulb, behind and above, by the prostate and urethra, and below by the rectum. The *spongy portion* contained in the corpus spongiosum of the penis reaches from the bulb, in which it commences, to the extremity of the penis, and its length is about six inches. Besides the common integuments that envelop the body of the penis, it is covered by the ejaculator urinæ, before examined in the dissection of the perinæum. It would be advisable to remove the integument from this part of the urethra to see it to its termination.

Prostatic portion.

Membranous.

Spongy portion.

Penis.

The *penis* is a cylindrical organ situated in front of the pubes,

connected posteriorly to the rami of the pubes and ischium, but is free anteriorly, and presents an enlarged extremity,—the glans. In the ordinary state this body is curved downwards, and hangs in front of the scrotum, but when distended, either naturally or artificially, the shape and position are altered. It consists of a firm fibrous structure, — the corpus cavernosum, — to which is added the corpus spongiosum that envelops the urethra, and forms the glans; and the whole is surrounded by the common integuments, and supplied with vessels and nerves. The covering or *integument* of the penis is continued from that of the abdomen; but at the extremity of the organ it is destitute of cellular tissue, and forms around the glans a loose fold or sheath — the *prepuce* — which consists of a double fold, since the skin is reflected backwards from the free extremity as far as to the corona glandis, and is again continued forwards, closely united to the glans, to the orifice of the urethra, where it joins the mucous membrane of the canal: the reflected layer, very thin and fine, assumes the character of a mucous membrane, and forms beneath the glans, and behind the aperture of the urethra, a small triangular fold,—the *frænum præputii*; around the corona glandis, but behind it, are some small sebaceous glands, — the *glandulæ Tysoni* or *odoriferæ*. The *corpus cavernosum* will be seen by removing the integuments. It forms the greater part of the body of the penis, and consists of a dense, fibrous, almost cylindrical tube filled with vascular structure; it ends behind, opposite the symphysis of the pubes, in two pointed processes, — the *crura*,—each of which is attached to the rami of the ischium and pubes as high as the symphysis; and in front it is truncated and covered by the glans penis from the corpus spongiosum. It is slightly grooved above for the dorsal vessels and nerves, but below it presents a deep sulcus in which is placed the urethra, enclosed in the structure of the corpus spongiosum. Besides the attachment of this structure to the bones of the pelvis by the crura, it is supported by the triangular suspensory ligament of the penis. The *corpus spongiosum urethræ* contains in its centre the urethral canal, and constitutes part of the body of the penis. It is a vascular erectile structure like the corpus cavernosum, and is invested by a thin but strong aponeurosis, continuous with that derived from the triangular ligament. It commences behind, in front of the triangular ligament, or opposite the junction of the crura of the corpus cavernosum, in an enlarged or dilated portion — the *bulb* — which is placed between the crura of the corpus cavernosum in the arch of the pubes, and below the level of the membranous portion of the urethra, which it partly covers inferiorly by its projection backwards: this dilatation of the corpus spongiosum varies much in size, and is covered by the accelerator urinæ, which also covers the spongy substance for some distance. From the bulb, the corpus

Integument.

Corpus cavernosum.

Corpus spongiosum.

spongiosum extends forwards to the extremity of the penis without visible increase of size; but at this part it enlarges, and forms a conically-shaped portion — the *glans penis* — which is placed on the truncated extremity of the corpus cavernosum, its base being directed backwards, and projecting beyond it in a slightly prominent border — the *corona glandis* — which is inclined obliquely downwards and backwards as if the glans had been cut in that direction. The fine reflected portion of the prepuce covers the glans, and the frænum is attached to a groove on the under surface between the converging sides of the corona. The termination of the urethral canal by a vertical slit is in the extremity of the glans. The structure of this body will be dissected with that of the organs in the pelvis.

DISSECTION OF THE FEMALE PELVIS.*

Dissection.

In the female pelvis, after the levator ani and pelvic fascia are removed, the appearance of the side view differs much from that of the male in the relations of the urethra, bladder, and rectum, which exist in the two sexes, because of the interposition of the uterus and vagina between the bladder and rectum, and of the absence of other parts that are peculiar to the male. The dissector will have to distend the vagina from its external aperture, as well as the rectum and bladder; and in removing the cellular membrane and vessels from the organs, he will find three curved tubes running to the outlet of the pelvis: the rectum behind, forming the largest curve, the vagina in front of it, and still farther forwards and near the pubes, the small canal of the urethra. In cleaning the vagina, numerous vessels and nerves from the iliac vessels and sacral plexus, as well as a very large plexus of veins, will be found along its walls; all these lie on the outer side of the *cul-de-sac* of the peritonæum between the uterus and rectum; they may be removed on this side to study the relative anatomy of the viscera, and their distribution will be subsequently seen on the other side.

Peritonæum.

The *peritonæum* partially envelops the viscera as in the male pelvis. After it has invested the upper part of the rectum, and attached it to the front of the sacrum by means of a fold,—the *meso-rectum*,—it extends forwards for a short distance, in front of the middle division of this portion of the intestine, and reaches the posterior wall of the vagina, on which it ascends to the back of the uterus; it covers the posterior as well as the anterior

Meso-rectum.

* The dissector of the male pelvis will omit this, and continue with the description at page 589.

surface of this viscus, and at the front of its neck is continued to the back of the bladder, forming a small *cul-de-sac*, and without touching again the front of the vagina. On each side it forms a wide fold—the *broad ligament of the uterus*—which connects this organ to the wall of the pelvis, and divides the cavity into two parts; an anterior which contains the bladder, vagina, and urethra, and a posterior for the rectum and small intestines; it is partly subdivided into three portions, which envelop the parts contained within, there being a posterior for the ovary and its ligament, an anterior for the round ligament which ascends to the internal abdominal ring, and a middle one, the highest, for the Fallopian tube, and at the free extremity or orifice of this canal, the serous joins the mucous membrane. As the peritonæum ascends on the bladder to the abdominal wall in front, it covers the posterior surface, the posterior part of each lateral surface, as well as the posterior part of the apex; and its further extension on the viscus is prevented by the position of the hypogastric artery, along which it is reflected off, forming the *superior ligament* above, the *lateral ligament* on each side, and the *posterior ligaments* behind, which are two semilunar folds reaching from the back of the pelvis to the bladder, on the side of the rectum and uterus, and are occasioned by the same vessels passing forwards to the bladder. Between the bladder and rectum the peritonæum forms a *cul-de-sac*, larger than that in the male, but it does not reach so far forwards between the two, because of the presence of the uterus and vagina on which it is reflected. It is not so necessary to observe the anterior termination of this in the female, seeing that the bladder is not in contact with the rectum, and that no operation on it will be attempted from the intestine.

Ligament of the Uterus.

False Ligaments of the Bladder.

Pouch.

The *rectum* consists of three portions, with different directions and relations. The *upper*, from the left sacro-iliac junction to the third piece of the sacrum, passes obliquely downwards and to the right, is enveloped by the serous membrane, except behind where the vessels lie, and is in contact, in front, with the broad ligament of the uterus of the left side, and the contents of the same, as well as with the uterus and vagina: on the left side are the internal iliac vessels. The *middle portion*, which reaches to the tip of the coccyx, has the vagina above and in close contact with it, but is separated from it at first by the *cul-de-sac* of the peritonæum, which covers only part of this piece of intestine: the coccygei muscles are on the sides. The *third and lower* part, from the tip of the coccyx to the anus, is curved, and in contact above with the vagina, but in turning downwards it leaves a triangular space between it and this tube, which corresponds, on the surface, to the interval between the vulva and the anus. The levatores ani lie on each side, and unite below it.

Relations of the Rectum

Upper portion.

Middle.

Lower.

Relations of the Vagina.

The *vagina* is a tube or canal which reaches from the uterus to the vulva, in which it opens. It is cylindrical in shape, but rather flattened in front and behind; it is from four to five inches in length, and is directed obliquely downwards and inwards, curving above the rectum, so that the measurement of the upper wall is about four inches, but that of the lower about six. The upper part receives the uterus, which passes through its upper wall, and leaves a kind of pouch beyond it; the lower extremity, the narrowest part of the tube, opens in the vulva, and in the child is closed by the *hymen*, a crescentic fold of mucous membrane that contains cellular membrane in its interior. The vagina is slightly curved above, and is in contact with the base of the bladder, to which it is united by dense cellular membrane, and the canal of the urethra is so closely adherent to this wall or boundary, that it appears to pass through its substance. Below the tube is the rectum, from which it is separated in its upper fourth by the pouch of peritonæum, but lower than this it is connected to the intestine, except at the extremity, as before said. To the sides are attached, below, the vesical fascia, and the levator ani passes by it to its insertion. The large vaginal plexus of veins is also placed on its side.

Relations of the Uterus.

The *uterus* is a conical, or pear-shaped, muscular organ, placed in the cavity of the pelvis between the bladder and the rectum, and kept in position by the round and broad ligaments. It is divided into body and neck, and its axis is directed obliquely downwards and backwards. The *anterior surface*, in close position to the bladder, is covered by peritonæum, except in its inferior fourth, and it is here in contact with the lower part of the bladder, and united to it by cellular membrane; the *posterior* is entirely covered by peritonæum and corresponds to the rectum and convolutions of the small intestines. The *lower extremity* is received into the upper wall of the vagina; and the upper is in contact with the small intestines. To the sides are attached the broad ligaments which contain above, on each side, the Fallopian tube, which is about four or five inches long, and reaches transversely from the upper angle of the uterus to the side of the pelvis; it is narrow at its uterine extremity, but is dilated, trumpet-mouth-shaped, and fringed at the other end, — the corpus fimbriatum, — and is directed backwards and inwards towards the ovary which is placed at the posterior part of the broad ligament. Below the Fallopian tube, and contained in the same fold of the peritonæum, is the round ligament, a fibrous cord that passes upwards and outwards over the obliterated hypogastric artery and the external iliac vessels, to leave the abdomen by the internal abdominal ring; it passes through the inguinal canal, and ends in the cellular membrane of the groin. In its course to the abdominal ring it is surrounded by the peritonæum, and it takes a tube of

Anterior surface.

Posterior.

Inferior extremity.

Superior.

Broad Ligaments.

this a considerable distance into the inguinal canal, but it is, generally, afterwards obliterated, like the similar process in the male. The other remaining body contained in the broad ligament is the ovary, which is of an oval form, its extremities being placed transversely: it is situated at the back of the fold, and is connected, internally, by a ligament of its own — the ligament of the ovary — to the side of the uterus, below the attachment of the two other structures.

Relations of the Bladder

The *bladder* is situated behind the symphysis pubis, and above the vagina, and its form, position, and relations, with few exceptions, so closely resemble those of the male, that it will be unnecessary to repeat them again, since they can be referred to in the description of the male pelvis. The chief differences are these: — it is larger, and its transverse measurement exceeds the vertical; the base is of less extent, and is not below the level of the urethra, as in the male, but is in contact with the inferior fourth of the anterior surface of the uterus, and with the vagina, which separate it from the rectum; the lateral surface has no vas deferens crossing it; the lower part of the anterior surface corresponds to the vestibule in the vulva, or the interval between the clitoris and the aperture of the urethra; and the prostate gland is absent from its neck. The anterior true ligaments, or the reflections of the vesical fascia are connected to the neck of the bladder, and the lateral, to the bladder and vagina.

Relations of the Ureter.

The *ureter* has a longer course in the female than in the male pelvis; it is contained in the posterior ligament of the bladder, crosses the internal iliac vessels, and in reaching forward to the bladder, it passes by the upper and lateral part of the vagina, and the neck of the uterus.

Relations of the Urethra

The *urethra* of the female, a small narrow tube, about one inch and a half in length, passes forwards and downwards above the vagina, being slightly concave upwards, to open within the vulva and below the clitoris and vestibule. This canal is the third arched tube that lies in the cavity of the female pelvis, and it is placed highest. In its course to the surface it perforates the triangular ligament, and is so closely united to the vagina, that it may be said to run in its substance. The urethra is at first covered above, by the anterior ligaments of the bladder, and is enveloped by a plexus of veins; when it enters within the layers of the triangular ligament it is surrounded by the compressor urethræ, and the transverse portions, described by Santorini as a depressor, are the most distinct.

The articulation of the pubic bones in the *symphysis* may be next dissected, since it will be necessary to remove it, to see the vessels and nerves in the pelvis.*

* The following description of the articulation, and of the vessels and nerves, will serve for the dissection of both the male and female pelvis.

Symphysis of the Pubes. The oval articular surfaces of the ossa pubis enter into this articulation, and they are retained in contact by an intervening strong fibro-cartilage, and by some scattered fibres on the anterior, posterior, and superior parts of the articulation, also below by a strong sub-pubic ligament: these will be readily exposed by removing the cellular structure.

Anterior Pubic Ligament. The *anterior pubic ligament*, in front of the bones, and the strongest of those surrounding the articulation, with the exception of the sub-pubic, consists of different layers of fibres; the superficial of these are oblique, and connected with the tendinous attachments of the abdominal muscles, but the deeper are transverse and lie on the fibro-cartilage, to which they are united. The other fibres above and behind the symphysis are sometimes called distinct ligaments, with the names of *superior*, and *posterior pubic*.

Sub-pubic Ligament. The *sub-pubic ligament* is a strong, firm, triangular ligament, placed below the symphysis, and occupying the upper part of the pubic arch; its fibres, curved downwards, and united above with the fibro-cartilage between the articular surfaces, are inserted on each side into the upper par of the rami of the pubes. It is situated between the layers of the triangular ligament, and its fibres are perforated by the pudic nerve and dorsal veins of the penis.

Articular Surface and Fibro-cartilage. Separate one os pubis from the other: the articular surfaces, marked on the dry bone, are seen only to be in contact for a small space about the middle, and this spot is covered with cartilage, and apparently by a synovial membrane, since there is a viscid fluid between them; but the remainder of the surface is united by an intervening *fibro-cartilage*, which is white, elastic, and formed by two distinct portions, one being attached to each bone, and connected together by transverse fibres which form concentric laminæ. This cartilage is thicker in front than behind, and its breadth is greatest at the upper and lower parts of the symphysis.

Dissection. To expose the internal iliac vessels of the right side, let the air out of the bladder, and draw it, the rectum, and in the female the uterus and vagina, from the central position that they occupy in the cavity of the pelvis to the opposite side, so as to allow of the dissection of the vessels. Remove the peritonæum and fascia from the wall of the pelvis and from the viscera, and clean away the great quantity of cellular membrane that surrounds the arteries: a plexus of nerves from the hypogastric accompanies each vessel to the viscera, so that there are as many secondary plexuses as arteries. The smaller branches of the veins that accompany the arteries, unless they are to be specially dissected, may be removed. In following the lower vesical and hæmorrhoidal branches, the nerves from the sacral plexus to these viscera may be exposed, and they

should be left to be afterwards seen. When the arteries are dissected out, the bladder may be again distended and the viscera replaced, to see the relative anatomy.

The *internal iliac artery*, one of the trunks into which the common iliac divides, supplies the wall of the pelvis both within and without; the viscera contained within it; also, for the most part, the genital organs. As now dissected, it is seen to be a short thick trunk, continued forwards along the side of the bladder to the umbilicus by a partially obliterated cord. This vessel in the fœtus is called hypogastric; and the internal iliac is the part which afterwards remains pervious for a certain distance. To understand this vessel, it will be advisable to consider its anatomy in the fœtus, as well as in the adult in which part is obliterated. The *hypogastric artery* of the fœtus commences at the sacro-iliac symphysis, from the division of the common iliac into it and the external iliac artery; it passes forwards to the posterior part of the bladder, contained in the posterior ligament, forms an arch whose concavity looks upwards, and is crossed by the ureter which then descends below it to the bladder; it gives off in this extent many branches to the wall and the viscera. The vessel then ascends on the side of the bladder to its upper part, along the line of reflection of the peritonæum from it, as the lateral and superior ligaments; and at the upper part of this organ it approaches the one of the opposite side, and ascends with the urachus to the umbilicus, between the peritonæum and fascia transversalis, and behind the rectus muscle of the abdominal wall; at this aperture, each perforates the fascia transversalis, comes into relation with the umbilical vein, and, receiving the name of *umbilical*, continues to the placenta, in which it ends. On the side of the bladder the hypogastric is crossed by the vas deferens, and supplies the vesical branches. This vessel, in the fœtus, is twice the size of the external iliac, but after birth these arteries are obliterated, more or less completely, to about an inch and a half of their commencement, or to the sacro-sciatic notch, and a ligamentous cord remains in the direction of the vessel; this is commonly pervious, by means of a very small canal, to near the upper part of the bladder, and from it arise the superior vesical branches. When the hypogastric begins to diminish, the external iliac, and the posterior part of the hypogastric, which is afterwards designated the internal iliac, increase in size. The *internal iliac* in the adult is a large short trunk, about an inch and a half long; it is directed obliquely downwards and inwards from the sacro-iliac symphysis to the upper part of the sacro-sciatic notch, and it here divides into two or three large branches in which it appears to terminate; but from its extremity the partially obliterated hypogastric extends forwards in the original direction of the trunk. The artery is accom-

Internal Iliac Artery.

panied by the internal iliac vein which is posterior and external to it; it lies in the fold of peritonæum which forms the posterior ligament of the bladder, and is crossed by the ureter; behind it is the lumbo-sacral nerve, and part of the pyriformis muscle. Its branches are very numerous, and some are very variable in their origin, though the distribution of the greater number of them is tolerably regular: they may be classed into those which supply the viscera in the pelvis: namely, the hæmorrhoidal, vesical, uterine, and vaginal; and into those distributed to the wall of the pelvis either within or without: these are the ilio-lumbar, lateral sacral, gluteal, sciatic, pudic, and obturator arteries. As the internal iliac artery divides into two trunks, the branches are sometimes referred to their origin from either the one or the other; thus, from the posterior, arise, most commonly, the ilio-lumbar, lateral sacral, gluteal, and obturator; and from the anterior, the middle hæmorrhoidal, vesical, uterine, and vaginal, and the partially impervious tube of the hypogastric, with the sciatic and pudic.

Branches.

Ilio-lumbar Artery.

The *ilio-lumbar* artery, the first of those supplied to the wall of the pelvis, arises from the posterior part of the internal iliac, is directed obliquely upwards and outwards beneath the psoas muscle and obturator nerve, and in front of the lumbo-sacral nerve, to reach the iliac fossa, in which it divides into an ascending and a transverse branch. The *ascending* or *lumbar* runs beneath the psoas muscle by the side of the lumbar vertebræ, and divides into an external branch for the psoas and quadratus muscles, and an internal one for the spinal canal and medulla; the *transverse* or *iliac* branch passes outwards a little above the brim of the pelvis, and subdivides into superficial and deep branches, which are directed towards the crest of the ilium and anastomose with the circumflex ilii artery, and some turn over the crest to join with the gluteal: one of the deep branches enters the substance of the bone.

Lumbar branch.

Iliac.

Lateral Sacral Artery.

The *lateral sacral*, one or two in number, arise from the inner side of the iliac, or from the gluteal; when there is only one, the artery descends in front of the pyriformis muscle and sacral plexus of nerves, at first external to the series of apertures by which the nerves escape, but afterwards over them or internal to them, as far as to the coccyx, on which it anastomoses with the branches of the middle sacral artery, and the one of the opposite side; but this will be more apparent after the removal of the viscera. Besides the branches to inosculate with the middle sacral, the artery gives off spinal branches which enter the spinal canal, and supply the membranes of the medulla with ramifications; others leave the canal by the posterior apertures in the sacrum to anastomose with the gluteal. When there are two arteries, the upper one enters the first aperture in the front of the sacrum, and is distributed in the canal in the same manner as the others; but before entering it, some sm

transverse arteries are given off to join those of the middle sacral.

The *gluteal artery*, the largest branch of the internal iliac, passes directly backwards above the upper border of the pyriformis muscle, between the lumbo-sacral and first sacral nerve, the former afterwards concealing the artery as it descends to join the plexus; it then leaves the pelvis by the upper part of the sacro-sciatic notch, lying close to the bone and accompanied by a vein and the superior gluteal nerve: as soon as it appears on the outer surface of the pelvis, it divides into its superficial and deep branches for the gluteal muscles; these are dissected in the thigh, and are now removed. Gluteal Artery.

The *ischiadic* or *sciatic artery* descends with the pudic into the pelvis; it arises anterior to the gluteal, is the next largest trunk, and runs downwards and forwards with the pudic but internal to it, and over the pyriformis muscle and the sacral plexus of nerves, to leave the pelvis at the lower part of the great sacro-sciatic notch, and with the pudic vessels and nerve and the sciatic nerves between the contiguous borders of the pyriformis and coccygeus muscles. External to the pelvis, it divides beneath the gluteal muscle into its terminal branches. This artery often arises by a common trunk with the gluteal, and from the division of this at the upper part of the sciatic notch, it descends in front of the pyriformis, and beneath the sacral plexus, to leave the pelvis by the same part. Sciatic Artery

The *pudic artery* has nearly the same relations in the pelvis as the sciatic, from which it often springs as this vessel is passing from the cavity. If it arises separately from the internal iliac, it and the sciatic appear to be the continuation of this artery into the pelvis; it passes downwards over the pyriformis, and sacral plexus, external to the sciatic, and leaves the pelvis between the borders of the pyriformis and coccygeus; it then winds over the outer surface of the spine of the ischium, and enters into the ischio-rectal fossa through the small sciatic notch, in which part its anatomy has been seen, when dissecting the perinæum. In this — the pelvic — part of its course, the artery lies behind the bladder and vesiculæ and along the side of the rectum, and gives small branches to these viscera; sometimes the middle hæmorrhoidal artery arises from it, and in the female, branches to the uterus and vagina. An important variety in this artery is its course in the pelvis along the side of the bladder, and either on or near the side of the prostate gland, to leave the cavity by perforating the triangular ligament below the arch of the pubes to become the dorsal artery of the penis. Pudic Artery.

The *obturator* will also be required to be seen only in its pelvic part, since the portion external to the pelvis is dissected with the lower extremity, and is usually completed before this Obturator Artery.

stage of the dissection of the abdomen. This artery springs either from the posterior or anterior division of the internal iliac artery, or it may arise altogether at the front of the pelvis from the epigastric artery, a branch of the external iliac. In the case of origin from the internal iliac, it crosses the pelvis from behind forwards, rather below the level of the brim, but above the attachment of the levator ani muscle, and is accompanied by the obturator nerve and vein, which are inferior to it. At the front of the cavity the obturator vessels and nerve pass through an obliquely grooved canal—the *sub-pubic*—in the upper part of the thyroid or obturator foramen, and as soon as they have escaped from it, the nerve and artery separate; the former continues along the thigh, but the latter divides into two branches that encircle the obturator foramen, and supply chiefly the obturator muscle, and the articulation. In the pelvis this branch gives some small arteries externally to the wall, and one rather large to the iliac fossa and muscle, which perforates the iliac fascia. When it is about to enter the sub-pubic aperture, it gives upwards a branch that varies in size, to anastomose with the epigastric, and inwards a transverse one behind the body of the pubes, to inosculate with a similar branch from the opposite side. When the obturator arises from the epigastric, it descends to the same aperture and has the same distribution externally, but in its course it passes by the crural ring; and it is the relation of this vessel to the neck of the sac of a femoral hernia that renders important the study of varieties in its position. If it arise high from the epigastric, and take a large sweep to the inner side of the iliac vein, it will most probably be on the inner side of the hernia, and therefore the neck of the sac would be surrounded in front and on the inner side by this artery, the epigastric lying on the outer side; but should the vessel arise near the commencement of the epigastric, and pass nearly vertically downwards into the pelvis, it will be found close to the iliac vein and to the outer side of the crural ring, and therefore of a femoral hernia: this last variety is not so important as the first, since it is not equally dangerous.

Middle Sacral Artery.

The *middle sacral artery* will be seen more fully after the viscera are removed from the pelvis; it arises from the division of the aorta, of which it is the continuation in its direction, and passes vertically downwards in the middle line over the last lumbar vertebra, the sacrum, and the coccyx, as far as the base of this bone, and where, much diminished in size, it divides into two lateral branches which inosculate with the lateral sacral arteries. Many small arteries are given to the front of the sacrum, and opposite the centre of each piece of this bone, as well as of the last lumbar vertebra, it gives to each side a transverse branch to anastomose with the lateral sacral: these are analogous to the lumbar and intercostal arteries of the aorta.

The coccyx is also supplied by some small branches from the bifurcation.

The branches to the viscera contained in the cavity of the pelvis are smaller and more irregular than those to the wall, and are generally derived from the portion of the artery that continues forwards to the bladder in the direction of the hypogastric. Branches to the Viscera.

The *middle hæmorrhoidal* artery, a small branch of uncertain origin, may come either from the internal iliac, or from the sciatic or pudic; it passes downwards and forwards along the front and lateral part of the rectum, and divides into branches that anastomose with the superior hæmorrhoidal, — a branch of the inferior mesenteric, and with the inferior hæmorrhoidal from the pudic in the ischio-rectal fossa. It gives also small branches — the *inferior vesical* — to the base of the bladder and prostate; or to the vagina in the female. The distribution of the *superior hæmorrhoidal*, a branch of the inferior mesenteric, can now be seen: after crossing the ureter and the left common iliac artery and vein, it descends in the meso-rectum along the posterior part of the intestine, and opposite the middle of the sacrum, or about four inches from the anus, it divides into two branches which continue forwards on the sides of the rectum, anastomosing with each other, with the middle hæmorrhoidal, and near the rectum with the *inferior hæmorrhoidal* from the pudic; so that the termination of the large intestine is supplied from the inferior mesenteric, from the internal iliac, and from the pudic artery. The branches of the superior hæmorrhoidal are the largest and the most important in operations on this intestine. Middle Hæmorrhoidal Artery. Superior. Inferior.

The *vesical arteries*, irregular in their origin, may come from the trunk or from some of the branches of the iliac. They are three or four in number, on each side, and are divided into superior, middle, and inferior. The *superior* come from the partially obliterated trunk of the hypogastric, and pass downwards and inwards along the front of the bladder. The *middle* vesical, generally arises as a separate branch from the internal iliac near the remains of the hypogastric; it passes forwards and inwards to the posterior part of the bladder, which it reaches on the outer side of the ureter, and is then distributed to the posterior surface by branches which anastomose with those of the opposite side, as well as with those from the superior. The *inferior*, some small branches from the middle hæmorrhoidal, sciatic, or pudic, are distributed to the base of the bladder, to the vesiculæ seminales, and to the prostate. An artery — the *deferential* — is also given to the vas deferens; it accompanies this tube to the spermatic cord, and anastomoses with the spermatic. Vesical Arteries. Superior. Middle. Inferior.

The uterine and vaginal arteries are peculiar to the female: Uterine.

the *uterine* arises from the internal iliac at its anterior part, near to the middle hæmorrhoidal, or with it, passes inwards in the broad ligament, and reaches the uterus opposite its neck; it next turns upwards along its side, becomes very flexuous, and divides into anterior and posterior branches, which anastomose with similar ones from the opposite side, and supply the front and back of the uterus; and middle, that ascend to the fundus and inosculate also with the opposite and with the spermatic. When the artery makes its turn upwards along the uterus, it sends one or more small branches between the bladder and vagina to these organs.

Spermatic or Ovarian.

The *spermatic artery* has been dissected to the lower part of the abdomen, and it may now be completed; it becomes very tortuous after it has passed the brim of the pelvis and entered the broad ligament by which it is conducted to the ovary, to which it gives many branches, as well as to the Fallopian tubes. After supplying the ovary, it ends in the substance of the uterus, anastomosing with branches of the uterine.

Vaginal.

The *vaginal artery* frequently arises by a common trunk with the preceding, or else very near to it; it passes forwards on the side of the vagina, giving a great number of branches to it, and some to the under and anterior part of the bladder and commencement of the urethra; and it ends by anastomosing, below the vagina, with the artery of the other side.

Veins. Internal Iliac.

The *internal iliac vein* receives the blood both from the wall of the pelvis and from the viscera contained in it, by branches corresponding for the most part to the arteries that arise from the internal iliac. It is situated at first internal to the artery, but as it ascends it passes behind, appears on its outer side, and joins with the external iliac, opposite the sacro-iliac symphysis, to form the common iliac vein. Some of the branches of the veins have the same distribution and anatomy as the arteries, but others differ. The *ilio-lumbar* vein anastomoses with the lateral sacral, receives some small branches from the spine, and lower lumbo-vertebral vein, and opens into the common iliac vein. The *lateral sacral* opens into the internal iliac, and by an upper portion into the common iliac; and the *middle sacral* joins the left common iliac vein. The *hæmorrhoidal* vein is united to a plexus — the *hæmorrhoidal* — around the lower part of the rectum, into which the superior and inferior hæmorrhoidal veins enter; the ramifications of this plexus round the anus become enlarged in hæmorrhoids. If these are injected from the inferior mesenteric vein before dissecting the pelvis, a more accurate idea of their extent will be obtained.* The *vesical* veins are connected with another large plexus, the *prostatic*, which is situated around the bladder and prostate, between the substance

Ilio-lumbar.

Sacral.

Hæmorrhoidal and Plexus.

Vesical. Prostatic Plexus.

* Tallow injection runs sufficiently minutely, and has the advantage of not requiring the body to be heated.

and sheath of the gland, and joins in front the dorsal veins of the penis, which perforate the triangular and sub-pubic ligaments: this may also be injected from the dorsal vein of the penis. In the female, the *vaginal* veins commence in a large plexus — the *vaginal* — surrounding the vagina, particularly its lower part or aperture, with a vascular network or erectile structure; this communicates, above, with a small plexus around the bladder and urethra, which corresponds to the prostatic in the male, and unites, below, with the hæmorrhoidal. The *uterine* veins also come from the uterine plexus which lies on the sides and upper part of the uterus, and they communicate above with the spermatic. The veins of the uterus are very much enlarged during gestation, and are called *sinuses of the uterus*, since they are dilated into pouches. The remaining veins are the same as the arteries.

Vaginal and Plexus.

Uterine.

The *hypogastric plexus* for the supply of sympathetic nerves to the viscera of the cavity of the pelvis, is situated in front of the sacrum and beneath the peritonæum. It consists of a right and a left portion; each division accompanies the internal iliac artery of the same side, and sends off filaments along its branches which, separately, are named distinct plexuses, but to dissect them requires a fresh body, and one uninjected. Thus the inferior hæmorrhoidal plexus accompanies that artery to the rectum, some filaments being distributed to the front, and some to the posterior part of the intestine. The *vesical* surrounds the artery of the same name, unites with branches of the sacral nerves, and at the posterior part of the bladder gives offsets to the upper and lower regions of this viscus, and to the prostate gland; other filaments go to the vesiculæ seminales, and also to the vas deferens, on which they run to join the nerves from the spermatic plexus, and they even continue onwards to the testis. In the female, branches are supplied to the uterus, forming the *uterine plexus*, from which filaments ascend with the vessels along the side of this body to the upper part, both before and behind; some others descend to the vagina supplying it, and others are distributed to the Fallopian tube and ovary; and on this last body they join the spermatic nerves that accompany the artery of the same name.

Nerves. Hypogastric Plexus.

Inferior Hæmorrhoidal.

Vesical.

Uterine and Vaginal.

Of the lymphatic glands of the pelvis, some lie along the external iliac, some in the interval between the internal and external iliac vessels, and others on the sacrum; they join, above, the lumbar glands by the side of the aorta.

Lymphatic Glands.

Separate the remains of the triangular ligament and the urethra, in both sexes, from the arch of the pubes; cut through the levator ani and pelvic fascia of the right side; saw off the symphysis of the pubes, and a portion of the body on the right side, to reach more easily the parts in the pelvis; let the air escape from the bladder, and then draw well over to the oppo-

Dissection.

site side the viscera of the pelvis. By this proceeding, the anterior branches of the sacral nerves can be dissected by removing the cellular membrane; the four first join, either in part, or entirely, with the lumbro-sacral nerve in the sacral plexus; but the two lowest will be found along the outer margin of the sacrum and coccyx, coming through the coccygeus muscle. The branches to the viscera are derived from these nerves, and from the hypogastric plexus of the sympathetic, but it will require care to follow them through the vesical fascia to the bladder, prostate, and rectum.

Sacral Nerves. The anterior branches of the six sacral spinal nerves differ much in size, as well as in their distribution; each joins with branches from the gangliated portion of the sympathetic nerve

First. after it escapes from its foramen. The branch of the first nerve is the largest, and is separated from the lumbo-sacral by a considerable interval, and by the gluteal artery; it is directed outwards in front of the pyriformis muscle to join in the sacral

Second. plexus. That of the second, nearly as large as the first, passes

Third. transversely outwards to the plexus. The anterior branch of the third nerve, much smaller than the other two, runs also outwards to join the sacral plexus; but it is separated by a considerable interval from the second, and it often gives a branch

Fourth. to the viscera. The branch of the fourth, still smaller than that of the third, separates into two portions; one very small joins the plexus, and the other divides into many branches: some of these — the *visceral* to the organs of the pelvis — are directed inwards and forwards, enter between the layers of the posterior ligament of the bladder, and join freely with filaments of the sympathetic from the hypogastric plexus, forming a kind of plexus from which branches are distributed to the rectum, to the under surface of the bladder, the vesiculæ seminales, and the prostate; whilst others ascend to the sides of the bladder: the viscera receive also sympathetic nerves from the hypogastric plexus with the arteries that supply them. The other branches—the *muscular*—are distributed to the coccygeus, to the levator ani by a long branch that enters the pelvic surface of the muscle, and reaches to near the front, or there are two branches, one to its posterior and one to its anterior part; and sometimes a branch perforates the coccygeus to supply the gluteus; the remaining branch is a long descending one by the side of the coccyx in the fibres of the coccygeus muscle, to join with the fifth nerve. The two remaining nerves are smaller than the preceding, and do not unite in the plexus. The branch

Fifth. of the fifth comes through the fibres of the coccygeus, and is joined by a descending filament from the fourth; it sends down one to communicate with the sixth, and gives a descending branch to the tip of the coccyx, which perforates the coccygeus or the levator ani, and, appearing in the ischio-rectal

fossa, is distributed to the integument and sphincter: this branch may come from the next nerve. The anterior branch of the sixth receives a descending filament from the fifth, and divides into branches that supply the coccygeus, and some perforate it and the sacro-sciatic ligament to end in the gluteus maximus. Sixth.

The *sacral plexus*, formed by the union of the lumbo-sacral nerve of the lumbar plexus with the three first sacral nerves and part of the fourth, is a flat band in which the nerves end, rather than form a plexiform body by the division, union, and subdivision of the branches entering into it as in the other plexuses. It is situated in the pelvis on the pyriformis muscle, external to the layer of pelvic fascia continued over it, and the pudic and sciatic branches of the internal iliac artery separate it from the viscera in the cavity. The plexus passes from the interior of the pelvis by the lower part of the great sacro-sciatic notch, below the pyriformis muscle, and it ends in the great sciatic nerve, which is the chief branch that arises from it; so that it is difficult to assign its limit. Its branches may be divided into those that arise within the pelvis and into those on the outer side; the internal are, a nerve to the obturator internus, the inferior hæmorrhoidal and internal pudic nerves, and a branch to the pyriformis muscle; and the external, a nerve to the superior gemellus, a branch to the inferior gemellus and quadratus femoris, but this most commonly comes from the great sciatic at the posterior part of the pelvis, and the small and great sciatic nerves. The origin of the superior gluteal from the lumbo-sacral can now be seen. Sacral Plexus. Branches.

The *nerve to the obturator internus* muscle arises within the pelvis from the front of the plexus, and chiefly from the lumbo-sacral and first sacral nerves; it runs downwards to the spine of the ischium, is placed on the outer surface of this with the pudic, enters the ischio-rectal fossa through the small sciatic notch, and is distributed by branches to the inner surface of the muscle. To the Obturator Muscle.

The *internal pudic* leaves the lower part of the plexus, turns over the posterior surface of the spine of the ischium with the branch to the obturator internus, and with the next nerve, enters the ischio-rectal fossa through the small sciatic notch, and is distributed to the perinæum and genital organs, as before seen. Pudic.

The *inferior hæmorrhoidal*, when a distinct branch, is given off close to the pudic, runs the same course to the ischio-rectal fossa, and its distribution is dissected with the perinæum. This nerve is very commonly a branch of the pudic in the perinæum. Inferior Hæmorrhoidal.

The *nerve to the pyriformis* arises from the back of the third nerve after it has joined the plexus, and it divides into branches that enter the anterior surface of the muscle. To the Pyriformis.

To the Gemelli and Quadratus.

The *nerve to the superior gemellus*, as well as that to the *inferior* and the *quadratus*, spring from the plexus at its termination in the great sciatic nerve, and are altogether on the back of the pelvis. The last very often arises distinctly from the great sciatic.

Small Sciatic.

The *small sciatic nerve* arises from the lower and outer part of the plexus, which may be said to end in this and the great sciatic, sometimes by one and sometimes by two nerves, that remain more or less distinct to their distribution to the gluteal region, and cutaneous parts of the back of the leg, and perinæal space.

Large Sciatic.

The *great sciatic nerve*, in which the plexus terminates, leaves the pelvis with the preceding, below the lower border of the pyriformis muscle, and is then distributed, as seen in the dissection of the thigh.

Dissection.

Divide the remains of the hypogastric artery, and also the other arteries that supply the viscera, in order to see the gangliated part of the sympathetic on the front of the sacrum.

Sympathetic in the Pelvis.

In the interior of the pelvis, the sympathetic has the same general disposition as in the other cavities of the body, viz. in the upper portion of the abdomen, and in the thorax; it consists of a large prevertebral plexus — the hypogastric — formed by branches from ganglia distant from those supplying the viscera, and of a gangliated cord on each side of the spine, to join the spinal nerves at their exit from the foramina. The hypogastric plexus has been seen. The gangliated cord is placed on the front of the sacrum, and internal to the anterior sacral foramina; it is continuous above with the last lumbar ganglion by a small filament which it is often difficult to trace, and it ends below, at the lower part of the sacrum, by a filament from the last ganglion turning inwards in front of the base of the coccyx to unite with a similar one from the opposite side in an arch, from which branches proceed to the periosteum of this bone. The cords approach each other in their course to the tip of the sacrum, and each is marked by a variable number of ganglia, though there are commonly three or four, from which filaments pass *externally*, and these are the largest, to join the sacral nerves, *internally* to communicate in front of the sacrum and around the middle sacral artery with branches from the opposite side, and *anteriorly* some slender filaments unite with the hypogastric plexus, and supply also the rectum. Occasionally, the last ganglion does not send a transverse branch to join with that of the opposite side, but distributes filaments to the coccyx; or there may be a small ganglion—the *ganglion impar*—at the point of union on the front of the coccyx, from which the branches descend.

Dissection.

Take the viscera from the pelvis, to examine their structure; separate the rectum from the bladder, and then blow up the

bladder to dissect the muscular fibres by taking away the peritonæum and cellular membrane. Clean the prostate and vesiculæ, and follow the common duct, resulting from the union of that of the vesicula with the vas deferens, into the posterior part of the prostate.*

Form and Structure of the Vesiculæ.

The *vesiculæ seminales* are two membranous sacculated reservoirs for a peculiar secretion. Each is formed by a tube folded upon itself, so as to give rise to small lateral pouches which are united together by a fibrous tissue that retains this form; and if an incision be made into it, the cellular structure will be seen, and also a brownish viscid fluid which it contains. The vesicula ends in front in its duct, a small straight portion, that joins with the vas deferens to form the *common ejaculatory duct*, which passes forwards through the prostate to open into the urethra. When this body is submitted to maceration, its coils may be unravelled, and the tube is found to measure about eight inches; it consists of an external fibrous, and of an internal mucous coat.

Of the Vas deferens.

The *vas deferens* is much dilated near the vesicula, is slightly sacculated like it, and ends in front in the common duct; its structure is an external fibrous coat, very thick, and an internal mucous, very fine and thin. The peculiar feel of this cord is always easily recognised.

Form and Structure of the Prostate.

The *prostate gland* is a firm greyish body surrounding the commencement of the urethra and neck of the bladder, and is enveloped by a sheath of vesical fascia. It is conical in form, the larger extremity, as before said, is placed behind, and the smaller in front: the upper surface is convex, without any mark of division, but on the under, there is a slight longitudinal depression, which, with a notch in the posterior part, indicates the division of it into a right and left lobe. In the centre of the base or posterior part is a large notch, into which the common ejaculatory ducts enter, the substance of the gland forming an arch both above and below them; and on each side of this excavation the gland is prolonged backwards, giving rise to the *lateral lobe*.

Lateral Lobe.

If the vesiculæ and common duct be thrown forwards over the gland, a transverse portion of it, about half an inch wide, is seen above them; this is the *middle lobe* which unites together the two lateral, and extends further backwards than the opposite or under margin of the hollow for the ejaculatory ducts.

Middle.

The prostate measures, transversely, about eighteen lines, vertically, about twelve, and from before backwards about fifteen lines; so that the transverse incision, or one directed obliquely downwards and outwards in the direction of the lateral lobe, is the longest that can be practised in this body. Its structure consists of a congeries of small glandular bodies placed in a fleshy-looking fibrous substance; and from these issue small

* The description of the anatomy and structure of the viscera of the female pelvis will be found at p. 603.

ducts, which either unite together, or run separately to open on the inner surface of the urethra contained in the prostate; they are lined by the mucous membrane of this canal: these will be seen when the gland is opened, and the small glandular bodies will be very well perceived now in the third lobe, by removing the dense external covering.

Structure of the Bladder.

Now the bladder is removed from the body, the extent of the different regions, but particularly the base, can be more readily seen; but its figure will be almost circular when it is much distended with air. A partial serous, a muscular, and a mucous coat, with a layer of cellular tissue between them, will be found in the substance of the bladder. The *peritonæal coat* has been examined and is now removed. The *muscular* consists of an external and an internal layer of fibres; the external, of longitudinal ones, passes downwards from the summit of the bladder and urachus, to which they are connected, to the prostate gland, some of the anterior being prolonged on its upper surface to be united to the pubes by the anterior ligaments; the lateral are connected to the sides of the prostate; and the posterior to the middle lobe of the gland. When this covering is removed, the internal layer of transverse fibres is exposed; it is stronger, and the fibres are closer together at the lower than at the upper part of the bladder, and on the posterior surface a few of them run irregularly and cross the others. Some of the lower fibres of this layer have been described as a sphincter vesicæ, but there does not appear to be any fasciculus of fibres distinct and separate from the other circular ones. This coat differs much in its development in different subjects, and in some the mucous coat projects in small pouches between its fibres, giving rise to the sacculated bladder. There is also a distinct muscular fasciculus passing from the opening of the ureter to the prostate; this is to be seen when the bladder is opened. The *mucous membrane* lines the interior of the bladder, being prolonged upwards into the ureter, and downwards into the urethra, and it is separated from the muscular coat by the layer of cellular membrane before mentioned. Cut open the bladder by an incision along its front, and carry it along the upper part of the prostate; the mucous membrane forms numerous folds in its present flaccid state, and the muscular columns project beneath; and if it is a sacculated bladder, the apertures to the pouches are seen. At the lower and anterior part of the bladder is the orifice of the urethra, which is situated within the base of the prostate gland, and partially closed by a small prominence from below,—*the uvula;* this is a little in front of the middle lobe of the prostate, and is a projection of the submucous tissue that raises the lining membrane into a fold which is continued forwards into the prostatic portion of the urethra. Immediately behind the orifice of the urethra is a small triangularly-shaped space

Peritonæal Coat.

Muscular.

Mucous.

Uvula.

the "*trigone vésical*," in which the mucous membrane is smooth, and more closely united to the other coats; into the posterior angles the ureters open, about one inch and a half behind the uvula, and the same distance from each other; so that a line extended from one aperture to the other, and one on each side from the ureter to the uvula, will define the boundaries of the space; the posterior line in the distended bladder is semilunar. The "*trigone*" is the most sensitive part of the bladder, and corresponds below to the interval included between the prostate in front, and vesicula and vas deferens on each side. It is smaller in the female, and the uvula is not so marked. In a muscular bladder two prominent lines extend from the apertures of the ureters to the uvula, and if the mucous membrane be removed, the *muscles of the ureters* are exposed: they are "two strong fleshy columns which descend from the orifices of the ureters towards the orifice of the bladder; they unite and run towards the prostate gland." "Where these columns unite they are most fleshy, and their fibres are more intricate; then directing their course towards the lower and backmost part of the prostate, they degenerate into tendon, and are inserted into the portion called the third lobe of the prostate." * In some subjects these are very indistinct.

Trigone.

Muscles of the Ureters.

Open the remainder of the urethra to the extremity of the penis, and carry the incision through the corpus cavernosum, but rather to one side of the middle line, to leave untouched its septum pectiniforme.

Dissection.

The *urethra*, or tube extending from the bladder to the extremity of the penis, is about eight inches long, and divided into a prostatic, membranous, and spongy portion. The *prostatic*, about fifteen lines in length, has not a coat distinct from the gland through which it passes, since it is only an excavation in this body along which the mucous membrane of the bladder is continued, together with some submucous cellular membrane. By the section of the gland it will be seen that the part above the urethra measures only about three or four lines, in consequence of the urethra passing through it much nearer the upper than the under surface. This division of the urethra is wider in the centre of the prostate than at either extremity, and it is altogether the widest part of the urethral canal. Where it joins the bladder is a small elevation — the *uvula* — which closes the orifice of this viscus in its contracted state; and in the centre, on the under surface, is a raised prominent fold of mucous membrane — the *caput gallinaginis* —

Divisions and interior of the Urethra

Prostatic portion.

Uvula.

Caput gallinaginis.

* See "Account of the Muscles of the Ureters," by Sir C. Bell, in vol. iii. of the *Medico-Chirurgical Transactions*, from which the above extract is taken.

Morgagni described these before, in his *Adversaria Anatomica*, i. 9., as "duo quædam carnea vesicæ corpora," but as ending in the "caput gallinaceum."

which is large and round behind, but is prolonged in front by a slightly elevated line to the membranous portion of the urethra. In the centre of this fold, near its posterior extremity, is a depression — the *sinus pocularis*, into the posterior part of which open the two common ejaculatory ducts, a thin portion only of the mucous membrane separating the orifices; these are seen by holding up the sides of the sinus, and a probe may be passed into each of them. External to this projection of the membrane, the substance of the gland is hollowed out on each side, this excavation is called the *prostatic sinus*, and into it the smaller ducts from the substance of the prostate gland open; but the larger ones, that can be followed downwards and backwards for some distance into the gland, open on the side of the caput gallinaginis in front of the sinus pocularis: bristles may be readily introduced into these last, and when the gland is pressed, a considerable quantity of a whitish fluid quickly escapes from them. If a probe is introduced into the ejaculatory duct, its relation to the substance of the prostate can be observed. The *membranous portion*, about one inch in length in this condition of the urethra, has very thin coats, and is supported chiefly by the muscle that surrounds it; it is one of the narrowest parts of the canal, and measures in diameter about four lines. The mucous membrane that is continued through it is surrounded by a thin vascular erectile covering, and externally by a muscular layer; in the interior of the tube the lining membrane presents nothing remarkable. The *spongy portion*, about six inches long, resembles the prostatic, in being contained in an enveloping substance — the corpus spongiosum. It is circular in form, like the membranous, is about four lines in diameter, but presents, nevertheless, slight variations in its size; for in the bulb, or commencement, it measures one line more, and from the increased size of this part it is named the *sinus*: it is slightly contracted opposite the scrotum, or bend of the penis, but is enlarged again in the glans, giving rise to the *fossa navicularis*, and the vertical orifice of the extremity is usually its narrowest part. A mucous coat lines the interior, and in it are numerous lacunæ, some smaller than the others, which secrete a lubricating fluid for the passage: they project into the submucous tissue, and their apertures are directed forwards; the largest of these, called *lacuna magna*, is placed on the upper surface of the urethra near the fossa navicularis. Near the bulb, and on the under surface of the canal, are the two apertures of the ducts of Cowper's glands, which will scarcely admit a bristle.

Sinus pocularis. Prostatic Sinus. Membranous portion. Spongy portion. Sinus of the Bulb. Fossa navicularis. Lacuna magna.

Structure of the Penis.

The *corpus cavernosum* or body of the penis is formed by a dense, fibrous, elastic covering, about a line in thickness, which determines its form, and sends inwards processes which cross each other, forming cells; but one of these, larger than the rest,

and named from its form the *septum pectiniforme*, reaches from the upper to the under surface, extends backwards to the division of the corpus cavernosum into two crura, and at the posterior part serves as a partition between the two sides of the organ, but anteriorly it is an imperfect septum, is not so strong, and consists of vertical bundles of fibres, like the teeth of a comb, with intervals between them, through which the vascular structure of one side of the penis communicates with that of the other. The tube of fibrous membrane is filled by a vascular erectile tissue, formed by veins capable of great distention, which anastomose with each other to form plexuses, and are contained in cells or spaces left between the crossing processes of the fibrous tissue, that project into the interior of the corpus cavernosum. Into these venous cells the blood is conveyed by a peculiar termination of the branches of the artery of the corpus cavernosum, which Müller describes as ending in two sets of branches. "The one set are the ultimate ramuscules, which terminate in the minute radicles of the veins, and are destined for the nutrition of the part. The other set come off from the side of the arteries, and consist of short slightly-curled branches, terminating abruptly by a rounded, apparently closed, extremity turned back somewhat on itself: these are sometimes single; sometimes several arise by one stem forming a tuft. I have named them *arteriæ helicinæ*. They project into the venous cells," are most distinct in man, and although no openings are found in them, Müller thinks they fill the venous cells during erection, since fine injection escapes from them into the cells.* The cellular structure of the penis, in which the venous plexuses are contained, may be seen by distending the penis with air, and drying it, or by injecting it with tallow, and afterwards dissolving it out in warm turpentine. The structure of the *corpus spongiosum* is the same as that of the corpus cavernosum; it is erectile like it, but the trabecular tissue is not so firm and strong as in the corpus cavernosum. The *artery* of the *corpus cavernosum* is now seen, if the subject is tolerably injected, to extend forwards to the front of the penis, giving off lateral branches to end in the arteriæ helicinæ. The *veins* of the penis end in the dorsal veins, and in deep veins of the cavernous body; some of these accompany the arteries of the same name to the pudic, and others join at the root of the penis with the superficial veins.

Septum pectiniforme.

Corpus spongiosum.

Artery.

Veins.

The *rectum* is to be washed out, distended with air, and then to have the cellular membrane and peritonæum removed from it. This part of the intestine is not sacculated as the colon, but is considerably dilated just before its termination. It has a partial serous coat, a muscular, and a mucous, with a dense cellular one

Structure of the Rectum.

* See Translation of *Müller's Physiology* by Dr. Baly; note to p. 225.

between the mucous and muscular. The *muscular coat* consists of two planes of fibres, as in the œsophagus; a superficial, of *longitudinal*, which are diffused over the whole surface of the intestine instead of being collected into three longitudinal bands as in the colon; and a deep, of *circular* fibres, which form a thick layer, and project around the extremity of the intestine, as the internal sphincter muscle. The *mucous coat* lines the interior of the rectum, and is continuous at the margin of the anus with the integuments. It is marked by folds, which are more or less regular, and have been described by Mr. Houston*; but to see them the intestine is to be hardened with spirit, and then cut open whilst it is in its natural position, since distending it with air destroys some of the folds or valves. "Three is the average number, though sometimes four, and sometimes only two are present in a marked degree. The position of the largest and most regular valve is about three inches from the anus, opposite to the base of the bladder. The fold of next most frequent existence is placed at the upper end of the rectum. The third in order occupies a position about midway between these; and the fourth, or that most rarely present, is attached to the side of the gut, about one inch above the anus." "The relative position of the valves, with respect to each other, deserves attention. That situated opposite to the base of the bladder, most commonly projects from the anterior wall of the gut; the valve next above from the left, and the uppermost from the right wall: that near the anus, which is of least frequent occurrence, occupies a place, when present, towards the left and posterior wall." Each valve, about half an inch wide, is semilunar in shape, and is attached by its convex border to about one half of the intestine; it is formed by mucous membrane, and by some of the circular fibres of the intestine which project into the cavity. In the mucous membrane will be found the same tubes and solitary glands that exist in the mucous membrane of the rest of the large intestine. The vessels and nerves of this part have been previously dissected in the pelvis.

ANATOMY OF THE FEMALE GENERATIVE ORGANS.

Dissection. To examine the organs peculiar to the female pelvis, take out the contents of the cavity, together with the external genital organs: examine first the external: the rectum may be separated from the vagina and uterus. The external organs consist

* "Observations on the Mucous Membrane of the Rectum," vol. v. of the *Dublin Hospital Reports*, from which the following extracts are taken.

of the mons veneris, the labia, the clitoris, the vestibule, the orifice of the urethra, the orifice of the vagina with its hymen or carunculæ: all these are included in the general term vulva or pudendum.

External Genital Organs.

Labia majora.

The *labia majora* are two raised folds of integument extending down from the prominence of the mons veneris, to unite below in the inferior commissure or fourchette; their point of divergence above is the superior commissure, and the interval between them is named the *rima;* they are folds of the common integument, containing vessels and nerves, and covered externally with hair, and lined internally by mucous membrane. Between the anus and fourchette is an interval about an inch long, which is sometimes named the perinæum. The *clitoris* will be exposed in the upper commissure by removing the integument; it is a small erectile organ, similar in structure to the penis, except that it wants the corpus spongiosum urethræ, and the uninary canal is not conveyed along it to the extremity. It is situated close below the superior commissure of the labia, and slightly projects between them; the anterior extremity is named the *glans*, and it is covered by a fold of integument — the *prepuce* — from which two prolongations pass downwards, as the labia minora. In structure this organ resembles the penis, since it is formed of a corpus cavernosum, attached by two crura to the rami of the ischium and pubes; it is divided into two portions by a septum pectiniforme, and it possesses the same erectile tissue. The *labia minora* or *nymphæ* are two folds of mucous membrane, which pass from the prepuce of the glans to about the middle of the vulva; they contain, in their interior, an erectile tissue. About one inch below the clitoris, and in the centre of a projection, is the *orifice of the urethra;* and the space between the clitoris and the meatus is called the *vestibule.* The *external aperture* of the *vagina* is close below the orifice of the urethra, and it is partially closed in the child and virgin by a semilunar fold of mucous membrane — the *hymen;* but when this is destroyed, small irregularly-shaped portions — the *carunculæ myrtiformes* — surround the entrance of the vagina. Between the orifice of the vagina and the inferior commissure of the labia majora is a small depression, the *fossa navicularis.* The distribution of vessels and nerves to the clitoris and labia is dissected with the perinæum.

Clitoris.

Urethra Orifice.

Vestibule.

Orifice of the Vagina.

Carunculæ.

Fossa navicularis.

Internal Generative Organs.

The internal organs concerned in the process of generation are the uterus, vagina, ovaries, and Fallopian tubes. The uterus and vagina will be best seen by removing, with care, the bladder from them.

Form and Structure of the Uterus.

The *uterus,* the organ for the reception of the ovum, and retention of it for a certain period, is a conical or pear-shaped body, divided into fundus, body, and neck. In the unimpregnated female it is much smaller than after parturition, and it

measures vertically, about two inches and a half, transversely at the fundus, one inch and a half, but at the neck, about half an inch; its thickness is near an inch. The *upper part* or Fundus. *fundus* is convex, and covered by peritonæum. The *body* de- Body. creases in size to the neck, and its anterior and posterior surfaces are also covered by peritonæum, but the lateral is less closely invested by it, and to it are connected, on each side, the Fallopian tube above, the round ligament rather below and before it, and the ligament of the ovary below and behind. Neck. The *neck* of the uterus, about six lines long, is received into the vagina which surrounds it, a greater part of this canal being found on the posterior than on the anterior surface; and to see this, cut open the vagina by an incision along its anterior part; it is now perceived also to become more pointed below, and in it is the aperture of communication with the vagina, which is a Os Uteri. transverse fissure — the *os uteri* or *os tincæ* — whose margins are named *labia*, the anterior being the thickest. Open the uterus by an incision along the front from the os tincæ to the Cavity of the Body. fundus. The cavity, very small for the size of the organ, is divided into two differently shaped portions, one of the body and one of the neck; that of the body is of a triangular form, the upper angles being prolonged towards the Fallopian tubes which open into them, one on each side, and below it is continuous with that of the neck by a narrowed part, sometimes named Of the Neck. the *os uteri internum;* that of the neck is circular in shape, is contracted at each extremity, but enlarged in the middle; and along both the anterior and posterior wall is a longitudinal line from which transverse rugæ pass: this appearance has been named the *arbor vitæ*, and in the depressions between the rugæ are contained some mucous follicles. The rugæ disappear after Mucous Membrane. gestation. The cavity of the uterus is lined by *mucous membrane* continued into it from the vagina, and it is then prolonged into the Fallopian tubes. The uterus consists of a reddish dense Structure. structure which is muscular, but its fibres appear only in the impregnated state, or when the uterus is enlarged.* The vessels and nerves have been dissected.

Form and Structure of the Fallopian Tube. The *Fallopian tube*, one on each side of the uterus, is a narrow circular tube about four inches long, connected by one end to the substance of the uterus, and by the other it is free and floating; its outer extremity is much dilated or trumpet-shaped, and the circumference of it, irregularly divided or fringed, is Corpus fimbriatum. named *corpus fimbriatum*, or *morsus diaboli*. When it is placed in water the fringed portion is seen to form two or more circles, the inner surrounding the orifice of a canal in its interior. A

* For farther information see Hunter on *The Anatomy of the Human gravid Uterus*, plate 14., and its explanation; and a paper by Sir C. Bell, "On the Muscularity of the Uterus," in the 4th vol. of the *Medico-Chirurgical Transactions.*

probe may be passed into the outer part of the tube, but the inner is so small as to admit only a bristle: this tube may be laid open. It receives externally a covering of the peritonæum, and internally the mucous membrane lines it, forming near the outer end some longitudinal folds, and being continuous internally with that of the uterus, and externally with the peritonæum that covers the tube: this is the only example in which a mucous and serous membrane are continuous. Between the peritonæal and the mucous coats is a fibrous structure similar to that of the uterus which it joins.

Structure of the round Ligament.

The *round ligament* of the uterus is a dense fibrous cord, attached to the lateral part of the organ, with which its fibres join. It is covered by peritonæum, and some veins run in it; it ends in the groin in cellular membrane.

Form and Structure of the Ovaries. Ligament.

The *ovaries*, the analogues of the testes in the male, are two in number, one for each side; each is of an oval form, and is attached by its internal extremity to the uterus by a ligamentous fold — the *ligament of the ovary*, and by its external, to one of the fimbriæ of the trumpet-shaped extremity of the Fallopian tube. This body is of a whitish colour, irregular on the surface, and consists of an external fibrous coat which is closely covered by the peritonæum, and encloses a spongy vascular tissue, in which are placed small roundish transparent bodies — the *Graafian vesicles*. The number of vesicles varies from eight to twenty, and each consists of two membranes enclosing a fluid, in which is contained granular matter together with the ovum. After the escape of an ovum from the ovary, a striated yellow spot — the *corpus luteum* — remains, and this is sometimes seen on the surface of the ovary.

Vesicles.

Form and Structure of the Vagina.

The *vagina*, or tube by which the uterus communicates with the surface, is larger above where it receives the uterus than below; now it is laid open, the position of the uterus in the upper wall, instead of at the extremity of the canal, is apparent. The anterior or upper boundary is very thick below, and contains in its substance the canal of the urethra; but the upper part of this portion of the vagina, and the posterior boundary or wall are much thinner. In the interior is a prominent line extending along the anterior wall, and from this pass folds or rugæ to each side, but these are most marked near the orifice, and present a rough transverse eminence: the same is seen on the posterior wall, but not so distinctly: these longitudinal lines are called the *columns* of the vagina. The rugæ are more distinct in the child, and before pregnancy; but they afterwards disappear in the upper part of the canal. The substance of the parietes is formed by a spongy erectile tissue situate between two fibro-cellular layers, the external being the stronger; and this structure is more abundant in the lower than in the upper part of the canal: around the urethra it forms a projection that

contains this tube, and gives to the vagina its greater thickness in this part. The aperture of the vagina is surrounded by the muscular fibres of the constrictor vaginæ. The mucous membrane lining it is marked by the folds before mentioned, and by mucous follicles, and it is continued into the uterus. It is covered by an epithelium which appears to cease at the mouth of the uterus. The vaginal plexus of veins that surrounds the canal has been already seen, as well as the vessels and nerves.

The rectum and bladder of the female so closely resemble in structure those of the male, that to notice them separately is unnecessary.

Urethra. The urethra in the female is very simple, it is contained in the erectile tissue of the vagina, and is surrounded by the compressor urethræ and by a thin layer of erectile tissue.

CONTINUATION OF THE ABDOMEN.

In the cavity of the pelvis is seen a part of the pyriformis, and of the obturator internus muscle: these will be readily exposed by removing the cellular tissue, or, if it be necessary, the sacral plexus, from the front of the pyriformis muscle.

Pyriformis Muscle. Origin. The *pyriformis muscle* is situated partly within and partly without the pelvis; is wide and fleshy at its *origin*, and arises within the pelvis by three or four digitations from as many pieces of the sacrum, except the first, in the interval between the foramina, as well as from the surface external to the foramina; it is also attached to the portion of the ilium which forms the upper and posterior part of the great sciatic notch, and to the great sciatic ligament. The fibres pass almost horizontally outwards, converging towards each other, and give rise to a conically-shaped muscle, which passes from the cavity, and ends in a tendon which is *inserted* into the great trochanter above the gemelli and obturator tendons. This muscle in passing through the great sciatic notch divides the space into two parts; through the upper pass the gluteal vessels and nerve, and through the lower the sciatic and pudic, with the branch of nerve to the obturator muscle. The anterior surface is in contact with the rectum, the sacral plexus, and the sciatic and pudic branches of the iliac artery; and the posterior rests on the sacrum. The upper border is near to the upper part of the sciatic notch, but separated from the bone by the gluteal vessels; and the lower is parallel to the coccygeus muscle, but the parts that escape by the lower part of the sciatic notch intervene between them. The relations of the part of the

Insertion.

Relations.

muscle external to the pelvis belong to the dissection of the thigh.

Obturator Internus Muscle. Origin.

The *obturator internus muscle*, also placed partly in the pelvis and partly without, presents its larger extremity at its attachment to the os innominatum. It *arises* by a broad fleshy attachment from the inner surface of the obturator membrane, from the margins of the sub-pubic notch, except above in the spot occupied by the ligament which converts it into a foramen, and it is here attached to this ligament; it also arises from the inclined surface of the pelvis behind the obturator foramen, extending backwards to the sciatic notch, and upwards to the brim of the pelvis, and some fibres are also connected to the obturator fascia covering the muscle. From this origin the fibres are inclined downwards and backwards, and end in four or five tendons which are at first concealed in the muscle, then appear on its under surface, and turn over the pulley-like surface of the ischium, to leave the pelvis by the small sacro-sciatic notch, the surface of the bone being covered with a portion of cartilage for each tendon, and lubricated by a large synovial membrane. When these tendinous processes have passed from the pelvis, they unite into one tendon which is *inserted* with the gemelli into the great trochanter. The muscle lies on the obturator membrane, and side of the pelvis; its pelvic surface is covered by the pelvic and obturator fasciæ, and all the portion below a line carried from the lower part of the symphysis to the spine of the ischium, forms the outer boundary of the ischio-rectal fossa; and near its lower attachment are placed the pudic vessels and nerve, with the branch of the nerve to the obturator muscle. It may be thrown down to expose the tendons in its interior, as well as the obturator membrane.

Insertion. Relations.

Obturator Membrane.

The *obturator membrane* or ligament may be further dissected by removing the obturator externus from its outer surface. It is a thin membranous structure that closes the obturator foramen, except above at the sub-pubic notch, and it is attached to the circumference of the aperture; the fibres cross in different directions, and perforating between them are branches of the obturator nerve. The outer surface is covered by the obturator externus, and obturator artery; and the inner is in contact with the obturator internus muscle.

Union of the Sacrum and Os innominatum.

The sacrum is articulated to the os innominatum by the contact of the irregular articular surfaces of these bones, which are covered with cartilage, and are maintained in position by anterior and posterior sacro-iliac ligaments. The lower part of the sacrum and os innominatum are also connnected together, without being in contact, by the great sacro-sciatic ligaments; and the upper part of the ilium is united in like manner to the last lumbar vertebra by the ilio-lumbar ligament.

Dissection

It will be necessary to remove the mass of muscle from the

hollow of the back of the sacrum to see the posterior sacro-iliac, but the anterior will be visible in front of the articulation by merely taking away some cellular membrane. The ilio-vertebral ligament is on a level with the crest of the ilium, and at its posterior part between it and the transverse process of the last lumbar vertebra. The great sciatic ligament has been dissected with the lower extremity, and the small one will be exposed by removing the coccygeus.

Articular Cartilage. The osseous surfaces that enter into the sacro-iliac junction or symphysis, are covered with a cartilage which is thicker on the sacrum than on the os innominatum, its surfaces are very rough and irregular, and connect the bones together. A synovial membrane is present in the child and pregnant female between the cartilages which cover the opposite portions of bone.

Anterior Sacro-iliac Ligaments. The *anterior sacro-iliac ligaments* are only a few scattered shining fibres in front of the articulation, and are connected to the surfaces of the bones.

Posterior Sacro-iliac Ligaments. The *posterior sacro-iliac ligaments*, much stronger than the anterior, pass transversely from the rough part on the inner surface of the os innominatum, behind the portion articulated with the sacrum, to the posterior part of the two upper pieces of this bone, and more particularly to the intervals between the foramina: the fibres of these ligaments are collected into bundles, and the intervals between them are filled with fat. One of these, flatter and more superficial than the rest, and distinct from them, is named the *long posterior* or *oblique ligament;* it is attached above to the posterior superior spinous process of the ilium, and descends almost vertically to be inserted into the posterior surface of the third piece of the sacrum, external to its foramen.

Oblique.

Ilio-lumbar Ligament. The *ilio-lumbar ligament* does not unite together articular surfaces, but extends between the crest of the ilium and the transverse process of the last lumbar vertebra; it is a triangular ligament divided into fasciculi, and is attached internally, by a narrow pointed portion, to the tip of the transverse process, externally, it radiates to be connected to the crest of the ilium about three inches above the posterior superior spine, or where the crest forms a projection inwards at the posterior part of the iliac fossa. This ligament assists in forming part of the fossa, and gives attachment by its front to the iliacus muscle. The posterior surface is covered by the erector spinæ muscle; and the upper border gives insertion to the layer of the lumbar aponeurosis that separates the quadratus lumborum from the erector spinæ.

Sacro-sciatic Ligament. The *sacro-sciatic ligaments*, very large and strong, connect, as the preceding, points of bone not in contact with each other; they pass from the lateral part of the sacrum and coccyx to the

spine and tuberosity of the ischium, across the space between the os innominatum and the sacrum, and divide this excavation into two notches, — the great and the small sciatic. The *great sacro-sciatic* ligament, which reaches from the side of the sacrum and coccyx to the tuberosity of the ischium, has been removed in the dissection of the gluteal region; but the *small sacro-sciatic*, which remains, is much weaker, and is attached internally to the border of the sacrum and coccyx by a wide expansion which is partly united with the great sciatic: the fibres have a direction outwards and downwards to the spine of the ischium, into which they are inserted by a pointed process. The anterior or pelvic surface is covered by the coccygeus muscle, and the posterior is in contact with the great sciatic. It divides the excavation between the sacrum and os innominatum into two portions, that above it, or the great sacro-sciatic notch, gives passage to the pyriformis muscle, the gluteal vessels and nerve being above the muscle, and the sacral plexus and branches, with the sciatic and pudic vessels, below; whilst the portion below it, between it and the great sciatic, or the small sacro-sciatic notch, allows the obturator internus muscle to come from the pelvis, and the pudic vessels and nerve to pass through it.

Great. Small.

The sacrum is articulated by its base with the last lumbar vertebra, by the same ligaments that unite one vertebra to the other, and these are exposed by dissecting, in front, for the *anterior common ligament;* by opening the canal for the *posterior* and *ligamentum subflavum*, which is already done if the medulla has been dissected; the *supra-spinal* and *inter-spinal* ligaments will be found between the spinous processes, and *capsular* ligaments and *synovial membranes* are connected with the articular surfaces. A *fibro-cartilage* is also placed between the sacrum and the body of the last vertebra. The ligaments that connect this bone and the last lumbar vertebra together are so similar to those that unite one vertebra to another, that it is unnecessary to enter into a detailed description of them, since their anatomy is fully given in the dorsal and lumbar regions.

Sacrum to the last Lumbar Vertebra.

The only remaining ligament to this articulation, that differs from the rest, is the *sacro-vertebral;* it is a strong bundle of fibres, that descends from the under part of the tip of the transverse process of the last lumbar vertebra to the base of the sacrum, on which it spreads itself out, and joins with some of the fibres that pass in front of the sacro-iliac articulation.

Sacro-vertebral Ligament.

The *sacrum* joins below with the coccyx by means of a fibro-cartilage placed between the smooth articular surfaces of the bones; and by an anterior and posterior ligament: these may be exposed by removing the cellular membrane from their surface.

Sacrum to the Coccyx.

The *anterior sacro-coccygeal ligament* consists of a few fibres that lie in front of the fibro-cartilage, and are connected to the

Anterior Sacro-coccygeal.

Posterior. front of the two bones. The *posterior sacro-coccygeal*, the largest, is wide above at its attachment to the posterior part of the sacrum, at the lower margin of the orifice of the sacral canal, but it narrows as it descends to be inserted into the Fibro-cartilage posterior surface of the coccyx. The *fibro-cartilage* between the two bones resembles that between the bodies of the vertebræ in having layers, but it is less pulpy in its centre. In the female, the pieces of the coccyx are united together also by fibro-cartilages, but these are ossified in the male.

Articulation of the Lumbar Vertebræ. The lumbar vertebræ are united together by the same ligaments as the other vertebræ of the dorsal region, viz. by ligaments between the processes, which are inter-spinous and supra-spinous between the spinous processes, and the ligamentum subflavum between the plates of the vertebræ, the articular processes being united by capsular ligaments and synovial membranes; and by ligaments to connect together the bodies, and these are an anterior and posterior common ligament, and an intervening fibro-cartilage.

Dissection. The anterior common ligament is dissected by taking away the crura of the diaphragm, vessels, and cellular membrane from the front of the spine in the lumbar region; and the posterior by opening the spinal canal, and removing the medulla; but if the medulla spinalis has been dissected, this is now exposed. The ligamentum subflavum requires the plates of the vertebræ to be removed, after they are sawn through near the articulating processes; and the spinous and articular ligaments are seen by a little dissection, externally, and the removal of the surrounding muscular fibres.*

Union of the Processes. The *inter-spinous ligaments* are situated between the spinous processes, and are larger in this region than in the dorsal, because of the greater space between the processes: they represent square membranous plates, which are united above and below to the upper and under surface of the spines. The anterior border is in contact with the ligamentum subflavum, and the posterior with the *supra spinous* ligament, which is a narrow fasciculus of fibres stretching from tip to tip of the spinous processes, is thickest in the loins, and is blended on each side with the tendon of the latissimus dorsi muscle inserted into the spines.

Inter-spinous Ligaments.

Supra-spinous.

Ligamenta subflava. The *ligamenta subflava*, seen on the inner surface of the plates that are removed in opening the spinal canal, close up the spaces between the laminæ of the vertebræ, and thus assist in forming its posterior boundary. There are two portions to each space, and each, somewhat square-shaped, is attached above to the under surface of the superior lamina, but below

* These ligaments have been particularly noticed in the dorsal and in the cervical region, and they will not be minutely described here; because it is presumed that the upper extremity will be dissected before the abdomen.

to the upper border of the inferior one; in the middle line behind they approach each other, and are in contact with the inter-spinous ligament. They are wider and stronger in the lumbar than in the dorsal or cervical region, and the peculiar elastic yellow structure is better seen.

Capsular Ligament.

The *capsular ligament* consists of scattered fibres which are attached around the articular processes both above and below, and are strongest in the lumbar region. They enclose a loose *synovial membrane* which covers the articular surfaces of the bones.

Inter-transverse.

A thin fibrous membrane occupies the intervals between the transverse processes, and is named the *inter-transverse ligament*.

Union of the bodies.

Anterior common Ligament.

The *anterior common ligament* is widest in the lumbar region, though not so thick as in the back: and the superficial set of fibres, which extend for the distance of three or four vertebræ, are well seen, as also the deep, that reach from vertebra to vertebra. The connection of these fibres is firmest to the large intervening fibro-cartilages and the margins of the bodies of the vertebræ. It is thicker in the middle than at the sides. The anterior surface is in relation with the aorta and cava, and is connected by fibres to the pillars of the diaphragm. The posterior lies on the bodies of the vertebræ, and intervening cartilages.

Posterior common Ligament.

The *posterior common ligament* is a narrow band of fibres, situated in the spinal canal, which connects together the bodies of the vertebræ; opposite each intervertebral cartilage it is swollen out so as to present a wavy margin. In this part of the canal it is much narrower than in either the dorsal or cervical region, and the fibres are both superficial and deep; but they are not so coarse as in the anterior common ligament: it ends at the back of the sacrum. The surface of the ligament in the canal is in contact with much cellular membrane that separates it from the dura mater containing the medulla: the intra-vertebral veins lie along the sides as in the other parts of the canal, and it rests on the bodies of the vertebræ and the fibro-cartilages.

Inter-vertebral Fibro-Cartilage.

The *intervertebral fibro-cartilage*, placed between the flat surfaces of the bodies of the vertebræ, takes the same shape; thus, in the loins it is oval, but in the back circular. In this region it is thicker than in either of the others, and is also of a greater depth behind than before, giving the convexity forwards to this part of the spine: the reverse is the case where the spine is concave forwards. In front of them is the anterior common ligament; behind, the posterior; and above and below they are in contact with the vertebræ. Their structure is best seen in the loins, and the layers of which it is composed are readily dissected: the fibres of one layer are oblique, and cross in their direction those of the next. If one vertebra be sepa-

rated from the cartilage, the layers are seen to be less close together towards the centre, and to have the intervals occupied by a viscid fluid; whilst, in the centre, they disappear, and there is only a spongy substance filled with this semi-fluid matter. When two vertebræ and an interposed fibro-cartilage are sawn across, the middle part projects by reason of its greater elasticity.

TABLE OF THE ARTERIES OF THE ABDOMEN.

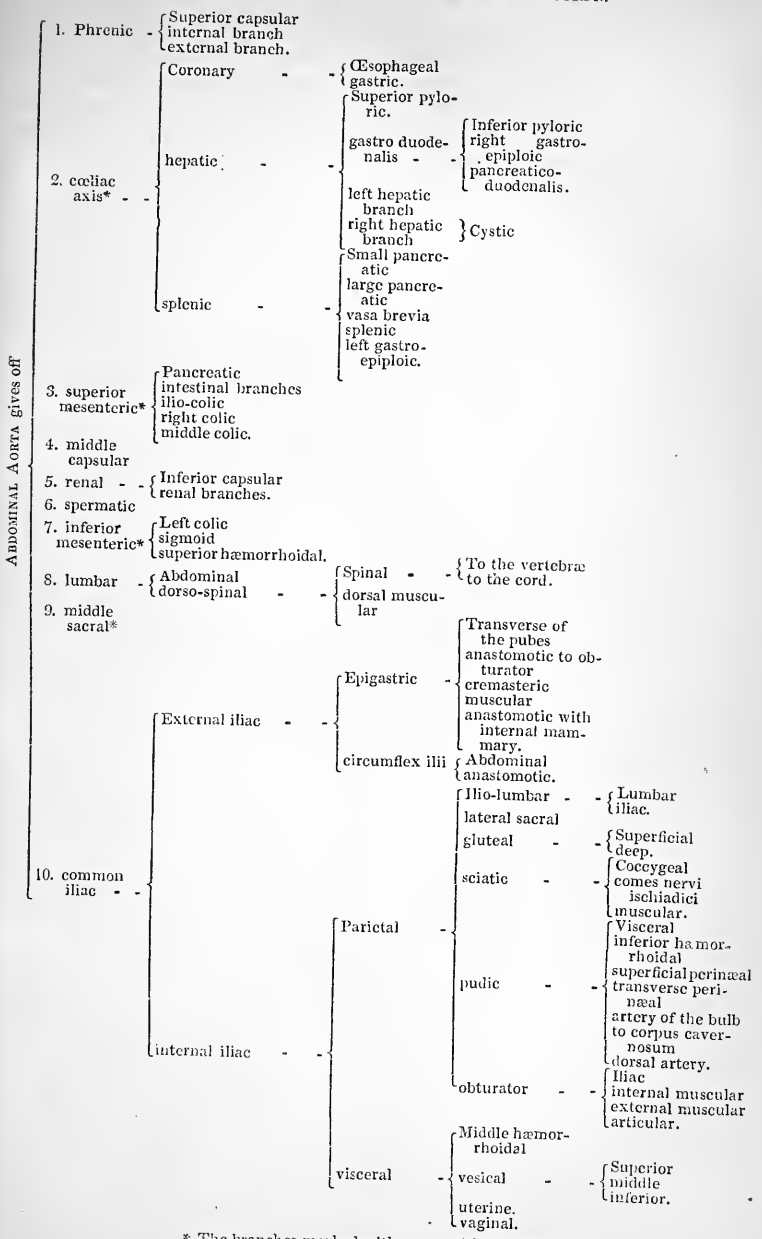

* The branches marked with an asterisk are single.

TABLE OF THE VEINS OF THE ABDOMEN.

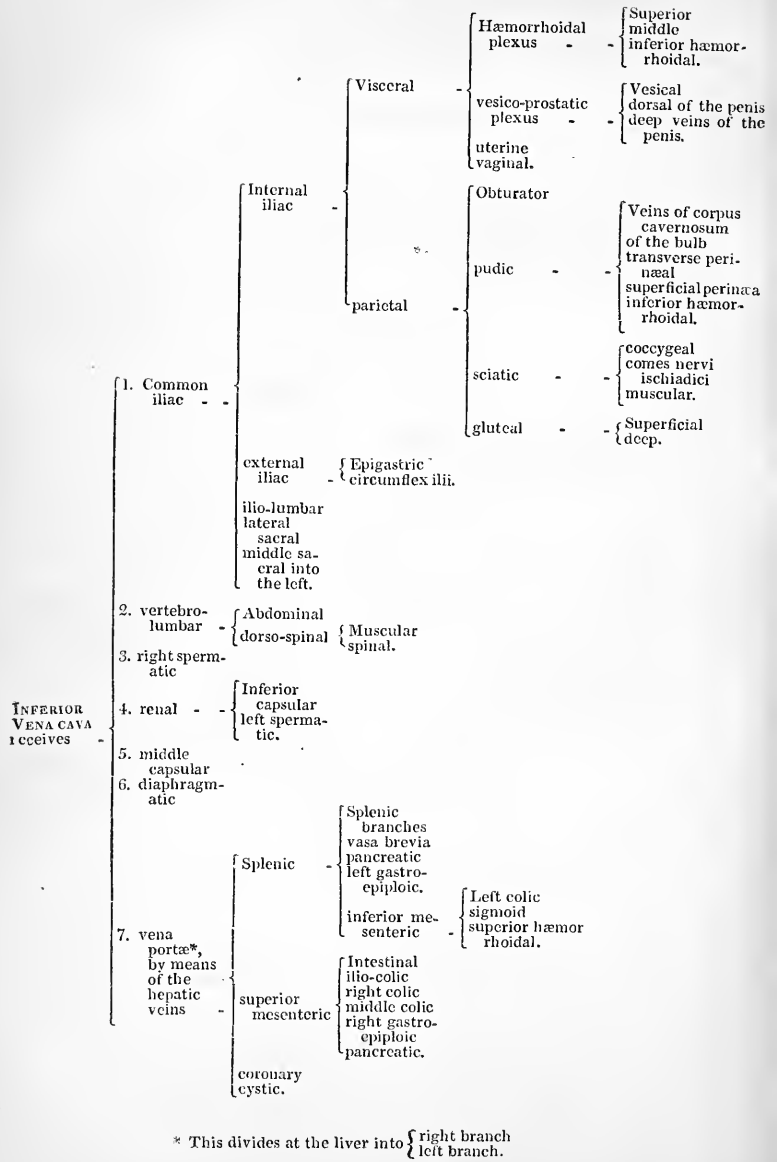

* This divides at the liver into { right branch / left branch.

TABLE OF THE SPINAL NERVES OF THE ABDOMEN.

- **Lumbar spinal nerves divide into**
  - Posterior branches
    - Internal — Muscular.
    - external — Muscular; cutaneous.
  - The anterior of the four first end in the lumbar plexus, which gives off
    - Musculo-cutaneous
      - Ilio-inguinal, or ilio hypogastric — Cutaneous of the ilium; abdominal inguinal.
      - small musculo-cutaneous.
    - external cutaneous — To integuments of the thigh.
    - genito-crural — Genital branch; crural branch.
    - anterior crural
      - Branches within the pelvis — To psoas and iliacus muscles.
      - branches without — are dissected in the thigh.
    - obturator — Accessory; muscular.
- **Sacral spinal nerves divide into**
  - Posterior branches unite together and give off
    - Muscular — filaments.
    - cutaneous — filaments.
  - The anterior of the four superior unite with the lumbo-sacral* in the sacral plexus, which gives off
    - Branches within the pelvis
      - Visceral
      - to levator ani
      - to obturator internus
      - to the pyriformis
      - pudic — Inferior hæmorrhoidal (*sometimes*); superficial perinæal, — anterior and posterior muscular; to the bulb; dorsal of the penis.
      - inferior hæmorrhoidal.
    - branches without — To the superior gemellus; to the inferior gemellus; to the quadratus; small sciatic; great sciatic — are dissected in the thigh.

* The lumbo-sacral gives off the superior gluteal nerve.

PNEUMO-GASTRIC NERVE IN THE ABDOMEN.

- Pneumo-gastric
  - Right
    - Coronary branches to the back of the stomach
    - filaments to join the solar plexus.
  - left
    - Coronary branches to the front of the stomach.

TABLE OF THE SYMPATHETIC NERVES OF THE ABDOMEN.

Solar plexus*, or prevertebral centre of the abdomen, gives off the following plexuses:

- Diaphragmatic
- cœliac
  - Coronary
  - hepatic
    - Right gastro-epiploic
    - cystic.
  - splenic
    - Left gastro-epiploic
    - pancreatic.
- superior mesenteric
- supra-renal
- renal
  - Some filaments to the spermatic plexus
  - some from the small splanchnic nerve.
- lumbo-aortic
  - Branches from the lumbar ganglia
  - right inferior portion to the hypogastric
  - left inferior to hypogastric.
- spermatic
- inferior mesenteric — Superior hæmorrhoidal.

Hypogastric plexus†, or prevertebral centre of the pelvis, gives off the following plexuses:

- Inferior hæmorrhoidal
- vesical
  - Prostatic
  - deferential
  - to vesiculæ seminales.
- uterine
- vaginal.

Gangliated cord of the sympathetic in the abdomen gives off

- External branches — To the lumbar and sacral spinal nerves.
- internal
  - To lumbo-aortic plexus
  - to hypogastric plexus in the pelvis
  - to the rectum
  - to join around middle sacral artery.
- communicating
  - Between the ganglia
  - between the cords on the coccyx, where is often the *ganglion impar*.

* This receives from
- Great splanchnic nerve
- part of small splanchnic
- from pneumo-gastric.

† This is joined above by
- Right and left portions of the lumbo-aortic plexus
- filaments from the lumbar ganglia.

TABLE OF THE ACTIONS OF THE MUSCLES.

THE TRUNK IS MOVED

forwards by	*backwards by*	*laterally by*	*rotated by*
Obliqui externi abdominis	Erectores spinæ	Obliquus externus abdominis	Obliquus externus of one side; and
Obliqui interni abdominis	Latissimi dorsi	Obliquus internus	Obliquus internus of the opposite.
Recti abdominis	Multifidi spinæ.	Transversalis	
Transversales		Rectus	
Pyramidales		Quadratus lumborum	
Psoæ; the pelvis being fixed.		Erector spinæ	
		Serratus posticus inferior	
		Inter-transversales.	

THE CAVITY OF THE ABDOMEN

is diminished by	*enlarged by*
Contraction of the abdominal muscles, particularly the transversales and recti by the descent of the diaphragm and contraction of the levator ani.	Relaxation of the abdominal muscles, and ascent of the diaphragm.

THE ANUS

is protruded by	*retracted and contracted by*
Relaxation of the levator ani and descent of the diaphragm.	Levatores ani Sphinctores ani.

URETHRAL CANAL

contracted by

- Ejaculator urinæ
- Compressor urethræ.

CANAL OF VAGINA

diminished by

- Constrictor vaginæ.

Cremasterici	draw upwards the testes.
Erectores penis vel clitoridis	compress and draw downwards the penis or clitoris.
Transversales perinæi	to fix the central point of the perinæum.

DISSECTION OF THE LOWER EXTREMITY.

Prominences or marking of the surface.

In the lower extremity there are certain prominences, or depressions corresponding to the intervals of muscles, which it is necessary to notice whilst the limb is untouched by the scalpel, for they serve as marks by which the situation of vessels may be certainly pointed out, or the abnormal position of the ends of the bones entering into an articulation more easily detected. After the skin and integument are removed, the facts alluded to can be more distinctly seen; but in taking away the cellular membrane and fasciæ the muscles should not be displaced from their natural positions until the true relation of the parts has been verified. When the limb is slightly rotated outwards, as the subject lies on the table, the upper part is separated from the region of the abdomen by Poupart's ligament, which is felt beneath the skin, as a round cord, intervening between the crest of the ilium and spine of the pubes; from the pubes, a line of bone can be traced downwards to the tuberosity of the ischium, and the prominence of the iliac crest terminates at the sacrum. Immediately below Poupart's ligament is the depression marking the femoro-inguinal region of the thigh, into which the complete femoral hernia protrudes, and through the centre of which pass the femoral vessels; its limit above is the ligament before named; the prominence on the outer side consists of the sartorius muscle, and that on the inner of the adductor longus; these approach below in the apex of the depression. Extending from the region along the inner part of the thigh, is a slight groove marking the position of the femoral artery, where it is covered by the sartorius muscle; this is lost in the lower third of the thigh. A line drawn from the centre of Poupart's ligament to the inner side of the patella at the knee-joint, would mark the situation of the vessel in the two upper thirds of the thigh. The outer surface of the thigh is convex from the large muscles beneath, but at the upper part, and about four inches below and behind the anterior termination of the crest of the ilium, is the large trochanter major of the femur, a process of bone of much value in determining, by the deviation from its natural position, fracture of the neck of the femur, or dislocations of the head of this bone from its articular cavity. The head of the femur may be recognised by placing the thumb in the hollow in front, and the fingers behind the trochanter, the limb being rotated inwards and outwards at the same time. In front of the knee-joint is the prominence of the patella, wide above and pointed below, which is best perceived dy slightly flexing the leg; but if the leg is ex-

tended this bone is very moveable on the condyles of the femur. On each side of the patella is the condyle of the femur: the internal being the most marked, and separated from the patella by a greater interval than is found between this bone and the outer. If the leg be semi-flexed, and the fingers passed along the sides of the patella, the outline of the condyles which articulate with the head of the tibia will be readily felt; and below them the head of the tibia, which is separated from the femur by a slight interval, and presents an internal and an external projection — the tuberosities of this bone. In the centre of the tibia, close below the articulation, is the tubercle receiving the insertion of the ligament of the patella, and terminating, above, the anterior spine or crest of the bone; and below its outer tuberosity is the head of the fibula. The depression behind the knee-joint corresponds to the popliteal space; on the outer side may be felt the tendon of the biceps, and on the inner, those of the adductor magnus and hamstrings. In the leg, the inner surface of the tibia is subcutaneous, and limited internally and externally by a sharp crest, the posterior tibial artery being about one inch behind the internal; and the anterior tibial, which, above, is midway between the tibia and fibula, is, below, close to the outer margin. The tibia ends inferiorly on the inner side of the ankle, in the large internal malleolus; and the fibula, which becomes cutaneous in the lower fourth of the leg, forms the outer projection of the external malleolus. In the centre of the posterior part of the leg is the strong tendo Achillis of the muscles of the calf, descending to the heel or os calcis. When the foot is extended, the head of the astragalus appears below the ankle-joint; and opposite this, on the inner side of the foot, is the projection of the scaphoid bone — the guide to Chopart's operation. At the tarsal extremity of the metatarsal bone of the great toe is felt the small tubercle which is the guide, on the inner side of the foot, to Lisfranc's operation, the large tarsal extremity of the metatarsal bone of the little toe being the other mark on the outer side. A line on the front of the foot, from the centre of the ankle-joint to the interval between the first and second toes, points out the course of the dorsal part of the anterior tibial artery.

Dissection. The subject lying on the back, place a block of moderate thickness beneath the buttocks to make tense the upper region of the thigh, rotate the limb outwards so as to bring forwards the hollow beneath Poupart's ligament, and let the leg hang over the side or end of the table, in which position it may be supported by resting on a stool. Commence the dissection by an incision *, about six inches in length, from the crest of the ilium along the outer border of the anterior surface of the thigh, and make another, of nearly the same extent, from the spine of the pubes, along the inner; connect the two below, and raise the

* This is to divide only the skin.

portion of integument included between them as high as to the line separating the thigh from the abdomen, or to Poupart's ligament. Beneath the skin is seen the subcutaneous cellular membrane, which is separated into two layers by the presence of the cutaneous vessels and inguinal glands of the thigh, and should be studied with attention from its relation to femoral hernia. To raise the layer of the fascia situated superficially to the vessels, make the same incisions through it as in the skin, but they are not to be extended so far down the thigh; its reflection may be begun below, over the saphenous vein, where it is least firmly united to the subjacent fascia, and the handle of the scalpel may be advantageously used in doing this. Its thickness varies in different subjects, but the separation from the other layer beneath the vessels is marked by the cutaneous veins of the thigh, and by a condensed membranous appearance of the under surface; near Poupart's ligament it contains little adipose substance, and is much more closely united to the deep fascia on the outer, than on the inner part of the limb. Take away next, with care, the loose cellular membrane which surrounds the inguinal glands and cutaneous vessels, and seek the femoral portion of the genito-crural nerve. The superficial vessels between the two layers of the fascia are the first branches of the femoral artery, which perforate the fascia lata, and are distributed to the integuments. Descending from the abdomen to the thigh, is a very thin condensed layer of fascia, easily moved on the structures beneath, which is placed beneath the vessels and glands, and is perforated by the vessels and lymphatic ducts; follow back some of the ducts to show them passing through apertures in it below Poupart's ligament, and rather to the pubic side of the centre of the thigh.

Superficial Fascia.

The *superficial fascia*, which gives a general investment to the extremity, is divided in the upper part of the thigh into two layers, by the interposition of cutaneous vessels and glands. The superficial layer is immediately beneath the skin, covers the vessels and glands, and consists of the subcutaneous cellular membrane, in which is deposited the adipose tissue, whose varying quantity determines the different degrees of its depth. It is continued downwards on the thigh, and close below Poupart's ligament it is thinner, more fibrous, and contains less fat; inwards to the scrotum, or labium; and upwards to the abdomen, —being unconnected to Poupart's ligament, on which it readily moves, and from which it is separated by the cutaneous vessels distributed to the lower part of the abdomen. The deeper of the two layers is examined after the vessels.

External Pudic Artery.

The *external pudic arteries* are two in number, a superior and inferior: the superior, after perforating the fasciæ, is directed upwards and inwards to the cord, which it crosses, and ends in the integuments of the penis and scrotum, anastomosing with

the pudic and superficial perinæal arteries: in the female it is smaller, passes to the labium, and inosculates with the same arteries. The inferior is deeper, and runs beneath the fascia lata to the inner border of the thigh, where it becomes cutaneous, and is distributed to the lower part of the scrotum and perinæum: this last branch cannot now be seen, but it arises sometimes by a common trunk with the superior, and at others, by a separate branch from the femoral.

Vein. The *external pudic vein* commences in the penis and scrotum, accompanies the superior artery, and joins the saphena vein.

Superficial Epigastric Artery. The *superficial epigastric artery*, larger than the preceding, but often forming a common trunk with the superior pudic, occupies the centre of the surface now exposed, passes upwards over Poupart's ligament to the lower part of the abdomen, and between the layers of the superficial fascia, anastomosing in the integuments with branches from the deep epigastric artery.

Vein. The *superficial epigastric vein* has the same anatomy and distribution as the artery, and joins the saphena.

Circumflex Ilii Artery. The external or *superficial circumflex artery* of the ilium, the smallest and most external of the branches seen in this dissection, appears external to the others, runs outwards to the spine of the ilium, and anastomoses with cutaneous branches of the deep circumflex artery. Very commonly, the artery appears only at the outer margin of the thigh, and close to the anterior superior spinous process of the ilium.

Vein. The *superficial circumflex ilii vein* is very small, accompanies the artery of the same name, and opens into the saphena.

Saphena Vein. The *internal saphena vein*, now partly exposed, ascends from the leg and foot to the femoro-inguinal region, passes through the fascia lata, and joins the femoral vein; but, before it unites with it, it receives the small cutaneous veins of this situation, which correspond to the small arteries, and also many other branches from the surface of the thigh.

Inguinal Glands. The *superficial inguinal glands*, situate between the layers of the fascia, vary greatly in number and size. They are commonly arranged in two rows: one is placed parallel to Poupart's ligament, and the other, consisting of larger glands, and of a greater number than the former, is situated on each side of the saphena vein; connecting one to the other are small intervening lymphatic vessels, though frequently they are joined by a continuity of substance. They are conglobate glands, and the lower set receive the lymphatics of the lower extremity, which, as they enter the lower part, are named vasa inferentia, but as they escape, vasa efferentia, and these last join the deep inguinal glands beneath the fascia. The glands placed on a level with the ligament are joined by the lymphatics of the penis, lower part of the abdomen, and the gluteal region.

Dissection. To examine the thin deep layer beneath the vessels and glands,

and continuous with that of the abdomen, detach it very carefully from the fascia lata beneath, around the point of entrance of the saphena vein, by means of a transverse incision near Poupart's ligament, (this is to divide also the small vessels,) another below the termination of the vein, and a third external to it. The handle of the knife is to be used to separate it from the fascia lata as far as to the saphenous opening, to show its continuity over it, and its attachment to the margins; this will be most certainly done by beginning below, where the aperture is most distinct; and, if it should be necessary, the saphena vein may be cut across. On the outer side it is most closely united to the fascia lata, and at the outer border of the aperture some fibrous bands unite them. If this detached portion of fascia is held up, the apertures in it for the passage of the cutaneous and lymphatic vessels are evident.

Deep layer of the Fascia.

The *deep layer* of the superficial fascia is a thin membranous lamina, scarcely apparent in fat subjects, placed beneath the vessels and glands. It is continued upwards on the tendon of the external oblique muscle of the abdomen, and as it passes over Poupart's ligament is connected to it by a cellular structure, which serves as a partition between the thigh and abdomen, and prevents effused fluid passing from one region to the other.* In the thigh it is closely applied to the fascia lata, though easily separated from it, near Poupart's ligament, on the inner side and lower part of the saphenous opening, but on the outer side the two are inseparably united. About one inch and a half below Poupart's ligament it covers the saphenous opening, and is connected to its margins, the union being more intimate on the outer than on the inner side, so that it is necessary to detach the fibrous bands joining the two, to render this border distinct. The portion that closes the saphenous aperture is joined to the inner side of the femoral sheath which appears through the opening, and is named *cribriform fascia*, in consequence of its being so perforated with apertures for the ducts of the glands, and some of the superficial vessels, as to resemble a sieve. When a femoral hernia occurs, it carries before it, as a covering, the cribriform fascia that is placed over the aperture by which it escapes on the thigh.

Cribriform Fascia.

Dissection.

Clean away the superficial fascia from the fascia lata as low as the incision in the integument, avoiding the cutaneous nerves and vessels that perforate it: separate entirely the cribriform fascia from the margins of the saphenous opening, tracing the outer border from the inner side, and it may be necessary to divide the connection of the two on the outer side. Sometimes

* It would facilitate the understanding of this fascia, with reference to hernia, if the lower part of the abdomen and upper portion of the thigh could be dissected at the same time.

one of the superficial arteries perforates the margin of the aperture, and destroys its regularity.

Saphenous opening.

The oval aperture in the fascia lata, now exposed, is the *saphenous opening*, which allows the saphena vein to reach the femoral, and the ducts of the superficial inguinal to join the deep glands. It is situated in the upper part of the thigh, below Poupart's ligament, and to the pubic side of its centre; its greatest measurement is in the vertical direction, the transverse being less by three or four lines. The outer side, semilunar, and directed downwards and inwards, is distant from the muscles, is on a plane anterior to the inner, and lies in front of the femoral vessels, which may be felt through it; the inner is flat, lies close to the muscles, and behind the femoral vessels. Its upper extremity is near the inner attachment of Poupart's ligament; and the lower, limited by a firm band of fascia, is placed about one inch and a half below the ligament, but subject to vary according to the height at which the vein perforates the fascia, and its concavity is directed upwards, and crossed by the saphena vein. Through this opening a femoral hernia escapes from its canal to appear as a tumour under the integument, and in consequence of the relation of the borders to the neck of the protrusion much attention is given to its form and mode of production. It is formed by the fascia lata dividing at the lower angle into two portions, which ascend, diverging, to be attached to separate points, and are so arranged as to form a valvular aperture, the outer or anterior portion being named iliac, and the inner or posterior, the pubic. The

Iliac portion of Fascia.

iliac portion of the fascia, so called from its attachment to the os ilii, is continuous below and behind with that covering the rest of the thigh, and is fixed above to the crest of the ilium, and to Poupart's ligament in its whole length; its extent inwards is to the saphenous opening, whose outer boundary it forms by a semilunar border, which, from its resemblance to a "*falx*," is named the *falciform border* or *process* of Burns. This

Falciform process.

process, bounding externally the saphenous opening, has its concavity directed downwards and inwards; one extremity, or the inferior *cornu*, ends by joining, at the lower angle, with the pubic portion on the inner side; and the other, or superior *cornu*, lying in front of the femoral vessels, turns beneath Poupart's ligament to join the base of Gimbernat's ligament, and to be inserted into the pectineal line external to it. About the upper fourth of the process, or the small triangular portion, which is placed internal to the femoral vessels, and joins Gim-

Hey's ligament.

bernat's ligament, is named Hey's or the *femoral ligament*. From the margin of the border, fibres pass to join the cribriform fascia, as well as the sheath of the vessels, and below, they sometimes form a distinct layer reflected downwards and back-

Pubic portion.

wards to the sheath. The *pubic portion* ascends on the pecti-

neus and adductor muscles, separating from the iliac, to be attached to the pectineal line of the pubes; it is continuous internally with the fascia lata of the thigh, and is attached to the rami of the pubes and ischium; where it forms the inner side of the opening it is flat, but at its junction below with the iliac, it is raised into a prominent fold. If it is followed externally, it may be traced behind the vessels and their sheath to the margin of the psoas muscle, and it joins with the iliac fascia covering this muscle. This portion of the fascia forms the posterior boundary of a space, the iliac forming the anterior, in which the femoral vessels are contained after passing from beneath Poupart's ligament, enveloped nevertheless by a proper sheath observable through the saphenous opening. The size and tension of the saphenous opening, and the constriction of a hernia that escapes through it, are greatly dependent upon the condition of the outer margin, which varies with the position of the limb; for if the thigh is bent upon the body the falciform border is relaxed, and if the limb be rotated inwards at the same time it will be much less tense. The finger should be introduced beneath the falciform border during the different states of flexion and extension, and of rotation inwards and outwards, to appreciate fully the influence of the position of the limb upon the rigidity of the aperture. The hernia, as it passes through it, receives as a covering the cribriform fascia, and lies beneath the upper part of the falciform process or femoral ligament which constricts it; and should the tumour increase in size, it turns upwards over Poupart's ligament in the angle of flexion of the thigh and trunk, where the cellular membrane and integument are loose and favour its extension.

Dissection.

To examine the reflection from the outer and lower margins of the saphenous opening, and also the sheath of the femoral vessels between the pubic and iliac portions of the fascia lata, make an incision into the fascia, parallel to Poupart's ligament, from the margin of the falciform process nearly to the border of the sartorius muscle; divide it also along the inner border of the sartorius to a little below the inferior aperture of the opening, and raising this portion of fascia throw it downwards, when the prolongation from the margin, either as separate bands, or as a distinct membrane, is perceived. By removing with the handle of the scalpel the cellular membrane that now appears, a thin membranous tube — the femoral sheath — is observed to surround the vessels as they enter the extremity, and if this is seized with the forceps, it is found to come from beneath Poupart's ligament, and to be attached to it by a union which is very slight, and easily detached with the handle of the knife. Separate carefully the sheath from the surrounding parts; but before examining it, proceed with the anatomy of Poupart's ligament in front of it, and Gimbernat's on the inner side, in

order that the parts concerned in femoral hernia may be more readily understood.

Poupart's ligament.

In front of the femoral sheath and vessels, is the firm tendinous cord of *Poupart's ligament*, or the lower border of the aponeurosis of the external oblique muscle, which is attached externally to the anterior superior spinous process of the ilium, and internally to the pubes; its direction is not straight between these points, but convex downwards, and it is retained in this position by the close attachment of the fascia lata to it. The outer half, oblique downwards and inwards, is closely applied to the muscles beneath; the inner, more horizontal in direction, is situated over the femoral sheath, is less cord-like, and is inserted into the pubes by two processes;—the superior, firm and round, is attached to the spine of this bone; but the inferior, best seen when Poupart's ligament, which hangs in front of it, is raised, is thin and membranous, is connected to the pectineal line, external to the other, for three fourths of inch or an inch, and is named Gimbernat's ligament. Near the point where the ligament is held down by the fascia, some of the lower fibres separate from the rest, and run inwards to the pubes below them, but in front of the femoral sheath to which the band is united, to be inserted into the pectineal line, in contact with the deep surface of Gimbernat's ligament; this is called the deep arch, and it has been supposed to cause the stricture of a femoral hernia. When Poupart's ligament is in its natural position, *Gimbernat's ligament* is seen to be a triangularly shaped process placed between its posterior border and the pectineal line of the pubes. It measures about one inch in length; the apex is at the spine of the pubes, and the base, concave, looks to the sheath of the vessels, is joined by the upper cornu of the falciform process, or the femoral ligament, and, at its attachment to the bone, is prolonged outwards, and is united to the pubic portion of the fascia lata. By the union of the ligament with the falciform process it is kept tense and inclined downwards, and the space between it and the vessels is diminished, by which the chances of a hernia are lessened; but should it exist, this band will be very instrumental in occasioning strangulation. In the erect position of the body the ligament is horizontal, the anterior border joining Poupart's ligament, and the posterior, the pectineal line of the pubes; the upper surface is in contact with the conjoined tendon and fascia transversalis, and the lower looks to the thigh, and is covered by the intercolumnar fibres and the deep layer of the superficial fascia. When Poupart's ligament is spoken of with reference to femoral hernia it is named the *femoral* or *crural arch*, and it, with the irregular border of the os innominatum between the anterior superior spinous process and the insertion of Gimbernat's ligament, bounds a space which gives passage to the vessels and

Gimbernat's.

Crural Arch.

parts passing from the abdomen to the thigh: this interval is larger in the female than in the male. The outer half is filled up by the fleshy iliacus and psoas muscles, and the ligament is united so closely to the muscles by the attachment of the fascia lata and fascia iliaca, that no protrusion of the contents of the abdomen will take place in this part; but the inner is appropriated to the passage of the femoral vessels, surrounded by their tube of membrane, and as all the sheath is not occupied by the vessels, a hernia may descend in it with them.

Femoral sheath.

The *femoral sheath*, whose anatomy may be resumed, is a thin membranous prolongation of fascia which contains the vessels, continuing on them to about two inches below Poupart's ligament, or to the junction of the saphena vein with the femoral, and ends by joining the common sheath. It is large and dilated above, extending from the psoas muscle externally to Gimbernat's ligament on the inner side, but is closely united, below, to the vessels, so as to resemble a funnel. It is derived from the fasciæ lining the inner surface of the wall of the abdomen, which send a funnel-shaped prolongation around the femoral vessels, similar to that from the fascia transversalis, around the cord; the anterior portion, descending from beneath Poupart's ligament and the transversalis muscle, is continuous with the fascia transversalis, and the posterior joins, above, the fascia iliaca; these are united internally and externally to form the tube. The outer border is nearly straight, and covered with cellular membrane; but the inner is oblique downwards and outwards, extending from the base of Gimbernat's ligament to the entrance of the saphena vein into the femoral, is joined at the saphenous opening by the cribriform fascia, and is perforated by numerous ducts of the inguinal glands, and by the saphena vein. The anterior part is covered by the iliac portion of the fascia lata, is also perforated by ducts from the glands, by small vessels, and by the femoral portion of the genito-crural nerve; and the posterior lies on the pubic portion of the fascia lata which passes behind it.

Dissection.

Open now the sheath by an incision across its front, parallel to Poupart's ligament, and raise the anterior part with hooks; remove carefully from the contained artery and vein their cellular investments, so as to leave untouched two thin partitions passing from the front to the back of the sheath, one being found internal to the vein, separating it from a lymphatic gland, and the other between the vein and artery. The cellular layer of the septum crurale, stretched across the upper aperture, is not to be taken away.

Interior.

The *interior of the sheath* is divided into three compartments by the two thin partitions passing from the front to the back, and in it are contained the femoral artery, vein, and a lymphatic gland: the artery is most external and close to the vertical side

of the sheath; the vein is internal to it, separated from it by one of the septa, and from the inguinal gland by the other, and each vessel is enclosed in its own cellular investment; the lymphatic gland is internal to the vein, and occupies the crural canal, or the space not filled up by the vessels. Immediately below Poupart's ligament the front of the sheath is less closely united to the parts within, than it is lower in the thigh.

Crural Canal. The space within the sheath, internal to the femoral vein, is named the *crural canal*, in consequence of a hernia traversing it in its passage from the abdomen to the thigh; and it results both from the sheath being larger than the contained vessels, and from the obliquity of the inner side. Its extent is from the free border or base of Gimbernat's ligament to the upper angle of the saphenous opening; it is larger above than below, and is only partially filled by a lymphatic gland; its upper aperture is called the crural ring, to maintain a similarity of nomenclature with that employed in inguinal hernia, for the aperture by which an inguinal hernia enters its canal is the abdominal ring. In front of it are the anterior part of the sheath, Poupart's ligament, and the upper cornu of the falciform process ascending to join Gimbernat's ligament; behind, are the posterior part of the sheath, and the pubic portion of the fascia lata on the pectineus muscle. On the outer side are the femoral vein and the septum; and on the inner, the sheath, with the cribriform fascia stretched over the saphenous opening.

Crural Ring. The *crural* or *femoral ring*, or the aperture of entrance to the crural canal, is of an oval figure, about half an inch in length, but larger in women than in men, and is on a level with the free border or base of Gimbernat's ligament; and its boundaries are, internally, the base of Gimbernat's ligament covered by the sheath of the vessels, and externally, the femoral vein. In front are the lower fibres of Poupart's ligament or the deep arch, the spermatic cord in the male, with a small artery from the epigastric which runs to the back of the pubes, and directed upwards along the superior and outer part is the epigastric, artery; but when the obturator artery arises from the epigastric and passes inwards to reach the obturator foramen, it may run on the outer or inner side*: in the latter case the ring will be entirely surrounded, except below, by vessels. Behind is the pubes, covered by the pubic portion of the fascia lata, together with the posterior part of the sheath of the vessels.

Septum Crurale. The *septum crurale* is a cellular layer extending across the upper opening of the crural canal, and serving, when dense, as a barrier to the protrusion of a hernia through this part, or if a

* The position and relations of these vessels to the crural ring are seen only on the inner side, in the dissection of the abdomen, see p. 500.

hernia is formed, it gives a covering to it. It varies in thickness in different subjects, is convex downwards, is perforated with apertures for the passage of the inguinal lymphatic ducts, and oftentimes a lymphatic gland is placed in one of these.

Femoral Hernia.

When a portion of intestine passes from the abdomen below Poupart's ligament, so as to appear in the femoro-inguinal region of the thigh, it is named *femoral hernia;* but, from the disposition of the parts that fill the space beneath the ligament, it is obvious that it will descend in the femoral sheath, and, from the previous examination of this part, it has been seen that the least impediment to its descent is on the inner side of the vein, or through the crural canal, in which a lymphatic gland is placed. Some herniæ have been occasionally found on the outer side of the vessels, between them and the crest of the ilium. The course that it follows depends upon the greater or less resistance of the structures by which it is surrounded, its direction being always determined to the part where this is least. A hernia, entering the crural ring, descends, at first, almost vertically in the crural canal, as far as to the saphenous opening, is separated from the vein by the inner septum, and is confined in its situation by the strong iliac portion of the fascia lata in front of it; at the aperture in the fascia lata it is released from its compression, changes its direction, comes forwards to the surface, and increases in size; as the tumour enlarges, it turns upwards between the layers of superficial fascia, and ascends on the falciform portion of the fascia lata, or even on to the tendon of the external oblique; for it is prevented from extending downwards by the increasing narrowness of the crural canal, by the connection of the superficial fascia to the fascia lata, which is closer below than above the saphenous opening, and by the obstruction that the small cutaneous vessels present. If the intestine follows the course above stated, and is free from its canal, it is called perfect; but if it has not escaped through the inferior aperture or saphenous opening, incomplete, and the different coverings will vary according to its position. In a complete hernia, the following are the coverings: — first, the peritonæum, which, lining the abdomen, is pushed before it, and serves as an enveloping sac; next, the septum crurale which is extended before the tumour, and then the inner side of the sheath; these two last are distinct only in small recent herniæ, for in large and old ones they are united together, and form the fascia propria of Sir A. Cooper; the next structure that the hernia carries before it is the cribriform fascia; and, after passing through the saphenous opening, it is covered by the superficial fascia and the skin. These different layers are found in an inverse order, when they are divided from without inwards; and those of the septum crurale, sheath of the vessels, and cribriform fascia, become more or less united together. The seat of

stricture may be either in the peritonæum at the neck of the sac, at the deep arch below Poupart's ligament, or at the sharp margin of the femoral ligament; and an incision, of a few lines in extent, directed upwards and inwards, is not more likely to injure the spermatic cord, or a vessel, than one in any other direction, and is more effectual in removing the firm constricting band of the femoral ligament when this is the seat of stricture.

Dissection. Slit down now the sheath to examine more fully the septa by the sides of the vessels, separate it from the pubic part of the fascia lata, which lies behind it, and carry the handle of the scalpel behind, to show the continuity of this part of the fascia lata with the iliac fascia. If the dissection should be undertaken only for the anatomy of the hernia, the vessels and sheath may be divided about two inches below Poupart's ligament, and then turned upwards; by which the union of the fasciæ, and the fibrous processes connecting posteriorly the sheath of the vessels to it, will be better seen.

Pubic part of the Fascia lata. The *pubic portion* of the fascia lata may now be followed outwards behind the femoral sheath to the inner border of the psoas muscle; it joins in this spot with the iliac fascia covering the psoas, and sends also a portion to the capsule of the hip-joint.

Iliac Fascia. The iliac fascia, covering the conjoined psoas and iliacus muscles, descends beneath Poupart's ligament, and is united in the thigh with the fascia lata, which sends processes inwards to it, particularly at the edge of the sartorius. At the inner border of the muscle it joins the pubic part of the fascia lata, and from it some fibrous processes pass to the back of the femoral sheath.

Dissection. From the transverse incision already made, carry another along the centre of the thigh, over the knee-joint, to a little below the tuberosity of the tibia; and, at its extremity, divide the skin transversely, to allow of its being raised in two flaps from the whole anterior part of the thigh. Dissect out of the fat the saphena vein along the inner side of the thigh, but carefully avoid the numerous nerves* that are found in relation with it: thus in the upper third are some small nerves, perforating the fascia, from the branch of the anterior crural distributed to the femoral vessels, and one or two cutaneous filaments of the internal cutaneous; in the middle third, a still larger branch from the internal cutaneous, one from the obturator, and some cutaneous filaments from the plexus formed by the accessory to the saphenus, and the obturator; in the lower third are some filaments from the obturator, which lies beneath the fascia, and perforates it near the knee, or a little below it, the internal cutaneous, which also passes through the fascia, and joins the

* The distribution of these, and even the point of perforating the fascia, vary so much that the dissector will be oftentimes unable to find the number here enumerated.

saphenus and obturator, some filaments sometimes from the accessory of the saphenus, and below the knee are the superior and inferior branches of the saphenus: all the branches, except those from the obturator, come from the anterior crural. On the front of the thigh is the middle cutaneous of the crural; and on the outer side the external cutaneous of the lumbar plexus.

Saphena Vein.

The large or *internal saphena vein*, appearing at the lower part of the dissection, is internal and posterior to the knee-joint, and superficial to the tendons of the muscles which turn forwards to be attached to the tibia, — viz. the sartorius, gracilis, and semi-tendinosus; above this it passes forwards to the anterior part of the thigh, being placed in the hollow observable on its inner part, and over the position of the sartorius muscle and femoral artery, and about one inch and a half below Poupart's ligament it passes through the saphenous opening, as seen, and joins the femoral vein. A little below the knee-joint it is in contact with the great saphenus nerve, in the middle of the thigh with a cutaneous nerve from the internal cutaneous, and above this with one or more filaments from the anterior crural.

Branches.

In this course it receives cutaneous veins from the outer part and front of the thigh, as well as from the inner surface; but the veins from the posterior and inner parts of the thigh generally unite together in a trunk, which ascends along the inner side, and opens into the saphena vein, near its entrance into the femoral. Sometimes, a separate trunk comes also from the outer side. Before perforating the fascia, the vein is joined by the veins that accompany the small arteries to the lower part of the abdomen, and the genital organs, — viz. the superficial pudic, epigastric, and circumflex. It sometimes joins with the deep veins, and near the knee receives an articular branch.

Cutaneous Nerves.

Anterior external.

The *external cutaneous nerve* of the lumbar plexus is the chief nerve for the supply of the integuments of the outer part of the thigh. It leaves the abdomen beneath Poupart's ligament, passing in the interval between the anterior superior and inferior spinous processes of the ilium. At first beneath the fascia lata, it soon divides into a posterior and an anterior cutaneous branch: the *posterior cutaneous*, given from the nerve as soon as it has entered the thigh, and whilst covered by the fascia, turns backwards over the tensor vaginæ muscle, perforates the fascia, and is distributed to the integuments over the gluteus medius muscle; when the trunk of the nerve is a branch from the anterior crural, the nerve analogous to this branch is supplied by the genito-crural, which is directed outwards, or by the lumbar cutaneous nerves which cross the crest of the ilium. The *anterior cutaneous branch*, or continuation of the nerve, lying in the prominent fold of fascia of the upper and outer part of the thigh, becomes cutaneous about four inches below the crest of the

ilium, and, descending along the outer side of the thigh, divides into two portions: the superior turns backwards, supplying the integuments of the outer and posterior parts, and terminates about the lower third of the thigh; the other reaches to the knee-joint, and is distributed in the lower and outer part of the thigh, and over the articulation and patella.

Anterior middle. The *middle cutaneous nerve* is a considerable branch from the anterior crural. Its point of perforating the fascia varies, it being sometimes as high as two inches below Poupart's ligament, and at others five from it. The nerve descends along the front of the thigh, giving filaments to the integuments as far as the knee, and joins in front of the patella with the cutaneous branches of the great saphenus nerve, which are distributed in front of the knee-joint. One or two other cutaneous nerves from the same source are frequently found with this on the front of the thigh; they are lost in the integuments, and do not extend so low down. Another small nerve perforates the fascia near the saphenous opening, and accompanies the upper part of the saphena vein.

Crural branch of the Genito-crural. The *crural* or *femoral branch* of the genito-crural nerve of the lumbar plexus is commonly a very small branch, which leaves the trunk of the nerve whilst it lies on the external iliac artery; it then descends beneath Poupart's ligament, crosses the external iliac artery, perforates the sheath of the femoral vessels, and the fascia lata, and ends in the integuments of the femoro-inguinal region. When this nerve is very small, its place is supplied by a cutaneous branch from the external cutaneous, which is external to the proper femoral branch, joins with a nerve from the anterior crural, and the trunk resulting from the two may be traced to the middle of the thigh. Occasionally, this nerve is directed outwards over the gluteal region to be distributed as the posterior branch of the external cutaneous.

Anterior internal. The *internal cutaneous nerve*, derived from the anterior crural, gives off through the fascia in the upper third of the thigh one or two small cutaneous filaments, and about the middle, a larger branch which passes with the saphena vein nearly to the knee; but the trunk of the nerve does not appear on the surface of the fascia till it reaches the lower third, it then descends to the knee, dividing into many filaments which are distributed to the integuments of the inner and lower part of the thigh, some turning forwards in front of the patella, and joining with the cutaneous branches of the saphenus to the same part. Near the knee it unites with the superior branch of the saphenus which perforates the sartorius muscle, and also with the obturator nerve after this becomes cutaneous.

Cutaneous of the great Saphenus. The *great saphenus nerve*, placed beneath the fascia, gives off sometimes a small branch about the middle of the thigh to join in a plexus with the obturator, and from this some filaments

perforate the fascia posteriorly to the sartorius, and then diverge to supply the integument of the inner and posterior part of the thigh. When another nerve, the accessory of the saphenus, is present, these filaments are derived from it, and this branch is absent. The trunk of the nerve divides, near the knee, into two branches, which separately pierce the fascia; the superior or anterior passes through the tendon of the sartorius on the inner side of the knee-joint, is joined by a filament from the internal cutaneous, then turns forwards to the front of the patella, and ends by dividing into many branches which radiate and join with the external cutaneous nerve, and some of them extend in front of the ligament of the patella to the upper and outer part of the leg; the inferior branch, the continuation of the nerve, appears below the knee, and comes from beneath the tendon of the sartorius; it is joined by the cutaneous branch of the obturator, and sometimes, by the descending branches of the accessory of the saphenus. It divides into many branches for the leg, which accompany the saphena vein.

Accessory of the Saphenus.

The *accessory nerve* of the *saphenus* (Cruveilhier), a branch of the anterior crural, joins in the plexus with the obturator, and from this the cutaneous branches appear in the middle of the thigh behind the saphena vein; it gives also some other small cutaneous filaments near the knee; but when this branch is absent its place is supplied in the middle of the leg by a nerve from the great saphenus.

Cutaneous of the Obturator.

The *cutaneous branch* of the *obturator nerve* lies beneath the fascia down to the knee, and gives off cutaneous filaments in its course, the largest of these appearing about the upper third of the thigh, and descending to about the middle with the saphena vein. Near the inner side of the knee the nerve appears behind the posterior border of the sartorius, it is then joined by the internal cutaneous nerve, is connected also to the great saphenus, and divides into filaments which descend to the leg*, as well as backwards to the popliteal space.

Cutaneous Arteries.

Numerous *cutaneous arteries* perforate the fascia, the larger ones with the nerves, and the saphenus is always accompanied by the cutaneous branch of the anastomotic. The named branches in the upper part of the thigh have been followed.

Fascia lata.

The *fascia lata* of the thigh is seen, when the cellular membrane is removed, to serve as a strong investing sheath, which

* This nerve is described by Dr. Alexander Thomson as ending opposite the head of the tibia, by joining the saphenus. See No. 95. of the *London Medical and Surgical Journal*. But it has been followed much farther in the dissecting-room of the College, in the careful dissections of two distinguished students. It was traced to the middle part of the inner surface of the calf of the leg by Mr. James Harrison, Session 1838–9, and to about four inches of the inner ankle by Mr. Henry Long Jacob, Session 1839–40. In the leg it communicates with the saphenus nerve, but this will be afterwards seen.

envelopes the different muscles, and sends processes inwards to separate them, a white line marking the position of each of these. It is perforated with many apertures for cutaneous nerves and vessels; these are most numerous near Poupart's ligament, and the largest is that for the saphena vein. The fascia is of a bluish-white colour, and is formed by fibres which cross in different directions; its density is often very little, particularly in fat subjects; but it is always stronger externally than internally, owing to the insertion into it of the tendons of the gluteus maximus and tensor vaginæ femoris, and this thickened part extends forwards to the line of the rectus muscle. At the upper part of the thigh it is fixed to the crest of the ilium, and posteriorly to this to the spines of the sacrum, covering in the gluteus maximus and medius muscles, and forming much the thickest layer over the last; between the crest of the ilium and the pubes it has been seen to be attached by one portion, in front of the vessels, to Poupart's ligament, and by another, behind them, to the pectineal line, to allow the saphena vein to reach the deep femoral vein. Inferiorly it is prolonged over the articulation of the knee, and is separated from the patella by a bursa; as it is continued over the joint it is inseparably united to a fibrous expansion from the extensor muscles of the leg, and is fixed to the heads of the tibia and fibula, but posteriorly the fasciæ of the thigh and leg are continuous. The chief of the processes sent between the muscles are the two intermuscular septa, which are fixed to the lines leading from the linea aspera to the outer and inner condyles of the femur: they separate the quadriceps extensor muscle from the others, and the external is most marked. Another portion of the fascia separates the adductors from the muscles behind, so that the muscles are divided into three bundles,—an anterior of the extensors of the leg, a posterior of the flexors, and an internal of the adductors. The different processes must be examined when the muscles are dissected.

Dissection. Replace the flaps of skin which were removed to follow the cutaneous nerves, and take away the fascia lata from the hollow or triangular space at the upper part of the thigh, to expose its boundaries, and the vessels and nerves contained in it. In the space, are the trunks of the femoral vessels and some of their branches, with the divisions of the anterior crural nerve; and in removing the cellular membrane and remains of the femoral sheath, it is chiefly the nerves that are likely to be cut, particularly some small ones from the anterior crural, that pass beneath the artery to the pectineus, or the small accessory of the obturator on the ramus of the pubes, between the pectineus and psoas muscles.

Triangle of the upper The *triangular space* which appears in the upper part of the thigh on the removal of the fascia, corresponds to the depres-

sion on the surface close to Poupart's ligament, and resembles in position the hollow between the trunk and upper extremity. Its base is above at Poupart's ligament, and the apex below, at the junction of the sartorius and adductor longus muscles, is to the inner side of the femoral vessels; its extent is about the upper third of the thigh, but this varies according to the breadth of the sartorius; and it is deepest below, in consequence of the muscles of the inner side passing back to their insertion. The space is covered in by the fascia lata, together with the superficial fascia, glands, and vessels. The inner boundary is inclined downwards and backwards, and is formed by the adductor longus and pectineus muscles, and a slight interval between them below, allows of the adductor brevis being seen; crossing this side is the inferior or deep branch of the external pudic arteries. The outer boundary is formed by the conjoined psoas and iliacus for about two inches, but below this by the sartorius which descends inwards to meet the adductors, and the anterior crural nerve is in relation with this boundary. Occupying the base are the parts that close the crural arch; thus, near the centre of the space is the femoral artery, placed on the inner part of the psoas muscle; but in emaciated subjects, in which the muscle is small, it lies with the vein on the pubes; it is crossed in front by the crural branch of the genito-crural nerve, and behind, by the branch to the pectineus muscle from the anterior crural. On the outer side of the vessel are the iliacus muscle and a part of the psoas, and deep in the interval between them, and about half an inch external to the artery, is the large anterior crural nerve; and on the iliacus muscle, between the anterior superior and inferior spinous processes of the ilium, is the external cutaneous nerve of the thigh. On the inner side of the artery is the femoral vein, lying on the ramus of the pubes between the borders of the pectineus and psoas muscles, and between it and the base of Gimbernat's ligament is the oval space of the crural ring, which is about half an inch wide, and gives exit to the femoral hernia. Through the centre of the space run the femoral artery and vein, the former supplying in this part its profunda and cutaneous branches, and the latter receiving the saphena and deep veins; external to them are the branches of division of the anterior crural nerve.

part of the thigh.

The artery or vessel for the supply of the lower extremity is the continuation of the external iliac, and like that of the upper extremity it takes the names of femoral, popliteal, and tibial, from its contiguity to different bones, or from the regions through which it passes. The first division of it, named *femoral*, extends from the lower border of Poupart's ligament to the lower third of the thigh, where it passes from before backwards through an aperture in the adductor magnus muscle, and assumes the name of popliteal. When the limb is rotated out-

Femoral Artery.

wards, its course is indicated by a line extended from the centre of Poupart's ligament to the inner side of the patella, but the vessel is comparatively superficial in the upper third, though deep and covered by the sartorius in the middle third of the thigh.

In the upper third of the thigh.

The trunk of the artery is now exposed only in the upper third of the thigh, and it lies in the triangular space of this region, its extent above being limited by Poupart's ligament, and below, by the sartorius muscle which it touches midway between the adductor longus and iliacus muscles. It is situated above over the head of the femur, but below it lies to the inner side of the bone. It is very superficial in this extent, being covered only by the integument, superficial fascia, and vessels, by the inguinal glands and fascia lata, and for about two inches it is enclosed in the femoral sheath. On the outer side for about two inches is the iliacus muscle, but below this is the anterior crural nerve, which emerges from its deep position as the iliacus passes back to be inserted, and approaches the artery, but separated from it by a cellular interval; on the inner side is the femoral vein, which gradually inclines behind the artery in its lower part. Posterior to it is the psoas muscle, which, two inches below Poupart's ligament, dips down to its insertion, so that this portion of the artery is not in contact with any muscle in the rest of its extent, but is supported by the profunda branch, the profunda and femoral veins, and by much cellular membrane, which separate it from the pectineus and adductor brevis, from which it is distant one inch and a half; it is separated from the hip-joint by the psoas, and the small internal branches of the anterior crural are beneath it on the muscle.

Branches.

The branches of the artery in this part are the superficial or external pudic, superficial epigastric, and circumflex ilii, which have been dissected, and the large profunda branch.

Inferior pudic.

The *inferior external pudic branch* is now visible; it arises sometimes from the trunk of the artery, at others, in common with the other external pudic already dissected; it runs upwards and inwards on the inner boundary of the space, beneath the fascia lata, becomes cutaneous at the inner border of the thigh, and is distributed to the scrotum and perinæum, anastomosing with branches of the perinæal artery of the internal pudic.

Profunda.

The *profunda branch*, nearly as large as the trunk, is distributed to the muscles of the thigh, but its anatomy will be resumed.

Femoral Vein.

The upper third of the *femoral vein* accompanies the artery through the triangular space, and has the same extent, and relations to the superficial parts. Beneath Poupart's ligament it lies on the pubes between the pectineus and psoas, to the inner side of the artery, and on the same level; but as it descends, it passes beneath the femoral, so as to appear on the

outer side opposite the upper border of the tendon of the adductor longus muscle. The vein makes a half-spiral turn behind the artery, and separates the branch of the profunda from the trunk. Sometimes it is altogether on the inner side of the artery, or the artery may pass through it. In this part it receives the saphena and profunda veins, which much increase its size.

Dissection.

To examine the muscles of the thigh, detach the cutaneous nerves and throw them upwards, raise the fascia from the whole anterior surface of the thigh by means of an incision along the centre. On the outer side, where it is thick, leave a narrow slip extending from the insertion of the tensor vaginæ femoris to the knee-joint, but posterior to this follow it back to the external intermuscular septum behind the vastus internus muscle. In removing it from the inner side be careful of the branches of the obturator and saphenus nerves, as well as of the branches of communication with these from the plexus formed by the obturator and accessory of the saphenus; avoid also displacing the connections of the sartorius muscle till its relations have been examined, and follow its tendon as well as that of the gracilis forwards to their insertion. During the dissection of the outer muscles, make them tense by flexing the leg, and extend the limb for the inner set; but the position of the extremity will often be required to be changed to render tense different muscles. As the fascia passes over the knee-joint it is united with an aponeurotic expansion from the quadriceps extensor muscle, and is fixed to the heads of the tibia and fibula; a bursa is placed between it and the patella. When the fascia is taken away, the sartorius muscle is seen winding across the thigh from the outer to the inner side, and dividing the muscles into an external and an internal set. In the outer are situated the quadriceps extensor and tensor vaginæ femoris: the former consisting of rectus femoris, easily recognised by its direction and superficial position, and of a large mass of muscle closely surrounding the bone, and divided into vastus internus, vastus externus, and cruræus; the latter, or tensor, is situated at the upper part of the thigh. The internal set includes the pectineus, the three adductors, and the gracilis; the last is a thin riband-like muscle, and passes with the sartorius to the upper part of the tibia, but the others are inserted into the inner side of the femur.

Sartorius Muscle.

The *sartorius muscle*, the longest in the body, is placed on the front and inner part of the thigh in a groove between the extensor and adductor muscles, and extends from the anterior superior spinous process of the ilium to the upper part of the tibia; its upper part is directed obliquely inwards in front of the femur, the middle descends vertically, internal to the bone, to the inner condyle, and the lower turns forwards to the tibia.

The centre of the muscle is wider than the extremities, and the height at which it crosses the thigh to reach the inner side, differs in subjects. To see its origin, detach it internally from
Origin. the iliacus, and externally from the tensor vaginæ. It *arises* by a tendon, most marked on the outer part and behind, from the anterior superior spinous process of the os ilii, from the interval between it and the inferior process, and from the intermuscular septum between this muscle and the tensor vaginæ. The fibres are directed obliquely downwards to the point at which they touch the adductor longus, they now descend vertically to behind the inner condyle, where the outer end in the tendon which commences opposite the condyle on the upper border of the muscle; but the inner, become lowest from the change in their direction,
Insertion. continue forwards to the tendon, which, flat and thin, is *inserted* into the inner surface of the tibia, close to the tuberosity of this bone, extending a little below it, and is situated above the tendons of the gracilis and semi-tendinosus, separated from them by a synovial membrane, an aponeurotic expansion being given off from its upper border to join with that from the quadriceps on the articulation, and another from the lower, to the
Relations. fascia of the leg. The upper or oblique portion of the muscle, which extends as far as the adductor longus, forms the outer boundary of the triangular space which contains the femoral artery, and has the following relations: — its surfaces look forwards and backwards, and are generally perforated by one or more branches of the cutaneous nerves. The upper border is in contact with the iliacus, anterior crural nerve, femoral vessels, and lastly with the adductor; and the lower touches the tensor vaginæ, and quadriceps extensor which is beneath it. The middle or vertical part lies in the groove formed by the vastus internus and adductor muscles; its surfaces are directed inwards and outwards, and the borders consequently forwards and backwards, the vastus internus and tendon of the adductor magnus being in contact with the anterior, and the gracilis muscle and obturator nerve with the posterior. The cutaneous surface is covered by the fascia lata, and perforated by the internal cutaneous nerve; and the deep is in relation with the femoral vessels and accompanying nerves, but separated by an aponeurotic expansion, and below the opening for the passage of the artery from the front to the back of the thigh, with the tendon of the adductor magnus, which it crosses; below the tendon it assists to form the inner boundary of the popliteal space, is placed against the upper part of the popliteal artery, and conceals the great saphenus nerve which escapes beneath its tendon. The lower or horizontal portion, partly tendinous and partly fleshy, the muscular fibres extending farthest forward below, turns round the upper extremity of the tibia. The borders are directed upwards and downwards; above the superior is the

anterior branch of the saphenus nerve, which runs inwards to the knee after perforating the muscle; and escaping from beneath the inferior, between it and the gracilis, is the saphenus nerve. On the cutaneous surface is the saphena vein; and the tendon lies on the internal lateral ligament of the knee-joint, in common with the tendons of the gracilis and semi-tendinosus muscles. Turn aside the sartorius, and remove any cellular membrane that may conceal the aponeurosis between the middle part of the muscle and the femoral vessels.

Aponeurosis over the Artery.

The *aponeurosis* concealing the femoral vessels is placed as a protecting arch during the contraction of the sartorius, and consists of strong transverse fibres between the vastus internus and adductor muscles. It commences above, where the sartorius comes into contact with the adductors, and ends below, at the opening in the adductor magnus muscle for the femoral artery, by a defined border, beneath which pass the saphenus nerve and anastomotic artery; it covers in the femoral vessels and saphenus nerves. Turn it to one side, leaving below a portion, and remove the cellular membrane from the vessels and nerves beneath it.

Femoral Artery in the middle third.

The *lower part* of the *femoral artery*, or the portion in the middle third of the thigh, is much more deeply seated than the upper. Its course is nearly straight, since it lies to the inner side of the femur, and its extent is from the upper border of the sartorius to the opening in the adductor magnus, through which it passes to the popliteal space, and takes the name of popliteal. The aponeurosis beneath the sartorius binds it closely to the tendons of the muscles behind, and it lies in a groove formed by the vastus internus and adductors. The artery is covered by the integument and fasciæ, by the sartorius and aponeurosis before mentioned; and it lies on the tendons of the adductor longus and adductor magnus; external to it is the vastus internus, and on the inner side, the adductor muscles descending to their insertion. In close contact with the artery, and on its outer side, is the femoral vein. Beneath the aponeurosis are some branches of the anterior crural nerve; they approach the femoral where it is covered by the sartorius, and are situated to its outer side, and external to the proper cellular sheath of the vessels. The longest and largest — the long saphenus — lies on the outer and anterior part of the artery through the middle third of the thigh, and leaves it at the opening in the adductor. The second nerve — the short saphenus, or nerve to the vastus internus — is nearly as large in size as the other, but is external to it, continues with the artery only for a short distance, and is then distributed to the vastus. The remaining nerve is the small accessory to the saphenus, which crosses from the outer to the inner side in front of the lower part of the artery, and terminates opposite the opening of the

adductor by dividing into branches which join with the obturator.

Branches. In this extent the femoral artery gives several unnamed branches to the muscles, and one named anastomotic.

Anastomotica magna. The *anastomotica magna artery*, a small branch of the femoral just before it passes into the popliteal space, escapes with the saphenus nerve from beneath the arched border of the aponeurosis, and divides into a superficial and a deep branch. The

Superficial branch. *superficial* accompanies the saphenus nerve, crossing the tendon of the adductor magnus, and running beneath the sartorius to its lower border, where it becomes cutaneous with the nerve, and ends in the integuments: it supplies branches to the sar-

Deep. torius whilst beneath it. The *deep branch* descends to the knee in front of the tendon of the adductor magnus, and covered by some fibres of the vastus internus, which may be divided to see it; at the articulation of the knee it leaves the fibres, continues over the inner side of the joint, anastomosing with the superior internal articular, and the recurrent branch of the anterior tibial. It supplies branches to the vastus whilst covered by it, and a little above the end of the femur gives off an artery which crosses obliquely the bone to join with a similar branch from the superior external articular of the popliteal, thus forming an arch above the articular surface of the femur, from which branches descend to the knee-joint. The deep portion of this artery will be better seen after the vastus is dissected.

Femoral Vein. The *femoral vein* in the middle third of the thigh, is situated to the outer side of the artery, but closely united to it by cellular membrane, and it has the same extent and relations to surrounding parts. Occasionally, the vein may be found on the inner side of the femoral, or it may be divided into two. The branches that join it are similar to those of the arteries.

Dissection. Divide the femoral artery and vein below the profunda, and throw them down, to examine the opening in the adductor through which they pass; remove the cellular membrane from the tendons of the adductor magnus and longus, and trace them to the femur.

Aperture of the Femoral Artery. The *aperture* by which the femoral artery and vein enter the popliteal space, and gain the posterior part of the limb, to pass the joint in the angle of flexion, is much larger than sufficient to transmit the vessels. It is situated to the inner side of the femur, and at the junction of the middle and lower thirds of the thigh; the anterior aspect is tendinous, but the posterior is fleshy. On the outer side are the tendon of the vastus internus, and the femur; and on the inner, the tendon of the adductor magnus, joined by some fibres from the tendon of the adductor longus; above, it is formed by the adductor magnus, and below, by the union of the tendon of the same adductor with that of the vastus internus.

Outer set of Muscles. The muscles on the outer side of the thigh are the tensor

vaginæ femoris, and a large muscular mass, which may be described either as a single muscle with the name of quadriceps extensor, or as three or four which are more or less distinct, though connected by a common tendon, and called rectus femoris, vastus externus, vastus internus, and cruræus.

Tensor Vaginæ Femoris Muscle.

The *tensor vaginæ femoris* is enclosed in the fascia lata, on which it acts, and is the most external and superficial of this set of muscles. It is short and thick, and *arises* from the outer part of the anterior superior spinous process of the ilium, and from the outer side of the crest; the fibres, parallel and almost vertical, end in tendinous portions which join the fascia lata about three inches below the great trochanter. The muscle is subcutaneous, and covered by the fascia; its origin is between the sartorius, and gluteus medius with which its fibres are generally united; and it lies on the gluteus, the vastus externus, the rectus, and the ascending branches of the external circumflex artery. If the muscle be turned outwards, the branch of the superior gluteal nerve that enters it will be seen.

Origin. Insertion. Relations.

Rectus Femoris Muscle.

The *rectus femoris muscle*, or superficial portion of the quadriceps extensor, is situated on the front of the thigh, and is smaller at each extremity, which is tendinous, than in the middle. To follow its upper attachment, separate from each other the tensor vaginæ and the sartorius, or partly detach them. Its *origin* is from the pelvis by two tendinous heads or processes: the external, largest and longest, from a depression on the posterior surface of the os innominatum immediately above the cotyloid cavity; the internal, from the anterior inferior spinous process of the same bone. These unite in a tendon that occupies the upper part and anterior surface of the rectus, and to it succeed fleshy fibres that descend, forming a fusiform shaped muscle with a penniform arrangement, and end on the anterior surface of the inferior tendon which joins with those of the vasti and cruræus in the common tendon of *insertion*, or the ligamentum patellæ. The cutaneous surface is aponeurotic above, the outer border being thin and riband-like, and is covered by the sartorius, but below this it is in contact with the fascia lata and forms the prominence of the front of the thigh; the deep or posterior is aponeurotic below, the tendinous fibres commencing nearly opposite to where the anterior cease, and is in relation with the hip-joint, the vastus externus, external circumflex artery, and branches of the anterior crural nerve, and with the cruræus muscle. The upper part is placed between the iliacus and tensor vaginæ, and the outer head is concealed by the gluteal muscles. Cut across the rectus near its lower attachment, and turn it upwards to see the muscles beneath; be careful at the same time of the branches of the circumflex artery and anterior crural nerve.

Origin. Insertion. Relations.

Vastus externus Muscle.

The *vastus externus* muscle, or outer portion of the quadriceps,

and the remaining vastus internus and cruræus closely surround the femur, occupying the whole surface of the bone, except the linea aspera and the surfaces included by the lines that diverge from it above and below, and extending in front as high as the trochanters and the inter-trochanteric line. This muscle is pointed above, and aponeurotic on the outer surface, and its separation from the rest is marked by a cellular interval containing the descending branches of the external circumflex artery.

Origin. The vastus *arises* from the anterior part and outer surface of the base of the great trochanter, its origin surrounding the insertion of the gluteus medius; from the line extending to the linea aspera; from the outer lip of the linea aspera in its whole length; and from the two upper thirds of the line going to the outer condyle; many fibres are also connected to the external intermuscular septum, and slightly to the outer surface of the bone. The fibres descend more or less obliquely inwards, the superior being most vertical, to end in a tendinous aponeu-

Insertion. rosis, which, situated on the inner side of the muscle, joins in the common tendon of insertion with the aponeurotic expansions of the other portions of the quadriceps, and sends off superficial aponeurotic fibres to join with the fascia lata in a capsule for

Relations. the knee-joint. The cutaneous surface is covered above by the rectus and tensor vaginæ muscles, and by branches of the external circumflex artery and anterior crural nerve; but below, it is subcutaneous and prominent. The muscle lies on the femur. The outer border is attached to the bone; and the inner overlays the cruræus, separated however by descending branches of the circumflex artery and crural nerve.

Vastus internus Muscle. The *vastus internus**, or inner portion of the muscular mass, is larger below than above, and near the patella projects more than the vastus externus. An aponeurosis occupies the outer surface in contact with the other vastus, by which it is partly concealed near the patella. The separation between it and the

Origin. cruræus may be begun near the knee. The muscle *arises* by a pointed portion from the root of the small trochanter, from the line leading from it to the linea aspera, from the inner lip of the linea aspera, from the two upper thirds of the line leading to the inner condyle, and the tendon of the adductor magnus fixed to this line, and from the surface of the bone as far for-

Insertion. wards as to a line with the inner border of the patella. The fibres are directed downwards to the tendon, which unites with the others, and sends off an expansion over the inner half of the

Relations. knee-joint to the head of the tibia. The upper part of the muscle lies deeply in the triangular hollow in the upper region of the thigh, and beneath the circumflex artery, whilst the

* The vastus internus and cruræus are here described as separate muscles because it is customary to do so; but the division of them is artificial, and it would be more natural to consider them one.

lower is superficial, and gives the prominence of the lower and inner part of the thigh, but in the intervening part it is covered in some measure by the sartorius; it rests on the bone, which has a space on the inner side, to which few fibres are attached. The adductor muscles are closely united to its origin, but only the tendon of the adductor magnus in the space between the linea aspera and inner condyle. It assists in forming the opening for the femoral artery.

Cruræus Muscle.

The *cruræus* is the central deep portion of the muscle, and occupies the front of the femur; it is fleshy beneath, but aponeurotic on its cutaneous surface. It *arises* from the anterior surface of the femur as high as the inter-trochanteric line, and as low as to within two inches of the articular surface, externally it reaches beneath the vastus internus near to its origin, and internally, to a line with the inner border of the patella: the fleshy fibres descend, and terminate in an aponeurosis which joins the common tendon. Some of the lower fibres do not join the tendon, but descend behind the patella, and end in scattered tendinous processes on the synovial membrane: this portion of the muscle, called *subcruræus*, consists of paler fibres, and is sometimes separated from the rest by a cellular interval. The muscle is covered by the rectus, by the profunda artery and circumflex branches; and it lies on the femur, and on the synovial membrane of the knee-joint, which projects upwards beneath it.

Origin.

Insertion.

Relations.

Expansion from the Vasti.

The *expansion* prolonged from the aponeurotic portions of the vasti, which serves as a capsule for the articulation, is seen by making a central incision over the patella and its ligament, when it may be raised as a thin covering, and may be reflected to the sides. It is strongest on the inner side, where the fascia is weak, and thinnest on the outer, where the increased strength of the fascia supplies the deficiency; united with the fascia lata, it forms a covering for the joint, which passes over the patella and its ligament, and is fixed internally to the head of the tibia, externally to that of the fibula, and joins laterally the tendons of the sartorius and biceps. When this expansion is thrown down a deeper set of fibres, which give additional support to the articulation, will be seen; they form on the inner side a strong band almost transverse, but looser than that on the outer side, which passes from the internal lateral ligament to the patella; and on the outer side is another band from the fascia lata to the patella.

Tendon of the Quadriceps.

The *tendon of the quadriceps extensor*, formed by the union of the different aponeuroses connected with the muscular portions, extends in front of the articulation between the tibia and femur, serving materially to keep the bones in contact, and has developed in it a sesamoid bone, or the patella; it is wide above the patella, extending higher on the outer than on the inner

side, but is narrow below this bone, and is attached to the prominence of the tuberosity of the tibia, a synovial membrane being situated between it and the bone close above its insertion. It is subcutaneous, and is separated from the synovial membrane of the articulation by much fat; but as this tendon is described as a ligament of the articulation, with the name of ligamentum patellæ, it will be particularly examined with the ligaments of the extremity. From its upper part the different aponeurotic processes may be traced to the respective muscles.

Intermuscular Septa.

The *intermuscular septa* are processes of fascia lata which pass inwards between the muscles to the linea aspera. The

External.

external, seen if the fascia lata be followed back, is the strongest; it reaches from the insertion of the gluteus maximus to the outer condyle, and is fixed to the linea aspera, external to the insertion of the vastus externus, and to the line leading to the outer condyle; by its anterior surface it gives origin to the vastus externus, and by the posterior, to the short head of the biceps; it is perforated above by branches of the circumflex artery, and near the condyle of the femur, by the superior external articular artery in its course to the front of the articula-

Internal.

tion. The *internal* extends from the small trochanter to the inner condyle between the vastus internus and adductor magnus, but is so thin that it is commonly removed without being noticed: the tendon of the adductor magnus supplies its place along the line from the linea aspera to the inner condyle, giving an attachment to the vastus, and is perforated by the internal articular vessels. By means of these septa, the extensor muscles of the leg, now described, are separated from the other sets.

Dissection.

Clean away the cellular membrane from the branches of the external circumflex artery which supplies these muscles, as well as from the branches of the anterior crural nerve; the small veins with the arteries are unimportant, since they have the same anatomy, and may be removed. The outer set of muscles, above described, are supplied with branches of the anterior crural nerve, except the tensor vaginæ femoris which receives its nerve from the superior gluteal.

External circumflex Artery.

The *external circumflex artery*, a branch of the profunda, is given off from the outer side of this artery, whilst it is external to the femoral and on the psoas muscle. It passes transversely outwards through the divisions of the anterior crural nerve to the vastus externus muscle, lying beneath the sartorius and rectus, and on the psoas and iliacus, and divides into its terminating branches, viz. ascending, descending, and transverse. The *descending* set, the largest and most numerous, run downwards and outwards between the vastus externus and cruræus, and distribute branches to each muscle, some of them being traceable to near the knee. The *ascending* branches, about three in number and smaller than the descending, pass beneath

the tensor vaginæ femoris to the anterior inferior spinous process of the ilium, and anastomose with the gluteal; and the *transverse*, one or two arteries of small size, perforate the vastus externus, and insertion of the gluteus maximus, and are seen on the back of the thigh, anastomosing with the perforating arteries from the profunda. As the profunda lies beneath the sartorius, rectus, and tensor vaginæ, it supplies them with branches. The origin of this branch may be from the femoral, instead of the profunda, either by a single trunk or by separate branches.

Anterior Crural Nerve.

The *anterior crural nerve*, the largest branch of the lumbar plexus, supplies the muscles already examined, except the tensor vaginæ, and leaves the abdomen beneath Poupart's ligament, lying in the interval between the psoas and iliacus, and half an inch distant from the femoral artery. In the thigh it is contained in the triangular space with the femoral artery, and, having perforated the iliac fascia opposite the bending backwards of the psoas and iliacus to their insertion, becomes superficial, and spreads out into its branches of distribution. Near Poupart's ligament it gives off a superficial portion, which divides into cutaneous branches, and those to the femoral artery and pectineus.

Branches.

From superficial portion. To Femoral Artery.

The *branch* to the *femoral artery* * arises from the small superficial portion of the nerve, and is directed inwards to the femoral vessels, around which its filaments entwine, and one or two occasionally perforate the fascia lata. This nerve may arise from the lumbar plexus, or from one of the other cutaneous branches which may come off from the anterior crural near its commencement; in either case it descends with the anterior crural to near Poupart's ligament, and then turns outwards to the vessels.

To the Pectineus.

The *branches* to the *pectineus muscle* are two or three slender filaments that pass inwards behind the femoral vessels, and supply the pectineus, and occasionally the psoas muscle.

Anterior middle Cutaneous.

The *anterior middle cutaneous* nerve of the thigh either passes through the fascia lata near Poupart's ligament, or perforates the sartorius muscle; its cutaneous filaments of distribution may be followed to the knee as before seen.

Anterior internal Cutaneous.

The *anterior internal cutaneous*, arising in common with the preceding from the superficial part of the anterior crural, enters the sheath of the sartorius, perforates the muscle, or only the fascia, in the lower third of the thigh, and ends in the integuments of the inner side of the thigh and knee.

Accessory of the Saphenus.

The *accessory cutaneous nerve of the internal saphenus* (Cruveilhier) arises in common with the internal cutaneous nerve from the superficial portion of the crural, though sometimes

* This is described by Schmidt (*Commentarius de Nervis Lumbalibus*, &c. § xxxviii.) as the "nervus arteriæ crurali proprius."

from the saphenus, descends beneath the sartorius and the fibrous expansion, crosses the femoral artery about the middle of the thigh, and, a little above the opening in the adductor magnus, passes from beneath the sartorius, and joins with the cutaneous nerve of the obturator in a kind of plexus, from which branches pass backwards through the fascia to the integument, and one long filament descends beneath the sartorius, and along the border of the tendon of the adductor magnus, to join with the internal saphenus nerve after this has escaped from beneath the aponeurosis covering it and the femoral artery. When the accessory nerve is large it sends downwards some branches, which join with the internal cutaneous, saphenus, or obturator, and are distributed to the integuments on the inner side of the knee. This nerve is occasionally absent, and its place is supplied by a branch from the internal saphenus, which joins in the plexus with the obturator.

To Sartorius. The sartorius muscle is supplied from the superficial portion of the anterior crural nerve, and receives its branches from the different cutaneous nerves that perforate it, or run in the sheath in contact with it.

From deep portion. To Rectus. The deep portion of the anterior crural, or the continuation of the nerve, divides into numerous muscular branches, — *one* of these to the *rectus* femoris muscle passes forwards and outwards to reach its under surface, and divides into branches as it is about to perforate its substance.

To Vastus externus. The *nerve to the vastus externus* is directed downwards with the descending set of arteries from the external circumflex, and divides near the muscle into two or more branches which enter into the muscular substance, but one of these, a long slender Articular. *articular* filament, continues to the tendon of insertion, where it becomes cutaneous, then descends over the outer part of the articulation, sending some filaments to the front of the patella, and others enter the articulation.

To Crurœus. The *nerve to the crurœus* enters the upper part of the muscle, and ends in it.

To Vastus internus. The *nerve to the vastus internus* is sometimes called short saphenus from accompanying the long saphenus, to which it is inferior in size and length. It often arises in common with the long saphenus, approaches the femoral artery where it is covered by the sartorius, descends externally to it, but covered by the aponeurosis which conceals the vessels, as far as to the middle of the thigh, and divides into a branch to supply the substance Articular. of the vastus, and one for the articulation. The *articular* branch descends on the surface of the muscle, and divides, about the lower third of the thigh, into two filaments; one enters the vastus, and may be followed in it to the articulation; the other is applied to the internal intermuscular septum, runs along it with the anastomotic artery to the articulation, perforates the inner

part of the fibrous capsule, and is distributed to the articulation by a transverse branch that runs outwards with an artery behind the anterior ligament. Whilst this branch is in contact with the intermuscular septum it is sometimes joined by the obturator nerve.

Internal Saphenus.

The *internal* or *long saphenus nerve*, the largest branch of the anterior crural, approaches the femoral artery whilst it is covered by the sartorius, and lies nearer to it than the branch to the vastus internus muscle. The nerve descends through the middle third of the thigh with the artery, but covered by the aponeurosis, and, at the aperture for the femoral vessels in the tendon of the adductor magnus, it passes from beneath this fibrous expansion, is joined by a branch from the plexus of the obturator and accessory of the saphenus, then crosses the tendon of the adductor magnus so as to be placed behind it, and divides beneath the sartorius into a superior and an inferior branch: the superior or anterior perforates the muscle and the fascia, turns forwards round the inner side of the articulation above the tendon of the sartorius, is joined by a branch from the internal cutaneous, and sometimes from the accessory of the saphenus, and terminates in numerous cutaneous branches, as before seen; the inferior branch, the continuation of the nerve, is accompanied by the cutaneous portion of the anastomotic artery, passes downwards to the lower border of the sartorius muscle, perforates the fascia between it and the gracilis, and, become cutaneous, is joined by filaments from the obturator nerve, and sometimes from the accessory of the saphenus, and then continues with the saphena vein along the inner side of the leg to the foot. In some instances, this nerve gives off, about the middle of the thigh, a small branch that passes inwards over the artery, escapes from beneath the inner border of the sartorius, and joins with the obturator nerve in the plexus before seen; this is absent in those subjects in which the accessory of the saphenus exists.

To the Obturator.

Superior Gluteal Nerve.

The branch of nerve to the tensor vaginæ femoris muscle is derived from the *superior gluteal*, which arises from the fifth lumbar nerve as this descends to the lumbar plexus. It appears beneath the anterior border of the gluteus medius muscle, comes into contact with the tensor vaginæ, and is distributed to its under surface; the filaments descend to near the insertion of the muscle.

Dissection.

Continue the dissection with the examination of the muscles on the inner side of the thigh; these consist of the gracilis, the most internal and thinnest, of the pectineus external to it and near the pelvis, and of the three adductors, named, from their length or size, longus, brevis, and magnus. The arteries supplying the muscles are branches of the profunda; and the nerves are from the obturator. The small veins may be removed from the branches of the artery which are now exposed.

Gracilis Muscle. The *gracilis muscle*, the most internal of the muscles of the inner part of the thigh, is thin and riband-like, and is attached above to the pubes, but below to the upper part of the tibia. Its surfaces look inwards and outwards, and its borders consequently forwards and backwards; the upper part is flat and

Origin. muscular, but the lower is tendinous. The *origin*, from two to three inches deep, and internal to the adductors, is thin and aponeurotic from the anterior surface of the body of the pubes, from the descending ramus of the same bone, and from the ascending ramus of the ischium. The fibres run downwards, and end in a tendon, which receives muscular fibres, in front, to near the condyle of the femur, but behind, only to a little below the middle of the thigh, is then continued forwards over the

Insertion. side of the articulation and internal lateral ligament, and is *inserted* as a flat band into the crest of the tibia below the sartorius, but above the tendon of the semi-tendinosus muscle; a fibrous expansion leaves the lower border of the tendon to join those from the sartorius and semi-tendinosus, and to end in the fascia of the leg, and a synovial membrane separates it from the

Relations. internal lateral ligament. The inner surface is subcutaneous, and is crossed in the thigh by the cutaneous nerves that are directed backwards over it, but below the knee by the saphenus nerve and vein; the outer lies against the adductor magnus, and below the tendon of this muscle it forms, by its position between the sartorius and semi-membranosus, part of the inner boundary of the popliteal space. The anterior border is in contact with the adductor longus, and below this muscle with the sartorius, with which it continues to the insertion; the posterior, with the origin of the adductor magnus from the tuberosity of the ischium, then with the semi-membranosus muscle, and tendon of the semi-tendinosus.

Pectineus Muscle. The *pectineus muscle* is the highest and most anterior of the muscles which act as adductors. It is fleshy above, at its attachment to the pelvis, but tendinous below at the femur; the surfaces look at first forwards and backwards, but inwards and

Origin. outwards near the insertion. It *arises* from the pectineal line of the pubes between the spine and pectineal eminence; and from the triangular surface of bone in front of it and Gimbernat's ligament: the fibres run downwards and outwards, forming

Insertion. rather a thin muscle, and end in a tendon which is *inserted* into the line leading from the linea aspera of the femur to the small trochanter, and as high up as to the insertion of the psoas. The

Relations. anterior surface is covered by the pubic part of the fascia lata, and by the deep branch of the external pudic arteries; and the posterior is in contact with the adductor brevis and obturator muscles, with the obturator nerve and its accessory, and with branches of the internal circumflex artery, which will be seen when the muscle is detached. The outer border touches the

ilio-femoral articulation, and lies by the side of the psoas, separated from it above by the femoral vein, and below by the internal circumflex vessels; and the inner or lower, longer than the other, touches the adductor longus at the origin, but at the insertion an interval is found between them, in which is seen the adductor brevis muscle. The vastus internus is in relation with the insertion.

Adductor longus Muscle.

The *adductor longus muscle* lies on the same level as the pectineus, and is superficial to the other adductors; it is pointed and tendinous at the pelvis, but wide and tendinous at the insertion into the femur, and it assists, with the pectineus, in forming the inner boundary of the triangular space of the upper part of the thigh.

Origin.

Its *origin* is by a strong roundish tendon from the spine of the pubes, and from the front of the body of this bone, in the angle formed by the union of the lines of the crest and the symphysis.

Insertion.

The fibres pass downwards and outwards, diverging and forming a flat muscle, and end in a tendon about three inches wide, which is *inserted* into the middle third of the linea aspera, and sends from its lower border an aponeurotic expansion to join with the tendon of the adductor magnus, and assist in forming the inner boundary of the opening for the femoral artery.

Relations.

The anterior or cutaneous surface is covered by the fascia lata, and near the femur is crossed by the sartorius and femoral vessels, and an aponeurosis extends from the tendon to the vastus internus; the posterior or deep lies on the adductor brevis and magnus, and branches of the obturator nerve and profunda artery. The upper border corresponds to the pectineus, but is separated, near the femur, by a cellular interval; the lower is in contact with the gracilis muscle, and coming from beneath it is the long cutaneous branch of the obturator nerve: this border joins the adductor magnus near the femur. The insertion is partly united with the vastus internus muscle.

Dissection.

Detach with care the pectineus from the pubes, and seek the small nerve of the accessory of the obturator which turns beneath its outer border, and is distributed beneath it. If this nerve be small, and do not supply the muscle, a branch will enter its under surface from the obturator nerve, which appears above the obturator muscle. The internal circumflex artery is partly exposed as it winds backwards, and it is necessary to divide some small branches to the pectineus.

Accessory Nerve of the Obturator.

The *accessory of the obturator nerve* (Schmidt), traced, in the dissection of the lumbar plexus, from the trunk of the obturator to the horizontal ramus of the pubes, perforates the fascia iliaca, and, lying close to the bone, divides a little below the level of Poupart's ligament into three branches: one passes inwards beneath the pectineus to join the trunk of the obturator nerve soon after it escapes from the pelvis, the middle, very long, is

distributed to the under surface of the pectineus, about its middle, and the most external descends to the branch of the artery to the inner side of the ilio-femoral articulation, and enters the joint with it.* Many small filaments perforate also the fibrous capsule of the articulation, on which the nerve lies. When the nerve is small, the branch to the pectineus and joint are absent, the place of the former being supplied by one from the trunk of the obturator, and of the latter, by some filaments that enter the upper part of the capsule.

Dissection. Throw down the adductor longus by dividing it near the pubes, taking care of the obturator nerve beneath; observe the branch supplied to the muscle from it, and detach the close connection of the cutaneous branch of the nerve from the under surface. Separate its tendon from that of the adductor magnus near the femur, so as to expose the trunk of the profunda artery beneath it. The adductor brevis is now exposed, and is to be separated from the adductor magnus behind it, a nerve and artery marking the line of separation. The parts covered by the adductor longus muscle are also seen.

Adductor brevis Muscle. The *adductor brevis muscle*, situate beneath the two preceding, is closely united behind to the adductor magnus; it is thick and muscular at the pelvis, but thinner and tendinous at the femur.

Origin. Its *origin* is from the anterior surface of the pubes between the symphysis and obturator foramen, beneath the adductor longus, and external to the attachments of the gracilis and adductor magnus. The fibres of the muscle run downwards, diverging,

Insertion. and end in a tendon which is *inserted* behind the pectineus into the line leading from the small trochanter to the linea aspera, extending as high as the tendon of insertion of this muscle, and into the upper part of the linea aspera, as low as to the insertion of the adductor longus, with which it is sometimes united. By

Relations. the anterior surface it is in contact with the pectineus, adductor longus, and branches of the obturator nerve, and, near the insertion, with the profunda artery; and the posterior lies on the adductor magnus, posterior division of the obturator nerve, and a branch of the internal circumflex artery. The upper border is placed by the side of the obturator externus, and is crossed by the internal circumflex artery; the lower, overlapped, at first, by the adductor longus, is side by side with it at the insertion. Near the femur the tendon usually presents two apertures for the perforating arteries; and at its attachment to the linea aspera, the pectineus and vastus internus are in front, and the adductor magnus behind it.

Dissection. Remove the cellular membrane and veins from the branches

* Schmidt, op. cit. § xl., does not state that a branch enters the articulation at this point; but, in describing the branch which corresponds to it, he says, "*medius* ramus versus corpus ossis pubis proficiscitur, et in adipe prope acetabulum cessat."

of the profunda artery, following the internal circumflex backwards above the upper border of the adductor brevis, and the perforating branches through the tendons of the adductor brevis and magnus, close to the linea aspera.

Profunda Artery of the Femora

The *profunda artery*, for the supply of the muscular substance of the thigh, and the channel by which the circulation of the limb is carried on when the main trunk is obliterated, is the largest branch of the femoral, and arises from its outer side about one inch and a half below Poupart's ligament, whilst the vessel lies in the hollow of the upper part of the thigh, and is supported by the psoas muscle. It is at first directed outwards, external to the artery, and is comparatively superficial, being covered by the integuments and fascia, and lying on the psoas muscle; the branch then turns downwards and inwards to the inner side of the femur, crossing beneath the femoral artery, but at a considerable depth below it, being separated from it by the profunda and femoral veins and much cellular membrane, and placed on the cruræus and vastus internus muscles; on the inner side of the femur the profunda again changes its direction, and descends parallel to the trunk of the femoral, but much nearer to it, the tendon only of the adductor longus intervening between the two; it is situated, in this part of its course, on the adductor brevis muscle, then between the adductor longus and adductor magnus, and it ends in a branch which perforates the adductor magnus, and is distributed to the hamstring muscles. The branches given off by it are, the external circumflex, on the outer side of the femur, to the external set of muscles, internal circumflex, on the inner side of the bone, to the back of the thigh, and perforating arteries through the tendons of the adductors on which it lies.

Branches.

External Circumflex.

The *external circumflex* arises from the outer part of the profunda, whilst it is external to the femoral artery, and has been seen to divide into descending, ascending, and transverse arteries for the supply of the muscles of the outer part of the thigh.

Internal Circumflex.

The *internal circumflex*, the next branch of the profunda, arises from the posterior part of the artery, passes backwards on the inner side of the femur, between the psoas and pectineus muscles, and above the upper border of the adductor brevis, following the course of the tendon of the obturator externus muscle below the head of the femur to the back of the thigh, where it divides into two branches: one of these ascends to the pit of the great trochanter; the other is distributed to the hamstrings, as will be afterwards seen, and passes between the borders of the quadratus femoris and adductor magnus muscles. Opposite the upper border of the adductor brevis muscle, the internal circumflex gives off an ascending and a descending branch for the muscles of the inner side of the thigh: the

ascending, the smallest, lies beneath the pectineus, supplying it, the adductor longus, and gracilis, and sends some branches through the pubic border of attachment of the obturator externus muscle to anastomose with the obturator artery; a considerable branch also passes outwards, either from this ascending branch or from the trunk of the artery, to supply the articulation, which it enters by the notch in the inner side; the large descending branch lies beneath the adductor brevis, which will be better seen when this muscle is detached, descends between it and the adductor magnus, with the posterior branch of the obturator nerve, and is distributed to these muscles. The internal circumflex frequently arises from the trunk of the femoral.

Perforating Arteries.

The remaining branches of the profunda on the inner side of the femur are named perforating arteries, from the manner in which they pass through the tendons of the adductors; they are usually three in number, and are near the linea aspera. The

First.

first perforating artery, given off at the lower border of the tendon of the pectineus, passes backwards close to the linea aspera, through the tendons of the adductor brevis and adductor magnus, supplying these muscles, and ends at the back of the thigh by being distributed to the hamstring muscles, and inosculating with the circumflex branches of the external circumflex artery.

Second.

The *second perforating branch* is directed backwards through an aperture in the tendon of the adductor brevis muscle a little above its lower border, then through the tendon of the adductor magnus to reach the back of the thigh, and is distributed to the hamstring muscles, anastomosing with the sciatic and the other perforating arteries. This branch gives off the small nutritious artery to the femur, and supplies the adductor muscles. The

Third.

third perforating artery passes through an aperture in the adductor magnus, either close to the inferior border of the adductor brevis, or lower down, and has the same distribution as the others on the back of the thigh. These branches are frequently

Terminal branch of the Profunda.

irregular in number and course. The terminal branch of the profunda is sometimes named a perforating artery; it perforates the tendon of the adductor magnus below the others, and ends in the hamstring muscles, joining below with the branches that these receive from the popliteal artery, and so assisting to maintain the chain of anastomosis between the sciatic and popliteal arteries on the back of the thigh.

Veins.

The *veins* that accompany the branches of the profunda have the same names and distribution; they unite together to form the trunk of the profunda vein, which is superficial to the artery of the same name, separates it from the femoral, and joins the femoral vein.

Obturator Nerve

The *obturator nerve* for the supply of the internal muscles of the thigh, the anterior crural being distributed to the ex-

ternal, is a branch of the lumbar plexus, and leaves the pelvis by the sub-pubic aperture in the upper part of the thyroid foramen; in the thigh it lies beneath the pectineus, and rests on the upper part of the obturator externus muscle, it is then joined by the filament from the accessory to the obturator, and divides into a superficial portion which passes over the adductor brevis, and a deep, which lies beneath it, and from these the branches to the muscles are given off. Whilst the nerve is passing through the aperture it gives two or more branches to the obturator externus muscle, which will be seen with the dissection of the artery; and a branch to the articulation with the vessels on the inner side, but this may be very small, or even absent, if the branch to the articulation from the accessory is large.

in the Thigh.

Branches to the Obturator and Articulation.

The superficial portion, lying in front of the adductor brevis, gives off a branch to the under surface of the pectineus when this muscle is not supplied by the accessory; another to the adductor longus, which is divided in detaching the muscle; a third to the gracilis, which enters its outer surface, and occasionally there is a filament from this division to the adductor brevis muscle. The most remarkable branch from it is the long *cutaneous nerve*, which continues beneath the adductor longus muscle to its inferior border, and gives off one or more branches round this border near its insertion into the femur, to join in the plexus* formed in the middle of the thigh between this nerve and the accessory of the saphenus, or the branch from the internal saphenus when this is absent; the nerve then descends through the thigh along the inner border of the sartorius, perforates the fascia lata opposite the knee or a little below it, joins with the internal cutaneous as well as the saphenus — with the former near the knee, and with the posterior branch of the latter after it appears below the sartorius — then descends in the leg to its lower third, and ends in the integuments. As this nerve lies beneath the fascia it gives off cutaneous branches through it, and the largest of these is in the upper third of the thigh. This nerve sometimes joins with the plexus at the lower border of the adductor longus, next turns forwards to the femoral artery, running on it into the popliteal space, and gives a filament to unite with the articular branch of the nerve to the vastus internus muscle from the anterior crural.

From superficial division.

To Pectineus.

Adductor longus.

Gracilis.

Cutaneous Nerve.

The deep portion of the nerve will be exposed by detaching the adductor brevis near its origin, turning it forwards, and

From deep division.

* This plexus is described with the accessory nerve of the saphenus, p. 647. In some subjects the obturator appears to enter altogether into the plexus, and in these instances the long cutaneous nerve is a trunk resulting from the union of branches of the accessory of the saphenus, or of the nerve of the internal saphenus, with those from the obturator.

removing the cellular membrane from the branches; it descends beneath the adductor brevis, or between it and the adductor magnus, with the descending branch of the internal circumflex artery, and divides into branches to supply the adductor brevis and adductor magnus muscles. One branch from it, which appears as if it were distributed to the substance of the adductor magnus, is an *articular nerve* of the knee-joint*, which descends towards the linea aspera, perforates the insertion of the muscle about its lower third, comes into contact with the popliteal artery which it surrounds, and gives off an internal branch that enters the articulation of the knee through the posterior proper ligament. Sometimes the nerve appears again on the front of the adductor, near the opening in it for the femoral artery, then accompanies the vessel into the popliteal space, and is distributed as before described.

To Adductor brevis and magnus. Articular Nerve.

Dissector. Remove now the cellular membrane and fascia from the surface of the adductor magnus muscle, and the descending muscular branch of the internal circumflex artery is seen. Clean, in like manner, the surface of the obturator externus muscle, as well as the insertion of the united portion of the psoas and iliacus.

Adductor magnus Muscle. The *adductor magnus muscle,* triangular in shape, is the largest and thickest of the adductors, and from its extensive attachment to the femur, being inserted into it nearly from one end to the other, serves as a partition between the muscles on the anterior and posterior surfaces of the thigh — the other adductors and the vastus internus being in front of it, and the gluteus maximus, short head of the biceps, and vastus externus behind it. It consists of two portions with fibres of different directions: an upper, fixed to the rami of the pubes and ischium, which is attached to the linea aspera by a wide muscular part; and a lower, to the tuberosity of the ischium, which ends in a strong roundish tendon inserted into the inner condyle of the femur.

Origin. The muscle *arises* from the tuberosity of the ischium by strong fibres, from the ascending ramus of the same bone, and from the descending ramus of the pubes, this attachment having the gracilis internal, and the other adductors and obturator external to it. From this origin, the fibres radiate to their insertion; thus the upper, from the pubes, pass horizontally outwards behind the small trochanter of the femur to be *inserted* into the line leading from the linea aspera to the great trochanter, as well as into the lower part of the linea quadrata, and these

Insertion.

* The trunk of this nerve is partly described by Schmidt (op. cit. § xxxix.), who says: "Medius ramus inter musculum adductorem brevem et magnum inseritur, et ad flexuram genu usque decurrit." But the extension of the nerve into the popliteal space, and its distribution to the popliteal vessels and knee-joint, were first noticed by Dr. Alexander Thomson: No. 95. of the *London Medical and Surgical Journal.*

extend as high as the insertion of the quadratus femoris into this line; the middle, from the ramus of the ischium, pass downwards with different degrees of obliquity, and are *inserted* into the whole length of the linea aspera, and slightly into the line leading from it to the inner condyle, these last lying between the femoral artery and the bone at the opening in the muscle; whilst the inferior, from the tuberosity of the ischium, end about the lower third of the thigh in a strong thick tendon, which, diminishing in size as it descends, forms the inner boundary of the opening for the femoral artery, and is *inserted* by an aponeurotic expansion into the line leading from the linea aspera to the inner condyle, and by a rounded tendinous process into a tubercle on the posterior part of the inner condyle, close above the attachment of the gastrocnemius, and above and behind the internal lateral ligament. The anterior surface of the muscle is covered by the adductor brevis and adductor longus, by the pectineus, by the descending branch of the internal circumflex artery, and deep branch of the obturator nerve, and by the profunda vessels. About the commencement of the lower third of the thigh is the large tendinous aperture for the femoral vessels, and near the bone, other smaller ones for the perforating arteries. The posterior surface is in relation with the hamstring muscles, and with the great sciatic nerve. The upper border overlaps the obturator externus, and, as will be seen in the dissection of the back of the thigh, is parallel to the quadratus femoris muscle, only the internal circumflex vessels passing between the two; and the lower or inner is in contact with the gracilis to the opening for the femoral vessels, but below that point to the insertion, with the sartorius muscle, and is crossed by the great saphenus nerve, and superficial branch of the anastomotic artery. The attachment to the linea aspera is united with the tendons of the other muscles inserted into it; and the aponeurotic portion, connected to the line leading to the inner condyle, gives attachment to the vastus internus, serves as an internal intermuscular septum, and the superior internal articular vessels perforate it to reach the front of the joint.

Relations.

The *psoas and iliacus muscles*, separate in the abdomen, pass from this cavity beneath Poupart's ligament, and are inserted into the femur as one muscle. As they lie beneath the ligament they occupy the interval between the ilio-pectineal eminence and the anterior superior spinous process of the ilium, and the psoas, placed to the inner side, presents a tendon which receives by its outer and anterior part the fleshy fibres of the iliacus; thus united, they pass downwards and inwards behind the femoral vessels, and are *inserted* by a tendon into the posterior part of the small trochanter, also by some fleshy fibres into the anterior surface of the bone below this prominence. This united portion of the muscles is superficial in the greatest part of its

Psoas and Iliacus in the Thigh.

Insertion.

Relations.

extent in the thigh; and close below the ligament the femoral artery is on the part corresponding to the psoas, and the anterior crural nerve in the line between the two. The outer border corresponds to the sartorius, and, at its insertion, to the vastus internus; and the inner, to the pectineus, the internal circumflex vessels passing between the two. Cut through the muscles; they will be seen to cover the anterior and inner parts of the ilio-femoral articulation, also the surface of the ilium, separated, however, by a large synovial membrane: the iliacus partly conceals the attachment of the rectus to the anterior inferior spinous process of the ilium.

Obturator externus Muscle.

The *obturator externus* is a conically shaped muscle, the base at the obturator foramen, and the apex directed backwards to the pit at the root of the great trochanter: and to obtain a good view of it, part of the origin of the adductor magnus should be

Origin.

cut from the ramus of the pubes. It *arises* from the cutaneous or femoral surface of the obturator membrane, except the portion near the acetabulum and the aperture in its upper part, from the surface of the ischium and the pubes bounding internally the thyroid or obturator foramen, and this attachment is external to the adductor muscles: the fibres are directed downwards and backwards from the internal or wide portion of the muscle, surround the lower part of the articulation of the hip-joint, and end in a tendon which is *inserted* into the pit at the root of the great trochanter. The muscle is covered by the pectineus, adductor brevis, and upper origin of the adductor magnus; the obturator nerve also lies on it; and it conceals the obturator membrane, obturator vessels, and, partly, the obturator nerve which comes through the sub-pubic aperture above its attachment. The inner half of the osseous circumference of the foramen gives origin to the muscle, but the outer, next the acetabulum, has no fibres attached to it.

Insertion.

Relations.

Detach the muscle from the pelvis, and the obturator artery, and the branches of the nerve which supply the muscle, will be exposed.

Obturator Artery.

The *obturator artery* is a branch of the internal iliac in the pelvis, and leaves the cavity by the sub-pubic aperture in the upper part of the obturator or thyroid foramen. As it is passing through the aperture it divides into a superior and an

Superior division.

inferior branch: the *superior* continues in the aperture with the obturator nerve, turns upwards and inwards beneath the muscle, encircling the inner half of the membrane, and terminates at the descending ramus of the ischium by a few small branches which perforate the muscle, and are distributed to the gracilis and upper attachments of the muscles to the pubes: it also supplies the obturator muscle, and sends a few branches upwards on the pubes to anastomose with the internal circumflex

Inferior.

artery. The *inferior division* perforates obliquely the membrane

with the branches of the nerve, descends beneath the muscle to the tuberosity of the ischium, circumscribing the lower or posterior half of the membrane, and terminates by dividing into two branches: one perforates the obturator muscle and ends in the origin of the adductor magnus; the other, very small, ascends to anastomose with the upper division of the artery. This division gives also a branch to the hip-joint, which enters it beneath the transverse ligament.

The principal branches from the obturator nerve to the obturator externus muscle are now seen to descend with the lower division of the obturator artery, and perforate obliquely the fibres of the membrane. Branches of the Nerve.

DISSECTION OF THE BACK OF THE THIGH.

The dissection of the front of the thigh being completed, that of the posterior part should follow, instead of that of the front of the leg, and the dissector should endeavour to complete the front by the time appointed for turning over the body. For the dissection of this part the subject lies on the face, the pelvis being raised by blocks to a height sufficient to make the buttocks tense, and the legs may hang over the end of the table. Make an incision along the centre of the sacrum, from the lower extremity of this or tip of the coccyx carry another downwards and outwards on the thigh, in the direction of the great trochanter but below it, and continue it to six inches below this prominence of bone; divide, next, the integuments along the crest of the ilium, and raise the skin from the part marked out by the incisions. Seek, now, the cutaneous nerves in the cellular membrane; in the middle line are the small branches of the sacral; crossing the crest of the ilium, in a line with the outer border of the erector spinæ, are branches of the lumbar nerves; in front of these, a cutaneous branch from the last dorsal, and sometimes from one of the nerves of the lumbar plexus; and near the anterior termination of the crest is the posterior branch of the external cutaneous. Some cutaneous branches from the small sciatic turn up over the lower border of the muscle, near the line of incision in the skin, and others perforate the muscular fibres. Should only the dissection of the muscle be desired, raise skin and integuments from it at the same time, using the knife in the direction of the fibres from the sacrum to the trochanter, and beginning below on the left side, but above, and at some distance below the crest of the ilium on the right. Dissection.

The *cutaneous filaments* of the posterior branches of the *sacral* Cutaneous

Nerves of the Sacral. *nerves* appear in the middle line of the body, and are accompanied by small cutaneous arteries: they are described with the cutaneous nerves in the dissection of the back.

Of the Lumbar Spinal. The *cutaneous branches* of the posterior divisions of the *lumbar spinal nerves* cross the crest of the ilium close to the bone, and near to the attachment of the erector spinæ muscle to this part. They are distributed to the integuments over the gluteus maximus, or to the upper and inner part of the buttock; some of them may be followed down nearly to the trochanter major.

Of the last Dorsal, The *cutaneous branch* of the anterior division of the *last dorsal nerve*, distributed in the wall of the abdomen, descends over the crest of the ilium, in front of those from the lumbar nerves, or about the middle of this border of the bone, and divides into many branches which radiate and supply the integuments over the gluteus medius and gluteus maximus, or the middle and upper part of the space now exposed. Occasionally, the ilio-inguinal nerve of the lumbar plexus sends another cutaneous branch over the crest, and it is situated about midway between that from the last dorsal, and those from the lumbar nerves.

and Ilio-inguinal.

Of the external Cutaneous. The *posterior cutaneous branch* of the external cutaneous of the thigh has been seen to leave the trunk of the nerve at the anterior superior spinous process of the ilium; it passes backwards over the tensor vaginæ femoris to the integuments over the gluteus medius muscle, or to the anterior and upper part of this region.

Of the small Sciatic. The *cutaneous branches* of the *small sciatic* nerve, two or three in number, come from beneath the lower border of the gluteus maximus, perforate the fascia, and are directed upwards and outwards, supplying the integuments over the lower part of the muscle, and a filament is sent externally towards the great trochanter. At the lower border of the muscle are also seen other cutaneous branches from the same nerve; one to the perinæal space, the inferior pudendal (Soemmering), and some to the integuments of the inner, and sometimes the outer side of the thigh: the continuation of the nerve descends beneath the fascia. The remaining nerves of the small sciatic, that perforate the substance of the gluteus, are minute, and are found with more difficulty than the others.

Dissection. Take away the subcutaneous cellular membrane from the surface of the gluteus maximus, and also the thin fascia lata that covers it; but in front of the muscle the fascia should remain. To do this more readily, separate the limb from the other, rotate it inwards, and begin, as before directed, either at the upper or lower border, according to the side. The separation of the integuments and fascia from the coarse fasciculi of the gluteus is very difficult, and will require some attention and care to accomplish it: be careful of the nerves of the small sciatic at the lower border of the muscle.

The *fascia lata* continued upwards from the thigh is attached to the crest of the ilium, and is greatly thicker over the gluteus medius than maximus muscle; it is much strengthened below by the insertion of a considerable part of the gluteus maximus into the aponeurotic fibres, and at the upper border of this muscle it divides into two layers, to incase it; the one above is thin, and fixed to the spines of the sacrum. Fascia lata.

The *gluteus maximus*, the largest muscle of the buttock and somewhat square in shape, reaches from the side of the sacrum to the upper part of the femur, forming the prominence of this part, and assisting powerfully to keep the body erect on the thigh. There is a great similarity between the gluteus and the deltoid in position, use, and texture. Its borders look upwards and downwards. The muscle *arises* from the outer lip of the posterior fifth of the crest of the ilium, from the impression on the outer surface of the same bone, near the posterior angle, from the sacro-iliac ligaments, from the ridge of tubercles on the sacrum, external to the foramina and corresponding to the transverse processes of the vertebræ, from the lateral part of the coccyx, and from the great sacro-sciatic ligament on which it lies, — this attachment corresponding to that of the erector spinæ. From this origin the fibres pass outwards and downwards, the two upper thirds of them being *inserted* by aponeurotic fibres into the fascia lata over the great trochanter of the femur, and the lower third into a rough surface on the femur in the line which leads from the linea aspera to this process of bone, being situated between the vastus externus and adductor magnus muscles. The cutaneous surface of the muscle is covered only by the integument, fascia, and cutaneous nerves. The upper border is short, thin, and connected to the strong fascia covering the gluteus medius muscle; but the lower border, more oblique, is longer and thicker, assists to form the outer boundary of the perinæal space, and crosses the hamstring muscles, and sciatic vessels and nerves. Gluteus maximus Muscle. Origin. Insertion. Relations.

To see the parts covered by the gluteus, divide it near its origin by a vertical incision from the upper to the lower border, and in cutting through the lower part take care of the great sacro-sciatic ligament beneath; a cellular interval between it and the medius will point out the depth to pass in separating the two muscles; or it will be more prudent, sometimes, to pass the handle of the scalpel between them. Take away the upper portion or origin of the muscle, and throw down the lower part to its insertion, by dissecting close to its fibres, and detach from it the small vessels and nerves that it receives by its under surface. Remove very carefully the loose cellular membrane which fills the interval between the sacrum and trochanter, and the parts to be looked for or avoided are seen, below, in the enumeration of the parts covered by the gluteus: the limb is to Dissection.

be well rotated inwards whilst doing this. Clean the tuberosity of the ischium and upper part of the hamstring muscles.

Parts covered by the Gluteus.

The gluteus maximus covers, by its inner attachment, the posterior part of the os ilii, a portion of the sacrum and coccyx, the great sacro-sciatic ligament, the tuberosity of the ischium from which it is often separated by a bursa, and the upper attachment of the hamstring muscles; by its outer, part of the femur and the great trochanter, a large bursa being placed between it and this process of bone. The intervening portion of the gluteus conceals the numerous muscles, vessels, and nerves seen in the hollow between these prominences of bone, viz. beginning above, part of the gluteus medius, then the pyriformis, and between them the gluteal artery, which gives a superficial branch to the gluteus maximus, and the superior gluteal nerve, which is deeper. Below the pyriformis, are the parts coming from the pelvis through the lower part of the sciatic notch, viz. the sciatic artery, which descends between the trochanter and tuberosity of the ischium; the pudic, which is internal to the sciatic and disappears by passing through the small sciatic notch; the great sciatic nerve, the small sciatic nerve accompanying the greater; the pudic nerve, the branch to the obturator internus muscle from the sacral plexus of nerves, and sometimes the inferior hæmorrhoidal nerve from the same source: the three last nerves cross the spine of the ischium, and accompany the pudic artery through the small sciatic notch. Still lower down is the white shining tendon of the obturator internus muscle with a fleshy fasciculus above and below it, or the gemelli muscles, the upper is not unfrequently absent; these lie on the articulation of the hip, and a small nerve to the quadratus muscle is beneath them. Next follows the quadratus femoris muscle, the tendon of the obturator externus being seen between its upper border and the inferior gemellus; and below the quadratus is the attachment of the upper part of the adductor magnus to the femur, the terminal branch of the internal circumflex artery escaping between the contiguous borders of the two muscles. External to the adductor, the gluteus covers part of the vastus externus.

Remove the fascia lata from the front of the gluteus medius muscle.

Gluteus medius Muscle.

The *gluteus medius* is a triangularly shaped muscle situated on the outer surface of the os innominatum, the base being attached to this bone, and the apex to the great trochanter.

Origin.

The *origin* of the muscle, which will be better seen when it is detached, is from the outer surface of the os ilii included between the superior semicircular line, the crest of this bone, and the portion to which the gluteus maximus is attached; and also from the strong fascia that covers the muscle; the fibres, less coarse than those of the maximus, pass downwards converging

to a tendon in the centre of the muscle and extended along the posterior border, which is *inserted* into an impression on the outer surface of the great trochanter, and is prolonged downwards and forwards to unite with the tendon of insertion of the gluteus minimus; a synovial bursa separates it from the great trochanter. This muscle is covered in its upper part only by the fascia lata, but below by the gluteus maximus. The anterior border, directed downwards and backwards, joins, above, by continuity of fibre with the tensor vaginæ femoris, and below it overlays the outer head of the rectus; the posterior is parallel to the pyriformis, but separated by the gluteal artery, and sometimes the gluteus minimus projects beyond it. Detach the origin from the bone without injuring the gluteal artery and superior gluteal nerve beneath it, and the muscle is seen to cover the gluteus minimus, and branches of the gluteal artery and superior gluteal nerve between the two, as well as the surface of the bone to which it is attached.

Insertion. Relations.

The *gluteal artery*, sufficiently exposed by removing the cellular membrane from it, is the largest of the parietal branches of the internal iliac, distributed on the outer side of the pelvis. It is a short thick trunk, which escapes from the pelvis above the pyriformis muscle, and close against the osseous margin of the upper part of the sciatic notch, and divides into a superficial and a deep branch. The *superficial branch* comes forwards between the gluteus medius and pyriformis, and divides into branches which enter the under surface of the gluteus maximus, anastomosing in it with branches of the sciatic, whilst others turn inwards to the sacrum and coccyx, and perforate the great sacro-sciatic ligament to reach the integuments. The *deep branch*, the larger division of the artery, lies deeply between the gluteus medius and minimus, and gives off a branch along the upper attachment of the gluteus minimus, others across its centre, and two or three smaller ones beneath the muscle. The first of these arteries extends along the upper margin of the muscle, accompanied by the upper branch of the superior gluteal nerve, to the anterior superior spinous process of the ilium, and anastomoses with the ascending branches of the external circumflex artery; the second set cross the centre of the gluteus, with the lower division of the superior gluteal nerve, to reach the anterior inferior spinous process of the ilium and front of the great trochanter, where they inosculate also with the ascending branches of the external circumflex; and the third set, the smallest and deepest, to be seen when the gluteus minimus is removed, perforate the substance of the muscle, and lying on the capsule send branches to it, whilst others pass forwards to the anterior inferior spinous process, and join those of the external circumflex.

Gluteal Artery. Superficial branch. Deep.

The branches of veins with this artery join in the gluteal vein, which opens into the internal iliac vein.

Vein.

Superior Gluteal Nerve.

The *superior gluteal nerve*, from the lumbo-sacral or communicating nerve between the lumbar and sacral plexus, leaves the pelvis with the gluteal artery through the upper part of the sciatic notch, and above the pyriformis muscle. The nerve does not then become superficial to supply the gluteus maximus, but, being deeply placed between the gluteus medius and minimus, divides into branches; the *upper* accompanies the superior branch of the gluteal artery between the two muscles, to which it is distributed; the *lower* set, consisting of two, cross the centre of the gluteus minimus with the inferior branch of the artery, and at the anterior border, one perforates the united fibres of the glutei muscles, enters the sheath of the tensor vaginæ femoris, and supplies the under surface of this muscle, in which it may be followed to its lower part; whilst the other is distributed to the glutei between which it lies.

Gluteus minimus Muscle. Origin.

The *gluteus minimus*, a small conically shaped muscle, is placed beneath the gluteus medius, and is exposed by the removal of the cellular membrane. It *arises* from the surface of the dorsum of the ilium included between the superior and inferior curved lines; the fibres converge, below, to a tendon,

Insertion.

which, placed on the cutaneous surface, is *inserted* into the fore part of the upper border of the great trochanter, and joins, by being prolonged downwards and forwards, the anterior border of

Relations.

the tendon of the gluteus medius. The cutaneous surface is covered by the other glutei. The anterior border, directed backwards, is united to the gluteus medius, and the posterior touches the pyriformis muscle, and the gluteal vessels and nerve. Throw down the muscle from its upper attachment, and it will be found to cover the capsule of the hip-joint, the portion of the ilium between the origin of the muscle and the attachment of the capsule, the external tendon of the rectus, together with the deep branches of arteries.

Outer head of Rectus.

The *outer* tendinous *head of the rectus* femoris, now exposed, is fixed to the groove in the os innominatum, close to the upper and outer half of the margin of the acetabulum, and as far forwards as to the anterior inferior spinous process, where it is unattached, and joins the other from that process; the lower border of the tendon is united to the fibrous capsule of the articulation.

Deep gluteal branches.

The deep branches of the gluteal artery are now seen to anastomose with the external circumflex, and to send branches to the bone and to the articulation of the hip.

Pyriformis Muscle.

The *pyriformis muscle*, so called from its shape, is contained in part within the pelvis, and a portion is external to this cavity. The pelvic part, large and muscular, arises by three or four processes from the front of the sacrum, and is dissected with the pelvis; the portion external to the cavity is a thick roundish muscle, whose fibres soon end in a long tendon, which is directed

Insertion.

outwards to be *inserted* into the posterior part of the upper border of the great trochanter, behind the tendon of the gluteus

minimus, with which it is frequently united. As the muscle passes through the sciatic notch it divides the space into two parts, the gluteal vessels and nerve passing through the upper, and the sciatic and pudic vessels and nerves through the lower. It is covered by the gluteus maximus. The upper border is parallel to the gluteus medius, only the gluteal vessels and nerve interposing; and the lower to the gemellus inferior, but separated by the sciatic and pudic vessels and nerves: cut across the muscle, and raise it to see that it lies on the vessels and nerves escaping beneath it, and on the bone and capsule of the hip-joint; it is connected by fibres to the great sacro-sciatic ligament, and upper boundary of the sciatic notch, and its nerve perforates the under surface of the muscle. Relations.

The *sciatic artery*, arising from the internal iliac, is another of the branches to the wall of the pelvis, and is the next largest to the gluteal. It escapes from the pelvis below the pyriformis muscle with the nerves of the same name, and descending, internal to the great sciatic nerve, in the interval between the tuberosity of the ischium and great trochanter, passes over the gemelli and obturator muscles, and reaches the quadratus femoris, opposite which it finally divides into branches: some of these pass inwards, ramifying on the tuberosity of the ischium; one outwards, beneath the nerve, to join the branch of the internal circumflex, which ascends to the pit at the root of the great trochanter; whilst another artery, in direction the continuation of the trunk, descends to anastomose with that branch of the internal circumflex, which, appearing between the quadratus and adductor magnus, is distributed to the hamstring muscles. The artery gives off other named branches in its course: the first of these is the *coccygeal branch*, of considerable size, which leaves it soon after it has quitted the pelvis, turns backwards to reach the cutaneous surface of the sacrum and coccyx by perforating the great sacro-sciatic ligament and attachment of the gluteus maximus, and ramifies in this muscle and on the sacrum, anastomosing with the gluteal. The branch to the *sciatic nerve*, a very small and slender artery, enters the sheath of the great sciatic nerve, and continues with it in its course through the thigh; its point of origin is irregular, but generally between the tuberosity of the ischium and the great trochanter. The *branch to the quadratus muscle* passes with the branch of the nerve beneath the gemelli and obturator, close to the articulation, to which it sends also many small branches. The sciatic gives, also, many *muscular* branches to the gluteus maximus and external rotator muscles, as well as to the articulation of the hip. Sciatic Artery. Branches. Coccygeal branch. To the Sciatic Nerve. To the Quadratus Muscle. Muscular.

The *small sciatic nerve*, one of the terminal branches of the sacral plexus distributed to the thigh, commences in the plexus by one or two portions, which may unite together in one nerve, Small Sciatic Nerve.

or remain separate. It leaves the pelvis through the lower part of the great sciatic notch, below the pyriformis muscle, with the great sciatic nerve, to the inner side of which it is placed, follows the course of the sciatic artery between the trochanter and tuberosity, lying on the external rotators, and gives off muscular branches to the gluteus maximus, and cutaneous, at its lower border, to the integuments of the buttock, thigh, and perinæum. The trunk of the nerve, much diminished in size, escapes beneath the lower border of the gluteus maximus, and descends along the thigh, beneath the fascia, to the upper part of the leg, where it becomes cutaneous, and will be afterwards followed.

Muscular branches. Inferior Gluteal. Cutaneous. Inferior Pudendal.

The muscular branches of the nerve are distributed to the gluteus maximus, and are named *inferior gluteal;* these enter the under surface of the muscle, some reaching to near the upper part, but the greater number, and the largest, enter it near the lower border. The chief of the cutaneous branches is the *long inferior pudendal* (Soemmering), which, frequently a separate branch from the sacral plexus, runs downwards beneath the gluteus, then turns inwards at its lower border, forming an arch below the tuberosity of the ischium; it is now continued forwards beneath the fascia along the upper and inner part of the thigh, perforates the fascia about an inch in front of the tuberosity of the ischium and near the margin of the ramus of this bone, and is distributed to the integuments of the perinæum and scrotum. In its course it gives many small cutaneous branches to the integuments of the inner and upper part of the thigh, or these may be separate filaments from the sciatic. The remaining cutaneous branches generally come from the trunk whilst it is covered by the gluteus, descend to its lower border, turn round it, perforate the fascia, and are directed upwards and outwards to the integuments of the gluteal region. Occasionally, another cutaneous branch appears on the surface of the fascia at the border of the muscle, and descends on the outer part of the thigh to about its middle.

To Gluteal region. To the Thigh.

Large Sciatic Nerve.

The *large sciatic nerve*, in which the sacral plexus seems to terminate, leaves the pelvis with the small sciatic below the pyriformis muscle, runs in the same direction with it between the tuberosity of the ischium and great trochanter, and finally descends through the thigh, beneath the fascia, to near the popliteal space, where it divides into the external and internal popliteal nerves. In the part of its course as far as the gluteus maximus, it lies deeply, but it is more superficial as it descends in the thigh. It is covered by the gluteus maximus, by the superficial branches of the small sciatic artery and sciatic nerve, and opposite the insertion of the gluteus it is crossed by the long head of the biceps muscle; and the nerve lies on the gemelli and tendon of the obturator internus, on the quadratus femoris,

and below these, on the adductor magnus muscle, which relation is maintained to the popliteal space. It is not uncommon to find this nerve divided into two large trunks at its exit from the pelvis, one of them passing through the substance of the pyriformis muscle. The branches of this part of the nerve supply two of the small rotator muscles, and the articulation. Branches.

The *articular branches*, very small, may come either from the sciatic, or from the sacral plexus; they run on the surface of the capsule, and then perforate it to supply the articulation. Articular.

The *nerve* to the *quadratus* and *inferior gemellus* leaves the under surface of the sciatic soon after its commencement, descends parallel to the trunk, either on its inner side or beneath it, to the superior gemellus, then passes close to the capsule of the hip-joint, beneath the gemelli and obturator tendon, with the branch of the sciatic artery, and divides beneath the quadratus into branches to supply this muscle, the inferior gemellus, and the articulation. The branch gives off an *articular filament* in its upper part, which passes outwards and perforates the capsule. This nerve may arise from the sacral plexus. To the Quadratus and Gemellus. Articular.

The *nerve* to the *superior gemellus*, very small and frequently removed, comes from the sacral plexus with the pudic and obturator nerves, runs parallel with them as far as to the spine of the ischium, and then turns outwards to the muscle. To superior Gemellus.

The *pudic artery*, also a branch of the internal iliac, and now seen in that part of its course which is external to the pelvis, on the spine of the ischium, leaves the pelvis with the sciatic, below the pyriformis, turns over the spine of the ischium, passes through the small sciatic notch with the pudic, obturator, and hæmorrhoidal nerves, and is then directed forwards in the perinæal space, supplying the perinæum and external parts of generation. Soon after it has left the pelvis it sends backwards some small branches to the sacrum, which anastomose with the other branches supplied to this part by the gluteal and sciatic arteries. Pudic Artery.

The *pudic nerve*, a branch of the sacral plexus, passes from the pelvis, below the pyriformis, with the artery which it accompanies through the small sciatic notch, lying internal to it, or nearer the sacrum, and is distributed like it. The anatomy of both these is seen in the perinæum. Pudic Nerve.

The *nerve* to the *obturator internus muscle*, a small branch from the lower part of the sacral plexus, passes with the pudic nerve through the small sciatic notch, and is distributed to the pelvic surface of the muscle with a small artery from the pudic: this is seen on the inner side of the tuberosity of the ischium. Nerve to Obturator.

The *inferior hæmorrhoidal nerve*, also sometimes a branch from the sacral plexus, accompanies the pudic through the small sciatic notch, and, after lying for a short distance against the outer wall of the ischio-rectal fossa, perforates the fascia that Inferior Hæmorrhoidal Nerve.

binds it down, and supplies the sphincter ani and integuments of the perinæum. This nerve is frequently only a branch of the pudic in the perinæal space.

Veins. The branches of the veins with the arteries join into larger trunks of the same name as the vessels, and unite with the internal iliac vein.

Dissection. To see the following small rotator muscles, it will be necessary to hook aside the sciatic nerves, and, if necessary, the vessels may be cut away. Separate the gemelli from the tendon of the obturator internus muscle, and keep the limb rotated inwards.

Gemellus superior Muscle. Origin. Insertion. The *gemellus superior muscle* lies above the tendon of the obturator internus, and is sometimes wanting. It *arises* from the spine of the ischium, above the groove for the tendon of the obturator: the fleshy fibres extend along the upper border of the obturator tendon, which the muscle joins, and are *inserted* with it into the root of the great trochanter.

Gemellus inferior. Origin. Insertion. Relations. The *gemellus inferior*, larger than the preceding, and much increased in size when the superior is abent, *arises* from the upper and posterior part of the tuberosity of the ischium, above the insertion of the great sacro-sciatic ligament. The fibres run outwards, and end in a tendon, which joins with that of the obturator internus, and is *inserted* with it into the root of the great trochanter. This muscle is wider than the superior, and receives the tendon of the obturator in a kind of groove: it lies below the obturator, and above the quadratus, but at its insertion the tendon of the obturator externus is in contact with it.

Obturator internus Muscle. Insertion. Relations. The *obturator internus muscle*, like the pyramidalis, arises in the pelvis, turns over the hollowed margin of bone corresponding to the small sciatic notch, and is then reflected outwards over the posterior part of the articulation of the hip, almost parallel to the part in the pelvis, and is *inserted* with the gemelli into the root of the great trochanter of the femur, above the pit for the obturator externus, and somewhat farther forwards than the tendon of the pyramidalis. The part of the muscle external to the pelvis is at first fleshy, but it soon ends in a tendon, and along its upper border is placed the superior gemellus, whilst along the lower is the inferior gemellus, interposed between it and the quadratus and obturator externus. The obturator and the gemelli are covered by the gluteus maximus, by the great and small sciatic nerves, and the sciatic artery; and passing through the small sciatic notch with it are the pudic artery and nerve, and the obturator and hæmorrhoidal nerves. Cut through the tendon near the insertion, and raise the muscle; it is seen to lie on the ischium, capsule of the joint, and the gemelli, and where the tendon rests on the bone, it is divided into four or five tendinous processes, continued into the fleshy part of the muscle, and these are enveloped by the synovial membrane which is placed between them and the bone: the surface of the

bone, moreover, presents elevations of cartilage, corresponding to the intervals between the tendons.

Quadratus femoris

The *quadratus femoris muscle* is of a square shape, and is situated between the inferior gemellus and the adductor magnus. It *arises* internally from a ridge on the outer part of the tuberosity of the ischium, close to the origin of the semi-membranous muscle, and the fibres run outwards to be *inserted* into the linea quadrata, or line that leads from the great trochanter to the linea aspera, above the attachment of the adductor magnus to the same line. By the cutaneous surface it is covered by the parts between the great trochanter and tuberosity of the ischium, viz. by the great and small sciatic nerves, by the sciatic artery, also by the gluteus maximus and semi-membranosus muscles. The upper border is parallel to the inferior gemellus; and the lower, to the adductor magnus, the terminating branch of the internal circumflex artery being between the two. Divide the muscle near the insertion, and throw it inwards; it lies on the obturator externus muscle, the ascending branch of the internal circumflex artery to the pit of the great trochanter, and the branch of nerve to the upper and inner part of the muscle, which will be more readily followed by cutting through the gemelli muscles.

Muscle. Origin. Insertion. Relations.

Internal Circumflex Artery.

The *internal circumflex artery* of the profunda, before traced to the back of the thigh, divides into two branches: one ascends, beneath the quadratus, with the tendon of the obturator externus, to the pit at the root of the great trochanter, and divides into branches that anastomose with the gluteal, external circumflex, and sciatic, and supply the bone; the other continues backwards between the quadratus and adductor magnus muscles, is distributed to the hamstrings, and anastomoses with the sciatic artery.

Obturator externus

The *obturator externus muscle*, before seen in the front of the thigh to arise from the obturator membrane and to pass below the hip-joint, is observed in this dissection to ascend obliquely outwards over the articulation, and to be *inserted* by a tendon into the pit at the root of the great trochanter. This part of the muscle is covered by the quadratus femoris, and surrounds the lower part of the joint, lying in the hollow between the acetabulum and tuberosity of the ischium. Its upper border is parallel, near its insertion, to the inferior gemellus, which separates it from the obturator internus; and the lower is in relation, near the origin, with the adductor magnus.

Muscle. Insertion. Relations.

Sacro-sciatic Ligaments.

The *sacro-sciatic ligaments* are attached to the sacrum and ischium, closing the pelvis behind, and are exposed by the removal of the gluteus maximus. The *great* or *posterior* is attached, internally, to the posterior inferior iliac spine, to the side of the sacrum and its lateral row of tubercles, and to the side of the coccyx; from this attachment the ligament extends outwards, closing, below, the large space between the os innomi-

Great.

natum, sacrum, and coccyx, to be inserted into the inner surface and lower part of the great tuberosity of the ischium; from this insertion a process is continued upwards along the ramus of this bone, and is connected to the obturator fascia by its inner thin margin. This ligament is wide at its sacral attachment, contracted in the centre, and expanded again at its other extremity. The cutaneous surface is covered by the gluteus maximus to which it gives origin, and is perforated by the coccygeal branch of the sciatic artery; and the deep is in contact with the small or anterior sacro-sciatic ligament. Divide it near the attachment to the ischium to expose the other.

Small. The *small* or *anterior ligament*, much thinner than the posterior and wide internally, is attached to the side of the sacrum and coccyx, but not so extensively as the other, and rather external to it, and is moreover united to the great ligament which is superficial to it: the fibres are directed outwards, and converge to the spine of the ischium, into which they are inserted. It is covered by the great sacro-sciatic, and lies on the coccygeus muscle. The space at the back of the pelvis, included between the posterior border of the os innominatum on the outer side, the sacrum and coccyx on the inner, and the great sacro-sciatic ligament below, is divided into two by the small sacro-sciatic ligament: the upper, the large sciatic notch, transmits the pyramidalis muscle, — the gluteal vessels and superior gluteal nerve being above it, and the great and small sciatic nerves and vessels, the pudic vessels and nerve, with the hæmorrhoidal and obturator nerves, below it; and the lower, the small sciatic notch, allows the obturator internus muscle, with the pudic vessels, and the pudic, obturator, and hæmorrhoidal nerves, to pass through it.

Dissection. Divide the integuments along the centre of the thigh *, and extend the incision to about four inches below the knee; at its lower extremity make a transverse cut to allow the skin to be reflected to each side. Seek the small cutaneous nerves, which are only portions of nerves before seen, as stated below.

Cutaneous Nerves of the back of the Thigh. No separate cutaneous nerves supply the integument of the posterior part of the thigh, but filaments to it are derived from the nerves on the front, and from the small sciatic; thus on the inner side are some cutaneous filaments from the accessory of the saphenus, and near the knee, some from the cutaneous branch of the obturator, which pass backwards over the inner part of the popliteal space; on the outer side the external cutaneous of the front of the thigh sends backwards some cutaneous

* Or the dissection of the popliteal space may be proceeded with before this; and if this be done, divide the integuments only over the extent of this region by a central incision, which extends upwards for one third of the femur, and downwards for one sixth of the leg; at each extremity make a transverse one, and raise the flaps.

filaments; and in the middle line are some very small filaments from the continuation of the small sciatic nerve, which perforate the fascia; one of these, a little above the knee, is larger than the others, and descends over the popliteal space to the upper and posterior part of the leg.

Fascia lata.

The *fascia lata* will be exposed by removing the cellular membrane. It invests, as on the front, the posterior part of the limb, and sends a process — the external intermuscular septum — inwards to the linea aspera; below, it is continued behind the knee to the leg, passing over the popliteal space, the boundaries of which are partly seen through the fascia. Where it covers the popliteal space it is attached to the boundaries of this region, and is moreover strengthened by transverse fibres, — the greater number being found on the outer side, and derived from the vastus externus and tendon of the biceps, and some few are given off from the tendon of the sartorius on the inner side, but these are less distinct. At this spot the fascia is frequently perforated by the short saphena vein which joins the popliteal, and branches of nerves also pass through it.

Dissection.

Instead of removing at once the fascia lata from the whole surface of the limb, raise only sufficient to dissect the popliteal space, making a central incision which extends upwards about six inches above the knee, and downwards nearly to the one in the skin; by means of two incisions at the extremities of this, the fascia may be thrown to the sides. In removing it, the dissector must avoid the small branch of the sciatic close beneath it, and, in taking away the fat which fills the space, some small articular nerves and arteries will be met with. In the middle line is the large internal popliteal nerve, giving from its inner and upper part the internal articular branches: close to the outer boundary, the external popliteal giving off nerves near the lower part, and deeper than it, and close to the outer wall, are the external articular nerves; lying in the middle line, and deeper than the nerve, are the popliteal vessels, and the superior articular branches that run transversely to the sides of the femur. In the bottom of the upper part of the space is the small articular branch of the obturator, which perforates the adductor magnus, and then descends on the artery; it also supplies the joint. When the space is clean, place the sartorius and gracilis in their natural position on the inner side, if they are detached.

The *popliteal space*, situated behind the knee-joint, is of a lozenge-shape, and extends upwards behind the femur about its lower third, and downwards on the tibia about its upper sixth; the widest part is opposite the articulation, and the deepest rather above it. Before the removal of the integument and fascia, the lateral boundaries are approximated, so that it reaches only slightly up the femur, and is limited almost to the extent of the joint. The lateral boundaries, down to the knee, consist

of the muscles of the thigh, which are inserted into the bones of the leg, and are named hamstrings, inner or outer, according to their position on the side of the space; but below this point, of the muscles of the leg attached to the condyles. Thus, on the outer side, down to the joint, is the biceps muscle, attached to nearly the whole length of the line leading to the outer condyle, and below it, the outer head of the gastrocnemius, and the plantaris; on the inner, it is bounded, as low as the knee, by the large muscular semi-membranosus muscle, with the tendon of the semi-tendinosus, which lies on it, and beneath it, or between it and the bone, by the sartorius and tendon of the gracilis; but below the articulation, only by the inner head of the gastrocnemius. The upper angle is formed by the contact of the biceps on the outer side, and the semi-tendinosus and membranosus on the inner; and the lower, by the union of the heads of the gastrocnemius. The space is covered in by the fascia lata; and the deep boundary consists of the lower part of the posterior surface of the femur, included between the lines from the linea aspera to the condyles, the posterior ligament of the joint, and the upper part of the tibia covered by the popliteus muscle. It contains the popliteal vessels and some lymphatic glands surrounding them, the divisions of the great sciatic nerve, or the external and internal popliteal, with their branches, the continuation of the small sciatic, and much cellular membrane. The short saphena vein, or cutaneous vein of the leg, enters the space to join the deep vein.

Popliteal Artery.

The *popliteal artery*, or continuation of the femoral, receives its name at the lower border of the opening in the triceps, and retains the same to the lower border of the popliteus muscle. The distinctness of the relations of the vessel, whilst beneath the gastrocnemius, or above it, readily allows of a description of it in two parts. The artery in the *upper part*, or to the point of union of the heads of the gastrocnemius, runs downwards and outwards from the inner side to the middle of the space, lying deeper in the upper part than opposite the articulation, where it approaches the surface by reason of the enlargement of the bone. In this course it is overlapped at its commencement by the belly of the semi-membranosus muscle, but, below this, is covered only by the integuments and fascia, and is separated from the surface by much cellular membrane. On the inner side is the semi-membranosus muscle partly reaching over it, and below the joint, the inner head of the gastrocnemius; on the outer, the artery is distant from the external boundary, except below, where it comes into contact with the plantaris and outer head of the gastrocnemius. It lies on the bone and posterior ligament of the articulation. The popliteal artery is accompanied by the vein of the same name, which is in close contact with it, but somewhat on the outer side; so that in looking into

Upper part.

the space, the artery is concealed by the vein on its cutaneous surface; and in the interval between the heads of the gastrocnemius, the vein is altogether superficial to the artery, since it is inclining to the inner side. Much more superficial than the artery, and slightly external to it in position, is the internal popliteal nerve, which, however, lies over it, like the vein, between the heads of the gastrocnemius, and is much closer to it. Some lymphatic glands surround the vessels.

Dissection. To see the remaining part of the popliteal vessels, cut through the inner head of the gastrocnemius muscle, raise it, and remove the cellular membrane, taking care of the small branches of the internal popliteal nerve and artery.

Lower part. The *lower part* of the artery, about two inches long, extends from the angle of union of the heads of the gastrocnemius to the lower border of the popliteus muscle, where it divides into anterior and posterior tibial arteries. It lies beneath the gastrocnemius, is crossed by the plantaris, and then enters beneath the soleus to terminate in the tibial arteries; it rests on the popliteus muscle. The popliteal vein crosses this part of the artery, lying between it and the nerve, and is placed to its inner side at the lower border of the popliteus muscle. The internal popliteal nerve also crosses superficially to the vessels, and lies to their inner side at the lower border of the popliteus, where it becomes posterior tibial, and accompanies the artery of the same name to the foot; thus both the vein and the nerve lie, above, to the outer side of the artery, but below, to the inner, and they cross it beneath the gastrocnemius muscle. The branches supplied by the artery are to the articulation and surrounding muscles: the articular arteries are five, — two superior, an internal and external, two inferior, the same, and an azygos branch that enters the back of the joint; these lie close to the surface of the bone, and pass almost transversely from the trunk.

Branches.

Superior Articular internal. The *superior internal articular artery*, given off from the inner side of the popliteal, and above the knee-joint, runs with a branch of the nerve to the inner border of the femur, turns forwards above the condyle, perforates the tendon of the adductor magnus, and, appearing in the front of the thigh, divides into superficial and deep branches: the former set give off ascending branches to inosculate with the anastomotic artery, whilst others descend to the surface of the articulation, ramifying over it, and joining with the other articular arteries, but chiefly with those from the inferior internal articular; the latter, or the deep, perforate the vastus internus, supplying it, and some descend beneath the muscle to the bone and synovial membrane.

External. The *superior external articular*, a branch from the outer side of the artery, opposite to the preceding, is directed outwards beneath the biceps to the external margin of the femur, close

above the condyle, it then winds round the bone to its front, passing through the external intermuscular septum, and divides also beneath the vastus externus into a superficial and a deep branch; the superficial descends through the vastus to the joint, anastomosing with the inferior external and the other articular arteries; the deep supplies the muscle, inosculating in it with the descending branches of the external circumflex, and sends transversely across the bone a branch to join with one from the anastomotic, and from the arch thus formed arteries are given to the synovial membrane. The lower part of the femur is also supplied by this artery.

Inferior Articular internal.

The *inferior internal articular branch* leaves the artery opposite the joint, descends below the head of the tibia, passing beneath the inner head of the gastrocnemius, the tendons inserted into the inner side of the tibia, and the internal lateral ligament, and runs along the upper border of the popliteus muscle, covered by the fascia from the semi-membranosus. At the anterior border of the ligament it turns upwards round the head of the tibia, and gives superficial branches which ramify over the articulation, anastomosing above and below with the other articular; and deep, downwards and forwards, to supply the articulation and head of the tibia.

External.

The *inferior external articular*, situated higher than the preceding, arises from the outer side of the artery, opposite the articulation, runs horizontally outwards above the head of the fibula, beneath the outer head of the gastrocnemius, the plantaris muscle, and tendon of the biceps, and lies on the posterior ligament of the joint and the tendon of the popliteus muscle. On the outer part of the joint it divides into ascending branches to anastomose with the superior articular of the same side, into descending to join with the anterior tibial recurrent, and transverse to the front of the patella; a branch also passes beneath the ligament of the patella, forming an arch with the inferior internal articular, which supplies the synovial membrane.

Azygos Articular.

The *azygos artery*, smaller than the others, springs from the posterior surface of the popliteal, opposite the knee-joint, perforates the posterior ligament, and is distributed to the synovial membrane, and to the cellular membrane and ligamentous structures at the back of the articulation. These small arteries are accompanied by veins and nerves of the same name; the veins join the popliteal vein, and the nerves are branches of the popliteal trunks.

Muscular.

Sural.

The *muscular branches* are small in the upper part of the artery, and unnamed, and supply the biceps, semi-tendinosus, and semi-membranosus muscles; but the lower or *sural branches*, of much larger size and three or four in number, descend in the interval between the heads of the gastrocnemius, supplying them, the plantaris, and the soleus, and a small artery runs on the

cutaneous surface of the gastrocnemius with the cutaneous nerve of the internal popliteal.

The *popliteal vein*, of the same extent as the artery, is formed at the lower border of the popliteus by the union of the anterior and posterior tibial veins. At its commencement it lies to the inner side of the artery, but as it ascends between the heads of the gastrocnemius, it is superficial to it, and higher than this it is situated on the outer side, but still in close contact with it. Its relations to parts both before and behind are nearly the same as those of the artery. In this course it receives large branches corresponding to the muscular and articular branches of the artery, and frequently about the middle of the space the posterior or short saphena vein, but the junction of this with the popliteal is very variable. Sometimes the popliteal vein is double, or its position to the artery may be changed, or the veins that form it may not unite into one till opposite the knee-joint. Popliteal Vein. Branches.

The *lymphatic glands* in this space, four or five in number, are situated close to the artery which they surround, one being on the cutaneous surface, another between it and the bone, and the rest on the sides of the artery; they receive the deep lymphatics of the lower part of the limb, and are connected to those higher up by their efferent vessels. In the natural state these are small and scarcely noticed, but in disease they are considerably enlarged. Lymphatic Glands.

The *popliteal nerves* are branches of the great sciatic, which divides in the upper part of the space, or higher in the thigh, into internal and external popliteal; they supply different articular branches to the joint, muscular to the muscles of the leg, and cutaneous filaments. Popliteal Nerves.

The *external popliteal* (peroneal) situated on the outer side, is smaller and more superficial than the other division. It occupies the upper angle of the space, passes downwards close to the biceps muscle as far as to the outer head of the gastrocnemius, then quits the space, following the direction of the biceps to the head of the fibula, and divides a little below this into the anterior tibial and musculo-cutaneous nerves, which are dissected with the leg. This division gives off only articular and cutaneous branches. The *superior external articular nerve**, arising either from the trunk of the sciatic, or from the external popliteal in the case of a high division of the sciatic, is a long slender nerve, which descends deeply in the popliteal space, under cover of the biceps muscle, nearly as low as to the outer condyle, then passes from the space beneath the tendon of the biceps, reaches the superior External Popliteal. Branches. Articular superior external.

* There is one articular branch with each articular artery, and it is proposed to apply the same names to them as to the arteries they accompany. See a paper by the author on the "Nerves of the Knee-joint," in the *Medical Gazette* of Jan. 3., and in the *Lancet* of Jan. 11. 1840.

external articular artery, which it accompanies to the front of the joint, and supplies the synovial membrane of the articulation.

Inferior external. The *inferior external articular*, more frequently a branch of the external popliteal than of the sciatic, is also a long nerve close to the biceps, and has the same direction as the preceding, but it extends lower down, passing beneath the tendon of the biceps, and below the condyle of the femur to the artery of the same name; and it divides, on the outer side of the articulation, into many branches, that extend forwards, perforate the capsule, and supply the synovial membrane.

Cutaneous. Near the head of the fibula the external popliteal gives some small cutaneous filaments to the integuments of the outer and upper part of the leg; and one of these, larger than the rest, the *communicating saphenous branch* (communicans fibulæ) of the external popliteal, descends in the superficial fascia of the leg to join with a similar one from the internal popliteal, to give rise to the external saphenus nerve.

Nerve to the Saphenus.

Internal Popliteal. The *internal popliteal nerve* (posterior tibial), larger than the external, lies nearer the centre of the space, descending vertically through it, enters beneath the gastrocnemius, and terminates at the lower border of the popliteus, where it takes the name of posterior tibial. In the upper part of the space the nerve is superficial, is rather to the outer side of the artery, and at a distance from it, but between the heads of the gastrocnemius it is close to the vessel, though superficial to it, and beneath this muscle it crosses to the inner side of the artery, separated from it only by the vein. It gives off muscular branches between the heads of the gastrocnemius, articular, and cutaneous to the leg.

Branches.

Articular superior internal. The *superior internal articular branch*, very small, arises above the articulation, descends on the outer side of the popliteal vessels, passes beneath them, and runs with its artery to the front of the femur and inner part of the articulation: this is the least constant of the branches.

Inferior internal. The *inferior internal articular*, the largest of the nerves to the joint, arises rather above the articulation, descends to it, lying external to the vessels, is then directed inwards beneath the popliteal vessels, and meets with the artery of the same name; it now lies on the popliteus, covered by the fascia, passes beneath the internal lateral ligament, winds round the head of the tibia, perforates the capsule, and supplies the synovial membrane. This branch gives, occasionally, some small filaments to the posterior part of the articulation.

Posterior. The last articular branch is the *posterior* or *azygos*, which is given off from the internal popliteal opposite the joint, or from the inferior internal nerve; it perforates the posterior ligament, and is distributed to the articulation.

Muscular. The muscular branches, the largest and most numerous, arise whilst the trunk is in relation with the gastrocnemius.

To Gastrocnemius. The *nerve* to

the *gastrocnemius* arises opposite the articulation, descends between the heads of the muscle, and divides into three branches, two being distributed to the outer, and one to the inner head. This nerve gives sometimes a branch to the plantaris, at others, this arises separately from the trunk. The *nerve* to the *soleus* also arises opposite the articulation, descends with that to the gastrocnemius, enters the cutaneous surface of the muscle, and divides into filaments for its supply. The *nerve* to the *popliteus* leaves the trunk at the upper border of the popliteus muscle, runs downwards external to the vessels, and at the lower border of the muscle turns beneath the vessels to supply its under and lower part. Sometimes the nerve to the tibialis posticus arises above the soleus muscle, and descends between its heads with the trunk of the nerve. The cutaneous nerve, or the *communicating saphenous branch* (communicans tibiæ) of the internal popliteal, leaves the trunk of the popliteal opposite the articulation, lies between the heads of the gastrocnemius, runs on the cutaneous surface of the muscle, but beneath the fascia, which it perforates below the middle of the leg, to join with the corresponding branch of the external popliteal in the external saphenus nerve. Occasionally this union is opposite the popliteal space.

To Plantaris. To Soleus. To Popliteus. Cutaneous to Saphenus.

The *articular nerve* of the deep branch of the *obturator*, if not removed in clearing away the fat, will be best traced by following it through the fibres of the adductor magnus from the front of the thigh, where it has been dissected. It is a very small branch, appears in the upper part of the popliteal space by perforating the fibres of the adductor magnus, descends to reach the popliteal artery, and sends numerous filaments around it, as well as an internal branch to the joint through the posterior ligament.

Articular of the Obturator.

Slit up the portion of fascia left on the back of the thigh, or if the popliteal space has been dissected before the intervening integument is removed, take this away, dissecting the cutaneous nerves, and then clean off the fascia as directed. Clean the cellular membrane from the muscles, and dissect with care the small sciatic nerve, and branches of the great sciatic distributed to the muscles. The flexor muscles of the leg, situated on the back of the thigh, are three in number: the biceps to the outer side, and the semi-tendinosus and membranosus on the inner.

Dissection.

The *biceps muscle*, divided above into two heads, is placed at the back of the thigh, and forms the outer hamstring. It *arises* by its long head from the outer surface of the tuberosity of the ischium in common with the semi-tendinosus muscle; and by its short head, from the outer lip of the linea aspera as high as the insertion of the gluteus maximus, from the line leading to the outer condyle nearly to this process, and from the inter-

Biceps Muscle. Origin.

muscular septum which is between it and the vastus externus. From these attachments the fibres take different directions; those of the long head descending almost vertically, and those of the short, obliquely downwards to the tendon, which is free from the fibres only near the head of the fibula, and is then divided by the external lateral ligament into two portions which are *inserted* into the heads of the tibia and fibula. An expansion is sent off from the lower part of the tendon to join the fascia of the leg, and from the upper, to unite with that of the vasti over the front of the joint. The muscle is covered above by the gluteus maximus, but below that it is subcutaneous, and forms the outer boundary of the popliteal space; and it lies on the upper tendinous part of the semi-membranosus, on the great sciatic nerve, and adductor magnus muscle. The inner border is joined above to the semi-tendinosus, with which it continues in contact down to the upper angle of the popliteal space, concealing thus the great sciatic nerve; below this is the external popliteal nerve, and outer head of the gastrocnemius muscle. The attachment of the short head to the femur has external to it the vastus externus and external intermuscular septum, and internal to it the adductor magnus.

Insertion.

Relations.

Semi-tendinosus Muscle.

Origin.

The *semi-tendinosus muscle,* long and narrow, is another of the flexors of the leg, and forms one of the inner hamstrings. Its *origin* is by fleshy fibres from the tuberosity of the ischium, in common with the long head of the biceps; these descend, forming a fleshy belly, and terminate about the lower third of the thigh in a tendon, which passes behind the knee-joint, is then reflected forwards below the head of the tibia, and is *inserted* into the crest of this bone by a flat portion that is united to the tendon of the gracilis, and placed below it. An expansion is given off from the lower border of the tendon to join with that from the sartorius, and a synovial membrane separates it and the gracilis from the internal lateral ligament. Of the three tendons inserted into the upper part of the tibia and placed on the synovial membrane, that of the sartorius is most superficial, and covers those of the semi-tendinosus and gracilis, which lie on the same level. The semi-tendinosus is covered above by the gluteus maximus, but thence to its termination it is subcutaneous; a tendinous intersection extended downwards and outwards crosses the centre of this hamstring muscle. It lies above in a groove in the expanded membranous portion of the semi-membranosus, and continues on this muscle to the knee-joint; and before turning forwards to its insertion, it lies between the inner head of the gastrocnemius and tendon of the semi-membranosus, and is then placed over the internal lateral ligament; in the thigh it partly conceals with the biceps the great sciatic nerve, but does not cross it. The outer border corresponds to the biceps as low as to the popliteal space, and

Insertion.

Relations.

to the internal popliteal nerve; and the inner touches the adductor magnus and gracilis muscles.

The *semi-membranosus muscle*, the largest and thickest of the flexors of the leg, which arise from the tuberosity of the ischium, has received its name from the membranous appearance of the upper tendon. The muscle is attached to the tuberosity of the ischium, external to the origin of the semi-tendinosus and biceps, and close to that of the quadratus femoris, by a tendon, which passes beneath the other two hamstring muscles, and forms a wide band, thicker externally than internally, which receives, as in a groove, the semi-tendinosus muscle. The fibres, arising from the tendon, descend vertically, forming a thick fleshy belly that reaches as far as the knee, and ends in a tendon, which, commencing by an aponeurosis on the inner side of the muscle, a little above where the upper one ceases on the outer side, is *inserted* by a thick and round process into the inner side of the head of the tibia; but the particular attachment, and the processes prolonged from it, must remain till the ligaments are dissected. This muscle is covered to its insertion into the femur by the semi-tendinosus muscle; and it lies on the adductor magnus as low as the tendon of this muscle, but below this on the gracilis and inner head of the gastrocnemius, which are between it and the femur; it also lies on the articulation of the knee. The outer border is in contact with the biceps and great sciatic nerve, with the popliteal vessels in the popliteal space, and near its insertion, with the tendon of the semi-tendinosus, which separates it from the inner head of the gastrocnemius; the inner border is in relation with the adductor magnus, and below, with the gracilis.

Semi-membranosus Muscle. Origin. Insertion. Relations.

The continuation of the small sciatic nerve escapes beneath the lower border of the gluteus maximus, descends beneath the fascia through the thigh and popliteal space, and perforates the fascia of the leg, accompanying then the posterior saphena vein, and supplying the integuments. In its course through the thigh it gives cutaneous branches, and near the upper part of the popliteal space a still larger one to the integuments over its outer part, as seen in the dissection of the cutaneous nerves.

Small Sciatic in the Thigh.

The *great sciatic nerve* of the sacral plexus, before seen as it leaves the pelvis by the sciatic notch, descends over the external rotator muscles to the middle or lower third of the thigh, and divides into the external and internal popliteal nerves. In the thigh, it is crossed opposite the insertion of the gluteus maximus by the long head of the biceps, and is concealed down to the popliteal space by the juxta-position of the biceps and semi-tendinosus; it lies on the adductor magnus in all its course after it has passed the quadratus, and it is situated on the outer side of the semi-membranosus muscle. The branches from it are muscular and articular, and they are given off where it is

Great Sciatic Nerve. Branches.

To Biceps. crossed by the biceps. The branch to the biceps divides into filaments, some entering the upper part of the muscle, and some

Semitendinosus. extending to near the lower. The branch to the semi-tendinosus is a small slender nerve, and enters the muscle at the lower part of its fleshy belly. One or two branches go to the

Semimembranosus. semi-membranosus muscle, and enter its substance near the lower part. Some branches are also supplied to the adductor magnus and short head of the biceps. The superior external

Articular. *articular* nerve, when it arises from the trunk of the sciatic, descends beneath the biceps to the articulation of the knee.

Dissection. Detach the hamstring muscles from the tuberosity of the ischium and throw them down, dividing, if necessary, the branches of arteries and nerves that they receive. Clean the surface of the adductor magnus muscle. The arteries seen perforating it, or passing above the upper border, are branches of the profunda, which are distributed to the hamstrings.

Adductor magnus. The *posterior surface* of the *adductor magnus* is altogether muscular, and the fibres from the rami of the pubes and ischium form a portion anterior to those from the tuberosity of the ischium. The opening for the artery is muscular on this surface, and is formed externally by the thin pointed process, about one inch in length, attached to the line leading to the inner condyle, and internally by the fibres from the tuberosity of the ischium, descending to the round tendon of insertion. This surface is covered by the hamstrings and by the great sciatic nerve, and perforating it are the branches of the profunda artery. The upper border is parallel to the quadratus femoris.

Dissection. The hip-joint should be examined before the removal of the limb; and to do this take away from it all the surrounding muscles and the cellular membrane. The subject should be turned to see the front of it.

Ilio-femoral Articulation. The ilio-femoral articulation is the most perfect of the ball and socket joints, and is formed by the acetabulum, or cup-shaped cavity of the os innominatum, receiving the head of the femur. The following ligaments are found in this joint: — a capsular, loose and free, enclosing the articular surfaces; a cotyloid to deepen the cavity for the reception of the head of the femur; and an interarticular between the surfaces in contact.

Capsular Ligament. The *capsular ligament* is a large loose fibrous structure surrounding, above, the cotyloid cavity, and, below, the neck of the femur. It is thicker on the outer and inner parts than elsewhere, because of the addition of accessory fibres; in the former position is the band of the ilio-femoral ligament, stretching from the anterior inferior spinous process of the ilium, and in the latter, some fibres from the ridge of the os pubis above the sub-pubic aperture. The weakest portion of the capsule is below and behind, where it is covered by the obturator ex-

ternus muscle. Near the inferior insertion numerous vessels perforate it to supply the neck of the femur. Its upper attachment is to the circumference of the cotyloid cavity about two lines from the edge, to the anterior inferior spinous process of the ilium, and also to the outer part of the ridge of the pubes above mentioned; at the inner side, where the notch of the acetabulum exists, the capsule is not fixed to the bone, but to a small ligament stretched transversely across it; the tendon of the rectus is connected to the upper and posterior part of the insertion into the bone. The lower part of the ligament is fixed, posteriorly, to the neck of the femur, about a finger's breadth from the inter-trochanteric line and pit of the great trochanter, and becomes very thin; anteriorly, to the inter-trochanteric line in this situation; above and to the outer side, to the root of the great trochanter, but below, to about the middle of the neck of the bone, so that the capsule does not extend to the limits of the neck. The muscles surrounding the capsule are, behind, the pyriformis, the gemelli, and tendons of the obturator internus and externus, with the quadratus; and, in front, the psoas and iliacus, which are separated by a synovial bursa; on the inner side are the edge of the pectineus and the obturator externus; on the upper and outer is the gluteus minimus, and inferiorly is the obturator externus winding backwards.

Ilio-femoral Ligament.

The *ilio-femoral ligament*, similar to the coraco-humeral of the shoulder-joint, consists of the thickened fibres of the capsule, which are attached to the anterior inferior spinous process of the ilium. It is narrow above, but the fibres radiate as they are continued over the joint, and they are inserted into the anterior inter-trochanteric line.

Dissection.

Divide the capsule over the head of the femur, disarticulate this bone, and the cotyloid ligament around the acetabulum and the interarticular ligament are exposed.

Cotyloid Ligament.

The *cotyloid ligament* is a fibro-cartilaginous process, fixed to the margin of the cotyloid cavity to deepen it for the reception of the femur, as the glenoid ligament is to the cavity for the head of the humerus. It is thick where fixed to the bone, and thin at the free border which is in contact with the head of the femur; its depth is greatest where the margin of the acetabulum is excavated, and it is continued over the notch in the inner side, giving rise to the *transverse ligament* which converts the notch into a foramen, through which pass the articular vessels and nerves. Both surfaces of the ligament are invested by synovial membrane.

Transverse.

Round Ligament.

The *interarticular* or *round ligament* is a fibrous band connecting the head of the femur to the acetabulum; the femoral extremity, the smallest, is inserted into the pit in the head of the femur, and the other, flatter, is attached by means of two processes to the margins of the notch in the side of the

acetabulum. The ligament is surrounded by synovial membrane.

Synovial Membrane. The *synovial membrane* of this articulation is simple in its reflections. It covers the acetabulum, being continued over the cellular substance called the synovial gland, and over the surfaces of the cotyloid ligament; it is next directed along the inner surface of the capsule to the neck of the femur, along which it ascends to cover the head of the bone, and finally passes on the round ligament to join that lining the cavity.

Dissection. Separate now the lower extremity from the trunk by dividing the round ligament, and any remaining portion of muscle connecting it to the pelvis, and examine the acetabulum.

Cavity of the Acetabulum. The cavity of the acetabulum is covered with cartilage only on the anterior, posterior, and upper parts, or in those pressed upon by the head of the femur during progression, for this prominence of bone does not project into the centre of the cavity. The deepest part of the cavity is the centre, which is free from cartilage, and in it is placed a reddish fatty structure with an unctuous feel, which is called sometimes a synovial gland; it receives a branch of an artery and a nerve beneath the transverse ligament.

DISSECTION OF THE BACK OF THE LEG.*

Dissection. In the dissection of the posterior part of the leg, place the limb on the front, with the foot over the side of the table, flex the ankle, and keep it in this condition by fastening the foot. Make an incision along the centre of the leg to the heel, a second cross one below, and raise the flaps of integument, — on the inner side as far as the surface of the tibia, and on the outer, to the external part of the leg: follow the cutaneous veins and nerves from the trunks exposed above, the internal saphena vein and its nerve being on the inner side, the posterior saphena vein with its nerve and branches, on the outer side, and the continuation of the small sciatic in the middle line; some cutaneous filaments of the external popliteal nerve are on the outer side, and some of the obturator on the upper and inner, near the internal saphenus nerve.

Cutaneous Veins. Internal Saphena. The *internal saphena vein* is situated in the leg along the inner border of the tibia. It commences at the inner termination of a venous arch on the upper surface of the foot, ascends before the inner ankle and on the surface of the tibia, runs near

The dissection of the front of the leg is sometimes begun before the back; and if this proceeding should be followed, see p. 705.

the border of this bone, lying on the soleus muscle, and passes behind the knee-joint, and along the thigh, to the saphenous opening. In the leg it is accompanied by the internal saphena nerve which comes into contact with it at the knee. It receives branches from the sole of the foot, from the plantar veins, and along the leg, some from the deep posterior tibial veins; in the middle of the leg it is joined by a branch from the anterior tibial, and an articular vein sometimes unites with it at the knee.

External Saphena.

The *external* or posterior, or short *saphena vein* begins on the dorsum of the foot from the outer extremity of the same arch as that in which the internal commenced; it turns round to the back of the leg below the outer ankle, and ascends along the middle part to open, between the heads of the gastrocnemius, into the popliteal vein, but its point of union with the popliteal is uncertain. Near the popliteal space the branch of the small sciatic nerve runs with it, and below, the communicating saphenus branch from the internal popliteal. It receives branches about the external malleolus, the os calcis, and back of the leg.

Cutaneous Nerves. Internal Saphenus.

The *internal saphenus nerve* appears beneath the lower border of the sartorius, near the knee, and in the leg it descends with its vein along the inner side, crossing it in its course, and dividing, about the lower third, into two branches; one continues along the edge of the tibia to the integuments about the inner ankle, and the other passes with the vein in front of the ankle to the integuments of the inner part of the foot, and extends to about its middle. It gives backwards filaments to the integuments, and to join with the cutaneous branch of the obturator nerve, whilst other branches go forwards over the tibia to the front of the leg.

Communicating from internal Popliteal. External Saphenus.

The *communicating saphenus branch* (communicans tibiæ) of the internal popliteal is placed at first beneath the fascia, but superficially to the gastrocnemius, perforates the fascia below the middle of the leg, runs with the posterior saphena vein, and most frequently joins, above the outer ankle, with the communicating saphenus branch of the external popliteal, to form the *external* or short *saphenus* nerve, which passes below the outer ankle with the vein, and supplies the outer side of the foot and the little toe. This nerve gives long and large branches in the lower part of the leg to the outer side of the calcaneum and heel.

Communicating from external Popliteal.

The *communicating saphenus branch* (communicans fibulæ) of the external popliteal nerve, not so large as the one from the internal, descends in the integuments, and unites with the communicating from the internal popliteal, after this has perforated the fascia, to form the external saphenus. Occasionally the junction of these two branches in the saphenus nerve takes

place opposite the popliteal space, and beneath the fascia; and in those instances in which the branch from the external popliteal does not unite with that from the internal, the saphenus is formed altogether by the one from the internal popliteal, whilst the branch from the external nerve is distributed to the integuments of the outer part of the leg. There are also other cutaneous branches to the outer side of the leg from the external popliteal nerve.

Continuation of small Sciatic.

The *continuation* of the *small sciatic nerve* perforates the fascia of the leg in its upper third, descends with the posterior saphena vein to about the middle of the leg*, supplying the integuments, and joining with the external saphenus nerve, or the communicating branch from the internal popliteal.

Cutaneous of the Obturator.

The *cutaneous branch* of the *obturator*, before seen at the knee, descends along the inner part of the leg to its middle or lower third, and joins with cutaneous filaments of the internal saphenus nerve.

The Fascia.

The proper *fascia* of the back of the leg envelopes the muscles, and is continued externally from one aspect to the other without interruption, but internally it is fixed to the edges of the tibia, and is not prolonged over its cutaneous surface. It sends a thick process between the muscles of the superficial and the deep layer, is continuous above with that of the thigh, and receives processes at the inner side of the knee from the tendons of the semi-tendinosus, gracilis, and sartorius muscles; and below it is connected to the internal annular ligament, which may be considered a thickened part of the fascia. Some cutaneous veins perforate it to join the superficial cutaneous veins.

Dissection.

Divide the fascia by a vertical incision along the centre of the leg as far as that in the skin, and remove it, but leave the deep process that divides the muscles into layers. In the superficial layer of muscles are the gastrocnemius and soleus, which form the prominence of the calf, and the small plantaris. Replace the divided head of the gastrocnemius.

Gastrocnemius Muscle.

The *gastrocnemius muscle*, the most superficial in the calf of the leg, is muscular and bifid above, but pointed and tendinous below, and the inner fleshy portion projects lower than the outer.

Origin.

It *arises* by two heads from the condyles of the femur: the inner being attached by a strong tendon to the inner condyle, close behind the insertion of the adductor magnus, and slightly to the ridge above it by fleshy fibres; and the outer head, not so strong as the inner, is also fixed by a tendon to the outer condyle, above the tendon of the popliteus muscle. From these heads the fibres descend, forming a thick muscle, and end below in a tendon, which, prolonged on the under surface of the mus-

* In a very careful dissection by Mr. Henry Long Jacob in the dissecting room of the College, Session 1839–40, it was traced to within two inches of the ankle.

cle, joins with that of the soleus about the middle of the leg in the *tendo Achillis*. Its cutaneous surface is covered by the fascia, and cutaneous nerves and veins. The inclination towards each other of the two heads of origin forms the lower boundary of the popliteal space; the internal has to its inner side the semi-membranosus and semi-tendinosus muscles, and the external is in relation with the biceps, and both are so closely united to the capsule that they cannot be removed without opening it. Cut through the outer head, and the vessels and nerves that supply the muscle, and throw it down. The gastrocnemius lies on the large soleus muscle, and the small plantaris, but, above, on the popliteal vessels and nerve, whilst they are on the popliteus, and on the branches that leave them in this extent. Relations.

The *soleus muscle*, which, with the gastrocnemius, forms the calf of the leg, is large and fleshy in the upper part, but tendinous in the lower. Its *origin* is from the posterior part of the head of the fibula, and from the posterior surface of the upper third of the same bone; from the oblique line across the tibia below the insertion of the popliteus, from the inner border of the middle third of the tibia, and between the bones from a tendinous arch over the vessels; the fibres also come from the aponeurosis on the under surface. From these attachments, the fibres run obliquely to an aponeurosis on the cutaneous surface, and to a tendon which joins with that of the gastrocnemius in the strong thick *tendo Achillis*, which commences about the middle of the leg, descends vertically to the heel, and is *inserted* into a rough surface on the posterior and lower part of the os calcis, a synovial membrane separating it from the upper part of the bone. The soleus is covered by the gastrocnemius and plantaris muscles, and the tendon resulting from the union of its tendon with that of the gastrocnemius, is subcutaneous; the muscle lies on part of the fibula, and touches the tibia by its linear attachment between the popliteus and tibialis posticus muscles, also on the deep layer of muscles and the vessels, separated, however, by the deep portion of fascia. Soleus Muscle. Origin. Insertion. Relations.

The *plantaris muscle* consists of a small muscular portion, and of a thin shining tendon, — the longest in the body. The *origin* is from the line leading to the outer condyle of the femur, above the attachment of the gastrocnemius, and from the posterior ligament of the knee-joint: the fibres form a small roundish muscle, about three inches long, which runs downwards and inwards over the popliteal artery but beneath the gastrocnemius, and ends in a tendon, which, concealed at first by the gastrocnemius, becomes cutaneous on the inner side of the tendo Achillis, and is *inserted* into the os calcis either before this tendon or by the side of it, or it may join the tendon. The muscle is covered by the gastrocnemius, and the tendon appears from beneath this muscle about the middle of the leg; it crosses the popliteal Plantaris Muscle. Origin. Insertion. Relations.

vessels, and lies on the popliteus and soleus muscles. The tendon is very thin, and when stretched laterally is like a riband. This muscle is frequently absent, or, when present, subject to great variety in its origin, course, or insertion.

Dissection. Detach the soleus from the tibia and fibula, avoiding a branch of the internal popliteal nerve, which supplies some of the deep muscles of the leg, and usually arises above the arch formed at the upper border of the soleus. This muscle and the gastrocnemius may next be removed by cutting through the tendo Achillis near its insertion; clean then the deep layer of fascia, and take away the integument between the heel and inner ankle to see the annular ligament.

Deep layer of Fascia. The *deep layer* of *fascia* is a horizontal process of the fascia of the leg, which separates the deep and superficial layers of muscles, and is fixed to the margins of the tibia and fibula. It is much thinner above than below, is perforated by some small apertures for vessels, and is attached superiorly to the line of origin of the soleus muscle, but inferiorly it joins the *internal annular ligament* — a structure formed chiefly by transverse fibres, and attached, internally, to the posterior border and summit of the internal malleolus, and externally, where it is wider, to the os calcis; and forming between these points a kind of arch, subdivided into smaller spaces by partitions sent downwards between the different tendons that pass beneath it. The cutaneous surface of the ligament is perforated by small nerves and vessels; the upper border joins the fascia of the leg, and the lower gives attachment to the abductor pollicis muscle of the foot.

Internal annular Ligament.

Dissection. Remove carefully the fascia, so as not to injure the vessels or nerves beneath, and the muscles of the deep layer, four in number, are exposed. The highest muscle is the popliteus, which lies close below the knee-joint, crossing the upper extremity of the bones, and being covered by a fascia which is to be reflected from it; and the three others are long muscles passing into the sole of the foot, and consist of a vertical part parallel to the bones of the leg, and of a horizontal, beneath the bones of the tarsus, so that they turn round the lower part of the tibia as over a pulley: it is only the vertical part of these muscles that is now dissected. The muscle on the tibia, the smallest, is the common flexor of the toes, that on the fibula, the flexor of the great toe, and the one between the two bones, reaching higher than the others, is the tibialis posticus. The posterior tibial artery and nerve, with their branches, are also to be dissected.

Popliteus Muscle. Origin. The *popliteus muscle*, of a triangular shape, and situated behind the knee-joint, part of which it crosses, *arises* by a strong round tendon from the outer condyle of the femur, below the attachments of the external lateral ligament and head of the gastrocnemius, and from the front of a depression on the

outer surface. The tendon, situated beneath the external lateral ligament and within the capsule of the joint, perforates the capsule, and gives attachment to the fleshy fibres, which extend obliquely downwards and inwards, the inferior being the longest, to be *inserted* into the posterior surface of the tibia above the oblique line on its posterior part. The cutaneous surface is crossed by the popliteal vessels and nerve, and by their branches; and the popliteus is concealed by the gastrocnemius and plantaris. Along the upper border run the inferior internal articular vessels and nerve, and the lower corresponds to the origin of the soleus. Trace the tendon into the muscle to see the processes into which it divides, and then cut it across; the muscle lies on the upper part of the posterior surface of the tibia, and, whilst within the capsule, on the external semi-lunar cartilage, and articulation of the tibia and fibula, but this portion of the tendon will be dissected with the tendons and ligaments around the knee-joint.

Insertion. Relations.

The *flexor longus digitorum* or *perforans* lies on the tibia, and is the smallest of the muscles of this layer, with the exception of the popliteus. Its *origin* is from the oblique line across the tibia, to which the popliteus is attached, from the posterior surface of this bone to within three inches of the inferior extremity, and also, on the outer side, from an aponeurosis covering the tibialis posticus; the fibres descend vertically to a tendon, which, appearing about the middle of the muscle, receives the fleshy fibres nearly down to the malleolus, is separated from the surface of the tibia, about three inches above the malleolus, by the tendon of the tibialis posticus, enters the partition in the annular ligament with the tendon of the tibialis, but separated from it by a fibrous process, and escaped from this it enters the foot, and divides into four tendons for the four outer toes. The cutaneous surface is covered by the fascia and superficial layer of muscles, and in the inferior fourth, by the posterior tibial vessels and nerve; and it lies on the tibia and tibialis posticus muscle. The inner border is in relation above with the attachment of the soleus, but below with the tibialis posticus which has passed beneath it; the outer is in contact with the tibialis posticus and tibial vessels, but below it corresponds to the flexor longus pollicis muscle. A separate synovial membrane is found with the tendon as it passes through the annular ligament.

Flexor Digitorum Muscle. Origin. Insertion. Relations.

The *tibialis posticus muscle*, situated between the two bones, is concealed by an aponeurosis which covers it, and partly by the other muscles which overlap it. It is large and muscular above, but gradually diminishes in size, and *arises* from all the posterior surface of the interosseous ligament, from the contiguous surface of the tibia, from the portion of the inner surface of the fibula behind the attachment of the interosseous ligament, and

Tibialis posticus Muscle. Origin.

above by two processes,—one to the head of the fibula, and the other to the tibia below the oblique line,—so that it is bifurcated superiorly, and between the heads pass the anterior tibial vessels. The fibres descend to a tendon, which, commencing high up on the cutaneous surface, and receiving fibres down to the internal malleolus, is directed, in the lower fourth of the leg, between the bone and flexor digitorum, and, become free from muscular fibres, lies in the groove behind the internal malleolus, enters the sheath of the annular ligament, which is lined by a separate synovial membrane, and it is fixed to the groove in the tibia by a process of fibrous structure that separates it from the tendon of the flexor digitorum, which is external to it; at the lower border of the ligament it enters the foot, and is directed to the scaphoid bone into which it is inserted. On the cutaneous surface is the aponeurotic expansion, which is connected to the bones, separates the tibialis from the other muscles, gives attachment to the flexor digitorum, and ends below in an arched border, below which passes the tibialis; it is also covered by the superficial layer of muscles, by the posterior tibial vessels and nerve, and below by the flexor digitorum; and in the middle of the leg it is overlapped by the flexor digitorum and flexor pollicis muscles. Along the outer border are the fibula, peroneal vessels, and flexor pollicis muscle: and along the inner, the tibia and flexor communis. The muscle lies on the interosseous ligament, and surfaces of the tibia and fibula, and the upper part allows the anterior tibial artery to pass forwards.

Insertion. Relations.

Flexor Pollicis Muscle. Origin.

The *flexor pollicis longus*, the thickest and largest of the muscles of this layer, is situated on the fibula, and its belly extends lower down than those of the other two. It *arises* from the two lower thirds of the posterior surface of the fibula, from the lower part of the interosseous ligament near it, and from the intermuscular septum between it and the peronei muscles: the fibres descend to a tendon, which becomes apparent on the surface of the muscle near the lower end of the fibula, passes through a separate partition in the annular ligament, about half an inch external to the artery and lined by a distinct synovial membrane, enters the groove in the astragalus, in which it is bound down by a fibrous expansion, and passes to the inner side of the foot to the great toe. The muscle is covered by the fascia and soleus, and lies on the fibula and lower extremity of the tibia, concealing the peroneal vessels which are enveloped in the fibres. The outer border is contiguous to the peronei muscles; and the inner touches the posterior tibial vessels and nerves in the middle of the leg, and overlaps the tibialis posticus muscle.

Insertion. Relations.

Posterior Tibial Artery.

The *posterior tibial artery* extends from the lower border of the popliteus muscle to the lower border of the internal annular ligament, where it divides beneath the abductor pollicis into the plantar arteries. Its direction is downwards and inwards from

the interval between the bones to the lower extremity of the tibia, on which it is placed, and it is separated from the margin of this bone by the breadth of the flexor digitorum. In this course the artery is covered by the fleshy bellies of the gastrocnemius and soleus to the middle of the leg, but below this, lying nearer the inner border of the tendo Achillis than that of the tibia, it is covered only by the integuments and fascia, and at its termination it is beneath the annular ligament: it lies on the tibialis posticus, to the spot at which the muscle passes beneath the flexor digitorum, then on the fibres of the flexor attached to the aponeurosis over the tibialis posticus, and finally, on the lower extremity of the tibia for about one inch, and on the astragalus. In the upper third the posterior tibial artery has no muscle in contact laterally with it, but it is accompanied by two veins which closely surround it, and by the posterior tibial nerve, which, lying on the inner side at the lower border of the popliteus, crosses it superficially, and is situated to the outer side close below the origin of the peroneal artery; in the middle third the flexor pollicis and flexor digitorum are close to the vessels, the nerve being still external, and maintaining this relation till it passes beneath the annular ligament: in the lower third the flexor pollicis is not so close to them, and the flexor digitorum is beneath them: the nerve has the same relation. Many muscular unnamed branches are given to the superficial and deep layers of muscles, besides the larger named branches. Branches.

The *internal recurrent*, to the knee-joint, perforates the inner part of the soleus muscle, crosses the inner surface of the tibia, turns upwards and inwards to the articulation of the knee, and inosculates with the inferior internal articular artery of the popliteal. Internal Recurrent.

The *peroneal artery*, often as large as the trunk of the posterior tibial, arises about one inch and a half below the border of the popliteus, runs downwards and outwards on the tibialis posticus muscle, external to the posterior tibial nerve, enters the fibres of the flexor pollicis longus, lying close to the fibula in a tendinous canal formed for it in the muscle, and reaches the lower border of the interosseous membrane, where it divides into an anterior and a posterior peroneal artery. In this course the artery sends two or three branches round the outer surface of the fibula, and beneath the flexor pollicis to the peronei muscles: the lowest of these, near the malleolus, anastomoses on this process with the external malleolar from the anterior tibial. Another branch of the peroneal is the *nutritious artery*, which enters the fibula about its middle, and supplies it. The *anterior peroneal*, one of the terminal branches, passes forwards through the aperture below the interosseous membrane, and in the front of the leg divides into branches to anastomose with Peroneal Artery. Nutritious. Anterior Peroneal.

Posterior. the external malleolar. The *posterior peroneal* descends, in the direction of the trunk, over the articulation between the tibia and fibula, and ends on the outer side of the os calcis by dividing into many branches; some of these supply the os calcis, others run forwards below the fibula to anastomose on the outer side of the tarsus with branches from the tarsal artery, whilst others descend vertically to the lower border of the foot, and join with branches from the external plantar. Opposite the lower border of the tibia, the posterior peroneal sends internally a transverse branch to join with a similar one from the posterior tibial, and thus to form an arch. Occasionally there is a second arch below this.

Nutritious of the Tibia. The *nutritious artery of the tibia* is a small branch that varies in its origin; it enters the foramen on the posterior surface of the tibia, and is distributed to its substance.

Communicating and Tarsal. Near the malleolus, branches run inwards to ramify on this process, and at the lower extremity of the tibia a communicating branch is directed horizontally outwards beneath the flexor pollicis, and forms an arch with a similar branch from the posterior peroneal. In the interval between the malleolus and os calcis numerous small branches are supplied to the bones of the tarsus, and the tibio-tarsal articulation, and they anastomose with branches given to these parts from the anterior tibial, plantar, and peroneal arteries.

Veins. The *posterior tibial veins* commence on the inner side of the foot by the union of the plantar with other deep branches; they surround the artery, sending cross branches over it, are joined by the peroneal and other branches corresponding to the arteries, and unite with the anterior tibial at the lower border of the popliteus to form the trunk of the popliteal vein. Many branches of communication pass to the internal saphena vein.

Posterior Tibial Nerve. The *posterior tibial nerve*, a continuation of the internal popliteal, begins at the lower border of the popliteus, where the name of popliteal ceases, extends to the interval between the heel and inner ankle, and divides beneath the internal annular ligament into internal and external plantar nerves. The nerve closely accompanies the artery, is covered by the same parts, and lies on the same muscles; it is to the inner side of the artery at the lower border of the popliteus, but it soon crosses to the outer side, being found between it and the peroneal, and it keeps this relation to the outer side of the vessel till it enters the foot. The branches to the deep layer of muscles arise either from it in the leg, or by a common trunk from the popliteal, which divides into the different branches. The nerve to the flexor digitorum frequently arises by a common trunk with the other branches, and descends to the muscle. The largest branch is the nerve to the tibialis posticus, which gives some filaments to the upper part of the muscle, and is then

Branches.

To Flexor digitorum.

To Tibialis posticus.

prolonged to near its middle. The nerve to the flexor pollicis runs outwards, sometimes lying on the peroneal artery, to about the lower third of the leg, before being distributed to the muscle. Above the os calcis it gives off a cutaneous branch, which descends, and is distributed to the integuments of the inner and lower part of the heel.

To Flexor pollicis.

Cutaneous.

Open the different sheaths of the annular ligament to see the relations of the tendons and vessels passing through them. The division nearest the malleolus contains the tendon of the tibialis posticus, which lies on the internal lateral ligament, and is received into a groove in the bone which is lined by a synovial membrane. Immediately external to the tendon of the tibialis is that of the flexor digitorum, which is separated from the former by a fibrous partition, and its sheath is also lined by a synovial membrane; in consequence of the tendons of the tibialis and flexor taking different directions in the foot, they are separated below from each other by an interval. The next sheath contains the posterior tibial vessels, with the nerve close to their outer side,—the tendons of the flexor digitorum longus and tibialis posticus being about a quarter of an inch nearer the malleolus, and that of the flexor pollicis half an inch external or posterior to them; the artery lies on the astragalus, and at the lower part of the ligament on the tendon of the flexor pollicis longus, which crosses beneath it; and at the lower border of the ligament, or sooner, it divides into internal and external plantar, and gives off branches to the malleolus and calcaneum. The nerve divides beneath the ligament into internal and external plantar, or this may take place above, one branch being then found on each side of the vessels; it gives off a cutaneous branch to the integuments of the sole of the foot, which perforates the ligament. The last division of the ligament is for the tendon of the flexor pollicis, which is contained in a groove in the astragalus, in which it is bound down by a fascia, the sheath containing a synovial membrane; above, it is placed on the outer side of the vessels, but below it crosses beneath them to reach their inner side.

Parts beneath the Annular Ligament.

DISSECTION OF THE SOLE OF THE FOOT.*

Place the foot on a block with the sole uppermost, and make the part tense by fastening down the toes; carry an incision along the centre of the sole, from the heel to the clefts of the

Dissection.

* The dissection is sometimes varied by taking next the front of the leg. See p. 705.

toes, and at its anterior extremity make a transverse one, raise the flaps of integument to the inner and outer borders of the foot, and afterwards remove the skin from each toe, avoiding the digital branches of the vessels and nerve along its sides. The cellular membrane is very abundant in the foot, and is thickest over the heel, and the articulations of the metatarsal bones with the phalanges. Some cutaneous branches of nerves with arteries perforate the fascia; and the cutaneous nerve of the sole, the annular ligament.

Cutaneous Nerve of the Sole.

The *cutaneous nerve of the sole of the foot* arises from the internal plantar nerve while this is beneath the annular ligament, perforates this structure, and descends into the sole of the foot, supplying the integuments of the inner and under part, whilst other filaments are continued to the heel. When there is a high division of the posterior tibial into the plantar nerves, this will arise from the plantar.

Cutaneous Plantar.

Other cutaneous filaments in the sole are derived from the plantar nerves, and the largest of these are from the internal plantar; they perforate, irregularly, the fascia, and are lost in the integuments.

Dissection.

Take away the cellular membrane from the sole to expose the plantar fascia, and begin behind where it is thickest; continue it forwards to the clefts of the toes, where fibrous processes given off from it to the skin are found to enclose the cellular tissue in their areolæ. On each side of the centre the fascia is weaker and nearer the integument, and the digital branches of the nerve and artery to the inner side of the great toe, and outer side of the little toe, are to be avoided as they escape from beneath the central piece of fascia farther back than the others. Along the toes, connecting one to the other, and corresponding to the web between them, is the fibrous band or transverse ligament of the phalanges, which is similar to that in the hand. If the digital branches along the sides of the toes are not dissected out, follow them.

Plantar Fascia.

The *plantar fascia* or aponeurosis is strong and shining, of a pearly white colour, and binds down the muscles in the sole of the foot, sending processes downwards which divide them into bundles. It consists of a thick central part, and of an external and internal weaker portion. The central part, which is referred to when speaking of the fascia, is thick and pointed behind, and is attached to the os calcis, but as it extends forwards to the toes it becomes thinner, and gives off when near to them numerous fibres, which contain much fat in their interspaces, and are inserted into the skin at the clefts of the toes, and into the transverse ligament. If the cutaneous fibres be removed the anterior arrangement of this portion of the fascia will be seen: opposite the heads of the metatarsal bones it divides into five processes, which are continued forwards to join

the sheath of the tendons to each toe, and the margins of each process are reflected downwards on the sides of the tendons to unite with the transverse metatarsal ligament, and thus to complete the upper part of the sheath for the tendons: this is seen by dividing the process over the tendons and reflecting it to the sides. Where the processes separate from each other they are connected by transverse fibres which form arches, and beneath these pass the digital branches of the artery and nerves, and the lumbricales muscles, which now become superficial. This portion of the fascia is separated from that on the outer and the inner side by a depressed line, in which a process is sent downwards between the muscles, and the cutaneous nerves perforate it in this spot; it bounds the middle set of muscles of the foot, and conceals the flexor digitorum brevis which arises from its under surface. The outer portion, next in thickness to the middle, is stronger behind than before, and forms a thick band between the os calcis and prominence of the fifth metatarsal bone; it conceals the abductor minimi digiti muscle. The inner division, much the thinnest, may be incautiously removed with the cellular membrane: it covers the abductor pollicis muscle, is attached behind to the internal annular ligament, and is continuous with the fascia of the dorsum of the foot. The *transverse ligament of the toes* is a band of fibres situated in the portions of skin between the toes, preventing their separation: the same is found in the hand. It is attached at the extremities to the sheaths of the great and little toe, and in the interval between them it is stretched across the centre of the metatarsal phalanges, being attached by processes to the sheaths, and forming arches in the intervals between the toes, beneath which pass the digital nerves and vessels. Some of the cutaneous fibres of the central portion of the fascia join this structure.

Transverse Ligament of the Toes.

The flexor tendons for each toe are contained in a sheath which binds them to the grooved surface of the phalanges, with which they are in contact from the head of the metatarsal bone to the last phalanx. This is thicker opposite the centre of the two first phalanges than opposite the articulation, from the presence of two firm cartilaginous bands, which arch over the tendons, and are united to the margins of the phalanges. If the thinner portions be removed, these bands will be more apparent. The sheath is formed in the upper part by the portions of the plantar fascia dipping down; and it terminates on the last or ungual phalanx: this is more distinctly seen in the hand, where the parts are larger. On the sides of the sheath are the digital nerves and vessels.

Sheath of the Tendons.

To examine the septa of the plantar fascia, divide the central portion by an incision along it, separate it from the muscle beneath, and throw back the flaps to the lines that mark the place where these are sent inwards; the cutaneous nerves are to be

Dissection.

left untouched in doing this. Remove also the outer and inner portions of the fascia, and separate the muscles that they cover from the septa; leave the thick process between the os calcis and tuberosity of the fifth metatarsal bone.

Septa of the Fascia.

The septa of the plantar fascia are two vertical processes that dip between the muscles of the foot, so as to divide them into three bundles or sets. The *internal* passes between the abductor pollicis muscle and flexor brevis digitorum to be fixed to the inner side of the tarsus; it is perforated by the internal plantar nerve, gives a sheath to the tendon of the flexor longus pollicis, and sends externally a horizontal process beneath the flexor brevis digitorum to join the external septum, thus giving a sheath to this muscle. The *external septum*, separating the flexor brevis digitorum from the abductor minimi digiti, is perforated by the digital nerve and artery for the outer side of the little toe, and is joined by the process sent to it from the internal.

Internal.

External.

Dissection.

Take away the septa, fascia, and cellular membrane from the foot, taking care, in front, of the digital nerves and arteries. The muscles of the foot are separated by the fascia into three sets: one for the great toe, another for the little, and the intervening one for the other toes; or they are again divided into layers: the first consisting of the abductor pollicis to the inside, the abductor minimi digiti to the outside, and the flexor brevis digitorum muscle between the two others: these are the three now exposed by the dissection.

Abductor pollicis Muscle.

Origin.

The *abductor pollicis*, the most internal of the superficial layer of muscles, is bifurcated behind, but pointed and tendinous in front. It *arises* from the inner side of the large tubercle of the os calcis, from the internal annular ligament, and along the side of the tarsus, from the tendon of the tibialis posticus inserted into the scaphoid bone, some fibres also come from the fascia covering it, and from the intermuscular septum between it and the flexor digitorum. The fibres run obliquely forwards to the tendon, which appears on the cutaneous surface about the midde of the foot, then passes forwards, being joined by fleshy fibres from the flexor brevis pollicis, and is *inserted* into the inner side of the metatarsal phalanx of the great toe, uniting with the tendon of the flexor brevis pollicis: a sesamoid bone is connected with the tendon of insertion. The muscle is in contact with the plantar fascia by its cutaneous surface; and it lies on the plantar vessels and nerves, on the tendons of the muscles seen in the back of the leg, viz. the flexor longus digitorum and flexor longus pollicis, on the accessory muscle to the long flexor, and on the flexor brevis pollicis. The outer border is separated from the flexor brevis digitorum by the internal plantar septum; and the inner corresponds to the tarsus, and insertions of the tibial muscles.

Insertion.

Relations.

The *flexor brevis digitorum* vel perforatus, situated in the centre of the sole of the foot in a sheath of plantar fascia, is pointed at its attachment to the os calcis, but divided about the middle of the foot into four tendons. It *arises* posteriorly from the inner side of the outer tuberosity of the os calcis, between the abductor pollicis and abductor minimi digiti, from the plantar fascia covering it, and from the septa between it and the other muscles of this layer: the fibres run forwards, and end about the centre of the foot in four small tendons, which are placed over the corresponding divisions of the long flexor, pass over the metatarso-phalangeal articulations, covered by the processes of the plantar fascia, and enter the sheaths of the tendons to be *inserted* into the second phalanges. Lay open the sheaths of one or two toes, and each tendon will be seen to be accompanied by a division of those of the flexor longus, which lies beneath it as far as the centre of the metatarsal phalanx; at this point the tendon of the flexor brevis is perforated by that of the flexor longus, which is now superficial, and continues to the last phalanx, into which it is inserted; the tendon of the brevis now placed nearest the bone — the lateral portions into which it was divided having again united — separates about the middle of the second phalanx into two processes, which are inserted into its sides. The flexor brevis is covered by the plantar fascia, and in front by branches of the internal plantar nerve; and it lies on the tendons of the flexor longus and its accessory muscle, and on the external plantar vessels and nerve.

Flexor Brevis Muscle. Origin. Insertion. Relations.

The *abductor minimi digiti muscle*, placed on the outer side of the foot, and the last of the superficial layer, *arises* from the outer tuberosity of the os calcis, from the outer part of the inner tuberosity of the same bone, from the plantar aponeurosis, and from the external septum. The fibres are directed forwards to a tendon, which commences at the base of the fifth metatarsal bone, passes onwards over it, and is *inserted* with the flexor brevis minimi digiti into the outer side of the base of the first phalanx of this toe. The strong plantar fascia covers the cutaneous surface of the muscle. It lies on the long plantar ligament, part of the accessorius muscle, the tendon of the peroneus longus, and the flexor brevis minimi digiti. Along the inner border are the external plantar vessels and nerve, and the outer corresponds to the external side of the tarsus, and the fifth metatarsal bone.

Abductor minimi digiti Muscle. Origin. Insertion. Relations.

Cut through the attachment of these three muscles to the os calcis, and throw them to the toes, noticing at the same time the nerves to the flexor brevis and abductor pollicis muscles from the internal plantar, and that to the abductor minimi digiti from the external plantar nerve. Remove the cellular membrane from the plantar vessels and nerves brought into view, and clean the accessorius muscle, and tendons of the long flexor

Dissection.

of the great toe and of the other toes, which constitute the next layer.

Plantar Arteries. The *plantar arteries* commence at the bifurcation of the posterior tibial artery, in the interval between the heel and inner ankle, and beneath the abductor pollicis muscle. The *internal*, the smallest, runs forwards beneath the abductor pollicis muscle with the plantar nerve, becomes superficial about the middle of the foot in the interval between the abductor pollicis and flexor brevis, and is distributed by small branches to the inner side of the foot and root of the great toe, anastomosing with small arteries from the anterior tibial. Occasionally, this artery passes to the interosseous space between the great toe and the next, joins with a digital artery from the external plantar, and supplies the great toe and the side of the next. The *external plantar*, the principal branch for the supply of the foot, is larger than the other. Its course is first outwards to the border of the foot, then forwards to the base of the fifth metatarsal bone, at this point it again changes its direction, and passes inwards and forwards, crossing the foot a second time, to reach the head of the metatarsal bone of the great toe, where it ends by anastomosing with the anterior tibial; the portion of the artery from the fifth to the first metatarsal bone is the plantar arch, from which the digital arteries are supplied to the toes. The part of the artery that passes outwards to the outer border of the flexor brevis, is covered by the abductor pollicis and flexor brevis muscles, and lies on the os calcis and flexor accessorius muscle; the external plantar nerve accompanies it, lying nearer the calcaneum. As the vessel extends forwards to the base of the little toe, it lies between the flexor brevis and abductor minimi digiti, being superficial, and close to the fascia; and the nerve is still with it. The transverse part towards the great toe, or the plantar arch, is close to the interossei muscles, and will be seen in a future dissection. From the part of the artery now exposed, or to the commencement of the arch, branches are supplied to the muscles and the outer side of the foot, anastomosing with the anterior tibial and posterior peroneal arteries. The digital branch for the outer side of the little toe arises near the base of the fifth metatarsal bone, but the distribution of the digital arteries will be resumed.

Internal.

External.

Branches.

Plantar Nerves. The *plantar nerves*, like the arteries, result from the division of the posterior tibial into two branches behind the inner ankle, but the larger division of the nerve accompanies the smaller branch of the arteries, and *vice versâ*. The *internal*, the largest, supplies branches to the three inner toes, and half the fourth, and also gives filaments to the muscles and integuments on the inner side of the foot. Its direction is forward beneath the abductor pollicis, and to the inner side of the internal septum, which it perforates to enter the sheath of the flexor brevis; it

Internal.

then appears between these two muscles about the centre of the foot, in close contact with the fascia, and divides into four digital branches for the supply of the toes. The muscular branches go to the abductor pollicis and flexor brevis digitorum, these were divided in detaching the muscle; and the cutaneous, are, the cutaneous nerve of the sole, and some plantar filaments that perforate the fascia. Branches.

The digital nerves of the internal plantar are named numerically, according to their position from within outwards. The *first*, for the inner side of the great toe, smaller than the others, crosses the tendon of the flexor longus pollicis, and comes into contact with the tendon of the abductor pollicis, with which it continues to the insertion; the nerve then runs forwards along the inner side of the metatarsal phalanx to the centre of the last, opposite which it divides into a dorsal and plantar branch: the dorsal, small, is directed backwards, and supplies the cutis beneath the nail; and the plantar, continuing in the direction of the trunk, ends in filaments which are distributed to the ball of the great toe, but do not join with the nerve of the inner side. This digital branch sends downwards one or two filaments to the flexor brevis pollicis muscle. The *second* is directed forwards over the first interosseous space, and, appearing beneath the arch formed for it by the fascia, at the cleft between the first and second toes, divides into two branches which are distributed to the contiguous sides of these toes; each subdivides on the last phalanx into a dorsal and a plantar branch, which have the same termination as those of the first. This nerve gives a filament to the first lumbricalis muscle, to the metatarso-phalangeal articulation of the great toe, and cutaneous filaments to both toes. The *third* lies over the second interosseous space, crosses the tendons of the second toe, and at the cleft between the second and third divides into two branches for their opposed sides; on the toes the anatomy is the same as in the others. The second lumbricalis muscle receives a filament from this branch, and the metatarso-phalangeal articulation of the second toe is supplied by it. The *fourth* digital nerve is directed outwards over the tendons to the third toe, reaches the third interosseous space, becomes cutaneous like the others, and is distributed like them to the sides of the third and fourth toes which are in opposition. This branch gives externally a small nerve to join with the external plantar nerve, and filaments to the metatarso-phalangeal articulations of the third and fourth toes. Digital Nerves. First. Second. Third. Fourth.

The *external plantar nerve*, like the artery, consists of a superficial and a deep part: the former giving branches to the little toe and half the fourth, and the latter, to the deep muscles in the sole of the foot. This small division of the posterior tibial accompanies the largest division of the artery, and corresponds External Plantar Nerve.

to the ulnar nerve in the hand, supplying, as it, one toe and a half; whilst the internal is analogous to the median in the same part, and gives nerves to three toes and a half. This nerve has the same course and relations as the artery; it passes beneath the abductor pollicis and flexor brevis digitorum, and over the accessorius muscle, to the interval between the flexor brevis and abductor minimi digiti, where it divides into a superficial and a deep branch: the latter will be seen in a future dissection; but the superficial runs forwards between the muscles, and divides into a digital branch for the outer side of the little toe, and one for the inner part of the same toe and the side of the toe next it. Whilst the trunk of the external plantar is covered by the flexor brevis digitorum, it gives a branch to the accessorius muscle, and one to the abductor minimi digiti, which passes either over or under the accessorius to reach the muscle.

Branches.

Digital Nerves.

The *digital nerves* of the external plantar are two; one to the outer side of the little toe, and one to the contiguous sides of the two last toes. The nerve to the outer side of the little toe crosses the flexor tendons and that of the abductor to reach the outer part of the little toe, to which, and the integuments of the outer side of the foot, it supplies filaments; it is distributed on the last phalanx, as the nerves in the other toes. It gives filaments to supply the short flexor of the little toe, and the interosseous muscles of the fourth space, or these last may come from the other digital nerve. The other digital branch of the external plantar nerve runs forwards over the fourth interosseous space, joins with the filament from the last digital nerve of the internal plantar, and, escaped from beneath the arch of fascia at the cleft of the toes, divides into two branches for the collateral parts of the two last toes; the branches give cutaneous filaments as they extend along the toes, and also articular nerves.

Dissection.

Cut across the internal plantar nerve, also the superficial part of the external, and throw them towards the toes, and a better view of the second layer of muscles is obtained.

Tendon of Flexor longus pollicis.

The *tendon* of the *flexor longus pollicis*, in entering the foot, lies between the heel and inner ankle in a groove in the astragalus and os calcis, in which it is bound down by a strong fibrous expansion. In the sole of the foot it is deeper than the tendon of the flexor longus digitorum, beneath which it crosses, and to which it is connected by a strong tendinous process, and runs inwards and forwards, crossing part of the flexor brevis pollicis, to reach the interval left by the insertion of the two heads of this muscle; the tendon then passes over the metatarso-phalangeal articulation, lying between the sesamoid bones, enters into the fibrous sheath which confines it to the phalanges, and, enlarging before its termination, is inserted into the base of the

last phalanx of the great toe. The sheath of the tendon is lined by a synovial membrane.

Tendon of Flexor Longus digitorum.

The *tendon* of the *flexor longus digitorum*, between the heel and ankle, lies against the internal lateral ligament, rather external or posterior to the tendon of the tibialis posticus, then separates from this tendon, runs forwards and outwards, crossing over the tendon of the flexor longus pollicis, to which it is united, to reach the centre of the foot. At this point the tendon expands, changes its direction to nearly straight, receives the accessorius muscle, and soon after divides into four tendons for the four outer toes, which are directed to the heads of the metatarsal bones, the most external being most oblique, and enter into the sheaths of the toes with the tendons of the short flexor. Opposite the base of the metatarsal phalanx each is beneath the enclosed tendon of the brevis, but about the centre of this bone it perforates that of the brevis, and is continued forwards, superficially to the other, to the last phalanx, into the base of which it is inserted by an expanded portion. Whilst the tendon is contained in the sheath it is lubricated by a synovial membrane. One or two of the sheaths should be laid open to see the tendons. The tendon of the flexor digitorum is frequently enlarged in size where it joins that of the flexor pollicis; and from its division arise the lumbricales muscles.

Lumbricales Muscles.

The *lumbricales muscles*, so called from their form, are four roundish fleshy bundles which decrease in size from the inner to the outer side of the foot; they are named numerically, and the first is the most internal.

Origin.

The first *arises* from the inner border and under part of the tendon for the second toe, and the three remaining from the tendons between which they are placed: the fibres run forwards, ending in small tendons, which appear with the nerves beneath the plantar fascia, and are *inserted* into the inner or tibial side of the base of the metatarsal phalanx of the four outer toes, sending an expansion to the dorsum to join with the tendons of the interossei.

Insertion.

Relations.

The muscles are covered by the short flexor and plantar fascia, and lie on the interossei and the next layer of muscles.

Accessory Muscle.

The *accessory muscle** to the long flexor is bifurcated behind, and by its action on the oblique direction of the tendon of the long flexor, it tends to bend directly backwards the toes.

Origin.

Its *origin* is by two distinct portions from the inner and under surfaces of the os calcis, the ligamentum longum plantæ appearing between the two, and giving attachment to the fibres: the muscular fibres pass inwards and forwards to join the tendon of the flexor longus digitorum about the centre of the foot, or near where it divides, — the inferior being inserted into the under part of the tendon, and the superior into the upper surface, so as to form a kind of canal for it.

Insertion.

Relations.

It is covered by the external

* Or sometimes, massa carnea Jacobi Sylvii.

plantar artery and nerve, by the abductor pollicis and flexor brevis digitorum, and the outer origin, by the abductor minimi digiti; and it lies on the os calcis, and calcaneo-cuboid ligament.

Dissection. Cut through the tendons of the second layer, and the accessorius muscle, about the middle of the foot, and turn them towards the toes, without injuring the deep branches of the external plantar artery and nerve, or the small filaments from the nerve to the two outer lumbricales muscles: remove the posterior part of this layer. The next layer of muscles, situated over the metatarsal bones, consists of those which belong to the great and the little toe; thus on the metatarsal bone of the great toe is the flexor brevis pollicis; external to this muscle and larger than it, but crossing obliquely the foot, is the adductor pollicis; on the metatarsal bone of the little toe is the flexor brevis minimi digiti muscle, which appears like one of the interossei, and crossing the heads of the metatarsal bones is the transversalis pedis muscle. The fleshy mass beneath the deep plantar artery and nerve belongs to the next layer, or the interossei.

Flexor brevis pollicis Muscle. The *flexor brevis pollicis muscle*, pointed behind, but large and bifurcated in front, is attached posteriorly, by a tendon, to the cuboid bone, and to the prolongation from the tendon of the tibialis posticus to the external cuneiform bone. From this

Origin. tendon the muscular fibres *arise*, pass forwards, and divide, near the digital extremity of the metatarsal bone of the great toe, into two portions or bellies, between which passes the tendon of the long flexor: the inner unites with the tendon of the ab-

Insertion. ductor pollicis, and is *inserted* into the internal part of the base of the metatarsal phalanx and the corresponding sesamoid bone; and the outer head joins with the tendon of the adductor pollicis, and is attached to the external side of the base of the bone,

Relations. as well as to the sesamoid bone of the same side. The abductor pollicis and tendon of the long flexor of the great toe lie on it; and it covers the metatarsal bone of the great toe, and the tendon of the peroneus longus inserted into the base of this bone. The outer border is contiguous to the adductor pollicis.

Adductor pollicis Muscle. The *adductor pollicis muscle*, larger than the preceding, and external to it, *arises* posteriorly from the sheath of the tendon of the peroneus longus, formed by fibres of the long plantar

Origin. ligament passing over it, and from the heads of the third and fourth metatarsal bones. The fibres form a thick fleshy belly, and end in a tendon, which unites with the outer head of the

Insertion. flexor brevis, and is *inserted* into the outer sesamoid bone, and outer part of the base of the metatarsal phalanx of the great

Relations. toe. The second layer of muscles covers the adductor, and it lies on the plantar artery and nerve, and the interossei muscles. The inner border is in relation with the flexor brevis pollicis;

and the outer, with the deep plantar vessels and nerve, which enter beneath this border.

The *flexor brevis minimi digiti muscle*, lying on the metatarsal bone of the little toe, and resembling one of the interossei, *arises* from the under surface of the metatarsal bone of the little toe, and slightly from the sheath of the peroneus longus. It is a thin narrow muscle, and is *inserted* into the outer side of the base of the metatarsal phalanx of the little toe. The muscle is concealed by the abductor minimi digiti. It lies on the metatarsal bone of the little toe, and is in contact internally with the most external plantar interosseous muscle. Flexor brevis minimi Digiti. Origin. Insertion. Relations.

The *transversalis pedis*, a small muscle extended transversely across the heads of the metatarsal bones, *arises* from the heads of the four outer metatarsal bones by small fleshy bundles which unite together, and it is *inserted* with the adductor pollicis into the outer side of the base of the metatarsal phalanx of the great toe. The cutaneous surface of the muscle is crossed by the tendons of the long and the short flexor of the toes, by the digital branches of the plantar nerve, and by the lumbricales muscles. The deep surface rests on the heads of the metatarsal bones, and the interossei muscles. Transversalis Pedis. Origin. Insertion. Relations.

Divide the flexor brevis and adductor pollicis muscles at their origins, and turn them forwards to the toes, without injuring much the nerves that supply them, and the arch of the external plantar artery with its nerve are seen, together with the interossei muscles which are covered by a strong fascia. Dissect out the branches of the nerve and artery. The flexor brevis minimi digiti muscle, belonging to the third layer, may be detached, and thrown forwards. In the posterior half of the foot, behind the muscles, are seen some of the ligaments, and the tendons of the peroneus longus and tibialis posticus muscles. Dissection.

The *plantar arch* of the external plantar artery, now exposed, extends obliquely forwards across the posterior extremities of the metatarsal bones, from the base of that of the little toe to the posterior extremity of the first interosseous space, and ends by joining a communicating branch from the anterior tibial. The arch formed by the artery in this course is convex forwards, is close against the interossei muscles, and is covered by the adductor pollicis and the two other layers of muscles. From the concavity of the arch branches pass backwards to supply the muscles; from the under part are given off the three posterior perforating arteries, which pass through the posterior part of the three outer interosseous spaces, and join the interosseous branches on the dorsum of the foot from the anterior tibial; and from the convexity spring the four digital arteries for the supply of the three outer toes and half the next, or the same number as from the ulnar in the hand. Plantar Arch. Branches.

The *digital branches*, with the exception of that for the outer Digital Branches.

side of the little toe, run forwards in the three outer interosseous spaces to the clefts between the toes, and lie on the interosseous muscles, but beneath the transversalis pedis. At this point they give off the anterior perforating arteries, which join with the dorsal interosseous of the anterior tibial, and each then divides into two branches for the supply of the sides of the toes between which it is placed. Along the toes the arteries have the same arrangement as in the fingers; they are accompanied by the digital nerves, send cross branches beneath the tendons, near the front of the first and second phalanges, which anastomose together and supply the articulations; and, on the last phalanx, they turn towards one another, and unite in an arch, from which numerous small arteries are given off to the extremity of the finger. The digital branch to the outer side of the little toe, arising more posteriorly than the others, continues forwards, supplying it in the same way as the others, and anastomosing at the extremity with the branch of the opposite side; as it extends along the sole of the foot, it communicates with the tarsal and metatarsal arteries of the dorsum.

Anterior tibial of the Foot.

The termination of the *anterior tibial artery* supplies digital branches to the great toe, and to half the next, in the same manner as the radial in the hand is distributed to the thumb and half the index finger.* The artery enters the sole of the foot at the posterior part of the first interosseous space, gives a

Communicating.

communicating artery, which is variable in size, to join the external plantar, and so complete the arch; and a digital branch,

Magna Pollicis.

the *magna pollicis artery*, which runs forwards along the outer border of the metatarsal bone of the great toe to near its anterior extremity, gives off the internal collateral branch of this toe, which passes inwards beneath the flexor brevis pollicis and tendon of the flexor longus, and then forwards with the nerve to the last phalanx, where it ends as the rest; whilst the continuation of the artery reaches the cleft between the two first toes, and divides into two branches for the supply of their contiguous sides.

Dissection.

Remove the transversalis pedis and digital branches of the arteries, if necessary, and clean the surface of the transverse metatarsal ligament which connects the heads of the metatarsal bones. The deep branch of the external plantar nerve will be more readily seen when the interossei are afterwards separated, and the fascia removed from their surface.

Metatarsal Ligament.

The *transverse metatarsal ligament* is a strong fibrous band connecting together the heads of the metatarsal bones, and is placed rather before and beneath the transversalis pedis. Its cutaneous surface is in contact with the tendons of the flexors of the toes, with the lumbricales, and digital vessels, and is joined

* In some instances this artery is very small, and appears only to join the plantar arch, which then gives off all the digital branches to the toes.

by the processes of the plantar fascia, which assist to form the upper part of the sheaths of the tendons; and its deep surface rests upon the articulations between the metatarsal bones and the phalanges, and on the interossei muscles. A thin fascia that covers the interossei, sending processes between them, is connected to the posterior border.

Dissection. Divide the transverse ligament in the intervals between the heads of the bones, which will give the line of separation between the two interossei muscles of a space; take away the fascia covering these muscles, and carefully separate them to see the small nerves supplying them.

External plantar Nerve. The *deep branch* of the *external plantar nerve*, with the plantar arch of the artery, passes deeply, from its origin, beneath the second layer of muscles, then between the second and third, and ends by supplying the adductor pollicis, which is superficial to it. The nerve distributes, besides, many filaments to the other deep muscles; thus, before entering beneath the adductor, it gives a small filament to the fourth or most external lumbricalis muscle, to the dorsal interosseous muscle of the fourth space, if this does not receive its nerve, like the plantar muscle of this space, from the superficial division of the external plantar, and also filaments to the articulations of the tarsus and metatarsus. Under the adductor it divides into many branches; some enter this muscle, one long filament goes to the third lumbricalis muscle, another to the transversalis pedis, and all the other interossei muscles are supplied from it.

Interossei Muscles. The *interossei muscles*, like those in the hand, are seven in number, two being found in each interosseous space, except the first, which has only one; all of them are seen in the dissection of the sole of the foot, and they are classed from their position into plantar and dorsal.

Plantar. The *plantar*, three in number, are adductors* to an imaginary line passing through the centre of the second toe, and are inserted into the inner or tibial side of the metatarsal phalanx of the three outer toes, to draw them to the others; they are smaller than the dorsal, and are situated more in the sole of the foot, since they are placed on the plantar surface of the metatarsal bones from which they arise. They arise from the three external metatarsal bones, being attached to their under and inner surfaces, and extending back to their heads, with the exception of the most internal, which occupies only the two lower thirds of the third metatarsal bone: the fibres end in tendons, which pass to the inner or tibial side of the metatarso-phalangeal articulations, and are inserted into the same side of the base of the metatarsal phalanx, sending off an expansion to join with the extensor tendon on the dorsum of the bone.

Dorsal. The *dorsal*, larger than the plantar, are four in number, one

* See Cruveilhier, *Anatomie Descriptive*, t. ii. p. 284.

being placed in each space, and are abductors from the same imaginary line, the second toe having two muscles which direct its extremity to either the right or the left of the line; and the third and the fourth, one to the radial or outer side of the metatarsal phalanx of each, to separate it from the rest. They arise by two heads from the dorsal and lateral surfaces of the two bones between which they are situated, but more particularly from the fibular or outer surface: the fibres converge from each side to a central tendon, which becomes free opposite the metatarso-phalangeal articulations, and is inserted as the others into the side of the metatarsal phalanx, an expansion being also sent off to join the tendon on the dorsum.

Relations. The interossei muscles close the spaces between the metatarsal bones, and form the deep or fourth layer of the sole of the foot. They are covered by the fascia connected to the transverse metatarsal ligament, and the plantar arch and deep nerve are in contact with them. The posterior extremities of the dorsal ones are perforated by the posterior perforating arteries; the dorsal are also covered by the parts on the dorsum of the foot.

Dissection. Follow the tendon of the tibialis posticus to its insertion into the scaphoid bone, and remove the cellular membrane from the processes that it sends off. The tendon of the peroneus longus is seen crossing the foot from the outer to the inner side, contained in a fibrous sheath; but this may be omitted till the muscle is examined.

Tendon of Tibialis Posticus. The *tendon* of the *tibialis posticus,* after passing through the annular ligament, runs forwards along the inner margin of the foot to the lower part of the prominence of the scaphoid bone, into which it is inserted; it is in contact with the internal lateral ligament, and with the inferior calcaneo-scaphoid ligament, which it supports in the erect posture of the body, a sesamoid bone being often developed in it at this spot. From the insertion, a tendinous process passes forwards to the under surface of the internal cuneiform bone, and serves as an inferior ligament between the bones; another portion, stronger and thicker, to the external cuneiform bone, which acts as a ligament to this bone, and gives attachment to the flexor brevis pollicis; and a short thick process is directed backwards to the margin of the groove in the os calcis for the tendon of the flexor longus pollicis: occasionally there is another thin triangular portion, which is connected to the inner and under part of the cuboid bone.

DISSECTION OF THE FRONT OF THE LEG.

Dissection.

Continue the dissection of the extremity with the front of the leg. The limb may be raised by blocks placed beneath the knee, and the foot is to be extended. Divide the integuments along the centre to the ankle, and at this part make a transverse incision, remove the skin from the leg, and seek the musculo-cutaneous nerve, which perforates the fascia about the lower third, and some small filaments of the saphenus on the inner side. Carry forwards the incision to the toes, and take the integument from the back of the foot, without injuring the arch of veins which ends internally in the long or internal saphena, and externally in the short saphena. The branches of the musculo-cutaneous nerve cross the arch of veins, and supply the toes; in the interval between the first and second toes is found a cutaneous nerve of the anterior tibial; on the outer side of the foot with the vein, the external saphenus nerve; and the internal, with its vein, on the inner side.

Cutaneous Veins. Venous Arch.

The *venous arch*, from which the cutaneous veins arise, is placed across the back of the foot, the convexity towards the toes, and it ends on the inner side in the internal, and on the outer, in the external saphena. By its convexity it receives the small digital branches, and by the concavity some small veins of the dorsum.

Internal Saphena.

The *internal saphena vein*, commencing at the inner part of the arch on the back of the foot, ascends along the inner side of the tarsus, then in front of the inner ankle, and along the inner side of the leg with the saphenus nerve. In its course along the tarsus it receives branches from this part, from the plantar region, and particularly some large ones from about the os calcis; and in the leg, some branches turning over the spine of the tibia.

External Saphena.

The *external saphena vein* begins in the outer extremity of the arch, passes backwards along the side of the foot, receiving branches from the plantar region and back of the foot; it then turns upwards below the outer ankle, and pursues its course along the posterior part of the leg, to open into the popliteal vein. As it passes by the outer ankle, it is joined by a vein from the outer side of the os calcis.

Cutaneous Nerves. From Saphenus.

The upper part of the leg is supplied by nerves from the internal saphenus on the inner side, from the cutaneous of the external popliteal on the outer side, and some descend from the nerves which are distributed over the patella.

Musculo-cutaneous.

The *musculo-cutaneous nerve*, a large branch of the external popliteal at the head of the fibula, supplies the integuments of the lower part of the leg, of the dorsum of the foot, and all the toes,

except the contiguous sides of the great toe and the next, which receive the anterior tibial, and the outer side of the little toe, to which the external saphenus nerve is distributed. The nerve becomes cutaneous rather below the middle of the leg, sends outwards some cutaneous twigs, and, after a short course, divides into an internal and external branch. The internal division passes over the ankle-joint to the inner side of the foot, gives some filaments to join the internal saphenus nerve, and is finally distributed to the inner side of the foot and the great toe; a branch also joins with the cutaneous part of the anterior tibial in the interval between the first two toes. The external division, the largest, descends almost vertically to the foot, and divides into three branches, which run forwards over the three outer interosseous spaces, dividing at the clefts of the toes into branches for the supply of the contiguous sides, thus giving filaments to the four outer toes, except to the tibial side of the second, which is supplied by the anterior tibial, and to the fibular side of the little toe, to which the external saphenus is distributed; this division joins the external saphenus on the outer side of the foot. The digital branches may be traced in the integument of the dorsal surface as far as the extremities. Occasionally this nerve divides beneath the fascia, and the branches perforate separately at different heights.

Cutaneous of anterior tibial. The *cutaneous part* of the *anterior tibial nerve* appears at the posterior extremity of the first interosseous space, by perforating the fascia; it joins with a branch of the musculo-cutaneous, and divides into two nerves for the opposed sides of the first and second toes. Sometimes there is, in addition, a separate nerve from the musculo-cutaneous distributed to this space.

Internal Saphenus. The *anterior branch* of the *internal saphenus nerve* passes with the vein in front of the lower extremity of the tibia, and along the inner part of the foot to about the centre, where it ends in very fine twigs for the integument and inner side of the foot; but these do not extend to the great toe, which is supplied from the musculo-cutaneous.

External Saphenus. The *external saphenus nerve*, formed, in the lower third of the leg, by the communicating saphenus branches of the internal and external popliteal nerves, as before seen, passes below the outer ankle and along the outer side of the foot, giving numerous branches to this region, and ends by being distributed to the outer side of the little toe. It is joined by a nerve from the musculo-cutaneous. This nerve sometimes supplies the whole of the little toe and part of the next.

Fascia of the Leg. The proper *fascia of the leg*, seen when the superficial cellular structure is removed, is thick and strong above, and formed by oblique fibres, but thinner below, and the fibres are more circular: it is fixed, internally, to the spine of the tibia, and externally, to the fibula, so as to separate the muscles on the front

from those on the outer part of the leg, and other smaller processes pass between the different muscles, giving them increased points of attachment; white lines mark the position of these intermuscular septa. The fascia is connected above to the heads of the tibia and fibula, and is continued below to the dorsum of the foot, but as a very thin membrane; opposite the lower extremity of the tibia and the ankle-joint it is thickened by transverse fibres, and forms the anterior annular ligament; below the extremity of the fibula is another thickened band, or the external annular ligament.

Dissection. Remove the fascia from the leg and dorsum of the foot, leaving untouched the anterior annular ligament, which consists of a thickened portion above the end of the tibia, and of another below it; in separating it from the anterior set of muscles, direct the scalpel upwards instead of downwards. The muscles in front of the leg are, the tibialis anticus next the tibia, the extensor longus digitorum next the fibula, its lower part with a separate tendon to the metatarsal bone being called peroneus tertius, and between them the extensor pollicis. Clean the outer muscles or the peronei, and leave the external annular ligament, below the fibula, which binds them down.

Anterior annular Ligament. The *anterior annular ligament,* formed by strong thickened fibres superadded to the fascia, consists of a portion above the extremities of the bones, which confines the vertical part of the muscles, and of another over the tarsus, to bind the horizontal part or the tendons to the foot; each is divided into compartments for the passage of the tendons. The *upper portion,* less perfect but stronger than the lower, is attached externally to the lower part of the fibula, and internally to the tibia; the upper border joins the fascia of the leg, and the lower, a thin portion of the fascia intervening between the two. Only two sheaths are found in it: one next the tibia contains the tendon of the tibialis anticus, and the other, external to this, the tendons of the extensor communis and peroneus tertius, whilst the tendon of the extensor pollicis, and the tibial artery and nerve lie beneath it. The *lower portion,* situated in front of the tarsal bones, is inserted externally by a thick strong process into the upper surface of the os calcis, in front of the depression for the interosseous ligament, and internally, where it is thinner and wider, into the internal malleolus and plantar fascia. This division has three sheaths; one externally for the tendons of the extensor longus digitorum and peroneus tertius, one to its tibial side for that of the extensor pollicis, and the other, still more internal, is for the tibialis anticus, but the artery and nerve are still beneath the ligament, and situated beneath the sheath for the tendon of the extensor pollicis. Separate synovial membranes lubricate the several sheaths.

Upper Portion.

Lower.

The *external annular ligament,* a thickened band below the

Externa annular

Liga-ment. fibula, is attached, above, to the lower extremity of the outer malleolus, and below, to the external surface of the os calcis. It confines the tendons of the peronei muscles in a sheath which is lined by a synovial membrane.

Tibialis Anticus Muscle. The *tibialis anticus*, the largest of the muscles on the front of the leg, is thick and fleshy above, and tendinous below; in the upper part it lies to the outer side of the tibia, but below it is Origin. in front of it, and crosses to its inner side. It *arises* from the outer tuberosity of the tibia, from the two superior thirds of the outer surface of this bone, from the interosseous ligament internal to the anterior tibial artery, and from the fascia of the leg and the intermuscular septum between it and the next muscle. The fibres descend and end in a tendon, which appears on the surface in the lower third of the leg, but is free from muscular fibres only at the annular ligament, then enters the innermost partition in the ligament, and is placed over the lower end of the tibia and the ankle-joint; escaped from the ligament, it passes over the articulation between the astragalus and Inser-tion. scaphoid bones, and is *inserted* into the inferior and internal surface of the internal cuneiform bone, a process being also sent forwards beneath the articulation between the internal cuneiform and metatarsal bone of the great toe, to join the under Rela-tions. surface of the tarsal extremity of the metatarsal bone. The muscle is covered only by the fascia and annular ligament; and it lies on the tibia, part of the interosseous membrane, on the tibio-tarsal articulation, and on the astragalus, scaphoid, and internal cuneiform bones of the tarsus. The inner border corresponds to the tibia, and, below this bone, to the abductor pollicis muscle; and the outer touches, in the leg, the extensor longus digitorum, and extensor pollicis, the anterior tibial vessels and nerves interposing, and on the foot, the tendon of the extensor pollicis is by the side.

Exten-sor pro-prius Pollicis. The *extensor proprius pollicis muscle*, thin and flat, is situated deeply between the tibialis anticus and extensor longus, at its origin, but superficially below; like the other muscles, the tendon of insertion is on the cutaneous surface, and the muscular fibres continue with it to the lower border of the annular liga-Origin. ment. The muscle *arises* from the middle part of the inner surface of the fibula in front of the interosseous ligament, and from the ligament near it: the fibres descend to the tendon, which passes beneath the upper portion of the annular ligament with the artery, though external to it; but at the lower portion it quits the vessel, and enters into the partition in front of it. From the lower border of the ligament it extends forwards over the inner part of the tarsus, first metatarsal bone and its phalanges, being connected to the first by a tendinous expansion, and is Inser-tion. finally *inserted* into the base of the second or last phalanx. The muscle is partly concealed by the tibialis anticus and extensor

communis, and is covered by the fascia and annular ligament; and it lies on the fibula, interosseous membrane, lower extremity of the tibia, over the tibio-tarsal articulation, on the bones of the tarsus, and on the first metatarsal bone. To the outer side is the extensor longus digitorum, as low as the annular ligament, but below this is the dorsal part of the anterior tibial artery, and on the toe, the tendon of the extensor brevis. To the inner, are the tibialis anticus, and tibial vessels and nerve, but below the ligament the vessels lie to the outer side, so that the tendon of this muscle crosses the vessels whilst it is in the lower division of the ligament, and is found to their inner side at the lower border of this structure. Relations.

The *extensor longus digitorum*, situated next the fibula to which it is attached, is large and fleshy above, but divided below into four tendons; and it consists of a vertical part which acts on the foot by means of the annular ligament, and of a horizontal, for the movement of the toes. Extensor longus Digitorum.

It *arises* from the outer part of the tuberosity of the tibia, from the head of the fibula, and from three fourths of the inner surface of this bone in front of the interosseous membrane, from the fascia of the leg, and intermuscular septa between it and the tibialis anticus internally, and the peronei externally. The upper fibres are directed vertically, the lower obliquely to the tendon, which is accompanied by them to the annular ligament, and divides into three portions, which enter the same sheath as that of the peroneus tertius, and are lubricated by the same synovial membrane; whilst traversing the ligament the inner tendon divides into two, so that four appear at its lower border, and diverge from each other, crossing the extensor brevis digitorum, to reach the four outer toes, on the metatarsal phalanx of which they form an expansion, by uniting with the inner border of the tendons of the extensor brevis, and with those of the interossei and lumbricales, which come up from beneath. At the distal extremity of this phalanx, as in the fingers, the expansion divides into three portions — the central one is fixed to the base of the second phalanx, but the lateral extend along its sides, converge at its anterior part, and unite to be *inserted* into the ungual or last phalanx. Origin.

The fascia and annular ligament cover the muscle, and it lies on the fibula, interosseous membrane and lower extremity of the tibia, over the articulation of the ankle, and, on the foot, on the extensor brevis and phalanges. To the outer side, in the leg, are the peroneus longus and brevis muscles, and on the foot, the peroneus tertius; and to the inner, above, the tibialis anticus, vessels, and extensor pollicis; and on the foot, the dorsal part of the anterior tibial artery. Insertion. Relations.

The *peroneus tertius muscle*, only a part of the extensor longus digitorum from which it is seldom separate, *arises* from the lower fourth of the inner surface of the fibula, below the extensor Peroneus tertius Muscle. Origin.

longus, and from the intermuscular septum between it and the peroneus brevis: the fibres descend to a tendon, which passes with those of the extensor longus through the same partition of the annular ligament; below the ligament it separates from the others, is continued downwards and outwards over the extensor brevis, and is *inserted* by a tendinous expansion into the upper edge of the tarsal extremity of the metatarsal bone of the little toe. This muscle has nearly the same relations as the long extensor; it is covered by the fascia, and lies on the lower part of the fibula, and on the extensor brevis muscle.

Insertion.

Relations.

Anterior tibial Artery. The *anterior tibial artery* extends from the bifurcation of the popliteal to the posterior part of the first interosseous space on the dorsum of the foot, where it dips into the sole, and ends by supplying the great toe and half the next, and joining the plantar arch. The course of the artery is first forwards through the interosseous membrane, then vertically downwards and inwards through the leg, and, finally, almost horizontally forwards on the inner side of the foot. From the marked difference in its direction and relations in the leg and the foot, it may be divided, for the sake of description, into a vertical and a horizontal part.

Vertical portion. The *vertical portion* in the leg, which reaches to the lower border of the annular ligament, or to the prominent head of the astragalus, is external to the tibia in the upper part, but in front of it and the ankle-joint in the lower; and a line from the head of the fibula to the centre of the ankle will nearly mark the position of the artery. It is covered by the common integuments and fasciæ, and its depth from the surface differs in the upper and lower parts of the leg; for in the two upper thirds it is deeply placed between the tibialis and extensor longus, but in the lower third it is more superficial, in consequence of the muscles having terminated in tendons, though it is still overlapped by them, and it is covered still lower down by the annular ligament, and tendon of the extensor pollicis, which crosses it. It rests on the interosseous membrane in the two upper thirds, on the front of the tibia in the lower third, then on the anterior ligament of the ankle-joint, from which it is separated by cellular membrane, and finally on the astragalus. As the artery passes from the back to the front of the leg it is above the interosseous membrane, close to the neck of the fibula, and between the two heads of origin of the tibialis posticus muscle. In the upper third of the leg it is placed between the tibialis anticus and extensor longus digitorum; in the middle, between the tibialis anticus and extensor pollicis; and in the lower third, between the same muscles, being overlapped by the extensor pollicis; and this relation to the extensor it keeps beneath the upper portion of the annular ligament, though at the lower, the muscle leaves the vessel to pass through the ligament, but is still superficial to it, and is found to the inner side

of the artery only at the lower border of the ligament. Two veins accompany the artery, forming by their cross branches a plexus over it. The anterior tibial nerve comes into contact with the artery about the middle third of the leg, and is placed to its outer side; it crosses the vessels once or twice in the leg, but beneath the annular ligament it is found external to them. This portion of the anterior tibial gives off numerous muscular branches in the leg. The *horizontal portion*, or dorsal artery of the foot, intervenes between the lower border of the annular ligament and the posterior part of the first interosseous space, where it gives off a superficial interosseous branch, and then enters the sole of the foot by perforating the interosseous muscle. It is here very superficial, being covered only by the integuments and fascia, and near its termination it is crossed by the internal tendon of the extensor brevis muscle; and it lies on the astragalus, scaphoid, and internal cuneiform bones. To the inner side is the tendon of the extensor pollicis, and to the outer, the internal tendon of the extensor brevis; but as this inclines inwards it crosses the artery about half an inch before it dips into the sole of the foot, so that the vessel then lies between a tendon of the extensor longus to the outer side, and one of the extensor brevis to the inner. The veins have the same relation to this part of the artery, and the nerve, still external to it, becomes cutaneous when the artery dips into the foot, and supplies the sides of the first two toes. The branches of the anterior tibial are many; some unnamed to the muscles, and other named ones to the parts by which it passes, as follow: —

Horizontal.

Branches.

The *recurrent branch* leaves the trunk as soon as it has passed through the space above the interosseous membrane, is directed upwards through the tibialis anticus muscle, and on the head of the tibia divides into branches; some ascend to anastomose with the inferior external articular artery, and others turn inwards over the articulation, supplying it, and anastomosing with the other articular branches in front of the joint.

Recurrent.

A *cutaneous branch* arises from the upper part, descends beneath the extensor longus with the musculo-cutaneous nerve, and is distributed to the integuments with it.

Cutaneous.

The *internal malleolar artery* arises above the lower extremity of the tibia, runs inwards beneath the tibialis anticus, turns to the inner surface of the bone, and anastomoses on the inner malleolus with a similar branch from the posterior tibial.

Internal malleolar.

The *external malleolar*, more variable in its point of origin than the preceding, but, generally, nearly opposite to it, runs outwards to the fibula beneath the extensor muscles, and joins with the anterior peroneal branch which comes forwards through the space below the interosseous membrane, and also with a branch sent round the fibula, forming thus an arterial anastomosis over the outer ankle.

External malleolar.

Articular. As the artery passes by the ankle joint it gives *articular branches* to it; these enter it by perforating the capsular ligament.

Tarsal Artery. The *tarsal artery*, a branch opposite the scaphoid bone, runs outwards beneath the extensor brevis digitorum to the outer side of the foot, anastomoses with the peroneal and external plantar arteries, and gives branches to the extensor, to the bones of the tarsus and their articulations: these will be seen when the muscle is divided. This artery varies much.

Metatarsal. The *metatarsal branch*, given off near the heads of the metatarsal bones, runs outwards across the tarsus to the outer side of the foot, forming an arch, and anastomosing with the external plantar. From the convexity of the arch three small interosseous branches are given off; these run on the interossei muscles in the three outer spaces, supplying the muscles, and divide at the clefts between the toes into two branches for the sides of the toes, on the dorsal surface, like the digital branches from the plantar arch on the palmar. At the posterior part of the interosseous spaces, these branches are joined by the posterior perforating from the plantar arch, and, in front, by the anterior perforating from the digital arteries.

Interosseous. The *interosseous branch* springs from the anterior tibial as it is about to enter the sole of the foot, runs forwards in the interosseous space between the first two toes, supplying their sides, like the other interosseous branches from the metatarsal.

Veins. The *anterior tibial veins* have the same extent and relations as the artery; there is one on each side of the artery, and they form a plexus of cross branches over it, particularly in the upper part. They pass with the artery through the aperture in the interosseous ligament, and join with the posterior tibial in the internal popliteal. They receive branches corresponding to those of the artery, and join by a branch with the internal saphena vein.

Dissection. To examine the extensor brevis digitorum, which is the only muscle on the dorsum of the foot, cut through the tendons of the extensor longus and peroneus tertius, below the annular ligament, and throw them to the toes; remove the cellular membrane from the surface of the muscle.

Extensor brevis Digitorum. The *extensor brevis digitorum*, a short thin muscle, and the only one on the dorsum of the foot, is divided like the long extensor into four tendons, but these pass to the four inner,

Origin. instead of the four outer toes. It *arises* from the anterior part of the upper surface of the os calcis, in front of the depression for the attachment of the interosseous ligament, and from the thickened part of the annular ligament, which is fixed to this depression. The fibres run forwards and inwards, forming four fleshy bellies, and end in four tendons, which are directed obliquely inwards to the four inner toes, passing beneath the

tendons of the long extensor, and sending down, as in the extensors of the hand, a tendinous expansion on each side of the articulation between the metatarsal bones and the phalanges; on the metatarsal phalanx the tendons join the fibular side of those of the long extensor, and form an expansion on this bone with the lumbricales and interossei, as before seen in the dissection of the long extensor. The tendon to the great toe is the largest, and is *inserted*, separately, into the base of the metatarsal phalanx. The muscle is covered by the tendons of the long extensor; and it lies on the bones of the tarsus, and branches of the anterior tibial nerve and artery, which will be seen when the muscle is divided. The inner border corresponds to the horizontal part of the anterior tibial artery, and the inner tendon crosses this vessel.

Insertion.

Divide the extensor brevis, and turn it upwards with care, so as not to injure the branches of the anterior tibial artery and nerve, which are beneath it and supply it. Cut through the lower portion of the anterior annular ligament over the sheath of the extensor pollicis, and the position of the anterior tibial artery and nerve are exposed; throw outwards the external half of the ligament, examining its different sheaths, its attachment to the bone, and the origin of the extensor brevis digitorum from it. Clean the cellular membrane from the divisions of the anterior tibial nerve beneath the extensor; these lie in a ligamentous substance, and are soft and enlarged; follow the nerves in the upper part of the leg to their origin from the external popliteal, and trace a small branch through the tibialis anticus to the knee-joint.

Dissection.

The nerves of the front of the leg are derived from the external popliteal (peroneal), which divides at the head of the fibula, and beneath the peroneus longus muscle, into the recurrent, musculo-cutaneous, and anterior tibial branches.

Nerves.

The *recurrent articular nerve*, the smallest of the branches of the popliteal, passes transversely inwards beneath the extensor longus digitorum to the anterior tibial recurrent artery, which it accompanies through the tibialis anticus, and gives some filaments to the muscle; it then leaves the muscle, and ascends with the artery to the knee-joint, to which it is distributed.

Recurrent articular.

The *musculo-cutaneous nerve*, named from its distribution, descends vertically in the leg, lying deeply between the extensor longus digitorum and peroneus longus, then between the extensor and the peroneus brevis, perforates the intermuscular septum and the fascia about the lower third of the leg, and divides into two branches for the dorsum of the foot and the toes, as was before dissected. In the leg it gives a branch near its commencement to the peroneus longus, and one lower down to the peroneus brevis muscle.

Musculocutaneous.

Branches.

The *anterior tibial nerve*, the only remaining branch, runs

Anterior tibial.

downwards and inwards beneath the extensor longus, comes into contact with the artery at the middle third of the leg, descends with the vessels, crossing them once or twice; but at the annular ligament it is external to the artery, and divides into an external and an internal branch. It has the same relations as the artery to muscles; and as it extends along the leg it gives branches to the tibialis anticus, extensor longus digitorum, and extensor pollicis. The internal branch of division runs forwards with the artery on the dorsum of the foot, lying external to it; and when the artery enters the sole it perforates the fascia, joins the musculo-cutaneous, and is distributed to the opposed sides of the first two toes; it gives a small filament to the interosseous muscle of the first space. The external branch, the larger of the two, is directed outwards beneath the short extensor of the toes, and divides into branches for that muscle and the interossei. It enlarges, before dividing, like the nerves of the hand, and its filaments are enveloped in a fibrous tissue, through which it is very difficult to follow them.

Branches to the muscles.

Internal branch.

External.

Dissection.

The remaining muscles of the leg are the two peronei, which are placed on the outer side of the fibula, and are named from their relative length, longus and brevis. They are separated by processes of fascia from the muscles in front and behind, and will be exposed by removing the fascia from their surface, if it is not already done.

Peroneus longus Muscle.

Origin.

The *peroneus longus muscle*, the most superficial, *arises* from the outer and anterior part of the head of the fibula, from the upper half of the outer surface of the bone, and from the outer border for some distance below, from the intermuscular septa before and behind, and from the aponeurosis of the leg. The fibres descend, forming a muscle which is thick above and flattened below, and terminate about the middle of the leg in a tendon, which descends vertically on the peroneus brevis, being closely united to its tendon, receives the lower fibres of origin by its posterior border, enters the groove behind the external malleolus, and passes beneath the external annular ligament with the tendon of the peroneus brevis, from which it is separated only by synovial membrane; escaped from the ligament, the tendon runs forwards along the side of the os calcis as far as to the groove in the outer border of the cuboid bone, being placed below the tendon of the peroneus brevis, and attached to the bone by a separate sheath, enters the sole of the foot, crosses it obliquely inwards and forwards to the great toe, and is *inserted* into the inner side of the base of the first metatarsal bone. In the leg it is covered only by the integuments and fascia; and it lies on the fibula and peroneus brevis muscle. The anterior border is separated from the extensor longus digitorum by a process of fascia and the musculo-cutaneous nerve; and the posterior, from the soleus and flexor pollicis longus also by the

Insertion.

Relations.

fascia. Beneath the external annular ligament it is placed on the middle portion of the external lateral ligament of the ankle with the tendon of the brevis, and both are surrounded by one synovial membrane, which sends prolongations into the sheaths on the side of the os calcis. On the outer side of the foot it is subcutaneous, and lies on the os calcis and cuboid bone, and the articulation between the two. In the sole it is close to the tarsus, and crosses the cuboid bone, and the articulation between the external cuneiform and the third metatarsal bone; it is contained in a sheath formed by fibrous structure, and fibres of the ligamentum longum plantæ, prolonged from the ridge of the cuboid to the third and fourth metatarsal bones. A synovial membrane lubricates the tendon in the sheath.

Peroneus brevis Muscle. Origin.

The *peroneus brevis muscle*, smaller than the preceding, and inferior to it in position, *arises* from the lower half of the outer surface of the fibula, nearly down to the external malleolus, and from the processes of fascia that separate it from the muscles on the front and back of the leg: the upper fibres descend, and the lower pass transversely to the tendon, which is joined by fibres down to the annular ligament, then passes forwards below the external malleolus, being nearer the fibula than that of the peroneus longus, and enters a sheath, separate from that of the longus, which conducts it along the os calcis and cuboid bone to the base of the metatarsal bone of the little toe, into the upper surface of which it is *inserted*. In the leg the muscle is covered by the peroneus longus, and it is placed on the fibula. The anterior border is separated from the extensor longus and peroneus tertius, which are parallel to it, by the intermuscular septum of fascia; and the posterior, from the flexor pollicis by the same means. Below the ankle it lies on the fibula and external lateral ligament. Along the outer side of the foot it is contained in a sheath above that of the tendon of the peroneus longus, and crosses the calcaneo-cuboid articulation. If the sheaths are opened, they are seen to contain prolongations from the synovial membrane behind the outer ankle.

Insertion. Relations.

CONTINUATION OF THE LOWER EXTREMITY.

Dissection.

To expose the tendons of insertion of muscles around the knee-joint, which were before omitted, remove the popliteal vessels and nerves from the back of the articulation, and take away the cellular membrane. The tendons to be seen are those of the biceps, popliteus, and semi-membranosus muscles; and a part of each, sufficient for this purpose, is to be left. The ligaments of the joint, external to the capsule, are, an external, round and

cord-like; an internal, wide; an anterior, or ligament of the patella, the largest of all; and a posterior, a wide ligamentous expansion. These will be dissected by taking away a portion of the capsule from them. If the ligaments should be very dry, they may be steeped for a short time in water.

Knee-Joint. The articulation of the knee, the largest and most complex ginglymus joint in the body, is formed by the articular surfaces of the condyles of the tibia receiving the condyles of the femur; and in front is the small patella. These bones are covered with cartilage, the surfaces in contact are lubricated by synovial membrane, and they are retained in position by the muscles passing from the thigh to the leg, and by strong ligamentous structures both external and internal to a capsule.

Capsule. A kind of *capsule* surrounds the ends of the bones, and serves to limit the extent of the synovial membrane. This fibrous investment is derived from the tendons of the vasti in front, is united with the fascia lata, and receives accessory fibres from the tendons around the joint, and from the semi-membranosus; it is attached to the head of the tibia close to the articular surface, to the outer surface of the condyles, and posterior part of the femur, and is perforated by the tendon of the popliteus, which is united to it by fibres. This expansion is dissected with the tendons of the vasti and crureus.

Tendon of the Biceps. The *tendon of the biceps* muscle divides into a superficial and a deep portion; the former, smallest, gives off an expansion to the fascia of the leg, crosses the external lateral ligament near its lower attachment, and is inserted into the upper and anterior part of the head of the fibula; and the latter, or deep, passes beneath the ligament, is inserted into the upper and posterior part of the head of the bone, and sends forwards a prolongation to the head of the tibia, which resembles that from the semi-membranosus on the inner side: this process to the tibia may come from either portion of insertion.

External lateral Ligament. The *external lateral ligament*, round and strong, is sometimes divided below into two portions. It is attached above to the outer condyle, close to the tendon of the gastrocnemius but rather below it, descends vertically between the two portions of the tendon of the biceps, and is inserted into the outer and lower part of the head of the fibula. The process which is occasionally present, and is named *short external lateral*, diverges from the external about the lower part of the condyle of the femur, and is inserted into the bone behind the other. This ligament is covered by the expansion of the vasti, and, in its lower part, by the superficial portion of the tendon of the biceps; it is placed over the tendon of the popliteus muscle, and the inferior external articular vessels and nerve.

Tendon of the Popliteus. Divide the external lateral ligament, and follow back the *tendon of the popliteus* to the outer condyle, through the cap-

sule; it is connected to the anterior part of the oblong depression on the outer surface of the external condyle of the femur, close below the attachment of the external lateral ligament, and rather anterior to it. The tendon is directed downwards and outwards beneath the ligament and over the condyle, crosses the external semilunar cartilage, from which it is separated by the synovial membrane of the knee-joint, also the head of the tibia and the upper tibio-peroneal articulation, and leaves the capsule to give rise to muscular fibres: from the upper part of the tendon fibres pass to the capsule, and, from the lower, to the head of the fibula. Flex the leg, and it will be seen that the tendon enters the depression on the condyle in this condition of the limb.

Internal Lateral Ligament.

The *internal lateral ligament*, situated rather behind the centre of the articulation, is wide and expanded above, where it forms part of the capsule, but pointed and thick below. Its attachment to the femur is by a thickened portion to a small prominence of the inner condyle, in front of the depression for the tendon of the adductor magnus: the fibres descend vertically to be inserted into the upper part of the inner border and surface of the tibia, as low as the insertion of the popliteus muscle. The sartorius and tendons of the semi-tendinosus and gracilis lie on it, but separated by a synovial membrane; and the ligament is placed over the tendon of the semi-membranosus, the internal semilunar cartilage, and the inferior internal articular vessels and nerve. The anterior border is connected to the expansion of the triceps that forms a strong lateral band to the patella; the posterior is partly continuous with the capsule, being free and separate from it only at the insertion of the semi-membranosus into the head of the tibia: this border is also joined by some fibres from the tendon of insertion of this muscle.

Tendon of Semi-membranosus.

The *tendon* of the *semi-membranosus muscle*, partly concealed by the internal lateral ligament which may be divided to an extent sufficient to see it, is inserted by three processes: — an anterior, the strongest, which passes beneath the internal lateral ligament to be inserted into the inner side of the head of the tibia, close below the articular surface, and a portion is prolonged from this to the internal lateral ligament; an inferior, thin and membranous, joins the fascia of the popliteus muscle; and a posterior, consisting of strong fibres, is directed backwards over the posterior surface of the capsule of the joint, — some descending to the head of the tibia, but the greater number ascending to the outer condyle of the femur, and these last constitute the posterior ligament of Winslow.

Posterior Ligament.

The *posterior ligament* closes the articulation behind, and consists of different layers of fibres; the most superficial and the strongest, from the tendon of the semi-membranosus, is inclined upwards and outwards to the external condyle, the deeper,

continuous with the general capsule of the joint, is joined by fibres from the tendons of the gastrocnemius and popliteus, and is attached above and below to the femur and tibia. Between the condyles of the femur it is depressed, and there are numerous apertures in it for vessels and nerves. The popliteal vessels lie on it, and it conceals the crucial ligaments.

Anterior Ligament.

The *anterior ligament*, or ligamentum patellæ, the continuation of the tendon of the quadriceps extensor cruris, is about three inches long, but narrower in the centre than at the extremities, and is attached above to the lower part of the patella, and the depression on the inner surface of its inferior angle, the greater number of the fibres coming over the cutaneous surface of the bone; and it is inserted below into the tuberosity of the tibia. The cutaneous surface is covered by the expansion of the vasti; and the deep is in contact with the cellular mass which separates it from the synovial membrane, and, close to the insertion, a bursa is placed between it and the bone.

Dissection.

To see the reflections of the synovial membrane in the interior, before it is removed for the dissection of the remaining ligamentous structures, open the joint by an incision, on each side, from near the upper part of the patella to the interval between the condyles of the femur; throw down to the tibia the anterior part of the capsule with the patella. A fold of the membrane, reaching from below the patella to the interval between the condyles, is the mucous ligament, which contains some vessels and cellular tissue; and a similar fold on each side of the patella is the alar ligament. A small part of the posterior ligament may be removed, to show the crucial ligaments external to the synovial membrane.

Synovial Membrane.

The *synovial membrane* of this articulation is the largest and most complex in its reflections; between the quadriceps extensor and front of the femur its thickness is seen. If it is traced upwards beneath the patella and quadriceps extensor, which it lines, it is found to reach the front of the femur two inches above its articular surface, and higher on the inner than the outer side; it is now reflected over the lower end of the femur, covering also the lateral parts of the condyles beyond the articular cartilage, and passes backwards on each side of the middle line to the posterior part, where it forms a small *cul-de-sac* between the condyle and tendon of the gastrocnemius; but in the centre it is arrested by the crucial ligaments, and by a small vessel and some cellular membrane, which give rise to the ligamentum mucosum. The membrane is then continued by the capsule and crucial ligaments to the posterior part of the semilunar interarticular cartilages, turns over the free margin of these, covers their under surface, and reaches the capsule below them, and the articular surface of the head of the tibia; in front, the cartilage is enveloped in the same way, and so the continuity

of the membrane is followed to the patella. Between the tendon of the popliteus and the external semilunar cartilage is a pouch of the synovial membrane, which is prolonged on the posterior surface of the head of the tibia, and over the tibio-peroneal articulation, serving as a bursa to the tendon of the muscle. Some of its folds containing fat have received separate names; thus the *ligamentum mucosum* stretches across the joint from the interval between the condyles to the fat below the patella, contains a vessel and some cellular membrane, and is sometimes a round portion, but at others a membranous fold prolonged backwards to the crucial ligaments. The other folds are the *ligamenta alaria*, which are two in number, one on each side of the patella, and extend downwards to meet the mucous ligament below the bone.

Liga-mentum muco-sum.

Liga-menta alaria.

The remaining ligamentous structures, although within the capsule, are considered to be outside the articulation, because they are external to the synovial membrane which is reflected around them; they consist of the crucial ligaments in the centre, an interarticular or semilunar cartilage on each side, and a transverse band connecting the anterior extremities of these. Separate the anterior ligament from the fat behind it, but be careful of the transverse ligament, which is sometimes very thin; detach the capsule from the semilunar cartilages, and follow out their anterior and posterior attachments; and remove the synovial membrane and capsule from the crucial ligaments. In the examination of these, the knee is to be supported by blocks beneath it.

Dissection.

The *crucial ligaments*, two strong fibrous processes between the ends of the tibia and femur, cross each other something like the legs of the letter X, but they do not meet in the centre, for the anterior crosses the posterior, below, in flexion of the joint, but, above, in extension of it. The *anterior*, oblique in direction, and smaller than the posterior, is attached, anteriorly, to a depression in front of the spine of the tibia, and close to the inner articular surface; the fibres are directed upwards and outwards, being collected into bundles which are separated by cellular membrane, and are fixed to the depression at the posterior part of the inner surface of the external condyle of the femur, and partly to the interval between the condyles. The *posterior crucial*, flatter and larger than the anterior, and almost vertical in direction, is attached, below, to the depression at the posterior part of the head of the tibia, behind the spine, and the fibres ascend to be inserted into the anterior part of the interval between the condyles of the femur, and also into the contiguous surface of the inner condyle. The process that ascends from the external semilunar cartilage to be attached to the condyle posterior to it, is closely connected to it. The crucial ligaments are covered in front by the synovial mem-

Crucial Ligaments.

Anterior.

Posterior.

brane which folds around them, but does not project between them. Posteriorly they are in contact with the posterior ligament of the joint. These ligaments are chiefly concerned in maintaining the bones in contact, as may be proved by moving the tibia in different directions now the other ligaments are divided. When the joint is much flexed the anterior is put on the stretch, when forcibly extended, the posterior is rendered tense, and the femur cannot be drawn backwards off the tibia as long as the anterior remains entire. Rotation inwards is limited by the anterior ligament, but rotation outwards may be performed to such an extent as to turn the leg hind part foremost, because the posterior is vertical. Divide the anterior ligament; the femur may now be displaced from the tibia, or the latter rotated about in any direction. If the condyles of the femur be pressed closely in the fossæ formed by the semilunar cartilages, a slight check will be given to the rotation of the leg as long as they retain this position.

Semilunar Cartilages.

The *interarticular* or *semilunar cartilages* are two fibro-cartilaginous plates, situated on the articular surfaces of the tibia, which they serve to deepen for the reception of the condyles of the femur. They are thin internally, but thick externally and united by fibres to the capsule, are hollowed out above, and are flat below; they form segments of circles, whose extremities are fixed before and behind the spine of the tibia. The *internal*, forming a segment of a circle larger than the external, is narrow and pointed in front but wide behind, and is attached, posteriorly, to the depression behind the spine of the tibia, between it and the posterior crucial ligament, and, anteriorly, to a small tubercle in front of the internal articulating surface, and near the anterior margin of the head of the tibia; its circumference is united to the fibrous capsule of the joint, which retains it in position. The *external*, nearly circular in form, is fixed to the bone within the points of attachment of the internal, and covers more of the external articulating surface of the tibia. The anterior extremity is inserted into the outer lip of the depression in front of the spine of the tibia, and is united to the anterior crucial ligament which is fixed to the inner lip of the same depression; and the posterior turns forwards to be inserted into the interval between the two prominences of bone which form the spine of the tibia, and in front of the attachment of the internal semilunar cartilage. The circumference is fixed to the capsule, except posteriorly, where the tendon of the popliteus and the synovial membrane intervene. A band of ligamentous fibres, attached to the posterior part of this semilunar cartilage, ascends from without inwards, crossing the direction of the posterior crucial ligament, to which it is united by synovial membrane, and is inserted into the inner condyle of the femur, behind or before the crucial ligament.

Internal.

External.

The *transverse ligament*, rather more than an inch in length, is a narrow band of fibres between the front of the semilunar cartilages. It lies on and conceals the attachment of the internal fibro-cartilage to the front of the tibia. The strength of this band is very variable. Transverse Ligament.

The form of the articular surfaces of the bones in this articulation is now visible. The lower extremity of the femur presents in the centre of its articular surface a slightly concave part, which corresponds to the prominent ridge of the patella; and on each side of this, a large convex condyle covered with cartilage, and separated below and behind by a deep excavation that lodges the crucial ligaments. The articular cartilage of the outer condyle is wider than that of the internal, and extends higher up the bone. Of the articular surfaces of the tibia, the inner is the largest. The posterior surface of the patella is very unequally divided by a vertical ridge into two portions; the outer, the largest, corresponds to the wide external condyle of the femur. Articular Surfaces of the Bones.

The tibia and fibula are united by superior and inferior ligaments, and by an interosseous ligament or membrane between the shafts of the bones. The upper tibio-peroneal articulation, exposed by removing the cellular membrane and ligamentous structures both in front and behind, is formed by the articulating surfaces on the heads of the tibia and fibula. These are covered with cartilage, invested by a synovial membrane, and kept in contact by an anterior and a posterior ligament. Union of Tibia and Fibula. Upper Articulation.

The *anterior ligament*, a flat fasciculus in front of the articulation, is attached above to the fore part of the outer tuberosity of the tibia, and below to the front of the head of the fibula. Anterior Ligament.

The *posterior ligament*, thinner than the anterior, is attached to the same bones, has the same direction behind the joint as the other in front, and is covered by the tendon of the popliteus muscle. Posterior.

The *synovial membrane* lines the contiguous surfaces of the bones, and extends upwards so as to touch the portion of the synovial membrane of the knee-joint, which is reflected over the posterior part of the tibio-peroneal articulation. Synovial Membrane.

The *interosseous membrane* should have the muscles removed from it in front and behind, to see its anatomy. It is an aponeurotic partition between the tibia and fibula, separating the muscles on the front from those on the back of the leg, and consists chiefly of fibres directed downwards and outwards from the external border of the tibia to the ridge on the inner surface of the fibula: some few fibres cross in the opposite direction. The membrane is divided superiorly into two processes which are attached to the tibia and fibula, and above it the anterior tibial vessels pass forwards close to the fibula; and inferiorly is found a smaller aperture which transmits the anterior peroneal Interosseous Membrane.

vessels. The anterior surface is covered by the extensor muscles of the front of the leg, and by the anterior tibial vessels and nerve; and the posterior is in contact with the deep muscles of the back of the leg, to which it gives origin.

Lower Tibio-peroneal Articulation.

The lower tibio-peroneal articulation is continuous with that of the ankle, for the same synovial membrane serves the two. The surfaces of bone in contact are covered with cartilage; and around it are placed an anterior, posterior, and inferior ligament, with an interarticular one between the bones.

Anterior Ligament.

The *anterior ligament* lies in front of the surfaces of bone in contact, and, attached above to the lower end of the tibia, is directed outwards to the lower part of the fibula.

Posterior.

The *posterior ligament* is attached to the lower extremities of the tibia and fibula, and passes from the one bone to the other behind the articulation. It is deeper than the anterior, and is covered by the peronei muscles, and the posterior peroneal artery.

Inferior.

The *inferior ligament*, continuous above with the posterior, though its fibres are thicker and rounder, is attached, externally, behind the outer malleolus, and is prolonged behind the articulation of the ankle-joint to be fixed to the posterior border of the articular surface of the lower end of the tibia, which is thus deepened by it.

Inferior Interosseous.

The *inferior interosseous ligament*, situated between the surfaces of the tibia and fibula and below the aperture for the anterior peroneal vessels, consists of strong irregular bundles of fibres, which extend between the bones for about one inch and a half of their lower extremities; they are separated by cellular membrane, and some of them cross the direction of the others. The ligament will be more perfectly seen by tearing the bones asunder, after the dissection of the ankle-joint.

Synovial Membrane.

The *synovial membrane* of this articulation is only a prolongation from that of the ankle-joint.

Ankle-joint.

The tibio-tarsal articulation, or ankle-joint, is another ginglymoid or hinge-joint, resulting from the reception of the head of the astragalus into an arch formed by the union of the lower extremities of the tibia and fibula. The surfaces of the bones are covered with cartilage, and between them is a synovial membrane. An anterior and posterior, internal and external lateral ligament connect together the bones.

Dissection.

To expose the following ligaments, remove the muscles, vessels, and nerves from the front and back of the articulation, and take away the cellular membrane. The internal lateral is concealed by the tendon of the tibialis posticus, and the external lateral by the peronei muscles.

Anterior Ligament.

The *anterior* or tibio-tarsal *ligament* is a thin fibrous membrane, placed in front of the articulation, which is attached above to the tibia, near its articular surface, and below to the

upper surface of the astragalus, near the articulation of this bone to the scaphoid, also, on the outer side, to the edge of the groove for the interosseous ligament. Its fibres are indistinct, are interrupted by cellular intervals and by apertures for small vessels, and are connected on the sides to the lateral ligaments. It is covered by the extensor muscle of the foot and toes, and by the anterior tibial vessels and nerve. If it is cut across, its anterior attachment is better seen, also some loose folds of the synovial membrane containing fat.

Posterior Ligament.

The *posterior ligament* closes, behind, the ankle-joint, and is attached to the lower extremity of the tibia, above its articular surface, and to the astragalus close to its articulating part. Its fibres are mostly transverse, and seem to be continuous with the posterior portion of the external lateral; it joins, on each side, the lateral ligament, and is covered by the posterior tibial vessels and nerve, by the tendon of the flexor pollicis, and near the tibia, by that of the tibialis posticus muscle.

External Lateral Ligament.

The *external lateral ligament* consists of three distinct portions, anterior, middle, and posterior. The anterior portion, attached to the fore part of the external malleolus near its summit, is the shortest of the three, and is directed forwards, forming a flat portion which is inserted into the astragalus in front of the articular surface for the outer malleolus. The middle, the longest, round and cord-like, descends from the tip of the malleolus to the outer surface of the os calcis, above and behind its middle; this portion is covered by the tendons of the peronei, and its under surface is in relation with the synovial membrane between the astragalus and os calcis, which projects on this side. The posterior portion, the strongest, and best seen by dividing the middle fasciculus and looking at it from below, is almost horizontal in direction, and is connected to the pit at the under part of the external malleolus; from this point the fibres diverge to be attached to a depression on the posterior surface of the astragalus, as far backwards as the groove for the tendon of the flexor longus pollicis, and between the articular surface for the ankle-joint and that for the os calcis. The peronei muscles cover this division of the ligament, and from its upper part pass the fibres that join the posterior ligament. Its surfaces look upwards and downwards, the upper being covered by the synovial membrane of the ankle-joint, and the lower by that between the astragalus and os calcis.

Internal Lateral Ligament.

The *internal lateral* or deltoid *ligament* appears as a broad fan-like structure, its apex being upwards at the internal malleolus, and its base downwards, and attached by three portions to the astragalus, os calcis, and the scaphoid bone. The posterior part, thickest, passes downwards and backwards to the posterior part of the inner surface of the astragalus; the middle, vertical, to the inner side of the small process of the os calcis, above the

groove for the flexor longus digitorum; and the anterior, thin and expanded, to the inferior calcaneo-scaphoid ligament, and to the upper and inner part of the scaphoid bone, joining with the anterior ligament of the ankle-joint, and with the ligament between the astragalus and scaphoid bone. The posterior part is covered by the tendons of the tibialis posticus and flexor longus digitorum, and the middle by that of the tibialis posticus; between the middle and posterior portions is a small space, in which is seen the interosseous ligament between the astragalus and os calcis. Cut across the different portions, and their attachments will be better seen. The posterior portion is lined by the synovial membrane of the ankle-joint; the middle by the same, and by that between the astragalus and os calcis; and the anterior by that of the ankle-joint, and that between the astragalus and the scaphoid bone.

Articular Surfaces.

Separate the astragalus from the tibia and fibula by dividing the ligaments, and the surfaces of the bones entering into the articulation are seen. The astragalus is prominent, and rises into the arch formed by the bones of the leg; on each side of it is an articular surface tipped with cartilage, the external being larger than the internal, by which it is in contact with the malleoli. Of the arch formed by the tibia and fibula, the tibia forms the greater part, ends internally in the projection of the malleolus, and is marked by a slight antero-posterior line. The fibula projects lower on the outer side than the malleolar process of the tibia on the inner, and is covered with cartilage for articulation with the astragalus.

Synovial Membrane.

The *synovial membrane* of the ankle-joint, although extensive, is simple in its arrangement. It lines the articular surfaces of the tibia and fibula, sends a process upwards between the bones, to serve as the synovial membrane to the lower tibio-peroneal articulation, and is then reflected to the capsule, and to the upper part of the astragalus, which it invests with the ligaments on the side of the articulation.

Union of the Bones of the Tarsus.

The bones of the tarsus are articulated by means of dorsal and plantar ligaments, and some interosseous ones; and the ends of the bones in contact are covered with cartilage and synovial membrane. Dissect these articulations by removing the tendons from both the dorsum and sole of the foot, and taking away the vessels and cellular membrane.

Astragalus to Scaphoid.

The articulation of the astragalus to the scaphoid bone takes place by means of the rounded head of the former being received into the cup-shaped cavity of the latter; but as the head of the astragalus is much larger than the articular surface of the scaphoid, it projects, below, into a hollow formed for it by a ligament stretching from the os calcis to the scaphoid bone. One ligament only is found between the bones on the upper surface, the place of an inferior being supplied by the calcaneo-scaphoid

ligament before mentioned. The *superior ligament*, astragalo-scaphoid, is a wide flat membrane, thicker internally than externally, which is fixed, behind, close to the articular surface of the head of the astragalus, and is inserted, in front, into the upper surface of the scaphoid bone. This ligament is continuous internally with the anterior part of the internal lateral of the ankle-joint: at its attachment to the astragalus it almost joins the insertion of the anterior ligament of the ankle, and at its insertion into the scaphoid it joins the ligament from this bone to the internal cuneiform. Its cutaneous surface is covered by the extensor pollicis and anterior tibial vessels, and partly by the extensor brevis digitorum. If the ligament be cut through, its attachments will be better seen. The *synovial membrane* of the articulation lines the surface of the bones, and the ligaments above and below, and is a prolongation of that between the astragalus and os calcis.

Superior Ligament.

Synovial Membrane.

In the articulation of the astragalus to the os calcis, the surfaces of the bones, where in contact, are covered with cartilage, are invested by synovial membrane, and are retained in apposition by a strong interosseous ligament, and by an external and a posterior band of fibres. The *external lateral ligament*, a small band of fibres, is connected to the sides of the astragalus and os calcis, and is parallel to the middle portion of the external lateral ligament of the ankle-joint, but a little anterior to it. The *posterior ligament* consists of fibres between the contiguous margins of the astragalus and os calcis, where they are grooved for the tendon of the flexor pollicis; it is concealed by this tendon. The *interosseous ligament*, situated between the bones, will be exposed by removing the head of the astragalus, which projects beyond it, by means of a cut with a saw directed obliquely upwards and inwards through the neck of the bone, and by taking away the cellular membrane from the hollow on the outer side of the foot between the astragalus and os calcis. This ligament consists of strong vertical and oblique fibres, which are fixed to the depression between the articular surfaces both of the astragalus and os calcis. Its extent is from the outer to the inner side of the bones, and it is much longer and stronger on the outer than on the inner side; much cellular membrane occupies the intervals between the fibres, and sometimes there are two distinct layers. Take away the astragalus by cutting through the interosseous ligament, and the bones will be seen to touch each other in two points: the posterior articulating surface, the largest, is placed behind the interosseous ligament, and a separate *synovial membrane* is found between the bones; the anterior, small and oval, articulates with a similar surface on the under part of the neck of the astragalus, and is lubricated by another synovial membrane, which projects upwards to the articulation between the head of the astragalus and the scaphoid bone.

Astragalus to Os Calcis.

External Lateral.

Posterior.

Interosseous.

Synovial Membranes.

Sometimes the anterior articular surface is divided into two, with an additional small separate synovial membrane.

Os calcis to Scaphoid Bone.

The os calcis is united to the scaphoid only by means of ligamentous processes, since the surfaces of the bones are not in contact. There is one below the head of the astragalus, and one on the outer side; these serve to complete the cavity for the reception of this process of bone, and are now visible in consequence of its removal. The *inferior ligament*, inferior calcaneo-scaphoid, should be also exposed in the sole of the foot by removing the cartilaginous substance interposed between it and the tendon of the tibialis posticus. It is attached, behind, to the anterior extremity of the os calcis, before the articular surface for the astragalus, and in front, to a groove on the under surface of the scaphoid bone, behind the insertion of the tibialis posticus. The upper surface is covered by synovial membrane, and supports the head of the astragalus; and the lower, in the sole of the foot, is in contact with the tendon of the tibialis posticus, in which there is oftentimes a sesamoid bone. The inner part is thin, and joins the internal lateral ligament of the ankle, and the outer is separated by an interval from the external calcaneo-scaphoid. The *external ligament*, or external calcaneo-scaphoid, forming the outer part of the cup-shaped cavity, is shorter than the inferior, and is close to a band of fibres between the os calcis and cuboid bone. It is fixed, behind, to the front of the os calcis, between the articular surfaces for the cuboid bone and the astragalus, and is inserted, in front, into the outer side of the scaphoid bone: it is about half an inch deep, and extends nearly down to the inferior ligament; at its insertion into the scaphoid bone it is in close contact with an interosseous ligament between this and the cuboid bone. The inner surface is lined by the synovial membrane. The *synovial membrane* that covers the ligaments and the head of the astragalus, is continuous with that of the anterior articulation between the os calcis and astragalus. By looking into the hollow formed by the ligaments, the membrane is seen to form two transverse folds containing cellular tissue; one lies before the articular surface of the os calcis, and one behind that of the scaphoid bone.

Inferior Ligament.

External.

Synovial Membrane.

Os calcis to Cuboid Bone.

Superior Ligament.

The surfaces of the os calcis and the cuboid bone, which are in contact, are covered with cartilage, and there are dorsal and plantar ligaments between the ends of the bones: the latter are much the strongest. The *superior ligament*, or superior calcaneo-cuboid, consists of a thin band of fibres, separated into portions by cellular intervals, and attached to the upper surfaces of the contiguous extremities of the two bones. When this is divided, some scattered fibres are seen to lie on the synovial membrane; and at the inner side of the cuboid bone is a short band of strong fibres, beneath the preceding, which passes from the superior and internal extremity of the os calcis

to the upper and inner part of the cuboid bone ; it lies close to the external calcaneo-scaphoid ligament. These ligaments are covered by the extensor brevis digitorum. The *inferior ligament* will be seen in the sole of the foot, where it forms the longest and strongest ligamentous structure. The direction of its superficial fibres is longitudinal, but the deep project inwards beneath them; which has occasioned the ligament to be divided into a superficial portion or ligamentum longum plantæ, and a deep or inferior calcaneo-cuboid. The superficial portion is attached to the under surface of the os calcis, as far back as the interval between the two tuberosities; the fibres proceed forwards, diverging, to be connected to the ridge on the under surface of the cuboid bone, and some of them are prolonged over the tendon of the peroneus longus muscle to the tarsal extremities of the third and fourth metatarsal bones. The accessorius muscle closely covers this portion, and on its inner side appear the deep fibres, which are separated from it by a reddish cellular membrane. The deep portion, exposed by dividing the superficial, consists of radiating fibres, which pass from the anterior tubercle on the under surface of the os calcis to the surface of the cuboid, behind the ridge on this bone; this portion is covered by the superficial, and is in contact with the bones. The *synovial membrane* of this articulation is single and covers the surfaces of the bones.

Inferior.

Synovial Membrane.

The scaphoid bone, not generally in contact with the cuboid, is connected to it by ligamentous fibres, above, below, and between the bones; but to see the inferior, as well as the other ligaments between the cuneiform bones, the tendon of the tibialis posticus, and its processes of insertion should be carefully removed from the sole of the foot. The *superior* or *dorsal ligament* is a band of fibres from the upper surface of the scaphoid to the same part of the cuboid, on which it joins with the ligament from the os calcis to the cuboid bone. The *inferior* or *plantar*, longer than the upper, passes in like manner between the bones, and is concealed by the tendon of the tibialis posticus. Cut across these ligaments, and the external calcaneo-scaphoid, so as to allow the os calcis to be separated from the other tarsal bones, and the interosseous ligament is seen. The *interosseous ligament* is a thick strong band of fibres, extended transversely between the contiguous surfaces of the scaphoid and cuboid bones; its extent is about half the depth of the inner surface, and the inferior border, wider than the upper, is seen in the sole of the foot. When the bones touch each other, so as to be covered with a layer of cartilage, there is also present a synovial membrane to lubricate the surfaces.

Scaphoid to Cuboid Bone.

Superior Ligament.

Inferior.

Interosseous.

The scaphoid bone is articulated to the three cuneiform by the three articular surfaces on its front, so as to form one articulation lined by a synovial membrane. There are dorsal

Scaphoid to Cuneiform Bones.

Dorsal Ligaments. and plantar bands between the bones. The *dorsal ligaments* are three in number, one to each cuneiform bone; that to the internal is the strongest, and that to the external, the weakest and most oblique. The bands between the bones in the sole of the foot are processes of insertion of the tendon of the tibialis posticus, and are removed with the tendon.

Synovial Membrane. The *synovial membrane* covers the articular surfaces, sends two processes between the cuneiform bones, and projects into the sole of the foot, where it is covered by some scattered fibres.

Union of Cuneiform Bones. The cuneiform bones are articulated together by dorsal and plantar bands, and by interosseous ligaments. The *dorsal* are short transverse bands between the upper surfaces of the bones.

Dorsal Ligaments. The *plantar* are wanting, except one transverse band between the internal and middle cuneiform.

Plantar. Interosseous. The interosseous ligaments, between the rough lateral surfaces not in contact, will be dissected after the articulation of the bones of the tarsus with those of the metatarsus, when the bones can be separated.

External Cuneiform to Cuboid Bone. In the articulation of the external cuneiform to the cuboid, the bones touch by a part of their surface, which is covered with cartilage, and they are further retained in *situ* by a plantar, dorsal, and an interosseous ligament.

Dorsal Ligament. The *dorsal ligament* passes transversely from the upper surface of the one bone to that of the other, as between the cuneiform bones.

Plantar. The *plantar* consists of a few fibres between the two bones, which in some subjects are very indistinct.

Interosseous. The interosseous will be seen with the interosseous of the cuneiform. Divide the plantar ligaments connecting the scaphoid and cuneiform bones, and those joining the cuneiform, and the external cuneiform and cuboid bones. The

Synovial Membrane. *synovial membrane* between the scaphoid and cuneiform bones is now seen to be single, and to send processes forwards to the articulations of the cuneiform bones with each other and with the cuboid, and one extends between the two inner cuneiform, to the articulation of the second and third metatarsal bones with the two outer cuneiform.

Tarsus to Metatarsus. In the articulation of the tarsus with the metatarsus, the tarsal extremities of the five metatarsal bones are in direct union with the cuneiform and cuboid, or with the last row of the tarsal bones, the three internal joining the three cuneiform, and the two external, the cuboid: the surfaces, covered with cartilage and lined by synovial membrane, are kept in contact by dorsal and plantar ligaments.

Dorsal Ligaments. The *dorsal ligaments* between the ends of the bones are longitudinal or oblique: there is one to the metatarsal bone of the great toe from the internal cuneiform; the second metatarsal bone receives a band from each cuneiform, in consequence of its impaction between them; between the third metatarsal and external cuneiform is a thin band; and the fourth and fifth metatarsal have, in like manner, a band to each from the cuboid bone, that to the fifth being

directed outwards to its projecting extremity. The *plantar ligaments* are also, mostly, longitudinal. There is one between the first and internal cuneiform, besides the prolongation of the tendon of insertion of the tibialis anticus muscle. The second metatarsal has an inferior longitudinal band connecting it to the middle cuneiform, and two internal ligaments that unite it to the internal cuneiform;—one a deep strong interosseous ligament to the inner surface of its base, and the other is a superficial fasciculus, extended from the anterior part of the cuneiform to it and the third metatarsal: it has also an external longitudinal band from the tendon of insertion of the tibialis posticus. The third metatarsal has an inferior band from the external cuneiform, and an external one from the same bone, which limits, in this direction, the synovial membrane of the second and third metatarsal bones; it receives also some fibres from the band of the internal cuneiform. The fourth and the fifth metatarsal have no inferior ligaments to the cuboid, but only some scattered fibres, the tendon of the peroneus longus taking the place of them; the fourth receives on its inner side a longitudinal band from the external cuneiform, which isolates the synovial membrane of the two outer metatarsal bones; and the fifth receives by its tuberosity a band of plantar fascia, which connects it to the os calcis, and in the sole of the foot there is a transverse band to the external cuneiform bone. Open the articulation between the tarsus and metatarsus by cutting through the dorsal ligaments, and the synovial membranes, and line of union of the bones are observed. The *synovial membranes* between the tarsus and metatarsus are three:—a separate one for the first metatarsal and internal cuneiform; another for the articulation of the second and third with the middle and external cuneiform, which is a continuation of the membrane between the scaphoid and cuneiform, and is prolonged between the two internal cuneiform bones; and the last is between the two external metatarsal and the cuboid bone. The line of union of the tarsus and metatarsus across the foot, is very irregular, and if the last row of tarsal bones, which enter into it, be looked at, it will present the following appearance: — the internal and external cuneiform bones project, whilst the middle cuneiform and the cuboid are posterior to them, the middle, being half an inch behind the extremity of the internal cuneiform. The metatarsal bones are so united together that the heads of some project backwards, and the prominences formed by these fit into the depressions between the tarsal bones; thus, the head of the second, fourth, and fifth project backwards beyond the line of the others, but that of the second, which is wedged in between the outer and inner cuneiform bones, the farthest. To open these articulations from without inwards, it would be required to carry the knife obliquely inwards and forwards, from the

Plan tar.

Synovia Membranes.

Articular surface.

tuberosity of the fifth metatarsal bone to the base of the second, for the articulation of the three outer metatarsal bones; to pass about two lines behind this, for the articulation of the second; and half an inch in front of the line of the second, for the union of the first metatarsal bone.

Interosseous Ligaments of the Cuneiform Bones.

Separate forcibly the cuneiform bones from each other and from the cuboid, to see the strong interosseous ligaments between them; in doing this the ligaments will be frequently found to break off thin shells of bone rather than rupture. The *interosseous ligament* between the internal and middle cuneiform is attached also to the head of the second metatarsal bone. That between the middle and external is weak; but that between the external and the cuboid bone is very strong, and occupies nearly the depth of the bones.

Metatarsal Bones.

The metatarsal bones are united at their tarsal extremity by dorsal, plantar, and interosseous ligaments. The *dorsal* consist

Dorsal Ligaments.

of transverse fibres extended from the upper surface of the base of one bone to that next it, except between the two first; those

Plantar.

between the fourth and fifth are the strongest. The *plantar ligaments* are similar to the dorsal, but none are found between

Interosseous.

the two first. The *interosseous ligaments* are short transverse fibres uniting together the heads of the four outer toes; they are fixed to the lateral rough surfaces, and to see them the heads of the bones must be torn asunder. The articular surfaces between the heads are covered by prolongations of the

Synovial Membrane.

synovial membrane which serves for their articulation with the tarsus. The digital extremities of the metatarsal bones are united by the transverse metatarsal ligament, which has been dissected.

Metatarsal Bones to the Phalanges.

The articulations of the metatarsal bones with the phalanges give rise to joints that have considerable motion, though less than in the corresponding ones of the hand, and they result from the convex head of the metatarsal bone being received into the cup-shaped cavity of the phalanx. A capsular ligament surrounds the ends of the bones, and there are also lateral ligaments; but the tendons that pass over the joint, to flex or extend the last phalanges, serve the purpose of superior and inferior ligaments, and the joint is further strengthened by an expansion sent to the capsule from the extensor tendon. The

Capsular Ligament.

capsular ligament surrounds the heads of the metatarsal bone and phalanx, being connected to each at a little distance from the articulating surface. It is very thin above, but much thickened below by the presence of a cartilaginous portion,

Inferior.

named *inferior ligament*, which is hollowed out to receive the flexor tendons, and is connected to their sheath and the transverse metatarsal ligament; this thickened part is very loosely attached, posteriorly, to the under part of the metatarsal bone, and it is joined on the sides by some fibres of the lateral liga-

ments. The *lateral ligaments* are two, one for each side, and are attached to the tubercles on the sides of the head of the metatarsal bone; from this point the fibres radiate, passing forwards and downwards, and are inserted into the inferior ligament and base of the phalanx. Open the articulation; the head of the metatarsal bone will be seen to leave the articular surface of the phalanx in extension of the articulation, and to rest on the inferior ligament. The *synovial membrane* covers the bones and ligaments, and projects at the upper part. The articulation of the first metatarsal bone with its phalanx differs from the rest in having two sesamoid bones developed in the tendons inserted into the base of the phalanx, and these are connected to the inferior and lateral ligaments: the external sesamoid bone is the largest. When this articulation is opened, the articular surface of the metatarsal bone will be seen to be grooved for the sesamoid bones.

Lateral.

Synovial Membrane.

First Metatarsal.

The articulations of the phalanges are two for each toe, except the first, for which only one exists. The ends of the bones are articulated in the same manner as the heads of the metatarsal bones with the phalanges, and the same ligaments are found in them, viz. a capsular, with a thickened inferior ligament, and two lateral, though they are less strongly marked: these will be most readily dissected in the articulations between the phalanges of the finger, where the ligaments are larger and more evident. The articulation between the two last phalanges is still much more indistinct, and the small bones entering into it are frequently connected by osseous union.

Union of the Phalanges.

TABLE OF THE ARTERIES OF THE LOWER EXTREMITY.*

- **Femoral Artery, a continuation of the external iliac.**
  - External pudic — Superior; inferior.
  - superficial epigastric
  - superficial circumflex ilii.
  - Profunda
    - External circumflex — Ascending; descending; transverse.
    - internal circumflex — Muscular; articular; ascending to trochanter; transverse to the hamstrings.
    - first perforating — Muscular; anastomotic.
    - second perforating — Muscular; anastomotic; nutritious.
    - third perforating — Muscular; anastomotic.
    - terminal branch
  - Muscular
  - Anastomotic — Superficial; deep.
  - Popliteal
    - Muscular
    - superior internal
    - superior external articular
    - inferior internal
    - inferior external articular
    - azygos
    - sural.
    - Anterior tibial
      - Recurrent
      - cutaneous
      - muscular
      - internal malleolar
      - external malleolar
      - articular
      - tarsal — Muscular; articular.
      - metatarsal — three interosseous.
      - interosseous communicating to deep arch
      - magna pollicis — Digital, to great toe and half the next.
    - Posterior tibial
      - Internal recurrent
      - peroneal — Muscular; nutritious; anterior peroneal; posterior peroneal — Transverse or communicating.
      - nutritious to tibia
      - communicating to peroneal
      - tarsal
      - internal plantar — Muscular; cutaneous.
      - external plantar — Muscular; plantar arch — Muscular; posterior perforating; digital, for three toes and a half; anterior perforating.

* The branches of the internal iliac artery, dissected in the extremity, will be found in the table of the arteries of the abdomen.

TABLE OF THE VEINS OF THE LOWER EXTREMITY.*

- **Femoral Vein, a continuation of the external Iliac.**
  - Muscular
  - Anastomotic
    - Superficial
    - deep.
  - Profunda
    - Terminal branch
    - first perforating
    - second perforating
      - Muscular
      - nutritious.
    - third perforating
    - External circumflex
      - Ascending
      - transverse
      - descending.
    - Internal circumflex
      - Muscular
      - articular
      - ascending to trochanter
      - transverse to hamstrings.
  - Internal saphena
    - Branch from dorsal arch of the foot
    - plantar
    - veins of os calcis
    - communicating with posterior tibial
    - communicating with anterior tibial
    - articular at knee
    - communicating with deep veins of thigh (*sometimes*)
    - cutaneous from outer part of thigh
    - external pudic
    - superficial epigastric
    - superficial circumflex ilii.
  - Popliteal
    - external plantar
      - communicating to external saphena
      - muscular
      - plantar arch
        - Posterior perforating
        - digital three toes and a half
        - anterior perforating.
    - internal plantar
      - communicating to saphena.
    - Posterior tibial
      - tarsal.
      - communicating to saphena.
      - peroneal
        - Muscular
        - anterior peroneal
        - posterior peroneal.
      - internal recurrent.
    - Anterior tibial
      - magna pollicis - digital.
      - communicating to deep arch
      - interosseous
      - metatarsal - interrosseous.
      - tarsal
      - malleolar
      - communicating to saphena
      - muscular
      - recurrent
    - External saphena
      - Branch from dorsal arch of foot
      - plantar
      - veins from outer side of os calcis
      - cutaneous in the leg.
    - sural
    - articular
    - muscular

* The veins with the internal iliac arteries will be found in the table of the veins of the abdomen.

TABLE OF THE SPINAL NERVES OF THE LOWER EXTREMITY.

Nerves of the Lumbar Plexus in the Thigh.

- 1. External cutaneous
  - Posterior cutaneous
  - anterior cutaneous
    - Superior
    - inferior.
- 2. Obturator
  - accessory
    - To obturator trunk
    - to pectineus
    - to hip-joint.
  - to obturator externus
  - to articulation
  - superficial division
    - To pectineus
    - to gracilis
    - to adductor longus
    - long cutaneous nerve.
  - deep division
    - To adductor brevis and magnus
    - articular.
- 3. Anterior crural
  - Superficial portion
    - To femoral artery
    - to pectineus
    - middle cutaneous
    - internal cutaneous
    - accessory cutaneous of saphenus
    - to sartorius.
  - deep portion
    - To rectus
    - to vastus externus - articular.
    - to crureus
    - to vastus internus - articular.
- 4. Femoral branch of genito-crural
  - To integuments.
  - internal saphenus
    - Superior or anterior
    - Inferior
      - Posterior
      - anterior.

Nerves of the Sacral Plexus in the Thigh.

- 1. Small sciatic
  - Inferior gluteal
  - inferior pudendal
  - cutaneous to gluteal region, thigh, and leg.
- 2. Great sciatic
  - Articular to hip
  - to quadratus and inferior gemellus (*sometimes*)
  - articular.
  - to hamstrings
  - superior external articular.
  - external popliteal
    - Inferior external articular
    - cutaneous communicating to saphenus
    - recurrent articular
    - musculo-cutaneous
      - To peronei
      - cutaneous to toes.
    - anterior tibial
      - Muscular
      - internal - Cutaneous to toes.
      - external
        - Muscular
        - articular.
  - internal popliteal
    - Superior internal articular
    - inferior and posterior articular
    - muscular
    - communicating to saphenus.
    - posterior tibial
      - Muscular to flexors
      - cutaneous
      - internal plantar
        - Cutaneous of the sole
        - muscular
        - four digital
        - communicating
        - articular.
      - external plantar
        - Superficial
          - Muscular
          - two digital
          - communicating
          - articular.
        - deep
          - Muscular
          - articular.
- 3. Superior gluteal from lumbo-sacral
  - upper branch - To gluteus medius and minimus.
  - lower branch
    - To glutei
    - to tensor vaginæ femoris.

TABLE OF THE MUSCLES MOVING THE LOWER EXTREMITY.*

THE THIGH IS MOVED

forwards by	*backwards by*	*inwards by*	*outwards by*
Psoas magnus	Gluteus maximus	Psoas magnus	Tensor vaginæ femoris
Iliacus	Part of gluteus medius	Iliacus	Gluteus maximus
Tensor vaginæ femoris	Pyriformis	Pectineus	Gluteus medius
Pectineus	Obturator internus	Gracilis	Gluteus minimus
Adductor longus	Part of adductor magnus	Adductor longus	Pyriformis.
Adductor brevis.	Long head of biceps	Adductor brevis	
	Semi-tendinosus	Adductor magnus	
	Semi-membranosus.	Obturator externus	
		Quadratus femoris.	

THE THIGH IS ROTATED

inwards by	*outwards by*
Tensor vaginæ femoris	Gluteus maximus
Part of gluteus medius;	Part of gluteus medius
	Pyriformis
and, when the leg is extended, by	Gemellus superior
Sartorius	Obturator internus
Semi-tendinosus.	Gemellus inferior
	Quadratus femoris
	Obturator externus
	Psoas magnus
	Iliacus
	Adductor longus
	Adductor brevis
	Adductor magnus
	Biceps cruris (*slightly*).

THE LEG IS MOVED

backwards, or flexed by	*forwards, or extended by*
Semi-tendinosus	Rectus
Biceps	Crureus
Semi-membranosus	Vastus externus
Gracilis	Vastus internus.
Sartorius	
Popliteus.	

THE FOOT IS MOVED

forwards, or flexed by	*backwards, or extended by*	*inwards by*	*outwards by*
Tibialis anticus	Gastrocnemius	Extensor proprius pollicis	Peroneus longus
Extensor proprius pollicis	Plantaris	Flexor longus digitorum	Peroneus brevis
Extensor longus digitorum	Soleus	Flexor longus pollicis	Extensor longus digitorum
Peroneus tertius.	Flexor longus digitorum	Tibialis posticus.	Peroneus tertius.
	Flexor longus pollicis		
	Tibialis posticus		
	Peroneus longus		
	Peroneus brevis.		

THE TOES ARE MOVED

backwards or flexed by	*forwards, or extended by*	*inwards by*	*outwards by*
Abductor pollicis	Extensor longus digitorum	Abductor pollicis	Adductor pollicis
Flexor brevis digitorum	Extensor proprius pollicis	Interossei.	Adductor minimi digiti
Abductor minimi digiti	Extensor brevis digitorum.		Interossei.
Flexor longus pollicis			
Flexor longus digitorum			
Flexor accessorius			
Lumbricales			
Flexor brevis pollicis			
Adductor pollicis			
Flexor brevis minimi digiti			
Interossei.			

* This table is taken from Quain's "Elements of Anatomy."

INDEX.

The letter (o) prefixed to the figures refers to the origin, (c) to the course, and (d) to the distribution, of a nerve or vessel, when it is described in different pages.

Abdomen, 504.
dissection of, 468.
Abdominal aponeurosis, 474.
cavity, 504.
regions, 505.
ring, external, 475.
internal, 487.
wall, 468.
Abducens nerve, (o) 23. (c) 61. (d) 97.
Abductor indicis, 419.
minimi digiti, 415.
pedis, 695.
oculi, 98.
pollicis manûs, 414.
pollicis pedis, 694.
Accelerator urinæ muscle, 457.
Accessorius muscle, 699.
ad sacro-lumbalem, 135.
Accessory nerve, (o) 24. (c) 217. (d) 127.
Accessory of the obturator, (o) 569. (d) 651.
Accessory of the saphenus, 647.
Acervulus, 45.
Acini of the liver, structure, 549.
vessels, 549.
Acromial artery, inferior, 315.
superior, 130.
cutaneous nerves, 120.
thoracic artery, 315.
Acromio-clavicular articulation, 373.
Adductor brevis, 652.
longus, 651.
magnus, 656, 680.
minimi digiti, 416.
oculi, 98.
pollicis manûs, 415.
pollicis pedis, 700.
Alar ligaments of axis, 277.
ligaments of knee, 719.
Alveolar vein, 71. 191.
Ampullæ, membranous, 294.
Ampullæ of the semi-circular canals, 291.
Amygdalæ of cerebellum, 49.
of fauces, 238.
Anastomotic artery of brachial, 384.
artery of femoral, 642.
Anconeus muscle, 425.
Angular artery, 71. 97.
vein, 71.
Ankle-joint, 722.
Annular ligament of ankle, anterior, 707.
external, 707.
internal, 691.
ligament of wrist, anterior, 420.
ligament of wrist, posterior, 421. 431.
protuberance, 28.
Annulus of Vieussens, 337.
Anterior commissure, 33. 46.
medullary velum, 51.
Anti-helix, 78.
Anti-tragus, 78.
Anti-tragus muscle, 79.
Aorta, 342.
abdominal, 523.
thoracic, 357.
Aortic arch, 342.
opening, 562.
plexus, 522.
sinus, 343.
Aperture of the aorta, 342.
of the cavæ, 337.
of the coronary arteries, 342.
vein, 337.
of the Eustachian tube, 237.
of the femoral artery, 642.
of the larynx, 238.
of the mouth, 238.
of the nostrils, 235.
of the œsophagus, 239.
of the pulmonary artery, 339.
veins, 340.
Aponeurosis, epicranial, 7.
of external oblique, 474.
of the femoral artery, 641.
intercostal, 321.

Aponeurosis of internal oblique, 480.
lumbar, 125.
palmar, 407.
of the pharynx, 234.
plantar, 692.
of the soft palate, 236.
temporal, 7.
of the transversalis muscle, 483.
vertebral, 132.
Appendix auriculæ, 334.
cæci, 539.
vermiformis, 539.
Appendices epiploïcæ, 516.
Aqueduct of the cochlea, 293.
of Sylvius, 44.
of the vestibule, 291.
Aqueous humour, 109.
Arachnoid membrane of the brain, 13.
of the skull, 13.
of the spine, 150.
Arbor vitæ cerebelli, 50.
vitæ uteri, 608.
Arch of aorta, 342.
crural or femoral, 477.
of diaphragm, 560.
palmar deep, 417.
superficial, 408.
plantar, 701.
of soft palate, 235.
Arciform fibres, 26.
Arm, dissection of, 375.
Arter. acromialis, inferior, 315.
superior, 130.
anastomotica brachialis, 384.
magna, 642.
angularis faciei, 71.
ophthalmica, 97.
aorta abdominalis, 523.
thoracica, 357.
articulares inferiores, 674.
superiores, 673.
articularis azygos, 674.
auricularis posterior (d) 3. (o) 183.
axillaris, 303. 314.
basilaris, 17.
brachialis, 381.
brachio-cephalica, 343.
bronchiales, 351.
buccalis, 191.
capsularis inferior, 553.
medius, 553.
superior, 552.
carotis communis dextra, 174.
carotis communis sinistra, 226, 344.
carotis externa, 180.
Arter. carotis interna (d) 18. (e) 62. 209.
carpi ulnaris anterior, 402.
posterior, 402.
radialis anterior, 399.
posterior, 430.
centralis retinæ, 95. (d) 111.
cerebelli inferior, 17.
inferior anterior, 18.
superior, 18.
cerebri anterior, 19.
media, 19.
posterior, 18.
cervicalis ascendens, 171.
cervicalis profunda, (o) 172. (d) 143.
choroidea cerebri, 19.
ciliares anteriores (o) 96. (d) 108.
ciliares posteriores, (o) 96. (d) 108.
circumflexa anterior, 370.
externa, 646.
circumflexa ilii interna, 491.
ilii superficialis, 470. (d) 624.
interna, 653. 669.
posterior, 369.
coccygea, 665.
cochleæ, 295.
cœliaca, 528.
colica dextra, 518.
media, 518.
sinistra, 521.
comes nervi ischiadici, 665.
mediani, 401.
phrenici, 346.
communicans cerebri anterior, 19.
communicans cerebri posterior, 19.
communicans palmaris, 409.
plantaris, 702.
coronaria dextra, 335.
labii inferioris, 70.
labii superioris, 71.
sinistra, 335.
ventriculi, 529.
corporis bulbosi, 463.
cavernosi, 463. (d) 605.
cremasterica, 489.
cystica, 530. (d) 551.
deferentialis, 595.
dentalis anterior, 206.
inferior, 190.
superior, 191.
diaphragmaticæ, 552.
digitales manûs, 409. 417.

Arter. digitales pedis, 701.
dorsales pollicis, 430.
dorsalis carpi radialis, 430.
carpi ulnaris, 402.
indicis, 430.
linguæ, 201.
pedis, 711.
penis, (o) 463. (d) 472.
pollicis pedis, 711.
scapulæ, (o) 316. (d) 374.
epigastrica, 490.
epigastrica superficialis, 470. (d) 624.
ethmoidalis anterior, 96. (d) 255.
ethmoidalis posterior, 96. (d) 255.
facialis, (d) 70. (o) 182.
femoralis, 637, 641.
frontalis, 2. 97.
gastricæ, 529.
gastro-duodenalis, 530.
epiploïca dextra, 531.
epiploïca sinistra, 529.
glutea, (o) 593. (d) 663.
hæmorrhoidales inferiores, (d) 454. (o) 462.
hæmorrhoidalis media, 595.
hæmorrhoidalis superior, (o) 521.
helicinæ, 605.
hepatica, 530. 546, (d) 547.
hyoidea lingualis, 201.
thyroideæ, 181.
hypogastrica, 591.
iliaca externa, 555.
interna, 591.
iliacæ communes, 554.
ilio-colica, 518.
lumbalis, 592.
incisoria, 190.
infra-acromialis, 315.
orbitalis, 191. 206.
scapularis, 367.
spinalis, 374.
intercostales anteriores, 323.
intercostales, rami anteriores, 322. 357. 486.
intercostales, rami posteriores, 142. 357.
intercostalis superior, (o) 172. (d) 358.
interlobulares, 547.
interossea, 405.
anterior, 405.
posterior, 428.
interosseæ manûs, 418.
pedis, 712.
Arter. intestinales, 518.
intra-spinales, 157.
ischiadica, (o) 593. (d) 666.
labialis inferior, 70.
lachrymalis, 95.
laryngealis inferior, 265.
superior, (o) 181. (d) 265.
lingualis, 200.
lumbales, 570.
rami anteriores, 571.
rami posteriores, 142. (o) 570.
magna pollicis manûs, 417.
pedis, 702.
malleolaris externa, 711.
interna, 711.
mammaria interna, (o) 170. (c) 346. (d) 323. 490.
masseterica, 190.
maxillaris interna, 189.
meatûs interni, 295.
mediastinæ, 323.
meningeæ anteriores, (d) 58.
meningeæ mediæ, 58. (o) 183. 190. 211.
meningeæ parvæ, 58. 190.
posteriores, 17. 58.
mentalis, 190.
mesenterica inferior, 521.
superior, 517.
metacarpa radialis, 430.
ulnaris, 401.
metatarsea, 712.
muscularis, 183.
musculo-phrenica, 323.
mylo-hyoidea, 190.
nasalis, 97.
nasalis lateralis, 71.
septi, 71.
nutritia femoris, 654.
fibulæ, 989.
humeri, 384.
tibiæ, 690.
obturatoria, (o) 593. (d) 658.
occipitalis, (d) 3. (c) 143. (o) 183.
œsophageales, 357. 529.
ophthalmica, 95.
palatina inferior, 182.
superior, 255.
palmaris profunda, 417.
palpebralis inferior, 97.
superior, 97.
pancreatica magna, 529.
pancreaticæ parvæ, 529.
pancreatico-duodenalis, 530.
perforantes femorales, 654.

Arter. perforantes mammariæ internæ, 323.
perforantes manûs, 417.
pedis, 701.
pericardiacæ, 323.
perinæi superficialis, 454.
peronea, 689.
anterior, 689.
posterior, 690.
pharyngea ascendens, 211.
phrenicæ inferiores, 552.
superiores, 346.
plantaris externa, 696. 701.
interna, 696. 701.
poplitea, 672.
princeps cervicis, 143.
profunda cervicis (o) 172. (d) 143.
femoris, 653.
inferior, 384.
profunda superior, (o) 384. (d) 388.
pterygoidea, 254.
pterygoideæ, 191.
pterygo-palatina, 254.
pudendæ externæ, 470. 638. (d) 623.
pudenda interna, (o) 593. (d) 462.
pulmonalis, 339.
dextra, 329. 340. 351.
sinistra, 329. 340. 351.
pylorica inferior, 530.
superior, 530.
radialis, 397. 429. (d) 416.
indicis, 417.
ranina, 201.
recurrens interossea posterior, 429.
radialis, 398.
tibialis, 711.
ulnaris anterior, 401.
ulnaris posterior, 401.
renales, 553.
sacra media, 594.
sacro-lateralis, 592.
scapularis posterior, 131.
sigmoidea, 521.
spermatica, (o) 554. (c) 489. 554. (d) 503.
spheno-palatina, 254.
spinales posteriores, 16. 155.
spinalis anterior, 17. 154.
splenica, 529.
sterno-mastoidea, 181.
stylo-mastoidea, (o) 183. (d) 289.
subclavia dextra, 118. 168.
sinistra, 225. (o) 344.
sublingualis, 201.
submentalis, 182.
subscapularis, 315.
Arter. superficialis colli, 130.
volæ, 398.
supra-acromialis, 130.
orbitalis, (d) 2. 95.
scapularis, (o) 130. (d) 374.
spinalis, 374.
tarsea, 712.
temporales profundæ, 191.
temporalis, 184.
temporalis anterior, 3.
media, 184.
posterior, 3.
superficialis, 3.
thoracica acromialis, 315.
alaris, 315.
humeraria, 315.
longa, 315.
suprema, 315.
thyroidea inferior, 171.
superior, 181.
tibialis antica, 710.
postica, 689.
tonsillaris, 182.
transversalis perinæi, 456.
pontis, 17.
pubis, 490.
transversalis colli, (o) 171. (d) 130.
transversalis faciei, (d) 71. (o) 171.
transversalis humeri, (d) 130. (o) 171.
tympanica, 190.
inferior, 289.
superior, 289.
ulnaris, 400.
umbilicalis, 591.
uterina, 595.
vaginales hepatis, 547.
vaginalis, 596.
vertebralis, (o) 170. (c) 143. 272. (d) 17.
vesicalis inferior, 595.
media, 595.
superior, 595.
vestibuli, 296.
vidiana, 58. 289.
Articular popliteal arteries, 673.
nerves, 675.
veins, 674.
Articulation, acromio-clavicular, 373.
astragalo-scaphoid, 724.
astragalus to os calcis, 725.
atlo-axoidean, 275. 277.
of bones of the tympanum, 284.
of carpal bones, 436.
carpo-metacarpal, 438.

Articulation of cervical vertebræ, 273.
chondro-costal, 363.
sternal, 363.
of coccygeal bones, 614.
coraco-clavicular, 372.
of costal cartilages, 363.
costo-clavicular, 278.
vertebral, 362.
crico-arytænoid, 269.
thyroid, 268.
of cuneiform bones, 728.
cuneiform to cuboid, 728.
to scaphoid, 727.
of dorsal vertebræ, 363.
femoro-tibial or knee, 716.
humero-cubital or elbow, 431.
ilio-femoral or hip, 680.
of lower jaw, 188.
of lumbar vertebræ, 614.
of the metacarpal bones, 437.
metacarpo-phalangeal, 439.
metatarsal, 730.
metatarso-phalangeal, 730.
occipito-atloidean, 275. 278.
axoidean, 276.
os calcis to cuboid, 726.
to scaphoid, 726.
peroneo-tibial inferior, 722.
peroneo-tibial superior, 721.
phalangeal of fingers, 439.
of toes, 731.
of pubic symphysis, 590.
radio-carpal or wrist, 434.
cubital inferior, 435.
superior, 432.
sacro-coccygeal, 613.
iliac, 611.
vertebral, 613.
scaphoid to cuboid, 727.
to cuneiform, 727.
scapulo-clavicular, 372, 373.
scapulo-humeral, 390.
sterno-clavicular, 278.
tarso-metatarsal, 728.
temporo-maxillary, 188.
thyro-arytænoid, 269.
tibio-tarsal or ankle, 722.
Arcus externus diaphragmatis, 560.
internus diaphragmatis, 560.
Arytæno-epiglottidean folds, 239.
muscle, 260.
Arytæno-epiglottideus inferior muscle, 262.
Arytænoid cartilage, 267.
gland, 263.
Arytænoid muscle, 260.
Ascending cervical artery, 171.
vein, 172.
pharyngeal artery, 211.
vein, 212.
Attollens aurem, 6.
oculum, 91.
Attrahens aurem, 6.
Auditory tube, external, 280.
Auditory nerve, (o) 23. (d) 295.
Auricle of the ear, 78.
Auricles of the heart, 334.
left, 340.
right, 336.
Auricular artery, posterior, (d) 3. (o) 183.
nerves, anterior, 120. 194.
posterior, 5. 82.
vein, 4. 183.
Auricular nerve of Arnold, (o) 215. (d) 289.
Auriculæ, 334.
Auriculo-temporal nerve, 194.
Auriculo-ventricular aperture, left, 341.
right, 338.
Auricularis magnus nerve, 119.
Axilla, 307.
dissection of, 306.
Axillary artery, 303. 314.
or brachial plexus, 316.
glands, 310.
vein, 303. 314.
Axis, cœliac of artery, 528.
thyroid of artery, 170.
Azygos artery, 674.
ganglion, 20. 600.
vein, large, (o) 562. (d) 354.
small, 355.
uvulæ muscle, 237.

Back, dissection of, 121.
Base of brain, 15.
Base of the skull, arteries of, 58.
dissection of, 54.
nerves of, 59.
Basilar artery, 17.
sinus, 57.
Basilic vein, 377.
Beak of the corpus callosum, 33.
Biceps femoris muscle, 677. 716.
flexor cubiti, 379, 390. 421
Bicuspid teeth, 242.
Biventer cervicis muscle, 137.
Bladder, form of, 580. 589.
ligaments of, 579. 582. 587.
relations of, 581. 589.
structure of, 602.
Bones of the ear, 284.

Brachial aponeurosis, 379.
artery, 381.
plexus, 173. 316.
veins, 384.
Brachialis anticus, 384. 420.
Brachio-cephalic artery, 343.
vein, left, 345.
right, 345.
Brain, base of, 15.
examination of base, 25.
examination of interior, 34.
membranes of, 9. 13.
origin of nerves, 20.
removal of, 11.
vessels of, 16.
Bronchial arteries, 351.
veins, 351.
glands, 351.
Bronchus, left, 329. 352.
right, 329. 352.
structure of, 353.
Brunner's glands, 537.
Buccal artery, 191.
glands, 241.
nerve, 193.
vein, 71.
Buccinator muscle, 68.
Bulb of the urethra, 585.
artery of, 463.
nerve of, 464.
Bulbous part of the urethra, 604.
Bulbus olfactorius, 21.

Calamus scriptorius, 52.
Calices of the kidney, 558.
Caliciform papillæ, 256.
Canal of Bichat, 43.
of Fontana, 106.
of Petit, 113.
of the tensor tympani, 283.
Canalis spiralis cochleæ, 292.
Canthus, 75.
Capsular arteries, inferior, 553.
middle, 553.
superior, 552.
veins, 553.
ligament of the hip, 680.
of the knee, 716.
of the shoulder, 390.
of the thumb, 438.
Capsule of crystalline lens, 114.
of Glisson, 547.
supra-renal, 559.
Caput coli, 539.
gallinaginis, 603.
Cardiac ganglion, 332.
Cardiac nerve, inferior, (o) 224. 230. (d) 349.
Cardiac nerve, middle, (o) 223. 230. (d) 349.
of pneumo-gastric, (o) 217. 230. (d) 330.
superior, (o) 222. 230. (d) 331.
Cardiac plexus, 331. 349.
Carneæ columnæ, 338. 341.
Carotid artery, external, 180.
internal, (d) 18. (c) 62. 209.
left common, 226. 344.
right common, 174.
plexus, 221.
Carpal artery, radial anterior, 399.
posterior, 430.
ulnar anterior, 402.
posterior, 402.
Carpo-metacarpal articulation, 438.
Cartilage, arytænoid, 267.
cricoid, 266.
cuneiform, 267.
of the ear, 79.
interarticular of the clavicle, 278.
interarticular of hip, 681.
of jaw, 189.
of knee, 720.
of ribs, 362.
of vertebræ, 275. 365. 615.
of wrist, 436.
interosseous of carpus, 439.
of tarsus, 725. 730.
thyroid, 266.
triangular of the nose, 243.
Cartilages of the nose, 73.
Caruncula lachrymalis, 75.
Carunculæ myrtiformes, 607.
Cava, inferior, 524.
superior, 345.
Cavernous body, 585.
artery of, (o) 463. (d) 605.
ganglion and nerves, 62.
sinus, 57.
Cavity of the omentum, 515.
Central artery of the retina, (o) 95. (d) 111.
pillar of the cochlea, 292.
tube of the modiolus, 292.
Centrum ovale, 35.
Cephalic vein, 377.
Cerebellar arteries, inferior, 17.
superior, 18.
Cerebellum, form of, 48.
lobes of, 49.

Cerebellum, structure of, 50.
Cerebral artery, anterior, 19.
middle, 19.
posterior, 18.
protuberance, form, 28.
structure, 29.
Cerebrum, division into lobes, 15.
form of, 34.
Cervical fascia, 116. 160.
ganglion, inferior, 223. 229.
middle, 223. 229.
superior, 221.
glands, 121.
nerves, anterior branches, 176.
posterior, 138.
plexus of nerves, 176.
plexus of nerves, deep branches, 177.
plexus of nerves, superficial, 116.
plexus, posterior, 140.
Cervicalis ascendens artery, 171.
muscle, 135.
vein, 172.
profunda artery, (o) 172. (d) 143.
profunda vein, 144.
superficialis nerve, 120. 159.
Cervico-facial nerve, 84.
Cervix uteri, 608.
vesicæ, 582.
Chamber of the eye, anterior, 108.
posterior, 108.
Cheeks, 241.
Chiasma of the optic nerves, 21.
Chondro-costal articulations, 363.
sternal articulations, 363.
Chorda tympani nerve, (o) 251. (d) 195.
Chordæ tendineæ, 330. 341.
vocales, 262.
Willisii, 10.
Choroid artery of the brain, 19.
coat of the eye, 105.
plexuses of the brain, 43, 44. 53.
veins of the eye, 105. 108.
of the brain, 43.
Cilia, 75.
Ciliary arteries, (o) 96. (d) 108.
ligament, 106.
processes of the choroid, 106.
of the hyaloid, 112.
nerves of nasal, (o) 93. (d) 108.
of lenticular ganglion, 94.
Circle of Willis, 20.
Circular sinus, 57.
Circumflex artery, anterior, 370.
external, 646.
Circumflex artery of the ilium, deep, 491.
artery of the ilium, superficial, 470. (d) 624.
internal, 653. 669.
posterior, 369.
nerve, (o) 319. (d) 370.
Clavicular cutaneous nerves, 120. 305.
Clitoris, 607.
Cochlea, 292.
nerve of, 295.
vessels of, 295.
Coccygeal artery, 665.
muscle, 575.
Cœcum coli, form, 539.
interior, 540.
relations of, 508.
structure of, 539.
valve of, 541.
Cœliac artery, 528.
plexus, 533.
Colic artery, left, 521.
middle, 518.
right, 518.
veins, 518.
Colon, form, 539.
ascending, relations of, 508.
descending, 509.
sigmoid flexure, 509.
structure of, 539.
transverse, 509.
Columella, 48.
Columnæ carneæ, 338. 341.
Columns of the vagina, 609.
Comes nervi ischiadici artery, 665.
phrenici artery, 346.
Commissure, anterior, 33. 46.
of the cerebellum, 49. 53.
of the cord, 156.
great, 35.
of the optic nerves, 21.
posterior, 46.
soft, 44.
Communicating artery of anterior cerebral, 19.
artery of posterior cerebral, 19.
artery in the palm, 409.
saphenus nerves, 683.
Complexus muscle, 137.
Compressor of the nose, 69.
of the urethra, 460.
of the veins of the penis, 473.
Conarium, 45.
Concha, 78.
Coni vasculosi, 503.
Conical papillæ, 256.
Conjoined tendon, 480, 483.
Conjunctiva, 75.

Conoid ligament, 372.
Constrictor inferior, 232.
of the fauces, 238.
middle, 233.
superior, 233.
Convolution of the corpus callosum, 30. 34.
Coraco-brachialis muscle, 380.
clavicular articulation, 372.
humeral ligament, 390.
Cordiform tendon, 560.
Cornea, 103.
Cornicula laryngis, 267.
Cornu inferius ventriculi cerebri, 41.
Corona ciliaris, 112.
glandis, 586.
Coronary arteries of the heart, 335.
of the lips, 70.
artery of the stomach, 529.
ligament of the liver, 544.
plexus of the stomach, 533.
plexuses of the heart, 336.
vein of the stomach, 529.
Corpora albicantia, 31.
Arantii, 339. 342.
cavernosa, 585. 604.
Malpighiana, 558.
mamillaria, 557.
olivaria, 26.
pyramidalia anteriora, 26.
posteriora, 53.
quadrigemina, 47.
restiformia, 27. 53.
striata, 33. 39, 47.
Corpus callosum, 32, 35.
dentatum cerebelli, 51.
medullæ, 27.
denticulatum, 42.
fimbriatum, 38.
uteri, 608.
geniculatum externum, 45.
internum, 45.
Highmori, 502.
luteum, 609.
psalloides, 39.
spongiosum urethræ, 585.
thyroideum, 227.
Corpuscules of Malpighi, 543.
Corrugator supercilii muscle, 66.
Cortical substance of the kidney, 558.
Costo-clavicular ligament, 278.
coracoid membrane, 313.
Cotyloid ligament, 681.
Covered band of Reil, 35.
Cowper's glands, 461.
Cranial aponeurosis, 7.
nerves, 20.
Cremaster muscle, 481.
Cremasteric artery, 489.
fascia, 481.
Cribriform fascia, 625.
Crico-arytænoid articulation, 269.
muscle, lateral, 260.
posterior, 260.
Crico-thyroid articulation, 268.
membrane, 268.
muscle, 259.
Cricoid cartilage, 266.
Crucial ligaments, 719.
Crura cerebelli, 51.
cerebri, 30, 48.
of the diaphragm, 560.
of the fornix, 46.
Crureus muscle, 645.
Crural arch, 628.
deep, 489.
canal, 630.
hernia, 500, 631.
nerve, anterior (o) 568. d) 647.
ring, 500, 630.
Crystalline lens, 113.
capsule, 114.
Cupola cochleæ, 292.
Cuneiform articulations, 728.
cartilages, 267.
Cutaneous nerves of the abdomen, 468.
of the arm, 378.
of the back, 122.
of the buttock, 659.
of the ear, 79.
of the face, 80.
of the foot, back, 705.
sole, 692.
of the forearm, 392.
of the hand, back, 392.
palm, 406.
of the head, 4.
of the leg, back, 683.
front, 705.
of the neck, behind, 122.
of the neck, fore part, 119.
of the perinæum, 452.
of the shoulder, 368.
of the thigh, back, 670.
front, 659.
of the thorax, 305.
Cystic artery, 530. (d) 551.
duct, 551.
plexus of nerves, 534.

Decussation of the pyramids, 26.
Deep cervical artery, (o) 172. (d) 143.
crural arch, 489.

Deferential artery, 595.
Deltoid ligament, 723.
muscle, 368.
Dens sapientiæ, 242.
Dental artery, anterior, 206.
inferior, 190.
superior, 191
Dental nerve, anterior, 206.
inferior, 194.
posterior, 205
Dental vein, anterior, 206.
inferior, 191.
superior, 255.
Dentate fascia, 42.
ligament, 152.
Descendens noni nerve, 179.
Depressor anguli oris, 69.
labii inferioris, 69.
labii superioris alæque nasi, 69.
oculi, 98.
Diaphragm, 361. 559.
Diaphragmatic arteries, 552.
plexus, 534. (d) 552.
Digastric muscle, 178.
nerve, 82.
Digital arteries of plantar, 701.
of radial, 417.
of tibial, anterior, 702.
of ulnar, 409.
nerves of median, 410.
of plantar, 697, 698.
of radial, 393.
of ulnar, 410.
Dissection of the abdomen, 468.
of the abdominal cavity, 504.
of the abdominal wall, 468.
of the anterior commissure, 33.
of the aorta, 330. 354. 523. 561.
of the arm, 375.
of the axilla, 306.
of the back, 121.
of the base of the skull, 54.
of the brachial plexus, 316.
of the brain, 25. 34.
of the brain, membranes, 9. 13.
of the brain, origin of nerves, 20.
of the buttock, 659.
of the cardiac ganglion, 330.
plexus, 348.
of the carotid artery, internal, 207.
of the carotid plexus, 207.
of the cerebellum, 48.
Dissection of the cerebrum, 34.
of the corpus callosum, 32.
striatum, 33.
of the cervical ganglia, 207. 220.
of the cervical plexus, 119.
of the crus cerebri, 30. 48.
of the ear, external, 78.
muscles, 78.
nerves, 79.
vessels, 79.
of the ear, internal, 279.
muscles, 285.
nerves, 287. 295.
vessels, 289. 295.
of the eighth nerve, 212.
of the eye, 103.
lids, 75.
of the face, 64.
of femoral hernia, 498.
sheath, 627.
of the fifth ventricle of the brain, 37.
of the foot, back, 705.
sole, 691.
of the forearm, 391.
back, 421.
front, 394.
of the fourth ventricle, 52.
of the glosso-pharyngeal nerve, 207. 212.
of the hand, back, 421.
palm, 406.
of the head, deep parts, 246.
external parts, 1.
of the heart, 333.
of the hypogastric plexus, 520.
of the inferior maxillary nerve, 185. 189.
of the inguinal hernia, 491.
region, 491.
of the internal maxillary artery, 185.
of the iliac vessels, 590.
of Jacobson's nerve, 287.
of the labyrinth, 289.
of the larynx, 258.
cartilages, 266.
muscles, 258.
nerves, 263.
of the lateral ventricles, 35.
of the left side of head and neck, 224.
of the leg, back, 682.
front, 705.
of the ligaments of atlas and axis, 275. 277.

Dissection of the ligaments of atlas and occiput, 275. 277.
of the ligaments of axis and occiput, 276.
of the ligaments of clavicle and scapula, 372.
of the ligaments of hip-joint, 680.
of the ligaments of jaw, 188.
of the ligaments of lower extremity, 715.
of the ligaments of pelvis, 612.
of the ligaments of ribs, 361.
of the ligaments of shoulder, 389.
of the ligaments of upper extremity, 431.
of the ligaments of vertebræ, cervical, 273.
of the ligaments of vertebræ, dorsal, 363.
of the ligaments of vertebræ, lumbar, 614.
of the lower extremity, 621.
of the lungs, 328.
root, 328.
of Meckel's ganglion, 246.
of the medulla oblongata, 26.
of the mouth, 240.
of the neck, 114. 269.
of the neck, anterior triangle, 158.
of the neck, posterior triangle, 114.
of the ninth nerve, 207. 212.
of the nose, 242.
of the ophthalmic of the fifth nerve, 87.
of the orbit, 87.
of the otic ganglion, 252.
of the pelvis, female, 586.
of the pelvis, female, side view, 586.
of the pelvis, male, 571.
of the pelvis, male, side view, 574.
of the perinæum, female, 466.
of the perinæum, male, 447.
of the pharynx, 230.
of the pneumo-gastric nerve, 207. 212.
of the pons, 29.
of the popliteal space, 671.
of the portio dura nerve, (d) 80. (c) 250.
Dissection of the portio mollis nerve, 294.
of the posterior mediastinum, 327. 354.
of the pterygoid region, 185.
of the sacral ganglia, 571. 600.
of the sacral plexus, 598.
of the saphenous opening, 623. 625.
of the semilunar ganglia, 532.
of the shoulder, 366.
of the soft palate, 238.
of the solar plexus, 532.
of the spermatic cord, 488.
of the spinal cord, 148.
vessels, 157.
of the submaxillary region, 197.
of the superior maxillary nerve, 204.
of the testis, 501.
of the thigh, back, 659. 669.
front, 622.
of the third ventricle, 44.
of the thorax, 324.
of the thoracic aorta, 330. 354.
of the tongue, 255.
of the triangular space of the thigh, 636.
of the tympanum, 279.
of the tympanum, arteries of, 289.
of the tympanum, nerves of, 287.
of the upper extremity, 303.
of the vena cava inferior, 523.
of the vidian nerve, 248.
Divisions of the cord, 155.
of the cord, antero-lateral, 156.
posterior division, 156.
posterior median cord, 156.
Dorsal artery of the penis, 463. (d) 472.
of the tongue, 201.
of the scapula (o) 316. (d) 374.
Dorsal nerves, anterior branches, 359. 569.
posterior branches, 140. 360.
of the penis (o) 464. (d) 472.

Dorsi-lumbar nerve, 506.
Dorsi-spinal veins, 144.
Ductus ad nasum, 101.
arteriosus, 340.
communis choledochus, 531.
cysticus, 551.
hepaticus, 531. 546.
lymphaticus, 310.
pancreaticus, 542.
Stenonis, 73.
Ductus ejaculatorii, 601. 604.
thoracicus, (d) 226. (c) 355. (o) 562.
dexter, 310.
Whartoni, 196. 204.
Duodenum, peritonæum of, 514.
relations, 526.
structure, 536.
Dura mater, 9.
of the cord, 149.
nerves of, 59.
processes of, 54.
vessels of, 58.

Ear, external, 78.
internal, 279.
Eighth nerve, (o) 24. (d) 213.
Elastic cornea, 104.
Elbow-joint, 431.
Eminentia collateralis, 41.
Endolymph, 294.
Epididymis, 503.
Epigastric artery, 490.
Epigastric artery, superficial, 470. (d) 624.
region of the abdomen, 505.
veins, 490.
Epiglottidean gland, 268.
Epiglottis, 239, 267.
Epiploon, 515.
Erector clitoridis, 466.
penis, 457.
spinæ, 135, 136.
Ethmoidal arteries, 96.
Eustachian tube, cartilaginous part, 237.
osseous part, 284.
valve, 337.
Expansion from the vasti, 645.
Extensor carpi radialis brevis, 423.
longus, 422.
carpi ulnaris, 425.
digiti minimi, 424.
digitorum brevis, 712.
communis, 424.
longus pedis, 709.
indicis, 427.
ossis metacarpi, 426.
proprius pollicis, 708.
primi internodii pollicis, 426.
Extensor secundi internodii pollicis, 427.
External cutaneous nerve of the arm, (o) 318. (c) 385. (d) 393.
cutaneous nerve of the thigh, (o) 568. (d) 633. 660.
Eye, 102.
brows, 74.
globe, 102.
lashes, 75.
lids, 75.
nerves of, 76.
vessels of, 76.

Facial artery, (d) 70. (o) 182.
nerve, 80.
vein, 71. 183.
Falciform ligament of the liver, 543.
process of fascia lata, 626.
Fallopian tube, 608.
Falx cerebelli, 54.
cerebri, 11.
Fascia axillary, 305.
brachial, 379.
cervical, deep, 116. 160.
superficial, 115.
costo-coracoid, 313.
cremasteric, 481.
cribriform, 625.
dentata, 42.
dorsal of the foot, 707.
of the forearm, 394.
iliac, 499. 563. 572.
intercolumnar, 476.
intermuscular of the humerus, 387.
of the thigh, 646.
lata, 635. 669.
of the leg, 684. 686. 706.
lumborum, 125.
obturator, 573.
palmar, 407.
pelvic, 572.
perinæal, deep, 459.
superficial, 451.
plantar, deep, 692.
propria, 499. 631.
of the quadratus, 562.
spermatic, 476.
temporal, 7.
transversalis, 486. 499.
vesical, 576.
Femoral arch, 628.
artery, 637. 641.
canal, 630.
hernia, 500. 631.
ring, 500. 630.
sheath, 500. 629.
interior of, 629.

Femoral vein, 637. 641.
Femoro-tibial articulation, 716.
Fenestra ovalis, 282.
Fibrous cone of Reil, 40.
Fifth nerve, (o) 22. (c) 60.
Fillet of Reil, 27. 29. 48.
of the corpus callosum, 32.
Fimbriæ of the Fallopian tube, 608.
First nerve, (o) 20. (d) 246.
Fissure of Bichat, 42.
of Glasserius, 282.
longitudinal, 545.
of Sylvius, 31.
transverse, 545.
for vena cava, 545.
Fissures of Santorini, 80.
Flexor accessorius muscle, 699.
brevis minimi digiti, 416.
pedis, 701.
carpi radialis, 395, 420.
ulnaris, 396.
digitorum brevis pedis, 694.
longus pedis, 687. 699.
profundus, 404. 412.
sublimis, 399. 411.
pollicis longus, 405, 413.
pedis, 688. 698.
pollicis brevis, 414.
pedis, 700.
Flocculus cerebelli, 49.
Follicles Meibomian, 77.
ceruminous, 281.
of Leiberkuehn, 537, 538.
solitary, 540.
tubular, 540.
Foramen centrale of the eye, 111.
cœcum, 25, 256.
commune anterius, 38.
of Monro, 38.
ovale, 337.
rotundum, 283.
of Winslow, 516.
Foramina Thebesii, 337.
Forearm, dissection of, 391.
Fornix, 38.
Fossa hemi-elliptica, 291.
hemispherica, 291.
ischio-rectal, 450.
navicular of the ear, 78.
of the urethra, 604.
of the pudendum, 607.
ovalis, 337.
sulciformis, 291.
Fourth nerve (o) 22. (c) 60. (d) 89.
Fourth ventricle, 52.
Fovea hemi-elliptica, 291.
hemispherica, 291.
Frænum epiglottidis, 239.
Frænum labii inferioris, 241.
superioris, 241.
linguæ, 240.
præputii, 585.
Frontal artery, 2. 97.
nerve, 89.
vein, 3.
Fungiform papillæ, 256.

Galea capitis, 7.
Galen, veins of, 43.
Ganglia, cervical, inferior, 223. 229.
middle, 223. 229.
superior, 221.
lumbar, 570.
sacral, 600.
semilunar, 532.
thoracic, 360.
Ganglion, azygos, 20. 600.
cardiac, superficial, 332.
Gasserian, 60.
impar, 600.
lenticular, 94.
Meckel's, 247.
ophthalmic, 94.
otic, 252.
of Ribes, 20.
spheno-palatine, 247.
submaxillary, 202.
Gall bladder, relations, 550.
structure, 550.
Gastric artery, 529.
plexus, 533.
vein, 529.
Gastro-colic omentum, 515.
duodenal artery, 530.
epiploic artery, left, 529.
right, 531.
veins, 531.
hepatic omentum, 515.
Gastrocnemius muscle, 684.
Gemellus inferior muscle, 668.
superior muscle, 668.
General commissure of the cerebellum, 53.
Genio-hyo-glossus, 199.
hyoid muscle, 199.
Genito-crural nerve, (o) 567. (d) 488. 634
Gimbernat's ligament, 478. 628.
Gland, epiglottidean, 268.
lachrymal, 89.
parotid, 72. 86.
pineal, 45.
pituitary, 32.
prostate, 58. 601.
sublingual, 203.
submaxillary, 196.

Glands, agminate, 538.
arytænoid, 263.
axillary, 310.
bronchial, 351.
Brunner's, 537.
buccal, 241.
cervical, 121.
ceruminous, 281.
concatenate, 121.
Cowper's, 461.
inguinal, 624.
labial, 241.
laryngeal, 263.
lingual, 256.
lumbar, 570.
mammary, 310.
mediastinal, 356.
Meibomian, 77.
mesenteric, 520.
molar, 73.
odoriferous, 585.
of Pacchionus, 10.
pelvic, 597.
Peyer's, 538.
popliteal, 675.
solitary, 538.
of Tyson, 585.
Glans of the clitoris, 607.
of the penis, 586.
Glasserian fissure, 282.
Glenoid ligament, 391.
Glisson's capsule, 547.
Globus major epididymis, 504.
minor epididymis, 504.
Glosso-pharyngeal nerve, (o) 24. (d) 213.
Glottis, 262.
Gluteal artery, 663. (o) 593.
nerve, superior, 664.
nerves, inferior, 666.
Gluteus maximus muscle, 661.
medius muscle, 662.
minimus muscle, 664.
Gracilis muscle, 650.
Graafian vesicles, 609.
Great omentum, 515.
Grey substance of the cord, 156.
of the corpus striatum, 33.
of the third ventricle, 45.
tubercle of Rolando, 53.
Gustatory nerve, 195. (d) 202.

Half arch of the palate, 235.
Hamulus laminæ spiralis, 293.
Hand, 406.
dissection of, 406.
Hæmorrhoidal artery, inferior, (d) 454.
middle, 595.
superior, (o) 521.
(d) 595.
nerve, inferior, (o) 464.
(d) 452.
plexus, 597.
Head, dissection of, 1.
Heart, 333.
dissection of, 333.
Helicis major muscle, 79.
minor muscle, 79.
Helicotrema, 293.
Helix, 78.
Hepatic artery, 530. 546. (d) 547.
ducts, 531. 546. (o) 548.
plexus, 533. (d) 548.
veins, 548.
Hernia, crural or femoral, 500.
inguinal, external, 495.
internal, 496.
Hippocampus, major, 41.
minor, 41.
Humero-cubital articulation, 431.
Hyaloid membrane, 111.
Hymen, 588. 607.
Hyo-glossus muscle, 198.
Hyoid bone, 265.
Hypochondriac region of the abdomen, 505.
Hypogastric plexus of nerves, 522. 597
region of the abdomen, 505.
Hypoglossal nerve, (o) 24. (c) 179. 218. (d) 203.

Iliac artery, common, 554.
external, 555.
internal, 591.
fascia, 499. 563.
region of the abdomen, 505.
vein, common, 555.
external, 555.
internal, 596.
Iliac portion of the fascia lata, 626
Iliacus muscle, 564. 657.
Ilio-cœcal valve, 541.
Ilio-colic artery, 518.
valve, 541.
femoral articulation, 680.
inguinal nerve, (d) 471. 485. (o) 567.
lumbar artery, 592.
Ilium intestine, relations of, 507.
structure of, 538.
Incisor branch of nerve, 195.
teeth, 242.
Incus, 287.
Indicator muscle, 427.

Inferior cornu of the lateral ventricle, 41.
Inferior maxillary nerve, (o) 60. (d) 192.
Infra-orbital artery, 191. 206.
nerve, 85. 206.
vein, 206.
scapular artery, 367.
spinal artery, 374.
trochlear nerve, 93.
Infra-spinatus muscle, 370.
Infundibulum of the brain, 31.
of the cochlea, 292.
Inguinal canal, 493.
glands, 624.
hernia, external, 495.
internal, 496.
region of the abdomen, 505.
Interarticular cartilage of the jaw, 189.
cartilage sterno-clavicular, 278.
cartilage of the wrist, 436.
cartilages of the knee, 720.
Interclavicular ligament, 278.
Intercolumnar fascia, 476.
fibres, 476.
Intercostal aponeurosis, 321.
arteries, anterior branches, 322. 357.
posterior branches, 142. 357.
artery, superior, (o) 172. (d) 358.
muscle, external, 147. 321.
internal, 321. 359.
nerves, (o) 148. (d) 322. 359. 384.
nerves, cutaneous anterior, 306. 469.
nerves, cutaneous middle, 306. 309, 468.
veins, superior, 355.
Intercosto-humeral nerves, (o) 309. (d) 378.
Intestine, large, 508. 539.
small, 507. 537.
Intermuscular septa of the arm, 387.
of the thigh, 646.
Internal cutaneous nerve of the arm, (o) 318. (c) 378. 383. (d) 392.
Internal cutaneous nerve of the thigh, (d) 634. (o) 647.
Interosseous arteries of the foot, 712.
artery, anterior, 405.
posterior, 428.
ligament of the arm, 433.
of the leg, 721.
muscles of the foot, 703.
muscles of the hand, 419. 430.
Interosseous nerve, anterior, 406.
posterior, 429.
Interspinal muscles, 146.
Intertransverse muscles, 147. 271.
Intestinal arteries, 518.
canal, 505.
form, 505.
divisions, 505.
structure, 534.
villi, 537.
Intestinum crassum, 505.
tenue, 505.
Intra-spinal arteries, 157.
veins, 158.
Iris, 106.
Ischio-rectal fossa, 450.
Island of Reil, 31.
Isthmus faucium, 238.
of the thyroid body, 227.
Iter a tertio ad quartum ventriculum, 44.
Iter ad infundibulum, 44.

Jacob's membrane, 109.
Jacobson's nerve, (o) 214. (d) 288.
Jejunum, relations of, 507.
structure, 538.
Joint, ankle, 722.
elbow, 431.
hip, 680.
knee, 716.
lower jaw, 188.
shoulder, 390.
wrist, 434.
Jugular vein, anterior, 160.
external, 115.
internal, 210.

Kidney, form, 556.
relations of, 511.
structure, 557.
vessels of, 556.
Knee of the corpus callosum, 33.
Knee-joint, 716.

Labia, 241.
pudendi externa, 607.
interna, 607.
Labial glands, 241.
artery, inferior, 70.
Labyrinth, membranous, 294.
osseous, 290.
Lachrymal artery, 95.
canals, 100.
duct, 101.
gland, 89.
nerve, 90.
sac, 101.

Lacteal vessels, 520.
Lacunæ of the urethra, 604.
Lamina cinerea, 32.
cornea cerebri, 41.
spiralis cochleæ, 292.
Large intestine or colon, 508. 539.
Laryngeal arteries, 265.
nerve, external, 216.
inferior, (o) 216. (d) 264.
superior, (o) 217. (d) 264.
pouch, 262.
veins, 265.
Larynx, 258.
aperture of, 261.
cartilages of, 266.
dissection of, 258.
interior of, 261.
muscles, 259.
nerves, 263.
ventricle, 261.
vessels, 265.
Lateral fibres of the cord, 27.
sinus, 56.
ventricles, 36.
Latissimus dorsi, 124. 128. 319.
Laxator tympani, 286.
Leg, dissection of the back, 682.
front, 705.
Lenticular ganglion, 94.
Levator anguli oris, 67.
scapulæ, 128.
ani, 456. 575.
glandulæ thyreoideæ, 227.
labii inferioris, 69.
superioris, 67.
alæque nasi, 67.
palati, 236.
palpebræ superioris, 91.
prostatæ, 577.
Levatores costarum, 147.
Lieberkuehn's follicles, 537, 538.
Ligament of the lung, 326.
Ligaments of the bladder, 579. 582. 587.
of the larynx, 268.
of the ovary, 609.
of the uterus, 587.
Ligament, alar of the axis, 277.
of the knee, 719.
annular, anterior of the ankle, 707.
external of the ankle, 707.
internal of the ankle, 691.
annular, anterior of the wrist, 420.
Ligament, annular, posterior of the wrist, 421. 431.
astragalo-scaphoid, 725.
atlo-axoid, anterior, 275.
posterior, 275.
transverse, 277.
calcaneo-astragaloid external, 725.
calcaneo-astragaloid, posterior, 725.
calcaneo-cuboid, inferior, 727.
superior, 727.
calcaneo-scaphoid, external, 726.
calcaneo-scaphoid, inferior 726.
capsular of the hip, 680.
of the knee, 716.
of the shoulder, 390.
of the thumb, 438.
carpal, dorsal, 436.
palmar, 436.
common, anterior, 274. 365. 615.
common, posterior, 274. 364. 615.
conoid, 372.
coraco-acromial, 373.
clavicular, 372.
humeral, 390.
costo-clavicular, 278.
coracoid, 313.
transverse, anterior, 362.
middle, 363.
posterior, 362.
costo-vertebral, 362.
cotyloid, 681.
crico-thyroid, 268.
crucial, 719.
deltoid, 723.
dentate, 152.
dorsal of the carpus, 437.
of Gimbernat, 478, 628.
glenoid, 391.
ilio-femoral, 681.
lumbar, 612.
interarticular of the clavicle, 278.
of the hip, 681.
of the jaw, 189.
of the knee, 720.
of the pubes, 590.
of the ribs, 362.
of the wrist, 436.
interclavicular, 278.
interosseous of astragalus and os calcis, 725.

Ligament, interosseous of carpus, 439.
interosseous of cuneiform bones, 730.
interosseous of metacarpal bones, 437.
interosseous of metatarsal bones, 730.
interosseous of radius and ulna, 433.
interosseous of the scaphoid and cuboid, 727.
interosseous of the tibia and fibula, 721.
interosseous, inferior, of the tibia and fibula, 722.
interspinal, 273. 364. 614.
intervertebral, 275. 365. 615.
lateral, external of the ankle, 723.
lateral, internal, 723.
lateral, external of the carpus, 437.
lateral, internal, 437.
lateral, external of the elbow, 431.
lateral, internal, 431.
lateral, phalangeal of the foot, 731.
lateral, phalangeal of the hand, 439.
lateral, external of the jaw, 188.
lateral, internal, 188.
lateral, external of the knee, 716.
lateral, internal, 717.
lateral, external of the wrist, 434.
lateral, internal, 434.
long plantar, 727.
metacarpal, dorsal, 437.
palmar, 437.
metatarsal, dorsal, 730.
palmar, 730.
mucous, 719.
obturator, 611.
occipito-atloid, anterior, 276.
posterior, 276.
occipito-axoid, 276.
odontoid, 277.
orbicular of the radius, 432.
of the patella, 718.
peroneo-tibial, upper anterior, 721.
peroneo-tibial, upper posterior, 721.
peroneo-tibial, lower anterior, 722.
Ligament, peroneo-tibial, lower posterior, 722.
of Poupart, 477. 628.
proper of the scapula, 373.
pubic anterior, 590.
posterior, 590.
round of the hip, 681.
round of the radius and ulna, 434.
sacro-coccygeal, anterior, 613.
posterior, 614.
sacro-iliac, anterior, 612.
oblique, 612.
posterior, 612.
sacro-sciatic, anterior or large, 669.
sacro-sciatic, posterior or small, 613. 670.
sacro-vertebral, 613.
of the scapula, anterior, 373.
posterior, 373.
stellate, 362.
sterno-clavicular, anterior, 278.
sterno-clavicular, posterior, 278.
stylo-hyoid, 207.
maxillary, 189.
sub-pubic, 590.
supra-spinous, 273. 364. 614.
suspensory of penis, 472.
tarso-metatarsal, dorsal, 728.
plantar, 729.
thyro-hyoid, 268.
arytænoid, 269.
tibio-tarsal, 722.
transverse of the atlas, 277.
of the fingers, 407.
of the hip, 681.
of the knee, 721.
of the metacarpus, 418.
of the metatarsus, 702.
of the toes, 693.
trapezoid, 373.
triangular of the abdomen, 478.
of the urethra, 459.
of Winslow, or posterior, 717.
Ligamentum arcuatum externum, 560.
internum, 560.
dentatum, 152.
latum pulmonis, 326.
mucosum, 719.
nuchæ, 128.
subflavum, 274. 363. 614.
teres, 681.

Limbus luteus, 111.
Linea alba, 476.
semilunaris, 477.
Lineæ transversæ, 477.
Lingual artery, 200.
glands, 256.
nerve, 195. (d) 202.
veins, 202.
Lingualis muscle, 200.
Lips, 241.
Liquor Cotunni, 293.
Morgagni, 114.
Lithotomy, 465.
Liver, form and divisions, 544.
ligaments, 543.
relations of, 509.
structure, 547.
vessels, 546.
Lobes of the cerebellum, 49.
of the cerebrum, 15.
Lobular biliary plexus, 549.
Lobular venous plexus, 549.
Lobules of the testis, 503.
Lobulus auris, 78.
caudatus, 545.
quadratus, 545.
Spigelii, 545.
Locus niger, 30.
perforatus, 31.
Longissimus dorsi, 136.
Longitudinal fissure of the liver, 545.
sinus, inferior, 56.
superior, 9.
Longus colli muscle, 270.
Lumbar aponeurosis, 125.
arteries, 570.
anterior branches, 571.
posterior branches, 142.
(o) 571.
ganglia, 570.
glands, 570.
nerves, anterior branches, 566.
posterior branches, 141.
plexus, 566.
region of the abdomen, 505.
veins, 571.
Lumbo-aortic plexus, 522.
sacral nerve, 569.
Lumbricales of the foot, 699.
of the hand, 413.
Lungs, 328.
form, 328.
relations, 328.
structure, 352.
Lymphatic duct, 355.
Lymphatics of the arm, 377.
of the axilla, 310.
of the groin, 470.
Lymphatics of the loins, 570.
of the lungs, 351.
of the mesentery, 520.
of the neck, 121.
of the pelvis, 597.
of the penis, 470.
of the popliteal space, 675.
of the thorax, 323. 356.
Lyra, 39.

Macula cribrosa, 291.
Malleus, 286.
Malleolar artery, external, 711.
internal, 711.
Mammary artery, internal, (o) 170. (d) 323. 490. (c) 346.
gland, 310.
Mamillæ of the kidney, 557.
Masseter muscle, 184.
Masseteric artery, 190.
nerve, 193.
Mastoid cells, 283.
Maxillary artery, internal, 189.
nerve, inferior, (o) 60. (d) 192.
superior, 205.
vein, internal, 191.
Meatus, artery of, 295.
Meatus auditorius externus, 280.
nerves of, 281.
vessels of, 281.
Meatuses of the nose, 244.
Meckel's ganglion, 247.
Median basilic vein, 376.
cephalic vein, 377.
nerve, (o) 318. (c) 382. 402. (d) 410.
vein, 392.
Mediastinum, anterior, 327.
posterior, 327.
testis, 502.
Mediastinal arteries, 323.
Medulla innominata, 30.
oblongata, 25.
spinalis, 152.
Medullary capsule of Reil, 33.
layer of the retina, 110.
substance of the kidney, 557.
velum, anterior, 51.
posterior, 50.
Meibomian follicles, 77.
Membrana dentata, 152.
pigmenti, 105.
pupillaris, 107.
sacciformis, 436.
tympani, 281.
Membrane hyaloid, 111.
Jacob s, 109.
of the labyrinth, 293.

Membranous labyrinth, 294.
part of the urethra, 584. 604.
Membranula of Zinn, 113.
Meningeal artery, anterior, 58.
middle, 58. 190.
posterior, 58.
small, 58. 190.
Mental artery, 190.
nerve, (o) 195. (d) 85.
Mesenteric artery, inferior, 521.
superior, 517.
glands, 520. 522.
plexus, inferior, 522.
superior, 519.
vein, inferior, 521.
superior, 519.
Mesentery, 516.
Meso-cæcum, 516.
colon, left, 516.
right, 516.
transverse, 515.
rectum, 516.
Metacarpal artery, 401. 430.
Metatarsal artery, 712.
Mitral valve, 341.
Modiolus, 292.
Molar teeth, 242.
glands, 73.
Mons veneris, 607.
Morsus diaboli, 608.
Motor oculi nerve, (o) 22. (c) 60. (d) 92. 97.
Mouth, cavity of, 240.
Multifidus spinæ muscle, 146.
Muscles of the ureters, 603.
Muscular artery, 183.
Musculi pectinati, 337. 341.
Musculo-phrenic artery, 323.
Musculo-cutaneous nerve, (o) 318. (d) 705.
of the lumbar plexus, 567.
Musculo-spiral nerve, (o) 319. (d) 388.
Musc. abductor digiti minimi, 415.
digiti minimi pedis, 695.
indicis, 419.
oculi, 98.
pollicis, 414.
pollicis pedis, 694.
accelerator urinæ, 457.
accessorius pedis, 699.
accessorius ad sacro lumbalem, 135.
adductor brevis, 652.
digiti minimi, 416.
longus, 651.
magnus, 656. 680.
Musc. adductor oculi, 98.
pollicis manûs, 415.
pedis, 700.
anconeus, 425.
anterior auris, 6.
anti-tragus, 79.
arytænoideus, 260.
arytæno-epiglottideus, 260.
arytæno-epiglottideus, inferior, 262.
attolens aurem, 6.
oculum, 91.
attrahens aurem, 6.
azygos uvulæ, 237.
biceps femoris, 677. 716.
flexor cubiti, 379. 390. 421.
biventer cervicis, 137.
brachialis anticus, 384. 420.
buccinator, 68.
cervicalis ascendens, 135.
circumflexus palati, 236.
coccygeus, 575.
complexus, 137.
compressor naris, 69.
urethræ, 460.
venæ dorsalis penis, 473.
constrictor inferior, 232.
isthmi faucium, 238.
constrictor medius, 233.
superior, 233.
coraco-brachialis, 380.
corrugator supercilii, 66.
cremaster, 481.
crico-arytænoideus lateralis, 260.
posticus, 260.
thyroideus, 259.
crureus, 645.
deltoides, 368.
depressor anguli oris, 69.
labii inferioris, 69.
superioris alæque nasi, 69.
oculi, 98.
diaphragma, 361, 559.
digastricus, 178.
erector clitoridis, 466.
penis, 457.
spinæ, 135, 136.
extensor carpi radialis brevis, 423.
longus, 422.
ulnaris, 425.
digiti minimi, 424.
digitorum brevis pedis, 712.
digitorum communis, 424.

Musc. extensor digitorum longus pedis, 709.
indicis, 427.
ossis metacarpi pollicis, 426.
primi internodii pollicis, 426.
pollicis proprius, 708.
secundi internodii pollicis, 427.
flexor accessorius, 699.
brevis digiti minimi, 416.
brevis digiti minimi pedis, 701.
carpi radialis, 396. 420.
ulnaris, 396.
digitorum brevis pedis, 694.
profundus, 404. 412
sublimis, 399. 411.
longus pedis, 687. 699.
pollicis longus, 405. 413.
pedis, 688, 698.
pollicis brevis, 414.
pedis, 700.
gastrocnemius, 684.
gemellus inferior, 668.
superior, 668.
genio-hyo-glossus, 199.
hyoideus, 199.
gluteus maximus, 661.
medius, 662.
minimus, 664.
gracilis, 650.
helicis major, 79.
helicis minor, 79.
hyo-glossus, 198.
iliacus, 564, 657.
indicator, 427.
infra-spinatus, 370.
intercostales externi, 147, 321.
interni, 321, 359.
interossei manûs dorsales, 419. 430.
palmares, 419. 430.
pedis dorsales, 703.
plantares, 703.
interspinales, 146.
inter-transversales, 147. 271.
latissimus dorsi, 124. 128. 319.
laxator tympani major, 286.
levator anguli oris, 67.
scapulæ, 128.
ani, 456, 575.
Musc. levator glandulæ thyreoideæ, 227.
labii inferioris, 69.
superioris, 67.
superioris alæque nasi, 67.
palati, 236.
palpebræ, 91.
prostatæ, 577.
uvulæ, 237.
levatores costarum, 147.
lingualis, 200.
longissimus dorsi, 136.
longus colli, 270.
lumbricales manûs, 413.
pedis, 699.
mallei externus, 286.
parvus, 286.
internus, 285.
massetericus, 184.
multifidus spinæ, 146.
mylo-hyoideus, 196. 198.
obliquus abdominis externus, 474. 479.
obliquus abdominis internus, 479. 482.
obliquus capitis inferior, 144.
superior, 145.
obliquus oculi inferior, 98.
superior, 91.
obturator externus, 658. 669.
internus, 611. 668.
occipito-frontalis, 6.
omo-hyoideus, 129. 165.
opponens digiti minimi, 416.
pollicis, 414.
orbicularis oris, 66.
palpebrarum, 65.
palato-glossus, 238.
pharyngeus, 238.
palmaris brevis, 407.
longus, 396.
pectineus, 650.
pectoralis major, 311.
minor, 313.
peroneus brevis, 715.
longus, 714.
tertius, 709.
plantaris, 685.
platysma myoides, 115. 159.
popliteus, 686. 716.
pronator quadratus, 405.
radii teres, 395.
psoas magnus, 563. 657.
parvus, 565.
pterygoideus externus, 187.
internus, 187.
pyramidalis abdominis, 484.
nasi, 66.

Musc. pyriformis, 610. 664.
quadratus femoris, 669.
lumborum, 565.
quadriceps extensor cruris, 643.
rectus abdominis, 483.
capitis anticus major, 270.
anticus minor, 271.
lateralis, 218.
capitis posticus major, 145.
minor, 145.
femoris, 643, 664.
oculi externus, 98.
inferior, 98.
internus, 98.
superior, 91.
retrahens aurem, 6.
rhomboideus major, 129.
minor, 128.
risorius Santorini, 68.
sacro-lumbalis, 135.
sartorius, 639.
scalenus anticus, 166.
minimus, 168.
posticus, 167.
semi-spinalis colli, 146.
dorsi, 146.
semi-membranosus, 679. 717.
semi-tendinosus, 678.
serratus magnus, 133. 320.
posticus inferior, 132.
superior, 132.
soleus, 685.
sphincter ani externus, 455.
internus, 456.
vaginæ, 466.
spinalis dorsi, 134.
splenius capitis, 133.
colli, 133.
stapedius, 286.
sterno-cleido-mastoideus, 163.
hyoideus, 165.
thyroideus, 165.
stylo-glossus, 199.
hyoideus, 179.
pharyngeus, 207.
subclavius, 319.
subscapularis, 367.
supinator radii brevis, 427.
longus, 422.
supra-spinatus, 374.
temporalis, 8. 185.
tensor palati, 236.
tarsi, 100.
tympani, 285.
vaginæ femoris, 643.
teres major, 271.
minor, 271.
thyro-arytænoideus, 260.
Musc. thyro-epiglottideus, 261.
hyoideus, 166.
tibialis anticus, 708.
posticus, 687. 704.
trachelo-mastoideus, 136.
tragus, 79.
transversalis abdominis, 482.
colli, 136.
transversus auris, 79.
pedis, 701.
perinæi, 457.
alter, 457.
trapezius, 124. 127.
triangularis sterni, 324.
triceps extensor cubiti, 386.
vastus externus, 643. 645.
internus, 644, 645.
zygomaticus major, 67.
minor, 67.
Mylo-hyoid artery, 190.
muscle, 196. 198.
nerve, 195.

Nares posterior, 235.
Nasal artery, 97.
lateral, 71.
cartilages, 73.
duct, 101.
fossæ, 243.
nerve, 93. (d) 86. (e) 254.
Naso-palatine nerve, 247.
Nates, 47.
Neck, anterior triangle of, 161.
posterior, 116.
dissection of, 114. 158.
Nerve of Wrisberg, (o) 318. (d) 378. (e) 383.
Nerve to the inferior gemellus and quadratus, 600. 667.
crureus, 648.
latissimus, 319.
levator anguli scapulæ, 131. 178.
obturator internus, 599.
pectineus, 647.
pyriformis, 599. (d) 667.
rhomboid muscle, (o) 174. (d) 131.
serratus muscle, (o) 174. (d) 131. 319.
subclavius, 174.
superior gemellus, 667.
tensor tympani, 253.
vaginæ femoris, 649.
teres major, 319.
minor, 370.
vastus externus, 648.
internus, 648.

Nerv. abducens, (o) 23. (c) 61. (d) 97.
accessorius obturatorii, (o) 569. (d) 651.
accessorius spinalis, (o) 24. (c) 217. (d) 127.
acromiales cutanei, 120.
articulares poplitei azygos, 676.
articulares poplitei inferiores, 675.
articulares poplitei obturatoris, 677.
articulares poplitei superiores, 676.
auditorius, (o) 23. (d) 295.
auriculares anteriores, 120. 194.
auricularis magnus, 119.
auricularis pneumogastricus, (o) 215. (d) 289.
auricularis posterior, 5. 82.
auriculo-temporalis, 194.
buccinatorius, 193.
cardiacus inferior (o) 224. 230. (d) 349.
cardiacus medius, (o) 223. 230. (d) 349.
cardiacus pneumogastrici, (o) 217. 230. (d) 330.
cardiacus superior, (o) 222. 230. (d) 331.
cervicales nervi facialis, 159.
cervicales, rami anteriores, 176. 316.
cervicales, rami posteriores, 138.
cervicalis, superficialis, 120. 159.
cervico-facialis, 84. 157.
chorda tympani, (d) 195. (o) 251.
ciliares ganglii ophthalmici, 94. 108.
ciliares nasalis, 93. (d) 168.
circumflexus, (o) 319. (d) 370.
clavicularis cutanei, 120 (d) 305.
communicans poplitei externi, 683.
communicans poplitei interni, 683.
corporis bulbosi, 464.
cruralis, (o) 568. (d) 647.
vaginæ, 647.
cutaneus accessorius saphenus (o) 647. (d) 635.
cutaneus externus brachialis, (o) 318. (c) 385. (d) 393.
cutaneus externus lumbalis, (o) 568. (d) 633. 660.
cutaneus externus musculo-spiralis, (d) 378. (o) 380.
Nerv. cutaneus internus brachialis, (o) 318. (c) 378. 383. (d) 392.
cutaneus internus femoris, (d) 634. (o) 647.
cutaneus internus ischiadicus, (d) 452. (o) 666.
cutaneus internus musculo-spiralis, (o) 380. (d) 378.
cutaneus internus Wrisbergii, (o) 318. (d) 378. (c) 383.
cutaneus longus obturatorii, (o) 655. (c) 655. (d) 635. 684.
cutaneus maxillaris inferioris, 5.
superioris, 4.
cutaneus medius femoris, (o) 647. (d) 634.
cutaneus musculo-cutaneus, 293.
palmaris, 403. 406.
plantaris, 692,
radialis, 393.
Sœmmeringii, 666.
ulnaris anterior, 402.
posterior, 393.
dentales posteriores, 205.
dentalis anterior, 206.
inferior, 194.
descendens noni, 179.
diaphragmaticus (o) 177. (c)346. (d) 552.
digastricus, 82.
digitales mediani, 410.
plantares, 697, 698.
radiales, 393.
ulnares, 410.
dorsales, rami anteriores, 359.569.
dorsales, rami posteriores, 140. 360.
dorsalis penis, 464. (d) 472.
dorsi-lumbalis, 566.
facialis, (o) 23. (d) 82. (c) 251.
frontalis, 89.
genito-cruralis, 567.
genito-cruralis, ramus femoralis, 634.
genito-cruralis, ramus genitalis, 489.
glosso-pharyngeus, (o) 24. (d) 213.
glutei inferiores, 666.
gluteus superior, 664.
gustatorius, 195. (d) 202.
hæmorrhoidales superiores, 597.
hæmorrhoidalis inferior, (d) 452. (o) 464. 599.
hepatici, 533.
hypoglossus, (o) 24. (c) 179. 218. (d) 203.

Nerv. ilio-inguinalis, (d) 471. 485. (o) 567.
incisorius, 195.
infra-maxillares nervi facialis, 84.
orbitales nervi facialis, 83.
orbitalis, 85. 206.
trochlearis, 93.
intercostales, (o) 148. (d) 322. 484.
intercosto-cutanei anteriores, 306. 469.
intercosto-cutanei medii, 306. 468.
intercosto-humerales, (o) 309. (d) 378.
interosseus anticus, 406.
posticus, 429.
ischiadicus major, (o) 600. (c) 666. 679. (d) 679.
ischiadicus minor, (o) 600. (c) 665. (d) 666. 684.
lachrymalis, 90.
laryngeus externus, 216.
laryngeus inferior, (o) 217. 229. 347. (d) 264.
laryngeus superior, (o) 216. (d) 264.
lingualis, (o) 24. (c) 179. 218. (d) 203.
lumbales, rami anteriores, 566.
rami posteriores, 141.
lumbo-sacralis, 569.
malares nervi facialis, 83.
malaris, 99.
massetericus, 193.
maxillaris inferior, (o) 60. (d) 192.
maxillaris superior, 205.
medianus, (o) 318. (c) 382. 402. (d) 410.
mentalis, 85. 195.
molles, 223.
motor oculi, (o) 22. (c) 60. (d) 92. 97.
musculo-cutaneus brachii, (o) 318. (c) 385. (d) 393.
musculo-cutaneus cruris, 713. (d) 705.
musculo-cutaneus lumbalis, (d) 485. (o) 567.
musculo-spiralis, (o) 319. (d) 388.
mylo-hyoideus, 195.
nasalis, (d) 86. (o) 93. (c) 254.
orbitalis, 93.
naso-palatinus, 247.
obturatorius, (o) 569. (d) 655.
obturatorius, articulares, 655, 656. 677.
occipitalis major, (d) 5. (o) 139.
Nerv. occipitalis minor, (d) 5. (o) 120.
œsophageales, 348.
olfactorius, (o) 20. (d) 246.
ophthalmicus, (o) 61. (d) 97.
opticus, (o) 21. (c) 94. (d) 110.
orbitalis, (d) 99. (o) 205.
palatinus magnus, 248.
medius, 248.
minor, 248.
palpebrales inferiores, 85.
superiores, 90. 93.
palmaris cutaneus, 406.
ulnaris profundus, 418.
superficialis, 410.
patheticus, (o) 22. (c) 60. (d) 89.
perforans Casserii, (o) 318. (c) 385. (d) 393.
perinæales superficiales, 453.
petrosus superficialis magnus, 249.
petrosus superficialis parvus, (d) 253. (o) 289.
pharyngei, 222.
pharyngeus, 216.
phrenicus, (o) 177. (c) 346. (d) 552.
plantaris externus, 697.
plantaris externus profundus, 703.
plantaris externus superficialis, 698.
plantaris internus, 696.
pneumo-gastricus, (o) 24. (d) 214. 347. 531.
popliteus externus, 675.
internus, 676.
portio dura, (o) 23. (d) 82. (c) 251.
portio mollis, (o) 23. (d) 295.
pterygoidei, 194.
pterygoideus internus, 253.
pudendus inferior, (o) 666. (d) 454.
pudendus internus, (o) 599. (d) 463.
pulmonares anteriores, 348.
posteriores, 348.
radialis, (d) 393. (c) 403.
recurrens, (o) 217. (d) 264.
articularis, 713.
renales, 534.
respiratorius externus, (o) 174. (c) 131. (d) 319.
sacrales, rami anteriores, 598.
rami posteriores, 142.
saphenus externus, 683. (d) 706.
saphenus internus, (c) 649. (d) 635. 683. 706.
spermatici, 522.

Nerv. spheno-palatini, 247.
spinales, 153. (c) 271.
origo, 145. 157.
radices, 153.
splanchnicus major, (o) 360. (d) 533.
splanchnicus minor, (o) 370. (d) 534.
splenici, 533.
sternales cutanei, 120. (d) 305.
stylo-hyoideus, 82.
sub-occipitalis, ramus anterior, 219.
sub-occipitalis, ramus posterior, 138.
subscapulares, 319.
superficialis cordis dexter, 222. (d) 349.
superficialis cordis sinister, 230. (d) 332.
supra-maxillares nervi facialis, 84.
orbitalis, 4. 84. 90.
scapularis, (o) 130. (d) 375.
trochlearis, 90.
sympatheticus abdominis, 519. 570.
sympatheticus cervicis, 219.
pelvis, 600.
thoracis, 360.
temporales nervi facialis, 83.
profundi, 192.
temporales superficiales, (d) 4, 5. (o) 99. 194.
temporo-facialis, 82.
thoracici anteriores, 317.
thoracicus posterior, (c) 131. (o) 174. (d) 319.
thyro-hyoideus, 180.
tibialis anticus, 713. (d) 706.
posticus, 690.
trigeminus (o) 22. (c) 60.
trochlearis (o) 22. (c) 60. (d) 89.
tympanicus (o) 214. (d) 288.
ulnaris (o) 318. (c) 383. 402. (d) 410. 418.
uterini, 597.
vaginales, 597.
vidianus, 249.
Ninth nerve (o) 24. (c) 179. 218. (d) 203.
Nodule, 49.
Nose, cavity of, 243.
meatus of, 244.
vessels and nerves of, 244.
Nutritious artery of fibula, 689.
of humerus, 384.
of tibia, 690.
Nymphæ, 607.
Obliquus abdominis externus, 474. 479.
internus, 479. 482.
capitis inferior muscle, 144.
superior muscle, 145.
oculi inferior, 98.
superior, 91.
Obturator artery, 658. (o) 593.
fascia, 573.
ligament, 611.
muscle, external, 658. 669.
internal, 611, 668.
nerve, (o) 569. (d) 655.
Occipital artery, (o) 183. (c) 143. (d) 3.
vein, 4. 183.
sinuses, 56.
Occipitalis minor nerve, 120.
Occipito-atloid articulation, 275. 278.
ligaments, 275. 278.
axoid ligaments, 276.
Odontoid ligaments, 277.
Œsophagus, relations of, 228, 356.
structure, 356.
Œsophageal arteries, 357, 529.
nerves, 348.
opening of diaphragm, 561.
Olfactory bulb, 21.
nerve, (o) 20. (d) 246.
Olivary body, 26.
Omentum, great, 515.
small, 515.
splenic, 516.
Omo-hyoid muscle, 129. 164.
Ophthalmic artery, 95.
nerve, 61.
vein, 97.
Opponens pollicis muscle, 416.
Optic commissure, 21.
nerve, (o) 21. (c) 94.
thalami, 45. 47.
Orbicular ligament of the radius, 432.
Orbicularis oris, 66.
palpebrarum, 65.
Orbit, 87.
dissection of, 87.
muscles of, 91.
nerves of, 89.
periosteum of, 88.
vessels, 95.
Orbital branch of nerve, (d) 99. (o) 205.
Orifice of the urethra, 607.
of the uterus, 608.
of the vagina, 607.
Os hyoides, 265.
Ossicula auditûs, 284.
Os tincæ, 608.
uteri, externum, 608.
internum, 608.
Otic ganglion, 252.

Otoconia, 294.
Outlet of the pelvis, 574.
Ovaries, 609.
Ovula Graafiana, 609.

Palatine arteries, superior, 255.
artery, inferior, 182.
nerves, large, 248.
small, 248.
Palato-glossus, 238.
Palato-pharyngeus, 238.
Palmar arch, deep, 417.
superficial, 408.
branch of the ulnar, deep, 418.
branch of the ulnar, superficial, 410.
cutaneous nerve, 403. 406.
fascia, 407.
Palmaris brevis muscle, 407.
longus muscle, 395.
Palpebræ, 75.
Palpebral arteries, 76. 97.
ligament, 76.
nerves, 76.
veins, 76.
Pampiniform plexus, 554.
Pancreas, 527.
form and divisions, 527.
structure of, 542.
Pancreatic arteries, 517. 529.
duct, 542.
veins, 530.
Pancreatico-duodenal artery, 530.
Papillæ circumvallatæ, 256.
conical, 256.
fungiform, 256.
Parotid gland, 72. 86.
arteries, 73.
veins, 73.
Patheticus nerve, (o) 22. (c) 60. (d) 89.
Pecten of Reil, 39.
Pectineus muscle, 650.
Pectoralis major muscle, 311.
minor muscle, 313.
Peduncles of the cerebellum, inferior, 27.
middle, 51.
superior, 51.
of the pineal body, 45.
Pelvis, female, dissection of, 586.
male, 571.
dissection of, 571.
Pelvic fascia, 572.
Penis, form of, 584.
structure of, 604.
vessels of, 605.
Perforating arteries of the femoral, 654.
of internal mammary, 323.
Perforating arteries of the palm, 417.
of the sole, 701.
Perforans Casserii nerve, (o) 318. (c) 385. (d) 393.
Pericardium, 332.
Perilymph, 293.
Perinæum, female, 466.
dissection of, 466.
male, 447.
dissection of, 447.
Perinæal artery, superficial, 454.
fascia, deep, 459.
superficial, 451.
nerves, superficial, 453.
Periosteum of the orbit, 88.
Peritonæal prolongation on the cord, 487.
Peritonæum, 511.
of female pelvis, 586.
of male pelvis, 578
Peroneal artery, 689.
anterior, 689.
posterior, 690.
Peroneus brevis muscle, 715.
longus muscle, 714.
tertius muscle, 709.
Peroneo-tibial articulations, 721, 722.
Pes accessorius, 41.
hippocampi, 42.
Petrosal sinus, inferior, 58.
superior, 57.
nerve, large, 249.
small, 253.
Peyer's glands, 538.
Pharynx, dissection of, 230.
muscles of, 232.
nerves of, 234.
Pharyngeal ascending artery, 211.
nerve, 216.
vein, 212.
Phrenic artery, 346.
nerve, (o) 177. (c) 346. (d) 552.
veins, 552.
Pia mater of the brain, 14.
of the cord, 151.
Pigmentum nigrum, 105.
Pillars of the abdominal ring, 475.
Pineal body, 45.
Pinna, or auricle of the ear, 78.
Pituitary body, 32.
Plantar aponeurosis, 692.
arch of the artery, 701.
artery, external, 696.
internal, 696.
ligament, long, 727.
short, 727.
nerve, external, 697. 703.
internal, 696.
Plantaris muscle, 685.

Platysma myoides muscle, 115. 159.
Pleuræ, 326.
Plexus brachial, 173. 317.
cardiac, 331, 349.
carotid, 221.
cervical, 176.
posterior, 140.
choroides cerebri, 43, 44.
cerebelli, 53.
cœliac, 533.
coronary, anterior, 336.
posterior, 336.
coronary of the stomach, 533.
diaphragmatic, 534.
hepatic, 533.
hæmorrhoidal, 597.
hypogastric, 522. 597.
lobular biliary, 549.
venous, 549.
lumbar, 566.
lumbo-aortic, 522.
mesenteric, inferior, 522.
superior, 519.
œsophagean, 348.
pampiniform, 554.
pharyngeal, 234.
posterior spinal of veins, 158.
transverse of veins, 158.
pterygoid of veins, 192.
pulmonary, anterior, 348.
posterior, 348.
renal, 534.
supra, 534.
sacral, 599.
solar, 533.
spermatic of nerves, (o) 522. (d) 489.
spermatic of veins, 489.
splenic, 533.
tympanic, 288.
transverse of veins, 158.
uterine, 597.
vaginal, 597.
vesical, 597.
vesico-prostatic, 597.
vertebral, 273.
Plica retinæ, 111.
semilunaris, 75.
Pneumo-gastric nerve (o) 24. (d) 214. 347. 531.
Pomum Adami, 266.
Pons Varolii, 28.
Popliteal artery, 672.
glands, 675.
nerve, external, 675.
internal, 676.
space, 671.
vein, 675.
Popliteus muscle, 687, 716.
Portio dura (o) 23. (c) 250. (d) 82.
mollis, (o) 23. (d) 295.
Porus opticus, 111.
Posterior commissure, 46.
ligament of Winslow, 717.
medullary velum, 50.
pyramid, 53.
triangle of the neck, 116.
Poupart's ligament, 477. 628.
Pouch, laryngeal, 262.
of the auricula, 337. 341.
of the peritonæum, 498.
Prepuce, 585.
Princeps cervicis artery, 143.
pollicis artery, 417.
of the foot, 702.
Processus cochleariformis, 283.
e cerebello ad testes, 51.
vermiformis inferior, 49.
superior, 49.
Profunda artery, inferior, 384.
of the neck, (o) 172. (d) 143.
of the thigh, 653.
superior, (o) 384. (d) 388.
Promontory, 282.
Pronator quadratus muscle, 405.
radii teres muscle, 395.
Proper ligaments of the scapula, 373.
Prostate gland, divisions, 601.
relations, 582.
structure, 601.
Prostatic part of the urethra, 584. 603.
sinuses, 604.
Protuberantia annularis, 28.
Psoas magnus muscle, 563. 657.
parvus muscle, 565.
Pterygoid arteries, 191. 254.
nerves, external, 194.
nerve, internal, 253.
plexus of veins, 192.
Pterygoideus externus muscle, 187.
internus muscle, 187.
Pterygo-palatine artery, 254.
Pubic portion of the fascia lata, 626. 632.
region of the abdomen, 505.
symphysis, 590.
Pudendum, 607.
Pudendal inferior nerve, (o) 666. (d) 454.
Pudic arteries, external, 470. 638. (d) 624.
artery, internal, (d) 462. (o) 593.
nerve, internal, (o) 599. (d) 463.
Pulmonary artery, 339, 350.
veins, 351.

Puncta lachrymalia, 100.
Pupil, 106.
Pylorus, 526.
Pyloric artery, inferior, 530.
superior, 530.
Pyramid, anterior, 26.
decussation of, 26.
of the cerebellum, 49.
of the thyroid body, 227.
of the tympanum, 283.
posterior, 53.
Pyramidal fibres of the cerebrum, 40.
Pyramidalis abdominis muscle, 484.
nasi muscle, 66.
Pyriformis muscle, 664. 610.

Quadratus femoris muscle, 669.
lumborum muscle, 565.

Radial artery, 397. 429. (d) 416.
nerve, (d) 393. (c) 403.
veins, 398.
cutaneous, 392.
Radialis indicis artery, 417.
Radio-carpal articulation, 434.
Radio-ulnar articulations, 432. 435.
Ranine artery, 201.
veins, 202.
Raphé of the corpus callosum, 35.
of the perinæum, 448.
Receptaculum chyli, 562.
Recto-vesical fascia, 576.
Rectus abdominis muscle, 484.
capitis anticus major, 270.
minor, 271.
posticus major, 145.
minor, 145.
lateralis, 218.
femoris, 643. 664.
oculi externus, 98.
inferior, 98.
internus, 98.
superior, 91.
Rectum, relations of, in the female, 587.
in the male, 579.
structure, 605.
Recurrent interosseous artery, 420.
radial, 398.
tibial, 711.
ulnar, anterior, 401.
posterior, 401.
nerve of pneumo-gastric, (o) 217. 347. (d) 264.
nerve of the tibial, 713.
Removal of the brain, 11.
Renal artery, 553.
plexus, 534.
vein, 553.
Respiratory nerve, external, (c) 131. (o) 174. (d) 319.
internal, (o) 177. (c) 346. (d) 552.
Restiform body, 27. 53.
Rete testis, 503.
Retina, 109.
Retrahens aurem, 6.
Rhomboideus major muscle, 129.
minor, 128.
Rima of the glottis, 262.
Ring, abdominal, external, 475.
internal, 487.
femoral, 500. 630.
Risorius Santorini muscle, 68.
Root of the lung, 329.
Round ligament of the hip-joint, 681.
of the liver, 543.
of the uterus, 609.
Rugæ of the bladder, 602.
of the stomach, 536.
of the vagina, 609.

Sacculus laryngis, 262.
vestibuli, 294.
Sacral artery, lateral, 592.
middle, 594.
ganglia, 600.
nerves, anterior branches, 598.
posterior branches, 142.
plexus, 599.
veins, 596.
Sacro-coccygeal articulation, 613.
iliac, 611.
vertebral, 613.
lumbalis muscle, 135.
sciatic ligament, large, 669.
small, 670.
Salvatella vein, 392.
Saphena vein, external, 683. (o) 705.
internal, 633. 683. (o) 705.
Saphenous opening, 626.
Saphenus nerve, external, 683. (d) 706.
internal, (o) 649. (d) 683. 706.
Sartorius muscle, 639.
Scala tympani, 292.
vestibuli, 292.
Scalenus anticus muscle, 166.
minimus, 168.
posticus, 167.
Scapular artery, posterior, 131.
ligaments, 373.
Scapulo-clavicular articulation, 372, 373.
Scapulo-humeral, 390.
Schneiderian membrane, 244.

Sciatic artery, (o) 593. (d) 665.
nerve, large, (o) 600. (c) 666. 679. (d) 679.
small, (o) 600. (c) 665. (d) 666. 684.
Sclerotic coat of the eye, 102.
Scrotum, 469.
Second nerve, (o) 21. (c) 94. (d) 110.
Secondary membrane of the tympanum, 283.
Semicircular canals, 291.
Semilunar cartilages, 720.
ganglia, 532.
valves of aorta, 342.
of pulmonary artery, 339.
Semi-membranosus muscle, 679. 717.
Seminiferal tubes, 503.
Semi-spinalis colli muscle, 146.
dorsi muscle, 146.
Semi-tendinosus muscle, 678.
Septum auricularum, 336.
crurale, 499. 630.
intermuscular, of the arm, 387.
of the thigh, 646.
lucidum, 37.
medullæ oblongatæ, 28.
nasi, 243.
pontis, 30.
pectiniforme, 605.
scroti, 471.
ventriculorum, 339.
Serratus magnus muscle, 133. 320.
posticus inferior, 132.
superior, 132.
Seventh nerve, (o) 23.
Sheath of the fingers, 408.
of the rectus, 484.
of the toes, 693.
Shoulder-joint, 390.
Sigmoid artery, 521.
flexure of the colon, 509.
valves, 339. 342.
vein, 521.
Sinus basilar, 57.
of the bulb, 604.
cavernous, 57.
circular, of Ridley, 57.
common, of the ear, 294.
lateral, 56.
longitudinal, inferior, 56.
superior, 9.
occipital, 56.
petrosal, inferior, 58.
superior, 57.
pocularis, 604.
prostaticus, 604.
Sinus, straight, of the skull, 55.
of Valsalva, 342.
Sixth nerve (o) 23. (c) 61. (d) 97.
Small intestine, 507. 537.
omentum, 55.
Soft commissure, 44.
Soft palate, 235.
dissection of, 238.
Solar plexus, 533.
Sole of the foot, dissection of, 691.
Soleus muscle, 685.
Spermatic artery, (c) 488. (o) 554. (d) 503.
cord, 488.
fascia, 476.
nerves, 489. (o) 522.
plexus, 522.
veins, 489. (o) 503. (c) 554.
Spheno-palatine artery, 254.
ganglion, 247.
nerves, 247.
Sphenoidal fold of dura mater, 55.
Sphincter ani externus, 455.
internus, 456.
Sphincter vaginæ, 466.
Spigelian lobe, 545.
Spinal accessory nerve (o) 24. (c) 217. (d) 127.
arteries, posterior, 16. 155.
artery, anterior, 17. 154.
cord, 152. 155.
dissection of, 148.
membranes of, 149.
nerves, 153.
filaments of origin, 154. 157.
roots of, 153.
veins, 155.
Spinalis dorsi muscle, 134.
Spiral canal of the modiolus, 292.
Splanchnic nerve, large, 360. (d) 533.
small, 361. (d) 534.
Spleen, form, 528.
relations, 510.
structure, 542.
Splenic artery, 529.
omentum, 516.
plexus of nerves, 533.
vein, 530.
Splenius capitis muscle, 133.
colli, 133.
Spongy bones, 244.
part of the urethra, 584. 604.
Stapedius muscle, 286.
Stapes bone, 287.
Stellate ligament, 362.
Steno's duct, 73.
Sternal nerves, cutaneous, 120.

Sterno-clavicular articulation, 278.
cleido-mastoid muscle, 163.
hyoid muscle, 165.
thyroid, 165.
Stomach, form and divisions, 526.
relations of, 506.
structure of, 535.
Straight sinus, 55.
Stylo-hyoid ligament, 207.
muscle, 179.
nerve, 82.
glossus muscle, 199.
mastoid artery, (o) 183. (d) 289.
maxillary ligament, 189.
pharyngeus muscle, 207.
Sub-arachnoid space, anterior, 13.
of the cord, 150.
posterior, 14.
Subclavian artery, left, 226. (o) 344.
right, 118. 168.
vein, 172.
Subclavius muscle, 319.
Subcutaneus malæ nerve, 99.
Sublingual artery, 201.
gland, 203.
Submaxillary ganglion, 202.
gland, 196.
Submental artery, 182.
Sub-occipital nerve, anterior branch, 219.
Sub-occipital nerve, posterior branch, 138.
Subpubic ligament, 590.
Subscapular artery, 315.
nerves, 319.
vein, 316.
Subscapularis muscle, 367.
Substantia perforata antica, 31.
Sulcus, longitudinal, of the liver, 545.
transverse, 545.
Sulcus of the spinal cord, anterior, 155.
lateral, 156.
posterior, 156.
Superficialis colli artery, 130.
volæ, 398.
Superficial fascia of the abdomen, 469. 471.
of the perinæum, 451.
of the thigh, 623. 625.
Supinator radii brevis, 427.
longus, 422.
Supra-acromial artery, 130.
orbital artery, 2. 95.
nerve, 4. 90.
renal capsule, 559.
plexus, 534.
scapular artery, (o) 130. (d) 374.
nerve, (o) 130. (c) 130. (d) 375.
Supra-spinal artery, 374.
nerve, 375.
spinatus muscle, 374.
trochlear nerve, 90.
Suspensory ligament of the liver, 543.
of the penis, 472.
Sympathetic nerve in the abdomen, 519. 570.
in the neck, 219.
in the pelvis, 600.
in the thorax, 360.

Tænia hippocampi, 38. 42.
semicircularis, 40.
Tapetum, 105.
Tarsal artery, 712.
cartilages, 77.
Tarso-metatarsal articulations, 728.
Teeth, bicuspid, 242.
cuspid, 242.
incisor, 242.
molar, 242.
Temporal aponeurosis, 7.
artery, 184.
deep, 191.
superficial, 184.
muscle, 8. 185.
nerves, deep, 192.
superficial, (d) 4, 5. (o) 99. 194.
vein, 3. 184.
Temporo-facial nerve, 82.
maxillary articulation, 188.
Tendo Achillis, 685.
oculi, 77.
palpebrarum, 77.
Tendon of the quadriceps extensor, 645.
Tensor palati muscle, 236.
tarsi, 100.
tympani, 285.
vaginæ femoris, 643.
Tentorium cerebelli, 54.
Teres major muscle, 371.
minor, 371.
Testes, 48.
Testis, 502.
Thalamus opticus, 45. 47.
Thebesian foramina, 337.
valve, 337.
Thigh, dissection of, back, 659.
front, 621.
Third nerve, (o) 22. (c) 60. (d) 92. 97.
ventricle, 44.
Thoracic duct, (d) 226. (c) 355. (o) 562.
ganglia, 360.
nerves, anterior, 317.

Thoracic nerve, posterior, (c) 131. (o) 174. (d) 319.
Thoracica-acromialis artery, 315.
alaris, 315.
humeraria, 315.
longa, 315.
suprema, 315.
Thorax, boundaries of, 325.
dissection of, 324.
Thyro-arytænoid articulation, 269.
ligaments, 269.
arytænoideus muscle, 260.
epiglottidean ligament, 267.
hyoid membrane, 268.
muscle, 166.
nerve, 180.
Thyroid artery, inferior, 171.
superior, 181.
axis of artery, 170.
body, 227.
cartilage, 266.
plexus of veins, 228.
vein, inferior, 172.
middle, 211.
superior, 182.
Tibial artery, anterior, 710.
posterior, 688.
nerve, anterior, 713. (d) 706.
posterior, 690.
veins, anterior, 712.
posterior, 690.
Tibialis anticus muscle, 708.
posticus, 687. 704.
Tibio-tarsal articulation, 722.
Tongue, dissection of, 256.
nerves of, 257.
structure of, 256.
vessels of, 257.
Tonsil, 238.
Tonsillitic artery, 182.
Torcular Herophili, 55.
Trachea, relations of, 228, 352.
structure of, 269.
Trachelo-mastoid muscle, 136.
Tragus, 78.
muscle, 79.
Transverse fissure of the liver, 546.
ligament of the acetabulum 681.
ligament of the atlas, 277.
of the knee, 721.
perinæal artery, 455
sinus, 57.
Transversalis abdominis muscle, 482.
colli artery, (o) 171. (d) 130.
colli muscle, 136.
Transversalis faciei artery, (o) 184. (d) 71.
fascia, 486.
humeri artery, (o) 171. (d) 130.
Transversus auriculæ muscle, 79.
pedis, 701.
perinæi, 457.
alter, 457.
Trapezius muscle, 124. 127.
Trapezoid ligament, 373.
Triangle of the neck, anterior, 161.
posterior, 116.
Triangular cartilage of the nose, 243.
ligament of the urethra, 459.
space of the thigh, 636.
Triangularis, or depressor sterni muscle, 324.
Triceps extensor cubiti muscle, 386.
Tricuspid valve, 339.
Trigeminal nerve, (o) 22. (c) 60.
Trigone vesical, 603.
Trochlea, 92.
Trochlear nerve, infra, 93.
supra, 90.
Tube of the cochlea, 292.
Tuber cinereum, 31.
Tubercle of Rolando, 53.
Tubercula quadrigemina, 47.
Tuberculum Loweri, 337.
Tubular portions of the kidney, 557.
Tubuli seminiferi, 503.
uriniferi, 557.
Tunica albuginea oculi, 103.
testis, 502.
conjunctiva, 75.
Ruyschiana, 105.
vaginalis, 501.
vasculosa testis, 503.
Tympanic artery, 190.
nerve, (o) 214. (d) 288.
plexus, 288.
Tympanum, 282.
arteries of, 289.
nerves of, 287.
Tyson's glands, 585.

Ulnar artery, 400.
nerve, (o) 318. (c) 383. 402. (d) 393. 410. 418.
veins, 401.
cutaneous anterior, 392.
posterior, 392.
Umbilical region of the abdomen, 505.
Umbilicus, 476.
Ureter, (c) 556. 582.
Urethra, female, 589. 610.
male, divisions, 584.

Urethra, male, interior, 603.
relations, 584.
structure, 603.
Uterine arteries, 595.
plexus of nerves, 597.
veins and sinuses, 597.
Uterus, form of, 607.
ligaments of, 587.
relations of, 588.
structure of, 608.
Uvea, 107.
Uvula cerebelli, 49.
palati, 235.
vesicæ, 602.

Vagina, relations, 588.
structure and form, 609.
Vaginal arteries, 596.
plexus, 597.
veins, 597.
Valve, Eustachian, 337.
ilio-cæcal, 541.
ilio-colic, 541.
mitral, 341.
of the rectum, 606.
semilunar, 339. 342.
sigmoid, 339. 342.
of Thebesius, 337.
tricuspid, 339.
of Vieussens, 51.
Valvulæ conniventes, 536.
Vas deferens (o) 504. (c) 489. 583.
Vasa brevia arteries, 529.
efferentia testis, 503.
recta testis, 503.
vorticosa, 105.
Vascular layer of the retina, 110.
Vasculum aberrans, 504.
Vastus externus muscle, 643. 645.
internus muscle, 644. 645.
Vein, alveolar, 71. 191.
angular, 3. 71.
articular, of the knee, 674. 633.
ascending cervical, 172.
auricular anterior, 192.
posterior, 4. 183.
axillary, 303. 314.
azygos, large, (o) 562. (d) 354.
small, 355.
basilic, 377.
brachial, 384.
brachio-cephalic, left, 345.
right, 345.
bronchial, left, 351.
right, 351.
buccal, 71.
coronary, 71.
of the stomach, 529.
Vein, capsular, 553.
cava, inferior, 524.
superior, 345.
cephalic, (d) 316. (o) 377.
cerebral, 10.
cervicalis ascendens, 172.
profunda, 144.
choroid, 105. 108.
circumflex of the brachial, anterior, 384.
circumflex of the brachial, posterior, 384.
circumflex of the femoral, internal, 638.
circumflex of the femoral, external, 638.
circumflex of the ilium, 491. 624.
colic, left, 521.
right, 519.
coronary, of the heart, 336.
of the lips, inferior, 71.
superior, 71.
of the stomach, 529.
of the corpus cavernosum, 605.
striatum, 39. 43.
deep cervical, 144.
dental, anterior, 206.
inferior, 191.
superior, 255.
diaphragmatic, inferior, 552.
superior, 345.
dorsi-spinal, 144.
dorsal, of the penis, 472.
emulgent, 533.
epigastric, deep, 490.
superficial, 624.
facial, 71. 183.
femoral, 637. 541.
frontal, 3.
of Galen, 43.
gastro-epiploic, left, 529.
right, 531.
hæmorrhoidal, inferior, 596.
middle, 596.
superior, 596.
hepatic, 548.
iliac, common, 555.
external, 555.
internal, 596.
ilio-lumbar, 596.
infra-orbital, 206.
intercostal, 358.
posterior branch, 144.
superior, left, 355.
right, 355.
intra-spinal, 158.
interlobular, 547.
intra-lobular, 549.

Vein, jugular, anterior, 160.
external, 115.
internal, left, 227.
right, 210.
laryngeal, 265.
lingual, 202.
longitudinal, of the spine, anterior, 158.
lumbar, or vertebro-lumbar, 571.
mammary, internal, 170, 324.
masseteric, 71.
mastoid, 183.
of the meatus, 296.
median, of the arm, 392.
basilic, 376.
cephalic, 377.
mediastinal, 345.
maxillary, internal, 191.
mesenteric, inferior, 521.
superior, 519.
nasal, 71.
occipital, 4. 183.
ophthalmic, 97.
palatine, inferior, 71.
superior, 255.
palpebral, inferior, 71. 76.
pancreatic, 530.
parotid, 70.
perinæal, superficial, 455.
pharyngeal, 212.
phrenic, inferior, 552.
superior, 345.
popliteal, 675.
portal, 531. 546. (d) 547.
posterior spinal, plexus of, 158.
transverse, 158.
profunda, of the thigh, 654.
pterygoid plexus, 192.
pudic, external, 624.
internal, 463.
pulmonary, 351.
radial, cutaneous, 392.
ranine, 202.
renal, 533.
sacral, lateral, 596.
middle, 596.
salvatella, 392.
saphena, external, 683. (o) 705.
internal, 633. 682. (o) 705.
sigmoid, 521.
spermatic, left, 554.
right, (o) 503. (c) 489. 554.
spheno-palatine, 255.
spinal, 155.
splenic, 530.
stylo-mastoid, 4.
Vein, subclavian, left, 173.
right, 172.
subscapular, 316.
supra-orbital, 3.
scapular, 131.
temporal, 184.
deep, 4.
superficial, 3.
thyroid, inferior, 172.
middle, 211.
superior, 182.
thoracic, 316.
thoracica-acromial, 316.
tibial, anterior, 712.
posterior, 690.
transverse facial, 72.
of the humerus, 130. 171.
of the neck, 131. 171.
ulnar, 401.
cutaneous, anterior, 392.
posterior, 392.
umbilical, 546.
uterine, 597.
vaginal, 597.
vertebral, 170. (o) 272.
vertebro-costal, 358.
lumbar, 571.
vesical, 596.
vidian, 289.
Vallecula, or valley, 49.
Velum interpositum, 43.
pendulum palati, 235.
Vena cava, inferior, 524.
superior, 345.
portæ, 531. 546, (d) 547
Venæ cavæ hepaticæ, 548.
Venous arch of the foot, 705.
of the hand, 392.
Ventricles of the brain, 36.
fifth, 38.
fourth, 52.
lateral, 36.
third, 44.
Ventricles of the heart, 335.
left, 341.
right, 338.
of the larynx, 261.
Vermiform appendix, 539.
process, inferior, 49.
superior, 49.
Vertebral artery, (o) 170. (c) 143. 272. (d) 17.
plexus, 273.
vein, 170. (o) 272.
Vessels of the brain, 16.
of the dura mater, 58.
Verumontanum, or caput gallinaginis, 603.

Vesica urinaria, 579, 580. 582. 602.
Vesical artery, inferior, 595.
middle, 595.
superior, 595.
fascia, 576.
plexus of nerves, 597.
veins, 596.
Vesiculæ seminales, relations, 583.
structure, 601.
Vestibule, 290.
Vidian artery, 58. 289.
nerve, 249.
Villi, intestinal, 537.
Vitreous body, 111.
fluid, 112.
Vitreous humour of the ear, 294.
of the eye, 112.
Vocal cords, 262.
Vulva, 607.

Wharton's duct, 196, 204.
Wilson's muscles, 460.
Winslow's foramen, 516.
Wrisberg's nerve (o) 318. (c) 383. (d) 383.
Wrist-joint, 434.

Zygomaticus major muscle, 67.
minor, 67.
Zonula of Zinn, 112.

THE END.

LONDON:
Printed by A. SPOTTISWOODE,
New-Street-Square.

B.P.L. Library

Rare Books
3.A.43
Demonstrations of anatomy : bei1840
Countway Library BDX3458
3 2044 045 561 941

Rare Books
3.A.43
Demonstrations of anatomy : bei1840
Countway Library BDX3458
3 2044 045 561 941